

Clinical Management of the White Spot Lesions After Vital Tooth Bleaching: A Case Report

Vital Beyazlatma Sonrası Oluşan Beyaz Nokta Lezyonlarında Klinik Yaklaşım: Olgu Sunumu

Dilek AKIN¹

<https://orcid.org/0000-0003-1713-7508>

Çiğdem ATALAYIN ÖZKAYA¹

<https://orcid.org/0000-0003-4144-4233>

Frederic MEYER²

<https://orcid.org/0000-0002-0940-2458>

Joachim ENAX²

<https://orcid.org/0000-0002-8334-6423>

¹Ege University School of Dentistry, Department of Restorative Dentistry, Izmir

²Research Department, Dr. Kurt Wolff GmbH & Co. KG, Bielefeld, Germany

Citation/Atf: Akın, D., Atalayın Özkaya, Ç., Meyer, F., Enax, J., (2023). Clinical Management of the White Spot Lesions After Vital Tooth Bleaching: A Case Report. Ege Üniversitesi Diş Hekimliği Fakültesi Dergisi, 2023; 44_3, 241-245.

ABSTRACT

Tooth-bleaching agents may lead to alterations on enamel surface. These changes require clinical treatment when they become visible and not limited with ultrastructural alterations. The aim of this case report is to present how white spot lesions, one of the potential side effects that can be encountered after tooth-bleaching, were treated by the combination of different remineralization agents. In a 28-year-old female patient, demineralized areas on the enamel surface were detected on the fourth day after office bleaching with 40% hydrogen peroxide (Opalescence Boost PF). The patient reported no post-operative hypersensitivity. Topical fluoride gel (1.23% APF-Imicryl) and fluoride varnish (5% NaF-Clinpro 3M ESPE) were applied respectively by one week interval. The lesions were less noticeable but they still exist at the follow-up one week later after the application. A toothpaste containing hydroxyapatite with fluoride free formulation-Karex was administered for daily oral care. One week later, it was observed that all demineralized areas were completely remineralized and the tooth color was determined as A1 with Vita color guide. The combined and gradually use of different remineralization agents in the treatment of white spot lesions after vital tooth-bleaching may be a clinically effective strategy.

Keywords: Tooth bleaching, toothpaste, remineralization, fluoride, hydroxyapatite

ÖZ

Beyazlatma tedavileri mine yüzeyinde değişikliklere ve demineralizasyona neden olabilmektedir. Bu değişiklikler ultrastrüktürel yapı ile sınırlı kalmayıp, gözle görünür hale geldiğinde klinik tedavi gerektirmektedir. Bu olgu sunumunun amacı; beyazlatma tedavisi sonrası karşılaşılabilecek yan etkilerinden biri olan beyaz nokta lezyonlarının, farklı remineralizasyon ajanlarının kombine kullanımı ile tedavisini aktarmaktır. Bu olguda 28 yaşındaki kadın hastada % 40 hidrojen peroksit (Opalescence Boost PF) ile yapılan ofis tipi beyazlatma sonrası dördüncü günde, beyaz nokta lezyonları tespit edildi. Hastada uygulama sonrasında hassasiyet oluşmadığı saptandı. Lezyonların remineralizasyonu için bir hafta arayla, sırasıyla topikal florür jeli (% 1.23 APF-Imicryl) ve florür vernik (% 5 NaF-Clinpro 3M ESPE) uygulandı. Uygulamadan bir hafta sonraki kontrol seansında lezyonların daha az farkedilir hale geldiği, ancak halen mevcut olduğu gözlemlendi. Bu seansta hastaya günlük kullanım için hidroksiapatit içerikli flor içermeyen diş macunu (Karex) tavsiye edildi. Bir hafta sonraki kontrol seansında tüm lezyonların iyileştiği saptandı ve diş rengi Vita Skalası ile A1 olarak kaydedildi. Farklı remineralizasyon ajanlarının aşamalı ve kombine kullanımı, beyazlatma sonrası oluşan beyaz nokta lezyonlarının tedavisi için etkili bir strateji olabilir.

Anahtar Kelimeler: Diş beyazlatma, diş macunu, remineralizasyon, flor, hidroksiapatit

Sorumlu yazar/Corresponding author*: dilekaknn@gmail.com

Başvuru Tarihi/Received Date: 30.03.2022

Kabul Tarihi/Accepted Date: 07.06.2023

INTRODUCTION

In recent years, cosmetic dentistry has become more important for patients and they have increasing demand for whiter teeth.^{1,2} In line with this demand, tooth bleaching is a treatment option that has a very common application area in dental practice and frequently requested by the patients. The most widely used method and technique for tooth whitening is the application of hydrogen peroxide (HP) containing agents. Bleaching treatment is basically divided into two concepts as vital and devital tooth bleaching. Vital tooth bleaching can be classified as 'office-type' with using high-concentrated products applied by the dentist in the dental office, and 'home-type' with using lower-concentrated products applied at home via prepared individual tray. Office-type bleaching is preferred by patients desiring rapid result. Bleaching occurs through the process of chemical degradation of chromophores by HP.³ HP is highly reactive compound that decomposes into water and reactive oxygen radicals. It is highly soluble, yields an acidic solution and the pH varies according to concentration. The pH of 1 % HP solution has been reported to be 5-6.⁴

There are several risks and possible side effects caused by oxidant agents used for tooth-bleaching.² The mineral content of the enamel decreases with the use of high concentrations of peroxide and it results in reduced enamel hardness and increased surface roughness.⁵ Additionally, tooth-bleaching agents may lead to alterations in the mineral content of the enamel surface.⁶ The potential side effects such as enamel hardness reduction, enamel roughness alteration, enamel surface loss, demineralization, color change and tooth hypersensitivity may be encountered after tooth-bleaching.

The aim of this case report is to present how demineralized areas, one of the potential side effects that can be encountered after tooth bleaching, were treated by the application of biomimetic remineralization strategy.

CASE REPORT

A 28-year-old female patient presented at Ege University School of Dentistry, Department of Restorative Dentistry, dissatisfied with her present tooth color. After taking anamnesis, it was determined that she used fluoride-free toothpaste. At clinical examination there was no caries, cracks and demineralized areas in the teeth. Both types of tooth-bleaching options as home and office-type were presented to the patient. The patient preferred the office-type tooth-bleaching method due to her drawbacks about home-bleaching (application procedures, using tray etc.) and limited time. Therefore, it was decided to apply office-bleaching.

The initial tooth color of the patient was determined as B2 with Vita classical shade guide (Figure 1A). In office-type bleaching Opalescence Boost PF 40% (Ultradent Products Inc., South Jordan UT) was applied according to the manufacturer's instructions. The bleaching gel was applied using a micro brush tip provided and the agent was removed from the tooth surface by aspiration 20 min later. The change in color shade was evaluated after the each application and the patient was kept under observation for sensitivity and irritation. Since the persistent tooth sensitivity was not occurred, the bleaching procedure was repeated three times at one session in line with the manufacturer's recommendations.

After the bleaching tooth color was determined as A1 (Figure 1B), the patient was informed about the restrictions and the recommendations and a follow-up appointment was arranged one week later. Four days after the application, the patient stated that she realized chalky opaque points on her teeth, but she did not report hypersensitivity. The patient was examined at the same day and demineralized areas/white spot lesions were detected on the enamel surfaces of incisor and premolar teeth (Figure 2A). The recurrent demineralization of remineralized post-orthodontic white spot lesions was suspected, but the patient declared she had not received orthodontic treatment previously. It was decided to begin the treatment with a topical fluoride agent, which is frequently used in the clinic. Topical fluoride gel containing 1.23% acidulated phosphate fluoride and 2% neutral fluoride (Imicryl, Turkey) was applied for 4 minutes according to the manufacturer's instructions. The patient was advised to minimize the acidic beverages/foods and to consume milk and dairy products to improve the calcium availability for remineralization. In addition, the patient was advised to brush her teeth with fluoride containing toothpaste regularly in daily oral care. One week later, the lesions were observed to shrink (Figure 2B). Therefore, it was decided to apply the fluoride varnish, which has more stable form than fluoride gel on the tooth surface. The fluoride varnish containing 5% sodium fluoride in combination with tricalcium phosphate (Clinpro, 3M ESPE, USA) which uniformly set to dentition in the presence of saliva, was applied to teeth with white spot lesions. The visibility of the lesions decreased noticeably, but they were still exist at the follow-up one week later (Figure 2C). A fluoride-free toothpaste based on hydroxyapatite (Karex, Germany) was administered for daily oral care in this period. One week later, it was observed that all demineralized areas were remineralized and the tooth color was determined as A1 (Figure 2D). The patient was advised to continue with the daily oral care routine with a toothpaste containing hydroxyapatite. The treatment approach applied was summarized in the flow chart (Figure 3). At the two-month follow up after the

bleaching, there was no demineralized areas detectable and the tooth color remained as A1 (Figure 4).

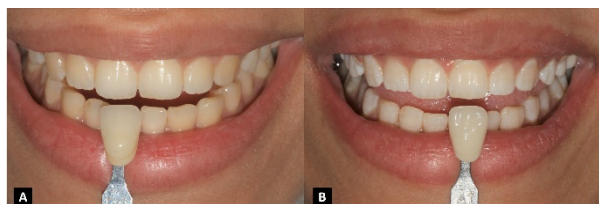


Figure 1: The view before and after tooth bleaching. A: The initial tooth color determination B: The tooth color immediately after the bleaching.

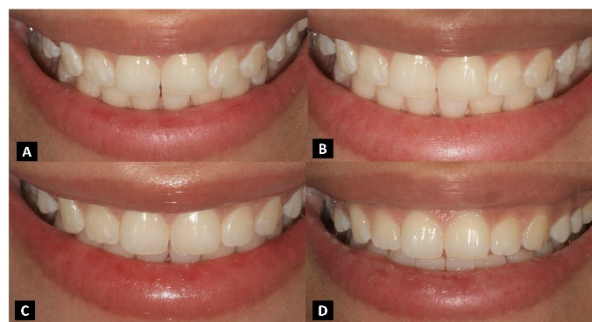

Figure 2: The white spot lesions occurred after tooth bleaching and intraoral condition during the remineralization treatment. A: Demineralized areas on fourth day after the bleaching. B: One week after the topical fluoride gel application. C: One week after the fluoride varnish application. D: One week after using the hydroxyapatite toothpaste.

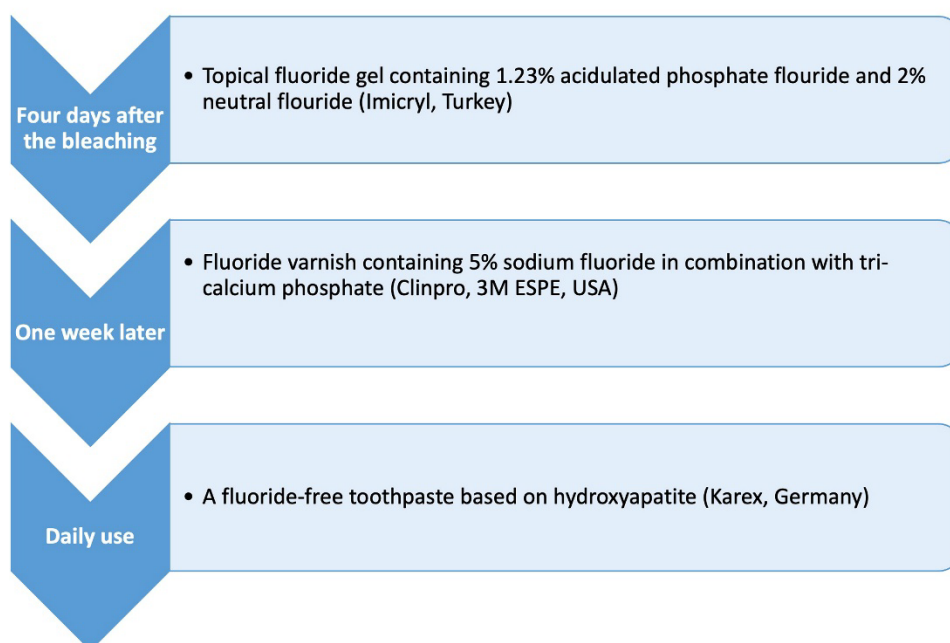


Figure 3: Flow chart of the treatment approach.

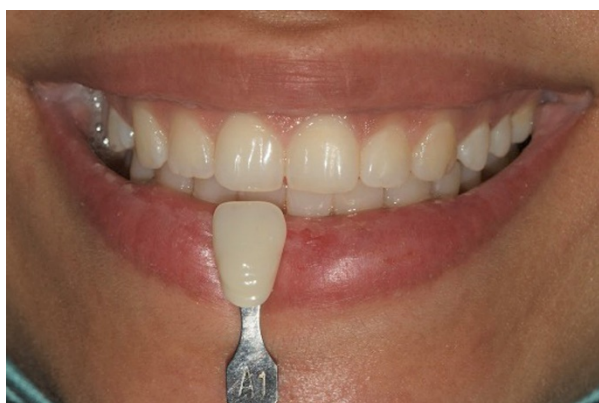

Figure 4: The view after two months.

DISCUSSION

The bleaching agents mostly have an acidic pH, creating an erosive environment, and contributing to the loss of enamel inorganic components.⁷ The side effects of the tooth bleaching on enamel such as demineralization may be recovered by remineralization agents such as fluoride, calcium, amorphous calcium phosphate and hydroxyapatite.⁸ Remineralization agents can be also used to compensate increased surface roughness and dentin hypersensitivity after tooth bleaching, contribute to maintaining the color stability and eliminate alterations and damages on the enamel surface.⁹⁻¹¹

The clinical management of a patient having demineralized areas after the tooth bleaching is presented in this case report. There is no definite clinical treatment protocol for such cases in the literature. Demineralization on the enamel surface after bleaching treatment is eliminated within 24 hours by the remineralizing effect of saliva.^{12,13} In this case, the effect of saliva was thought to be insufficient and remineralization agents were used. After the lesions were occurred, it was aimed to obtain a faster result to relieve the patient's anxiety. Therefore, the remineralization agents in different form and type were applied gradually as the treatment approach in this case. Topical fluoride gel was applied firstly on the fourth day after the bleaching and fluoride containing toothpaste was recommended for daily use. In the control session one week later, it was aimed to increase the effect by changing the form of the remineralization agent. The varnish becomes stable due to setting in the presence of saliva. Prolonged contact of fluoride with teeth increases fluoride incorporation into the enamel surface.¹⁴ For this reason, 5% sodium fluoride varnish with tricalcium phosphate was applied only to the lesion. It was aimed to provide calcium release and improve remineralization in addition to fluoride release into the oral environment. The lesions had become smaller after fluoride varnish application, but they were still existed. At this point it was decided to support the treatment via changing the type of remineralization agent. Hydroxyapatite particles have been incorporated in toothpastes for remineralization. After an erosive or abrasive attack, hydroxyapatite particles can attempt to repair (remineralize) enamel as they have proven to self-assemble and create enamel like structures in aqueous solutions.^{15,16} Hydroxyapatite is known as a substance replicating natural dental enamel and ensure biomimicry. Biomimetic hydroxyapatite particles have remineralization capacity to rebuild tooth mineral.¹⁷⁻¹⁹ Compared to fluoride, hydroxyapatite particles can penetrate deeper layers of the lesion.¹⁹ In order to benefit from this effect and advantage of hydroxyapatite, in addition to the fluoride for the remineralization strategy, the patient was recommended to use hydroxyapatite-

based toothpaste for daily use. In the control session one week later, it was determined that all lesions were healed completely by the applied biomimetic remineralization strategy.

In the treatment approach in this case, in addition to the application of remineralization agents, daily recommendations were also administered. The patient was recommended to minimize the intake of acidic food and drinks and consume milk and dairy products for a sufficient calcium intake to support remineralization. Casein is known as a milk protein and casein-containing agents have a high affinity to bind and aggregates with calcium and phosphate ions in hard tissue and ensure to maintain the saturation of calcium and phosphate ions. Thus, the demineralization process caused by erosive attacks may be prevented.²⁰

Remineralization is a process by which minerals such as calcium and phosphate precipitate on the enamel surface under favourable intraoral conditions.¹⁰ Although the white spot lesions which appeared after tooth bleaching seem scary initially, they could be remineralized in this case with the patient's compliance and application of different remineralization strategies gradually. However, waiting longer than one week between the applications of remineralization agents could also be an effective treatment approach until the size of the lesion does not change. It was preferred to apply different agents to achieve expeditious results effectively and relieve the patient anxiety in this case. The degree and formation of demineralized areas, one of the side effects that occur after tooth bleaching, may vary according to the patient related factors and the other components such the type, content, concentration, application method and duration of the bleaching agent used. The combined use of different remineralization agents in the treatment of these lesions may be a clinically effective treatment approach. Moreover, a peroxide-free concept for a gentle and safe tooth bleaching may be the usage of hydroxyapatite products.^{11,21-23} Further researches and clinical trial findings are needed on this subject.

REFERENCES

1. Akarslan ZZ, Sadik B, Erten H, Karabulut E. Dental esthetic satisfaction, received and desired dental treatments for improvement of esthetic. *Indian J Dent Res* 2009; 20: 195-200.
2. Epple M, Meyer F, Enax J. A Critical Review of Modern Concepts for Teeth Whitening. *Dent J (Basel)* 2019; 7: 79.
3. Alkahtani R, Stone S, German M, Waterhouse P. A review on dental whitening. *J Dent* 2020; 100: 103423.
4. Walsh L J. Safety Issues Relating to the Use of Hydrogen Peroxide in Dentistry. *Aust Dent J* 2000; 45: 257-269.
5. Cunha AG, Vasconcelos AA, Borges BC et al. Efficacy of in-office bleaching techniques bined with the application of a casein phosphopeptide-amorphous calcium phosphate paste at different moments and its influence on enamel surface properties. *Microsc Res Tech* 2012; 75: 1019-1025.
6. Monteiro D, Moreira A, Cornacchia T, Magalhaes C. Evaluation of the effect of different enamel surface treatments and waiting times on the staining prevention after bleaching. *J Clin Exp Dent* 2017; 9: 677-681.
7. Demarco FF, Meireles SS, Sarmiento HR, Dantas RV, Botero T, Tarquinio SB. Erosion and Abrasion on Dental Structures Undergoing at-Home Bleaching. *Clin Cosmet Investig Dent* 2011; 3: 45-52.

8. Sasaki RT, Catelan A, Bertoldo Edos S et al. Effect of 7.5% hydrogen peroxide containing remineralizing agents on hardness, color change, roughness and micromorphology of human enamel. *Am J Dent* 2015; 28: 261-267.
9. Gümüştaş B, Dikmen B. Effectiveness of remineralization agents on the prevention of dental bleaching induced sensitivity: A randomized clinical trial. *Int J Dent Hyg* 2022; 20: 650-657.
10. Bilge K, Kılıc V. Effects of different remineralizing agents on color stability and surface characteristics of the teeth following vital bleaching. *Microsc Res Tech* 2021; 84: 2206-2218.
11. Sarembe S, Enax J, Morawietz M, Kiesow A, Meyer F. In vitro whitening effect of a hydroxyapatite-based oral care gel. *Eur J Dent* 2020; 14: 335-341.
12. Yu D, Gao S, Min J, Zhang Q, Gao S, Yu H. Nanotribological and Nanomechanical Properties Changes of Tooth After Bleaching and Remineralization in Wet Environment. *Nanoscale Res Lett* 2015; 10: 463.
13. Basting RT, Rodrigues AL Jr, Serra MC. The effects of seven carbamide peroxide bleaching agents on enamel micro-hardness over time. *Journal of the American Dental Association* 2003; 134: 1335-1342.
14. Ercan E, Bağlar S, Çolak S. Topical Fluoride Application Methods in Dentistry. *Cumhuriyet Dent J* 2010; 13: 27-33.
15. Robinson C, Connell S, Kirkham J, Shore R, Smith A. Dental Enamel a Biological Ceramic: Regular Substructures in Enamel Hydroxyapatite Crystals Revealed by Atomic Force Microscop. *J Mater Chem* 2004; 14: 2242-2248.
16. Tao J, Pan H, Zeng H, Xu X, Tang R. Roles of Amorphous Calcium Phosphate and Biological Additives in the Assembly of Hydroxyapatite Nanoparticles. *J Phys Chem B* 2007; 111: 13410-13418.
17. Meyer F, Enax J, Amaechi BT et al. Hydroxyapatite as remineralization agent for children's dental care. *Front Dent Med* 2022; 3; 859560.
18. O'Hagan-Wong K, Enax J, Meyer F, Ganss B. The use of hydroxyapatite toothpaste to prevent dental caries. *Odontology* 2022; 110: 223-230.
19. Limeback H, Enax J, Meyer F. Biomimetic hydroxyapatite and caries prevention: a systematic review and meta-analysis. *Can J Dent Hyg* 2021; 55: 148-159.
20. Somasundaram P, Vimala N, Mandke L G. Protective Potential of Casein Phosphopeptide Amorphous Calcium Phosphate Containing Paste on Enamel Surfaces. *J Conserv Dent* 2013; 16: 152-156.
21. Shang R, Kaisarly D, Kunzelmann KH. Tooth whitening with an experimental toothpaste containing hydroxyapatite nanoparticles. *BMC Oral Health* 2022; 22: 331.
22. Shang R, Kunzelmann KH. Biomimetic tooth-whitening effect of hydroxyapatite-containing mouthrinses after long-term simulated oral rinsing. *Am J Dent* 2021; 34: 307-312.
23. Steinert S, Zwanzig K, Doenges H, Kuchenbecker J, Meyer F, Enax J. Daily application of a toothpaste with biomimetic hydroxyapatite and its subjective impact on dentin hypersensitivity, tooth smoothness, tooth whitening, gum bleeding, and feeling of freshness. *Biomimetics (Basel)* 2020; 5: 17.