

Effects of Midazolam, Propofol and Thiopental on Gastric Ulcer in Rats

Nilay Boztaş¹, Şule Özbilgin¹, Mücahit Özbilgin², Ebru Taylan³, Mehtat Ünlü⁴, Sevda Özkardeşler¹, Mert Akan⁵, Bülent Serhan Yurtlu¹, Volkan Hancı¹

¹Department of Anesthesiology and Reanimation, Dokuz Eylul University, Izmir, Turkey

²Department of General Surgery, Dokuz Eylul University, Izmir, Turkey

³Department of Biochemistry, Dokuz Eylul University, Izmir, Turkey

⁴Department of Pathology, Dokuz Eylul University, Izmir, Turkey

⁵Department of Anesthesiology and Reanimation, Kent Hospital, Izmir, Turkey

Abstract

Introduction: The present study was conducted to research whether the intravenous (iv) anesthetics of propofol, midazolam and thiopental have a protective effect against gastric injury induced in rats with indomethacin.

Methods: Rats were randomly divided into 6 groups (n=7). Rats in Group 1 (n=7) had 8 ml/kg saline administered via gavage. Rats in Group 2 (n=7) were administered 25 mg/kg indomethacin via gavage. Rats in Group 3 (n=7) were given 20 mg/kg famotidine intraperitoneal. Rats in Group 4 (n=7) were given 40 mg/kg propofol intraperitoneal. Rats in Group 5 (n=7) were administered 40 mg/kg thiopental intraperitoneal. Rats in Group 6 (n=7) were administered 10 mg/kg midazolam intraperitoneal and then 5 minutes later 25 mg/kg indomethacin via gavage in all groups except Group 1. All groups were sacrificed 6 hours after administration of oral indomethacin and gastrectomy was performed. All samples were photographed. Macroscopic photographs were uploaded to a computer. A pathologist used the "Olympus Stream Start" image analysis method to measure the size of the ulcer areas on photographs of each stomach excision sample in "pixels". The total number of ulcers and total ulcer area were calculated for each rat. Other pieces of gastric tissue were assessed with histopathological study.

Results: Clear ulceration was observed in the gastric mucosa of the indomethacin group. The iv anesthetic medications of propofol, midazolam and thiopental used in the study did not have any antiulcer efficacy.

Discussion and Conclusion: It was determined that propofol, midazolam and thiopental had no protective effect against gastric injury induced in rats with indomethacin.

Keywords: Indomethacin; rats; stomach ulcer.

In anaesthesia and intensive care applications and after surgical stress, the development of gastric ulcers is commonly observed. Among the causes of gastric ulcers, an imbalance of aggressive factors (increased acid secretion) and protective factors [mucus, bicarbonate, prostaglandins (PGs)], stress, sepsis, trauma, haemorrhagic shock, Helicobacter pylori, smoking, and the use of alcohol, steroids and non-steroidal anti-inflammatory drugs (NSAIDs) may be included^[1]. The pathophysiological effects of gastric ulcers include oxidative stress, reduced antioxidants, neutrophil accumulation, increased inflammatory cytokines and reduced blood flow to the gastric mucosa^[2]. Of the

Of the

Correspondence (İletişim): Nilay Boztaş, M.D. Dokuz Eylul Üniversitesi Anesteziyoloji ve Reanimasyon Anabilim Dalı, Izmir, Turkey

Phone (Telefon): +90 505 224 27 52 **E-mail (E-posta):** nilayboztas@hotmail.com

Submitted Date (Başvuru Tarihi): 04.03.2019 **Accepted Date (Kabul Tarihi):** 11.04.2019

Copyright 2021 Haydarpaşa Numune Medical Journal

OPEN ACCESS This is an open access article under the CC BY-NC license (<http://creativecommons.org/licenses/by-nc/4.0/>).



stress-related mucosal diseases, ulceration and bleeding are the most important causes that increase morbidity and mortality. The basic factor in preventing stress-related mucosal ulcerations is the suppression of acid production. Exposure to ulcerogenic substances causes an excessive production of reactive oxygen species (ROS); however, the mucus layer and endogenous antioxidants protect the gastro-intestinal system against cytotoxicity, which is linked to free oxygen radicals (FORs)^[3]. Excessive FOR production causes infiltration of activated neutrophils, which leads to disrupted gastric microcirculation. Reduced mucosal circulation is an aetiological factor for gastric ulcers^[4].

Non-steroidal medications inhibit endogenous PG synthesis by cox blockage; however, inhibition of PG synthesis is not sufficient alone to induce ulcer formation^[5]. Other mechanisms may include leukocyte adhesion to the vascular endothelium^[6], the production of FORs and an increase in proteases^[4]. FORstamamdir sadece are a part of enzymatic reactions in organisms, often as products of oxidation reactions and play an important role in gastric ulcer pathophysiology^[7].

PGs in the L-arginine/nitric oxide pathway are the major protective factors that cause relaxation of arterial smooth muscle in the gastric mucosa. Nitric oxide synthase inhibition aggravates gastric injury in gastric ulcer animal models^[8].

Among the traditional prophylactic choices for gastric ulcers there are antacids, sucralfate, histamine (H₂) receptor antagonists, and proton pump inhibitors. Currently, though there are many medications used for gastric ulcer treatment, none of these medications are curative because gastric ulcers are multi-aetiological and chronic diseases^[9]. In anaesthesia and intensive care applications, many intravenous agents are used for anaesthesia and sedation. Propofol (2,6-diisopropylphenol) is a commonly used intravenous anaesthetic, sedative and hypnotic agent. The hydroxyl group inhibits lipid peroxidation, and in continuous infusion, especially for the management of refractory status epilepticus, propofol has a low clearance rate. Thiopental is a weak acid and has low solubility in water^[10]. Midazolam is a benzodiazepine with a high clearance rate and may be used as premedication and induction agent during anaesthesia. It ensures sedation and hypnosis through GABA. GABA is an inhibitory neurotransmitter in the CNS^[11].

Previous studies have suggested that centrally administered endogenous opioids inhibit gastric acid secretion, but peripheral administration of these compounds enhances acid secretions and can potentiate gastric erosion^[12].

However in the literature, the gastroprotective effects of

different effective materials have been researched in a variety of experimental animal models^[13,14]. Additionally, the number of studies on the gastroprotective effects of anaesthetic agents in experimental ulcer models are very limited^[15-20].

The hypothesis of our study is that the intravenous induction agents propofol, thiopental and midazolam, which have antioxidant properties that have been emphasized in previous studies, will have beneficial effects in preventing the acute gastric injury induced by indomethacin. To test this hypothesis in our study, the effects of propofol, midazolam and thiopental on the gastric ulcers of rats with indomethacin-induced gastric injury will be assessed.

Materials and Methods

The surgical procedure, use of anaesthesia, and animal care methods in the experiments were consistent with the guidelines in the National Institute of Health's Guide for the Care and Use of Laboratory Animals (National Institutes of Health Publication No. 86-23, revised 1985, Bethesda, MD). The study was completed after receiving approval from the Dokuz Eylul University Animal Experiments Local Ethics Committee (Project No: 18/2014, President Prof. Dr. Osman Yılmaz, date: 15.04.2014) at Dokuz Eylul University Multi-disciplinary Experimental Animals Laboratory. The study used a total of 42 male Wistar Albino rats weighing 250-300 g with each group comprising of 7 animals. The rats were housed in standard conditions (temperature 22-24 °C, 12 hours light/12 hours darkness).

All animals were fed with standard pellet feed and given a sufficient amount of water. Considering that it may affect the gastric function of all subjects, feeding was at the same time every day to avoid diurnal variation^[13].

Famotidine and indomethacin were dissolved in distilled water. All medication solutions were prepared fresh. Rats were administered oral indomethacin via gavage after 16-18 hours of starvation with the aim of creating a gastric ulcer.

For laboratory experimentation, indomethacin, famotidine, and sodium thiopental, propofol, and midazolam were obtained from Deva Holding Cor. (Istanbul), Fako (Istanbul) and IE-Ulagay (Istanbul), Abbot Co. (England), Dem Medical and Pharmaceutical Warehouse Industry and Trade Limited Company (Istanbul) respectively.

Experimental Groups and Protocol

Rats were randomly divided into 6 groups.

Group 1 (*sham*, n=7): rats were administered with 8 ml/kg saline via gavage.

Group 2 (indomethacin, n=7): rats were administered with 25 mg/kg indomethacin in 8 ml/kg saline via gavage.

Group 3 (famotidine, n=7): rats were administered with 20 mg/kg famotidine (Nevofam-L IM/IV 20 mg ampoule containing lyophilized injectable powder) i.p., then 25 mg/kg indomethacin in 8 ml/kg saline via gavage 5 minutes later.

Group 4 (propofol, n=7): As described previously rats were administered with 40 mg/kg propofol intraperitoneally, then 25 mg/kg indomethacin in 8 ml/kg saline via gavage 5 minutes later^[21].

Group 5 (thiopental, n=7): As described previously rats were administered with 40 mg/kg thiopental i.p., then 25 mg/kg indomethacin in 8 ml/kg saline via gavage 5 minutes later^[22].

Group 6 (midazolam, n=7): As described previously rats were administered with 10 mg/kg midazolam i.p., then 25 mg/kg indomethacin in 8 ml/kg saline via gavage 5 minutes later^[23].

All animals completed the study. The antiulcer effects of the intravenous anaesthetics were researched using an indomethacin-induced ulcer model^[24]. All groups had 100 mg/kg ketamine (Ketalar®, Parke Davis-Eczacıbaşı, Istanbul, Turkey) i.p. administered 6 hours after oral indomethacin administration, and the rats were then sacrificed via cardiac puncture. Gastrectomy was rapidly performed via an abdominal incision on the midline. Gastric tissue was divided in two, with one portion stored for histopathological investigation^[1,25].

Each stomach tissue sample obtained for pathology was placed on a flat platform along the large curvature with incision performed along the small curvature and then washed with ice water. To photograph gastric tissue, all corners were opened, and the tissue was stretched. All samples were photographed from an equal distance at equal magnification. Macroscopic photographs were uploaded to a computer. A pathologist used the "Olympus Stream Start" image analysis software to measure the size of the ulcer areas in "pixels" on photographs of each excised sample. All images including the largest and smallest ulcer area, the numbers were saved, and the total number of ulcers and total ulcer area was calculated for each rat^[26].

Histopathological Assessment: A piece of gastric tissue from each rat containing ulcer area and normal mucosa, as determined using a light microscope, was placed in 10% neutral formalin for 24 hours for fixation and processed for routine tissue analysis. Sections 5 µm thick were ob-

tained and stained with haematoxylin and eosin. Histological changes were assessed with a light microscope by a pathologist who was blind to the study. This assessment was used to show that ulcers had developed microscopically. All stomach tissue was not monitored, and there was no microscopic measurement made related to ulceration.

Rats with resuscitation requirements were planned to be excluded from the study; however, no rat required resuscitation in any group.

Statistical Analysis

Statistical analysis was performed using Statistical Package for the Social Sciences (SPSS) Version 15. Comparisons between the groups were assessed by the Mann-Whitney U test. All data are presented as the mean±SD. Values of $p<0.05$ were accepted as statistically significant.

Results

The study included a total of 42 rats. All of the rats finished the study. There were no significant differences between the ages or the weights of the rats ($p>0.05$).

Besides the sham and famotidine groups, all groups were observed to have ulcer formation linked to NSAIDs.

When we compared the sham group with the indomethacin group, there was a significant difference in terms of the number of ulcers and the ulcer area ($p<0.05$).

There was no significant difference observed in terms of ulcer number or area between the famotidine group and the sham group ($p>0.05$).

There were significant differences observed between each of the other 3 experimental groups that were administered anaesthetic medications and the sham and famotidine groups ($p<0.05$).

In the groups administered intravenous anaesthetics, the number of gastric mucosal ulcers was higher, and the ulcer area was greater compared to that in the indomethacin group, though there was no significant difference ($p>0.05$). In terms of the smallest ulcer area, there were no significant differences observed between the groups administered intravenous anaesthetics and the indomethacin group ($p>0.05$).

In terms of the largest ulcer area, though there were no significant differences between the groups given intravenous propofol and midazolam, and the largest ulcer area in the thiopental group was significantly larger than that in the indomethacin group ($p<0.05$) (Table 1). In the damaged stomachs, mucosal lesions of various sizes and forms were

Table 1. Effects of intravenous anaesthetic (propofol, thiopental, and midazolam) administration on indomethacin-induced ulcers in the rat stomach

Group	Ulcer count	Ulcer area (pixels)	Largest ulcer area (pixels)	Smallest ulcer area (pixels)
Sham	1.85±4.91	4.12±10.9	2.1±5.57	0.89±2.37
Indomethacin	9.42±10.42*	323.52±513.87*	53.25±59.48*	4.03±3.37
Famotidine	1.00±1.00	16.51±17.26	11.51±12.32	7.91±8.07
Propofol	17.00±10.39*	510.22±372.71*	80.80±58.10*	5.15±1.96*
Thiopental	13.57±6.77*	486.99±246.37*	133.18±47.45* [†]	7.18±5.03*
Midazolam	13.71±5.49*	392.24±168.54*	73.39±39.36*	5.38±4.91*

*: p<0.05; Significantly different from the sham group; Mann-Whitney U test; [†]: p<0.05; Significantly different from the indomethacin group; Mann-Whitney U test.

dispersed over all stomach surfaces. Lesions of the gastric mucosa in each group are shown in Figure 1.

Microscopic views of the normal and damaged gastric mucosa are shown in Figure 2.

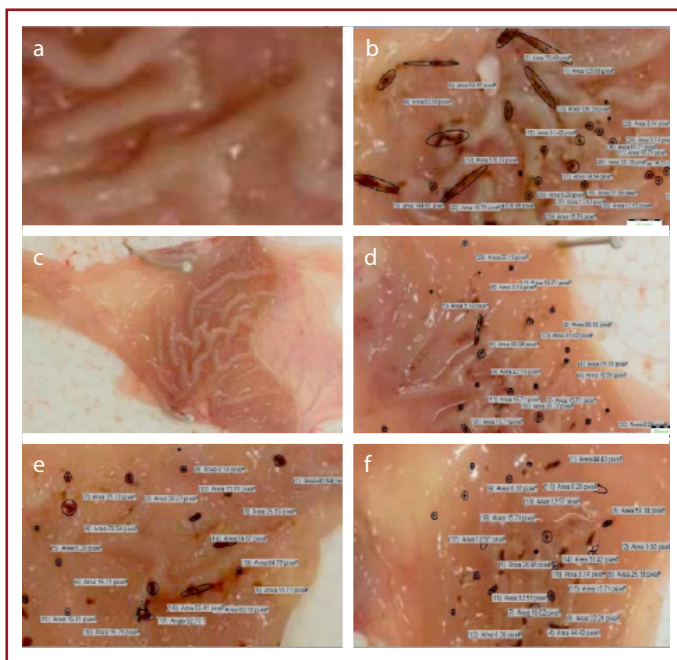


Figure 1. Photographs of rat gastric mucosa. **(a)** Normal mucosa in the sham group. **(b)** Severe mucosal injury in the indomethacin group. **(c)** Protected gastric mucosa in the famotidine group **(d)** Severe mucosal injury in the group pretreated with propofol. **(e)** Severe mucosal injury in the group pretreated with thiopental. **(f)** Severe mucosal injury in the group pretreated with midazolam.

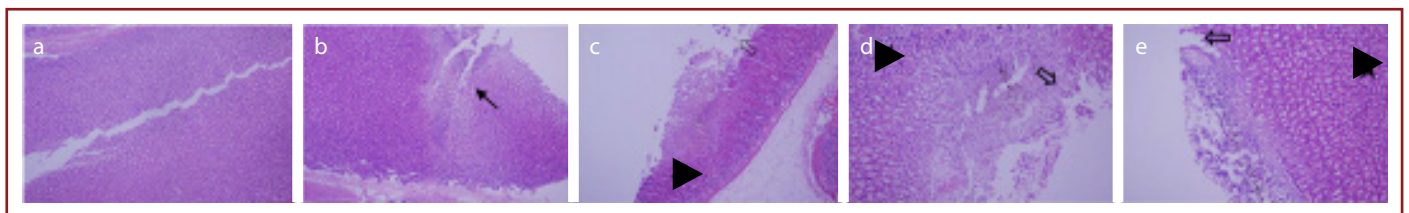


Figure 2. Histopathological examination of rat gastric mucosa. **(a)** Normal gastric mucosa in the sham group and the famotidine group. **(b)** Deep mucosal ulceration in the indomethacin group. **(▶)** **(c, d, e)** Widespread necrosis with loss of the surface epithelium (=) and marked neutrophil infiltration (▶).

Discussion

In our study assessing the protective effects against ulcers of different intravenous anaesthetic medications in an indomethacin-induced ulcer model in rats, there was clear ulceration observed histopathologically in the gastric mucosa of the group that was administered indomethacin alone. None of the intravenous anaesthetics were observed to have any protective effect against gastric ulcers caused by indomethacin; contrarily, dense ulcer areas were identified in these groups. The increase in the largest ulcer diameter in the group administered thiopental is noteworthy.

The protective effects of different agents on ulcers have been shown in experimental ulcer models in rats. Experimental studies have determined the beneficial effects on induced gastric injury in different rat models for many medications such as sildenafil^[25], coenzyme-Q10^[27], vardenafil^[13], minocycline^[28], and mirtazapine^[1].

Some anaesthetic medications have been used in a variety of ulcer models in previous studies.

Cheney et al.^[15] induced stress ulcers in rats by leaving them hungry for 48 hours and then restraining them within wire mesh for 4 hours, while rats in the other group were left for 4 hours without restraint. They completed 10 different experiments with subjects collected in three series. The researchers identified that though ketamine alone did not create ulcers in the unrestrained subjects, with restraint it significantly increased the ulcer-inducing effect. They em-

phasized that this effect was probably related to the vasoactive properties of the anaesthetics. Ketamine administered to rats before restraint increased the ulcer incidence by 35-98%^[15].

Cho et al.^[16] researched the efficacy of morphine for the prevention and treatment of stress ulcers in rats. In a pre-treatment experiment, 3 groups were first administered 2 and 8 mg/kg morphine in 1 ml of saline i.p. and then exposed to 3 hours cold stress before sacrifice.

The post-treatment experiment first exposed rats to 3 hour of cold stress and then the rats were returned to room temperature and administered 2 and 8 mg/kg morphine in 1 ml of saline i.p. This treatment was repeated 3 hours later, and rats were sacrificed after 24 hours.

To observe the effect of opioid receptor blockage on ulcer amelioration, 15 min before administering morphine, 8 mg/kg naloxone i.p. was administered, and rats were sacrificed after 24 hours. The macroscopic lesion length was measured.

In both the pre- and post-treatment experimental groups, a dose-linked reduction in ulcer severity was reported. The ameliorative effect of morphine on ulcers was partially negated by naloxone, which showed that the effect of morphine is mediated by opioid receptors. Cho et al.^[16] reported that morphine had a certain level of anti-inflammatory effect (by reducing myeloperoxidase activity) and increased cell proliferation and mucus secretion in gastric tissue, ensuring lesion repair.

Debreceni et al.^[17] researched whether there were gastro-protective effects of morphine and naloxone on gastric ulcers that were induced by indomethacin, ethanol and HCl. A 10 mg/kg dose of naloxone did not reduce ulcers, but gastric acid secretion was clearly reduced, while a 20 mg/kg dose had a clear protective effect against ulcers linked to indomethacin and HCl, though there was no effect reported against ethanol-linked ulcers (not acid dependent). Morphine, even at 10 mg/kg i.p., had no protective effect, and at 2 mg/kg, HCL-induced ulceration increased; however, there was no effect on ulcers linked to indomethacin or ethanol. The effect of morphine on stress-linked ulcers is very complex and is reported to vary based on dose, time and administration route^[17].

Gyires et al.^[18] induced ulcers in rats with ethanol and indomethacin and studied the effect of clonidine on ulcer development and whether there was an interaction between alpha-2 receptors and the opioid system. Clonidine was shown to inhibit gastric injury in both ulcer models. Gyires et al.^[18] identified that naloxone, naltrindole and yohim-

bine antagonized the gastroprotective effect of clonidine. This situation shows that the gastroprotective effect of clonidine occurs via the opioid and alpha-2 receptors^[18].

Beyzagul et al.^[19] used an indomethacin-induced ulcer model in rats to research the gastroprotective effect of a new intravenous anaesthetic agent: dexmedetomidine. Additionally, they researched whether there was a role for oxidant and antioxidant parameters in the antiulcer mechanism. Rats were randomly divided into 7 groups: the sham, famotidine 20 mg/kg (p.o.), indomethacin 25 mg/kg and dexmedetomidine 10, 25, 50 and 100 µg/kg groups. The sham group was administered distilled water via gavage. Five minutes after the study medications were administered, all groups were administered 20 mg/kg indomethacin via gavage, sacrificed 6 hours later and had a rapid gastrectomy performed. Ulcerous regions were macroscopically assessed and measured with millimetric paper. The anti-ulcerative effect of dexmedetomidine was compared with that of the famotidine and sham groups.

Additionally, the glutathione peroxidase, catalase, SOD, myeloperoxidase enzyme activity, MDA and glutathione levels in the stomach tissue were assessed. Groups with dexmedetomidine doses of 25, 50 and 100 µg/kg had similar antiulcer effects to those in the famotidine group. The GPO, SOD and MPO activity levels and the GSH level were clearly increased in the famotidine group and all of the dexmedetomidine groups compared to those in the indomethacin group, with CAT and MDA activity clearly reduced.

The study by Beyzagul et al.^[19] identified that the dose-linked dexmedetomidine effects did not have a direct antioxidant effect on gastric ulcers in rats but prevented them by increasing antioxidant enzyme activities. Dexmedetomidine was reported to have a dose-linked anti-ulcerative effect on rat gastric tissue.

In previous studies Suleyman et al.^[29] reported a gastro-protective effect of alpha-2 receptors. In other studies, presynaptic alpha-2 adrenergic receptors were shown to play an inhibitory role on indomethacin, aspirin and stress-related ulcers. The presynaptic alpha-2 receptors regulate gastric acid secretion.

El-Ficky et al.^[20] studied the protective effects of 0.5, 1 and 2.5 mg/kg midazolam and the effects on gastric acid secretion in a stress-induced ulcer model by immobilization of rats. At all 3 doses, they identified that midazolam reduced gastric acid secretion. Again, histopathologically, as the midazolam dose increased, they reported that the ulcer severity reduced. The study by El-Ficky et al.^[20] reported

that the central effect of midazolam prevented the stress ulcers.

Midazolam reduced the excitatory stimuli transmission frequency to the vagal nucleus found in the medulla oblongata in the central pathway and thus reduced the risk of local vascular paralysis and gastric mucosal ulceration. However, in the NSAID-linked ulcer model used in our study, the 10 mg/kg dose of midazolam did not have any gastric protective effect.

Erol et al.^[30] researched the antioxidant effects of midazolam in a renal ischaemia reperfusion model in rats and determined that the use of midazolam did not reduce the FOR activity in the renal ischaemia reperfusion model. The results of our study are in parallel to these study results, and we believe that the lack of antioxidant properties of midazolam is the cause of the lack of effect on indomethacin-induced ulcers^[30].

Propofol and thiopental are two medications with positive effects on oxidative stress and antioxidant mechanisms. Studies have shown that both propofol and thiopental reduce lipid peroxidation^[31].

The structure of propofol is different from that of other hypnotic sedatives and is similar to that of the non-enzymatic antioxidant of vitamin E with a phenolic hydroxyl group (-OH) inhibiting lipid peroxidation and ensuring cleaning of ROS. Additionally, midazolam, propofol and thiopental used in our study were not determined to have any protective efficacy.

This outcome may be linked to the fact that even though propofol and thiopental have antioxidant efficacy, the aetiology of gastric ulcers is multifactorial.

Of course, we do not fully know the location of the anaesthetic effects in ulcer pathogenesis (peripheral/central). However, the majority of patients have a greater tendency for ulcers observed during the postoperative period, which provides the potential for stress ulcers.

Study Limitations

In our study, MDA and NO concentrations were measured biochemically as gastric tissue oxidant/antioxidant parameters, but biochemical results were very inconsistent and incorrect. Our study was evaluated by gastric tissue ulcer index and histopathological study.

In our study we identified that the i.v. anaesthetics midazolam, propofol and thiopental, which are commonly used in anaesthesia practice, have no antiulcer efficacy in an NSAID-induced rat ulcer model.

The protective effect of midazolam on a stress ulcer model has been reported^[27]; however, there are no data on the protective effect of propofol or thiopental on stress ulcers. As a result, proven ulcer prophylaxis should definitely be administered to all these patients. There is a need for advanced studies with different animal models on this topic.

Ethical Committee Approval: The study was completed after receiving approval from the Dokuz Eylul University Animal Experiments Local Ethics Committee (Project No: 18/2014, President Prof. Dr. Osman Yılmaz, date: 15.04.2014) at Dokuz Eylul University Multidisciplinary Experimental Animals Laboratory.

Peer-review: Externally peer-reviewed.

Authorship Contributions: Concept: N.B., M.Ü., E.T., V.H.; Design: N.B., M.A., S.Ö., S.Y.; Data Collection or Processing: N.B., Ş.Ö., M.Ö., E.T.; Analysis or Interpretation: M.Ü., M.A., S.Ö., S.Y.; Literature Search: N.B., Ş.Ö., M.Ö., V.H.; Writing: N.B., E.T., M.Ü.

Conflict of Interest: None declared.

Financial Disclosure: The authors declared that this study received no financial support.

References

1. Bilici M, Öztürk C, Dursun H, Albayrak F, Sağlam MB, Uyanik A, et al. Protective effect of mirtazapine on indomethacin-induced ulcer in rats and its relationship with oxidant and antioxidant parameters. *Dig Dis Sci* 2009;54:1868–75.
2. Alimi H, Faiedh N, Bouoni Z, Hfaiedh M, Sakly M, Zourgui L. Antioxidant and antiulcerogenic activities of *Opuntia ficus indica* f. *inermis* root extract in rats. *Phytomedicine* 2010;17:1120–6.
3. Tuluçe Y, Ozkol H, Koyuncu I, Ine H. Gastroprotective effect of small centaury (*Centaureum erythraea* L) on aspirin-induced gastric damage in rats. *Toxicol Ind Health* 2011;27:760–8.
4. Wallace JL. Nonsteroidal anti-inflammatory drugs and gastroenteropathy: The second hundred years. *Gastroenterology* 1997;112:1000–16.
5. Takeuchi K, Mizoguchi H, Araki H, Komoike Y, Suzuki K. Lack of gastric toxicity of nitric oxide-releasing indomethacin, NCX-530, in experimental animals. *Dig Dis Sci* 2001;46:1805–18.
6. Asako H, Kubes P, Wallace JL, Wolf R, Granger DN. Modulation of leukocyte adhesion in rat mesenteric venules by aspirin and salicylate. *Gastroenterology* 1992;103:146–52.
7. Naito Y, Yoshikawa T, Matsuyama K, Nishimura S, Yagi N, Kondo M. Effects of free radical scavengers on indomethacin-induced aggravation of gastric ulcer in rats. *Dig Dis Sci* 1995;40:2019–21.
8. Konturek SJ, Brzozowski T, Majka J, Pytko-Polonczyk J, Stachura J. Inhibition of nitric oxide synthase delays healing of chronic gastric ulcers. *Eur J Pharmacol* 1993;239:215–7.
9. Stollman N, Metz DC. Pathophysiology and prophylaxis of stress ulcer in intensive care unit patients. *J Crit Care* 2005;20:35–45.
10. Rowe K, Fletcher S. Sedation in the intensive care unit. *An-*

- aesth Crit Care Pain 2008;8:50–5.
11. Peck TE, Hill SA, Williams M. *Pharmacology for Anaesthesia and Intensive Care*. 2nd ed. Greenwich: Medical Media Ltd.; 2003.
 12. Morley JE, Levine AS, Silvis SE. Endogenous opiates and stress ulceration. *Life Sci* 1982;89:86–91.
 13. Karakaya K, Hanci V, Bektas S, Can M, Ucan HB, Emre AU, et al. Mitigation of indomethacin-induced gastric mucosal lesions by a potent specific Type V phosphodiesterase inhibitor. *World J Gastroenterol* 2009;15:5091–6.
 14. Kato S, Otaka M, Odashima M, Sato T, Jin M, Matsuhashi T, et al. Mitigation of stress-induced gastric mucosal lesions by a specific Type IV phosphodiesterase inhibitor. *Dig Dis Sci* 2007;52:711–6.
 15. Cheney DH, Slogoff S, Allen GW. Ketamine-induced stress ulcers in the rat. *Anesthesiology* 1974;40:531–5.
 16. Cho CH, Wua KK, Wub S, Wongb TM, Soa WH, Liua ES, et al. Morphine as a drug for stress ulcer prevention and healing in the stomach. *Eur J Pharmacol* 2003;460:177–82.
 17. Debreceni A, Debreceni B, Mozsik G. A study of the actions of naloxone and morphine on gastric acid secretion and gastric mucosal damage in the rat. *J Physiol Paris* 1997;91:189–97.
 18. Gyires K, Müllner K, Fürst S, Ronai AZ. Alpha-2 adrenergic and opioid receptor-mediated gastroprotection. *J Physiol Paris* 2000;94:117–21.
 19. Polat B, Albayrak Y, Süleyman B, Dursun H, Odabaşoglu F, Yigiter M, et al. Antiulcerative effect of dexmedetomidine on indomethacin-induced gastric ulcer in rats. *Pharmacol Rep* 2011;63:518–26.
 20. El-Ficky MS, El-Azeiz MA, El-Gaby SS. Effect of midazolam on gastric secretion and stress-induced gastric ulceration in male albino rats. *Res Opin Anesth Intensive Care* 2016;3:191–8.
 21. Li Z, Liu X, Zhang Y, Shi J, Zhang Y, Xie P, et al. Connection changes in somatosensory cortex induced by different doses of propofol. *PLoS One* 2014;9:1–8.
 22. Ergün Y, Darendeli S, Imrek S, Kiling M, Oksüz H. The comparison of the effects of anesthetic doses of ketamine, propofol, and etomidate on ischemia-reperfusion injury in skeletal muscle. *Fundam Clin Pharmacol* 2010;24:215–22.
 23. Hasan ZA, Abdul Razzaq RL, Alzoubi KH. Comparison between the effect of propofol and midazolam on picrotoxin-induced convulsions in rat. *Physiol Behav* 2014;128:114–8.
 24. Guidobono F, Pagani F, Ticozzi C, Sibilila V, Pecile A, Netti C. Protection by amylin of gastric erosions induced by indomethacin or ethanol in rats. *Br J Pharmacol* 1997;120:581–6.
 25. Moustafa YM, Khoder DM, El-Awady EE, Zaitone SA. Sildenafil citrate protects against gastric mucosal damage induced by indomethacin in rat. *Eur Rev Med Pharmacol Sci* 2013;17:179–88.
 26. OLYMPUS Stream-Holger Hartmann. Available from: <https://www.holgerhartmann.no/.../olympus%20stream%20>.
 27. Karakaya K, Barut F, Hanci V, Can M, Comert M, Ucan HB, et al. Gastroprotective effects of CoQ10 on ethanol-induced acute gastric lesions. *Bratisl Lek Listy* 2015;116:51–6.
 28. Asmari A, Omani S, Otaibi M, Abdulaaly A, Elfaki I, Yahya K, et al. Gastroprotective effect of minocycline in experimentally induced gastric ulcers in rat. *Int J Clin Exp Med* 2014;7:586–96.
 29. Suleyman H, Halici Z, Cadirci E, Hacimuftuoglu A, Keles S, Gocer F. Indirect role of alpha2-adrenoreceptors in anti-ulcer effect mechanism of nimesulide in rats. *Naunyn Schmiedebergs Arch Pharmacol* 2007;375:189–98.
 30. Erol U, Gurdal M, Erol A, Aslan R, Konukoğlu D, Onmus H. Is midazolam effective as an antioxidant in preventing reperfusion injury in rat kidney? *Int Urol Nephrol* 2002;34:121–7.
 31. Serdaroglu H, Yalçın S, Erdamar H, Alanoglu Z, Yılmaz A, Hasdogan M, et al. Effects of fetal thiopental and propofol on oxidative stress parameters in Cesarean section. *J Anesth* 2010;18:213–9.