

Refractive Results and Endothelial Safety of a Foldable Iris-claw Phakic Intraocular Lens

İhsan Çakır, Alper Ağca, Dilek Yaşa, Yusuf Yıldırım, Burçin Kepez Yıldız, Mustafa Gürkan Erdoğan, Ahmet Demirok

Department of Ophthalmology, University of Health Sciences, Beyoglu Eye Training and Research Hospital, Istanbul, Turkey

Abstract

Introduction: To report long term results after foldable iris-claw phakic intraocular lens (pIOL) implantation for the treatment of high myopia.

Methods: The medical records of patients who underwent Artiflex (Ophtec BV, Netherlands) or Veriflex (Abbott Medical Optics Inc., USA) pIOL were retrospectively analyzed. Patients with five years of follow-up were included in this study. Uncorrected distance visual acuity (UDVA), corrected distance visual acuity (CDVA), and central endothelial cell density (ECD) were analyzed preoperatively and in five years after surgery. The complications observed during and after surgery were also recorded.

Results: This study included 23 eyes of the 23 patients. Mean preoperative SE was $-10.71D \pm 2.84D$ and improved to $-1.60D \pm 0.80D$ at the postoperative 5-year visit. Mean preoperative and postoperative UDVA were 1.47 ± 0.22 logMAR and 0.26 ± 0.16 logMAR, respectively ($p < 0.05$). Mean preoperative and postoperative CDVA were 0.26 ± 0.15 logMAR and 0.17 ± 0.12 logMAR, respectively ($p < 0.05$). Mean ECD decreased from 2526 ± 268 cells/mm² to 2357 ± 295 cells/mm² in five years postoperatively. ($p < 0.05$) In two eyes, a temporary, steroid-induced increase in intraocular pressure (IOP) was detected.

Discussion and Conclusion: Artiflex/Veriflex pIOL implantation was found safe and effective in five years after surgery. However, a 5-year follow-up is not sufficient to evaluate its long term endothelial safety profile.

Keywords: Endothelial cell density; high myopia; phakic intraocular lens.

Phakic intraocular lens (IOL) implantation is an option for the surgical treatment of high myopia^[1]. Phakic IOL implantation offers some advantages in highly myopic individuals when compared to laser in situ keratomileusis and refractive lens exchange, which may result in a better quality of vision and offer significant vision-related quality-of-life advantages over corneal refractive surgery and has the advantage of correcting greater myopia^[2]. Refractive lens exchange, in contrast to phakic, IOL implantation results in loss of accommodation.

There are two types of pIOLs as follows: Anterior chamber

and posterior chamber. Anterior chamber pIOLs can be further divided into two groups: Iris-claw and angle supported. Artiflex (Ophtec BV, Netherlands) or Veriflex (Abbott Medical Optics Inc., USA) phakic IOLs are similar foldable iris-claw phakic intraocular lenses. They yield predictable refractive results and they are considered to have good safety^[3]. However, there are only a limited number of studies describing long-term clinical outcomes following implantation of these lenses and the results are conflicting^[4]. As a result, there is still a need for data on long-term follow-up of these lenses to establish especially their safety profile.

Correspondence (İletişim): İhsan Çakır, M.D. Sağlık Bilimleri Üniversitesi, Beyoglu Göz Eğitim ve Araştırma Hastanesi, Istanbul, Turkey

Phone (Telefon): +90 531 738 76 65 **E-mail (E-posta):** dr.ihsan6534@hotmail.com

Submitted Date (Başvuru Tarihi): 25.07.2018 **Accepted Date (Kabul Tarihi):** 25.09.2018

Copyright 2020 Haydarpaşa Numune Medical Journal

OPEN ACCESS This is an open access article under the CC BY-NC license (<http://creativecommons.org/licenses/by-nc/4.0/>).



The present study aims to report long term efficacy and endothelial safety after foldable iris-claw pIOL (Artiflex or Veriflex) implantation for the treatment of high myopia.

Materials and Methods

This study followed the tenets of the Declaration of Helsinki, and approval was obtained from the Institutional Review Board. Medical records of patients who underwent Artiflex or Veriflex pIOL implantation were evaluated retrospectively. Only patients with 5-year follow-up were included in this study. Spherical equivalent (SE) of manifest refractive error, UDVA, CDVA, and ECD were evaluated preoperatively and five years after surgery. Perioperative and postoperative complications were also recorded.

Preoperative and Postoperative Examinations

All patients underwent a standard detailed anterior and posterior segment examination with a slit lamp. Intraocular pressure was measured with Goldmann applanation tonometer at every visit. An autorefractometer (RM-8800 Autorefractor, Topcon, Tokyo, Japan) was used for keratometry measurements. An LED LCD monitor chart (CC-100 XP, Topcon, Tokyo, Japan) was used for uncorrected distance visual acuity (UDVA) and corrected distance visual acuity (CDVA) measurements. Endothelial cell density was measured with a specular microscope (CEM 530, NIDEK, Japan).

Surgical Procedure

The power calculation was performed using the modified vergence formula in the software provided by the manufacturer. Two paracenteses were performed, and 0.01% acetylcholine (Miochol-EO, Novartis) was injected into the anterior chamber. A 2.75-mm main incision centered at 12 o'clock was performed with a slit knife. The anterior chamber was filled with a cohesive viscoelastic material (Provisc, Alcon). The IOL was introduced from the main incision and rotated until it was horizontal, and the iris was enclaved in the claws of the pIOL using a special needle introduced from the paracentesis. An iridotomy was performed and the viscoelastic material was removed. The incisions were hydrated with BSS.

Statistical Methods

Statistical analysis was performed using SPSS for Windows (version 21.0; IBM, Armonk, NY). The mean, standard deviation, and frequency were used in the statistical analysis. The assumption of normality was assessed using the Shapiro–Wilk test. A paired t-test was used to analyze data with a normal distribution, and a non-parametric Wilcoxon

signed-rank test was used to analyze the data with a non-normal distribution.

Results

This study included 23 eyes of 23 patients. There were nine (39%) male subjects and 14 (61%) female subjects. The preoperative characteristics are shown in Table 1. Preoperatively, mean SE was $-10.71\text{D}\pm 2.84\text{D}$ and mean CDVA was 0.26 ± 0.15 logMAR. Five years postoperatively, mean SE was $-1.60\text{D}\pm 0.80\text{D}$, and mean UDVA improved to 0.26 ± 0.1 logMAR (Table 2). Five years postoperatively, the efficacy index, and safety index were 1.07 ± 0.51 and 1.28 ± 0.46 , respectively. Preoperative and postoperative cumulative visual acuities are shown in Figure 1. The mean ECD loss was 6.6% in five years postoperatively (Fig. 2). No patient lost two or more lines (Fig. 3), and no vision-threatening complications occurred during follow up. However, in two patients, elevated intraocular pressures (IOP) were detected at the one month postoperatively. These increases were considered to be steroid-induced as there was no pigment dispersion or pupillary block. In both of these patients, the IOP returned to its baseline levels after cessation of steroid use.

Table 1. Preoperative characteristics

Parameter	Preoperative Mean \pm SD (Range)
SE (D)	-10.71 ± 2.84 (-4.75 to -15.50)
UDVA (logMAR)	1.47 ± 0.22 (-1.30 to 1.80)
CDVA (logMAR)	0.26 ± 0.15 (0 to 0.52)
ECD (cells/mm ²)	2526 ± 268 (2243 to 3155)
ACD (mm)	3.27 ± 0.21 (3.02 to 3.78)
AL (mm)	27.93 ± 1.59 (23.70 to 30.08)

SD; standard deviation; D= diopters; SE: Spherical equivalent; CDVA: corrected distance visual acuity; WTW: white-to-white; ECD: endothelial cell density; Sim K: simulated keratometry; IOP: intraocular pressure; AL: axial length.

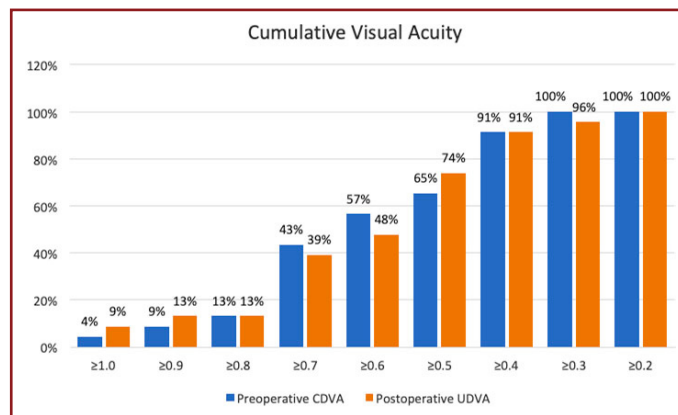


Figure 1. Preoperative and postoperative cumulative visual acuities.

Table 2. Preoperative and postoperative refractive results and endothelial cell density

Parameter	Preoperative Mean±SD (Range)	Postoperative 5 th year Mean±SD (Range)	p*
SE (D)	-10.71±2.84	-1.60±0.80	<0.001
UDVA (logMAR)	1.47±0.22	0.26±0.16	<0.001
CDVA (logMAR)	0.26±0.15	0.17±0.12	0.007
ECD (cells/mm ²)	2526±268	2357±295	<0.001

SD; standard deviation; D= diopters; SE: Spherical equivalent; UDVA: Uncorrected distance visual acuit; CDVA: corrected distance visual acuity; ECD: endothelial cell density; *: Paired samples T-Test, two tailed p value.

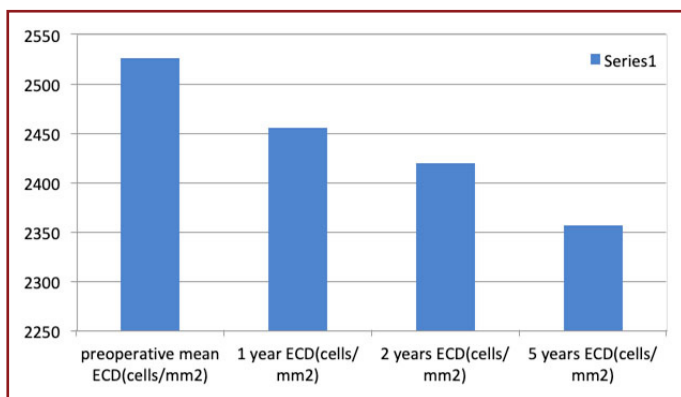


Figure 2. The mean ECD at different visits.

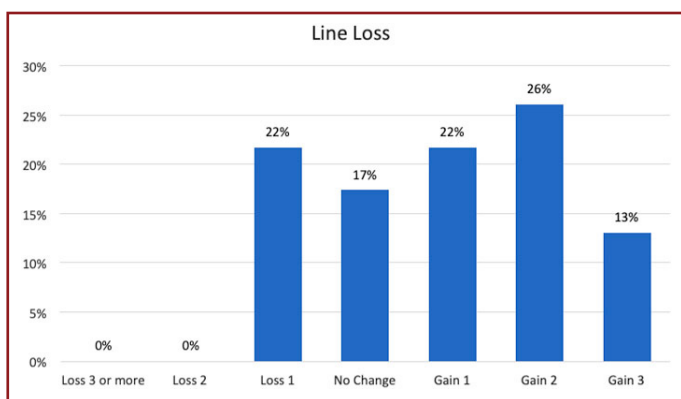


Figure 3. Postoperative changes in Snellen lines of CDVA.

Discussion

In this study, we evaluated long term results after foldable iris-claw phakic intraocular lens (pIOL) implantation for the treatment of high myopia. We found that only four of 23 (17%) eyes were within ±0.50 D of emmetropia in five years. Although refractive predictability after phakic iris-claw has been reported to be high^[1, 2, 6-8], there is a regression of the refractive effect over time, probably due to the progres-

sive nature of pathological myopia. In a study of 399 phakic iris-claw IOLs, Güell et al.^[5] reported that 10% and 38% of the eyes were within ±0.50 D of emmetropia in five years in the 5-mm and 6-mm optic groups, respectively.

Despite the low number of patients within the intended target at five-years, we found the efficacy index was >1 at a five-year follow up. In other words, although most of the patients had residual refractive errors, the mean UDVA was better than the mean CDVA. We found that sixty-percent of the eyes gained one or more lines of CDVA, and this increase in CDVA is probably the reason for the high efficacy index. Because most of the patients gained at least one line of CDVA safety index was also >1, which means that mean postoperative CDVA was above mean preoperative CDVA. Other studies in the literature also report an increase in CDVA after surgical correction of high myopia^[6, 7]. One of the mechanisms of the postoperative increase in CDVA may be the relative magnification of the image and the reduction in visual aberrations after an anterior chamber pIOL implantation when compared to spectacle lenses used in the preoperative determination of CDVA^[8]. However, the exact mechanism of increased CDVA is not clear. This increase in the CDVA probably masks the effects of residual refractive error. As a result, although most of the patients have a residual refractive error, they have an increase in CDVA and a UDVA similar or slightly lower than the preoperative CDVA, which results in high efficacy and safety.

Endothelial cell loss is always a source of concern after implantation of a phakic IOL. There are conflicting results in the literature. Tahzib et al.^[9] evaluated 10-year results of a phakic iris-claw IOL and concluded that there was no progressive ECD loss and there was ECD gain at 10-years. Jonker et al.^[10] reported that there was a progressive cell loss over ten years follow up and ECD was <1500 cells/mm² in 3.9%, 10 years after implantation. Some authors concluded that ECD loss occurs primarily during the surgical procedure, and the decrease stabilizes after a certain time^[7, 11, 12]. It is also possible that endothelial remodeling further complicates the issue and the change in ECD may reflect at least partially a remodeling rather than a loss or gain of ECD^[13]. A European prospective multicenter study evaluated the surgical results of Artiflex. The mean endothelial cell changes was -0.05%, 1.79%, and -1.07% in six months, one year, and two years^[3]. In this study, we found that endothelial cell loss at five years was 6.6%. The ECD loss in our study is higher than the loss reported by Dick et al.^[3]. Doors et al.^[14] found that a shallow ACD and a smaller distance between the pIOL edge and the endothelium were risk factors for ECD loss. Surgical trauma, as well as different pIOL

edge and the endothelium distances, maybe the reason for the higher endothelial loss in our study. However, because of the retrospective nature of our study, we were unable to measure the pIOL edge and the endothelium distance.

The major weaknesses of this study are its retrospective nature, lack of a control group and the absence of pIOL edge and the endothelium distance measurements. These weaknesses make it difficult to draw a conclusion on the endothelial safety profile of the procedure. However, none of the eyes in this study developed endothelial decompensation glaucoma or vision-threatening complications during follow-up. Furthermore, the number of patients included in our study might be higher.

In conclusion, we found that foldable iris-claw phakic IOL implantation is effective concerning visual acuity despite residual refractive errors (≥ 0.50 D) in most of the patients. Also, most of the patients experienced an increase in CDVA. However, ECD loss, which is higher when compared to ECD loss of normal non-operated eyes, requires further studies with longer follow-up to demonstrate endothelial safety profile.

Ethics Committee Approval: The Ethics Committee of SBÜ Beyoğlu Eye Training and Research Hospital Medical Specialization Training Board provided the ethics committee approval for this study (18/04/2018-14).

Peer-review: Externally peer-reviewed.

Authorship Contributions: Concept: A.D.; Design: A.D.; Data Collection or Processing: B.K.Y.; Analysis or Interpretation: A.A.; Literature Search: Y.Y.; Writing: İ.Ç.

Conflict of Interest: None declared.

Financial Disclosure: The authors declared that this study received no financial support.

References

- Bohac M, Anticic M, Draca N, Kozomara B, Dekaris I, Gabric N, et al. Comparison of Verisyse and Veriflex Phakic Intraocular Lenses for Treatment of Moderate to High Myopia 36 Months after Surgery. *Semin Ophthalmol* 2017;32:725–733. [\[CrossRef\]](#)
- Stulting RD, John ME, Maloney RK, Assil KK, Arrowsmith PN, Thompson VM; U.S. Verisyse Study Group. Three-year results of Artisan/Verisyse phakic intraocular lens implantation. Results of the United States Food And Drug Administration clinical trial. *Ophthalmology* 2008;115:464–472.e1. [\[CrossRef\]](#)
- Dick HB, Budo C, Malecaze F, Güell JL, Marinho AA, Nuijts RM, et al. Foldable Artiflex phakic intraocular lens for the correction of myopia: two-year follow-up results of a prospective European multicenter study. *Ophthalmology* 2009;116:671–7.
- Özertürk Y, Kubaloglu A, Sari ES, Koytak A, Capkin M, Akçay L, et al. Foldable iris-fixated phakic intraocular lens implantation for the correction of myopia: two years of follow-up. *Indian J Ophthalmol* 2012;60:23–8. [\[CrossRef\]](#)
- Güell JL, Morral M, Gris O, Gaytan J, Sisquella M, Manero F. Five-year follow-up of 399 phakic Artisan-Verisyse implantation for myopia, hyperopia, and/or astigmatism. *Ophthalmology* 2008;115:1002–12. [\[CrossRef\]](#)
- Kwon SW, Moon HS, Shyn KH. Visual improvement in high myopic amblyopic adult eyes following phakic anterior chamber intraocular lens implantation. *Korean J Ophthalmol* 2006;20:87–92. [\[CrossRef\]](#)
- Yaşa D, Ağca A, Alkin Z, Çankaya Kİ, Karaküçük Y, Coşar MG, et al. Two-Year Follow-Up of Artisan Iris-Supported Phakic Anterior Chamber Intraocular Lens for Correction of High Myopia. *Semin Ophthalmol* 2016;31:280–4.
- Barequet IS, Wagnanski-Jaffe T, Hirsh A. Laser in situ keratomileusis improves visual acuity in some adult eyes with amblyopia. *J Refract Surg* 2004;20:25–8. [\[CrossRef\]](#)
- Tahzib NG, Nuijts RM, Wu WY, Budo CJ. Long-term study of Artisan phakic intraocular lens implantation for the correction of moderate to high myopia: ten-year follow-up results. *Ophthalmology*. 2007 Jun;114:1133–42. [\[CrossRef\]](#)
- Jonker SMR, Berendschot TTJM, Ronden AE, Saelens IEY, Bauer NJC, Nuijts RMMA. Long-Term Endothelial Cell Loss in Patients with Artisan Myopia and Artisan Toric Phakic Intraocular Lenses: 5- and 10-Year Results. *Ophthalmology* 2018;125:486–94. [\[CrossRef\]](#)
- Budo C, Hessloehl JC, Izak M, Luyten GP, Menezo JL, Sener BA, et al. Multicenter study of the Artisan phakic intraocular lens. *J Cataract Refract Surg* 2000;26:1163–71. [\[CrossRef\]](#)
- Chen Y, Liu Q, Xue C, Huang Z, Chen Y. Three-year follow-up of secondary anterior iris fixation of an aphakic intraocular lens to correct aphakia. *J Cataract Refract Surg* 2012;38:1595–601.
- Benedetti S, Casamenti V, Benedetti M. Long-term endothelial changes in phakic eyes after Artisan intraocular lens implantation to correct myopia: five-year study. *J Cataract Refract Surg* 2007;33:784–90. [\[CrossRef\]](#)
- Doors M, Cals DW, Berendschot TT, de Brabander J, Hendrikse F, Webers CA, et al. Influence of anterior chamber morphometrics on endothelial cell changes after phakic intraocular lens implantation. *J Cataract Refract Surg* 2008;34:2110–8.