

# Bloody Nipple Discharge in Children: Single-Center Experience

 Sefa Sağ<sup>1</sup>,  Hatice Küçük<sup>2</sup>

<sup>1</sup>Department of Pediatric Surgery, University of Health Sciences, Kanuni Training and Research Hospital, Trabzon, Türkiye

<sup>2</sup>Department of Pathology, University of Health Sciences, Kanuni Training and Research Hospital, Trabzon, Türkiye

## Abstract

**Introduction:** Bloody nipple discharge (BND) in children is an exceptionally rare entity. The aim of the study was to evaluate the underlying etiologies, treatment strategies, and clinical outcomes in children with BND.

**Methods:** The retrospective study included pediatric patients (aged below 18 years) who presented with BND in our clinic between May 2015 and May 2020. Demographic and clinical characteristics including age, gender, laboratory, ultrasound (US), and histopathological findings, treatment modalities, and follow-up records were evaluated for each patient.

**Results:** Patients comprised six (75%) girls and two (25%) boys. Median age at diagnosis was 15 years (minimum-maximum: 3–192 months) and all the girls were adolescents. BND was located in the left breast in five and in the right in three patients, and bilateral BND was not detected in any patient. All patients had normal serum hormone levels and a negative discharge culture. In US examination, mammary ductal ectasia (MDE) was diagnosed in two patients, one patient had hypoechoic tissue in the subareolar region, whereas the others had normal US findings. Cytology showed ductal epithelial cells without malignancy, which confirmed MDE in all patients. BND resolved with antibiotic treatment in one patient and resolved with no treatment in other patients.

**Discussion and Conclusion:** BND can occur in adolescent girls as well. MDE is a leading cause of BND. Given that MDE is usually a self-limiting condition, unnecessary invasive interventions should be avoided. Cytological and US examinations seem to be highly useful in the diagnosis and follow-up of patients with BND.

**Keywords:** Adolescent; breast diseases; child; hemorrhage; nipple.

**B**loody nipple discharge (BND) is a rare condition that bothers both parents and older children due to its association with breast cancer in adulthood<sup>[1,2]</sup>.

A few studies report on BND in childhood, and most of these studies have a limited number of cases. In addition, there is no clear algorithm regarding diagnostic tools,

treatment strategies, and follow-up durations in children with BND<sup>[1-3]</sup>.

Hereby, we aimed to present patients with BND that were diagnosed in our clinic and to evaluate their underlying etiologies, treatment strategies, and outcomes in the light of literature.

**Correspondence:** Sefa Sağ, M.D. Department of Pediatric Surgery, University of Health Sciences, Kanuni Training and Research Hospital, Trabzon, Türkiye

**Phone:** +90 462 229 51 50 **E-mail:** drsefa51@gmail.com

**Submitted Date:** 30.06.2022 **Revised Date:** 30.06.2022 **Accepted Date:** 01.08.2022

Copyright 2023 Haydarpaşa Numune Medical Journal

**OPEN ACCESS** This is an open access article under the CC BY-NC license (<http://creativecommons.org/licenses/by-nc/4.0/>).



## Materials and Methods

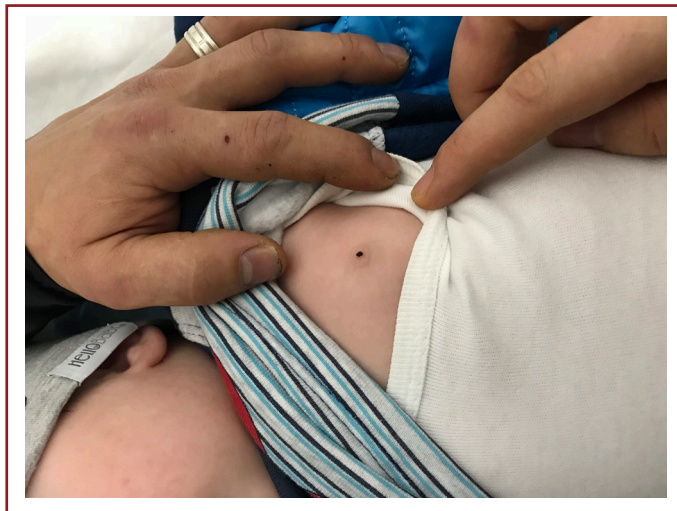The retrospective study included pediatric patients (aged below 18 years) who presented with BND in our clinic between May 2015 and May 2020. Demographic and clinical characteristics including age, gender, laboratory, ultrasound (US), and histopathological findings, treatment modalities, and follow-up records were evaluated for each patient. All the patients were examined and followed up by a pediatric surgeon, and histopathological examination was performed by a pathologist. Patients who had undergone previous breast biopsy or surgery were excluded from the study. An ethical approval was obtained from the local ethics committee (Ethics Committee no: 2022/11434).

## Statistical Analysis

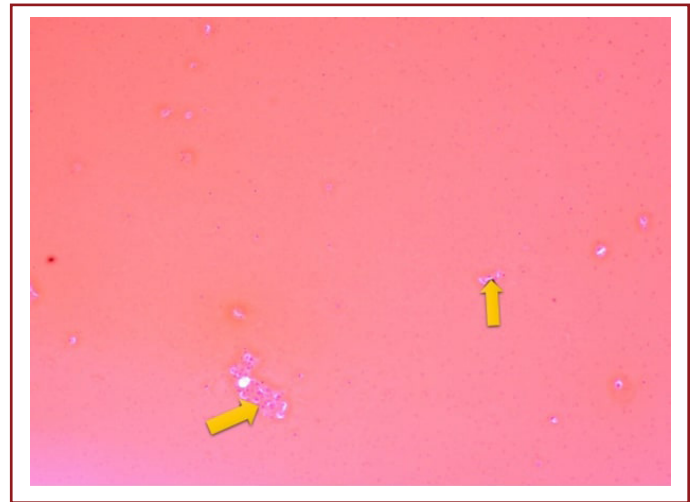
All the analyses were performed using SPSS for Windows version 22.0 (Armonk, NY: IBM Corp.). Continuous variables were expressed as median (range) and categorical variables were expressed as percentages (%).

## Results

The eight patients comprised six (75%) girls and two (25%) boys. Median age at diagnosis was 15 years (minimum-maximum: 3–192 months). Their parents and older children suffered from daily bloody discharge that discolored the undershirt. BND was located in the left breast in five and in the left in three patients, and no bilateral BND was present in any patient (Fig. 1). On physical examination, applying pressure on the breasts resulted in the extraction of blood drops from the ipsilateral nipple in all cases. Two breasts had palpable cystic masses located in the areolar area, with no associated skin findings. One patient had only mild ten-



**Figure 1.** Bloody nipple discharge in a patient.



**Figure 2.** Photomicrography (PAP,  $\times 20$  magnification) showing epithelioid histiocytes without malignancy in a patient (Black arrows: Epithelioid histiocytes).

derness, whereas the other patients had normal findings. On initial admission, none of the patients had palpable axillary lymph nodes. Laboratory investigations showed normal serum estradiol, estrone, progesterone, follicle-stimulating hormone, luteinizing hormone, thyroid-stimulating hormone, prolactin, and testosterone levels in all patients. Bacterial culture of discharge was negative. In US examination, the bile duct caliber was  $>3$  mm and mammary ductal ectasia (MDE) was diagnosed in two patients, both of whom had cystic lesions. One patient had hypoechoic tissue in the subareolar region, whereas the others had normal US findings. Cytology showed ductal epithelial cells without malignancy in all patients, which confirmed MDE (Fig. 2). One patient with breast tenderness was treated with empirical oral antibiotics (ampicillin/sulbactam). Although no pathogenic microorganisms were detected in the discharge culture of this patient, antibiotics were administered due to the presence of hypoechoic tissue in the subareolar re-

**Table 1.** Characteristics of the patients and duration of complete resolution

No	Age (months)	Gender	Side	Duration of complete resolution
1	3	Male	Left	3 months
2	6	Male	Right	2 months
3	192	Female	Left	4 months
4	180	Female	Left	3 weeks
5	60	Female	Right	6 months
6	192	Female	Left	3 months
7	180	Female	Right	8 months
8	180	Female	Left	4 months

gion in US and high C-reactive protein level. BND resolved within 3 weeks after the administration of oral antibiotics. No other patients underwent medical treatment, biopsy, or surgery. Parents and older children were advised not to apply pressure on the breast. In all patients, complete resolution of nipple discharge occurred within a period ranging between 3 weeks and 8 months (Table 1). Patients were followed up for a minimum period of 1 year. No recurrence was noted in any patient during the follow-up. Patients with cystic lesions and ductal ectasia on US were followed up with US at 6-month intervals despite complete resolution of the discharge. No additional surgical intervention or biopsy was performed in any of these patients and also no malignant transformation or abnormal US findings were detected during the follow-up.

## Discussion

To our knowledge, the eight patients presented in the current study constitute the second largest single-center series of children with BND. A previous large series was reported by Imamoglu et al.<sup>[2]</sup> in 2006 and most of their patients underwent surgery. In our patients, however, BND resolved without surgery.

There are very few studies on childhood BND in the literature. In the largest series, it was noted that the patients were aged between 3 months and 12 years and their mean age was 3.8 years<sup>[2]</sup>. In a systematic review, Acer et al.<sup>[1]</sup> reported that all the patients were aged under 4 years. On the contrary, all the patients in our study were adolescents except for two patients. In addition, most previous studies claimed that BND was more prevalent in male gender, which contradicts with the reported female preponderance in the adult population<sup>[3]</sup>. In our study, all the patients aged under 6 months were boys and all of our adolescent patients were girls. Although our findings were consistent with those of studies suggesting male preponderance in preadolescent patients, our findings indicated a higher proportion of girls with BND in adolescents.

The pathologies underlying BND vary remarkably<sup>[1]</sup>. Possible etiologies in children include MDE, hemorrhagic cyst, gynecomastia, intraductal papilloma, infarcted fibroadenoma, and benign phyllodes tumor<sup>[4]</sup>. In the literature, BND related to malignant pathology has not been reported in any pediatric study, and MDE has been suggested as the most common underlying cause of BND<sup>[1,3]</sup>. MDE is a condition characterized by duct dilatation and inflammatory reaction surrounded by periductal fibrous tissue. This dilatation causes disparity with respect to other channels and its

lumen is filled with lipids and debris. Subsequently, phagocytic giant cells surrounding the lipid material together with histiocytes form a granulation tissue with the ulceration of the ductal epithelium, which will later be responsible for BND<sup>[3]</sup>. To date, many factors have been implicated for the development of MDE, including maternal hormonal stimulation, congenital abnormalities, infection, trauma, and autoimmune reaction<sup>[1,3,5]</sup>. In our series, we detected no malignant pathologies that could be considered underlying causes of BND. In previous studies, MDE was diagnosed by US or histopathology<sup>[1-3,5]</sup>. In our study, cytological examination detected ductal epithelial cells without malignancy, which confirmed MDE in all patients. Moreover, two out of eight patients were male and these patients were aged under 6 months. The previous study indicated that in young children, temporarily elevated progesterone levels might be responsible for the discharge<sup>[6]</sup>. On the other hand, reduced estradiol concentrations have also been reported as an endocrine abnormality accompanying BND<sup>[6,7]</sup>. Contrariwise, all patients had normal hormone levels and we could not detect any factors such as congenital anomaly or trauma to explain the etiology of MDE.

Common clinical presentation in children includes the presence of unilateral or bilateral BND with or without breast hypertrophy or a palpable mass<sup>[3]</sup>. Acer et al.<sup>[1]</sup> noted that most of their patients had bilateral BND and the authors suggested that the predominance of bilateral disease indicates a systemic cause of BND. In contrast, all our patients had unilateral BND, which suggests that BND was probably caused by ductal ectasia in the breast rather than a systemic cause, although the triggering factor could not be discovered.

US is the primary imaging tool for the evaluation of breast abnormalities in children<sup>[3,4,8]</sup>. Contrarily, mammography and other imaging techniques are seldom used due to the radiation exposure of the patient, required a contrast agent and the dense parenchymal tissue in children<sup>[4,8,9]</sup>. Previous studies suggested that US can be used for diagnosing MDE in patients with BND<sup>[1,3]</sup>. Nevertheless, it has been reported that sonographic examination may provide nonspecific findings, and although the presence of dilated ducts is a common finding, it is not a fixed feature<sup>[3]</sup>. In our study, US detected MDE in two patients. However, we consider that since US does not show any findings in favor of malignancy on first admission and during the follow-up, it can help clinicians assess whether the underlying disease is malignant. Therefore, we consider that US is a useful imaging tool in BND. In addition, we consider that the rate of MDE diagnosis in US could have been higher if the US ex-

aminations had been performed by an experienced pediatric radiologist in our study.

Recent studies suggest that unnecessarily invasive approaches should be avoided in patients with BND,<sup>[1,3]</sup> whereas some other studies recommend surgery in selected cases<sup>[10-12]</sup>. In our study, BND resolved with antibiotic treatment in one patient, while it resolved with no treatment in other patients. MDE is a self-limiting disorder considered the main cause of BND in children<sup>[1,3]</sup>. Our findings support this view, therefore we recommend avoidance of unnecessary invasive approaches.

Previous studies reported that BND resolved spontaneously between 3 weeks and 11 months<sup>[1-3]</sup>. Some adult studies also noted that the majority of the patients had a benign cause, the risk of malignancy was approximately 5% in adults, and these studies recommended US and clinical examinations every 6-month during the follow-up<sup>[13,14]</sup>. We could not draw any conclusions from the literature about whether and how long the patients should be followed after complete resolution of BND. Nonetheless, our patients were followed up for at least 1 year by performing US and clinical examinations every 6 months.

Our study was limited since it was a retrospective study and the data were obtained from the medical records of a single center. Another limitation was that US examinations were not performed by the same radiologist.

## Conclusion

BND can occur in adolescent girls as well. MDE is a leading cause of BND. Given that MDE is usually a self-limiting condition, unnecessary invasive interventions should be avoided. Cytological and US examinations seem to be highly useful in the diagnosis and follow-up of patients with BND.

**Ethics Committee Approval:** All procedures performed in studies involving human participants were in accordance with the ethical standards of the institutional and/or national research committee (protocol No: 2022/11434 by Ethics Committee of University of Health Sciences, Kanuni Education and Research Hospital) and with the 1964 Helsinki declaration and its later amendments or comparable ethical standards.

**Peer-review:** Externally peer-reviewed.

**Funding:** This research did not receive any specific grant from funding agencies in the public, commercial, or not-for-profit sectors. There are no relevant financial or non-financial competing interests to report.

**Authorship Contributions:** Concept: S.S., H.K.; Desing: S.S., H.K.; Supervision: S.S.; Materials: S.S., H.K.; Data Collection: S.S., H.K.; Analysis or Interpretation: S.S.; Literature search: S.S.; Writing: S.S.; Critical Review: S.S., H.K.

**Conflict of Interest:** None declared.

**Financial Disclosure:** The authors declared that this study received no financial support.

## References

1. Acer T, Derbent M, Hiçsönmez A. Bloody nipple discharge as a benign, self-limiting disorder in young children: A systematic review including two related case reports. *J Pediatr Surg* 2015;50:1975–82.
2. Imamoglu M, Cay A, Reis A, Ozdemir O, Sapan L, Sarihan H. Bloody nipple discharge in children: Possible etiologies and selection of appropriate therapy. *Pediatr Surg Int* 2006;22:158–63.
3. Nascimento M, Portela A, Espada F, Fonseca M. Bloody nipple discharge in infancy--report of two cases. *BMJ Case Rep* 2012;2012:bcr2012006649.
4. Lee JY. Bloody nipple discharge caused by an intraductal papilloma of the breast in an adolescent girl: A case report. *Radiol Case Rep* 2021;16:3346–9.
5. Kaplan R, Hoda SA, Hoda RS. Cytological evaluation of bloody nipple discharge fluid. *Diagn Cytopathol* 2013;41:183–5.
6. Sigalas J, Roilides E, Tsanakas J, Karpouzas J. Bloody nipple discharge in infants. *J Pediatr* 1985;107:484.
7. Gama de Sousa S, Costa E, Carvalho L, Gonçalves de Oliveira J. Bloody nipple discharge in a breastfeeding boy. *J Paediatr Child Health* 2010;46:786–8.
8. Gao Y, Saksena MA, Brachtel EF, terMeulen DC, Rafferty EA. How to approach breast lesions in children and adolescents. *Eur J Radiol* 2015;84:1350–64.
9. İkizceli T, Gulsen G. The diagnostic accuracy of abbreviated breast magnetic resonance imaging (Abbreviated Breast MRI). *Dicle Med J* 2021;48:468–77.
10. Weimann E. Clinical management of nipple discharge in neonates and children. *J Paediatr Child Health* 2003;39:155–6.
11. Aydin R, Gul SB, Polat AV. Detection of duct ectasia of mammary gland by ultrasonography in a neonate with bloody nipple discharge. *Pediatr Neonatol* 2014;55:228–30.
12. Marshall PS, Duarte GM, Torresan RZ, Cabello C. Bloody nipple discharge in childhood. *Breast J* 2011;17:692–3.
13. de Paula IB, Campos AM. Breast imaging in patients with nipple discharge. *Radiol Bras* 2017;50:383–8.
14. Chen L, Zhou WB, Zhao Y, Liu XA, Ding Q, Zha XM, et al. Bloody nipple discharge is a predictor of breast cancer risk: A meta-analysis. *Breast Cancer Res Treat* 2012;132:9–14.