



# Surgical Treatment of Penile Fracture Accompanied by Complete Urethral Rupture

Cevper Ersöz<sup>1</sup>, Abdullah Ilktac<sup>1</sup>, Yunus Çolakoğlu,<sup>2</sup> Abdulmuttalip Şimsek,<sup>2</sup> Senad Kalkan<sup>1</sup>

<sup>1</sup>Department of Urology, Faculty of Medicine, Bezmialem Vakıf University, Istanbul, Turkey

<sup>2</sup>Department of Urology, Başakşehir Çam and Sakura City Hospital, Istanbul, Turkey

## Abstract

**Introduction:** Penile fracture accompanied by complete urethral rupture is a rare condition. This study aims to evaluate the long-term lower urinary tract symptoms and sexual functions of patients with penile fracture and concomitant complete urethral rupture who underwent urgent surgical reconstruction.

**Methods:** Preoperative, perioperative, and long-term results of five patients who were operated on for complete urethral rupture and concomitant penile fracture were evaluated. Patients were diagnosed by physical examination and retrograde urethrography (RUG). Operation data were recorded and physical examination, International Prostate Symptom Score, International Index of Erectile Function-5 forms, and uroflowmetry results were evaluated to determine long-term results.

**Results:** The mean age of the patients was  $35.6 \pm 6.3$  (25–42) years and the mean follow-up period was  $18.4 \pm 9.9$  months. Penile fracture occurred in three patients during sexual intercourse, one patient during masturbation, and one patient during sleep. Erectile dysfunction was not observed in any patient after the surgery. One of the patients developed anterior urethral stricture and one patient had a 15° ventral curvature during erection.

**Discussion and Conclusion:** Urethrorrhagia and urinary retention are the major signs indicating urethral rupture. In these patients, the urethra should be evaluated with RUG preoperatively. The long-term results of early surgical repair of the corpus cavernosum and urethra in this group of patients are very good.

**Keywords:** Penile fracture; rupture; urethra.

Penile fracture is a rare condition caused by a blunt trauma to the erect penis and it is characterized by sudden detumescence following a cracking sound, swelling, and ecchymosis<sup>[1]</sup>. Blunt trauma causes a rupture in tunica albuginea, in 1–38% of these cases a concomitant urethral injury also occurs and anterior (penile and bulbous) urethra is injured most frequently<sup>[2]</sup>. Urgent surgical exploration and repair of the urethra and tunica albuginea are very important in preventing long-term complications.

The most common cause of penile fracture is penile trauma during sexual intercourse<sup>[3]</sup>. Other causes are sudden bending of the erect penis to obtain detumescence (taghaandan maneuver) which is frequently observed in the Middle East, rolling over in bed in an erect state, and blunt trauma during masturbation<sup>[4,5]</sup>. An erect penis is much more prone to trauma-related injury than a flaccid penis. The pathophysiology of penile fracture is explained by two factors. First, the thickness of the tunica albuginea

**Correspondence (İletişim):** Cevper Ersöz, M.D. Bezmialem Vakıf Üniversitesi Tıp Fakültesi Uroloji Anabilim Dalı, İstanbul, Turkey

**Phone (Telefon):** +90 532 582 32 91 **E-mail (E-posta):** cersoz@bezmialem.edu.tr

**Submitted Date (Başvuru Tarihi):** 15.10.2021 **Accepted Date (Kabul Tarihi):** 17.12.2021

Copyright 2022 Haydarpaşa Numune Medical Journal

**OPEN ACCESS** This is an open access article under the CC BY-NC license (<http://creativecommons.org/licenses/by-nc/4.0/>).

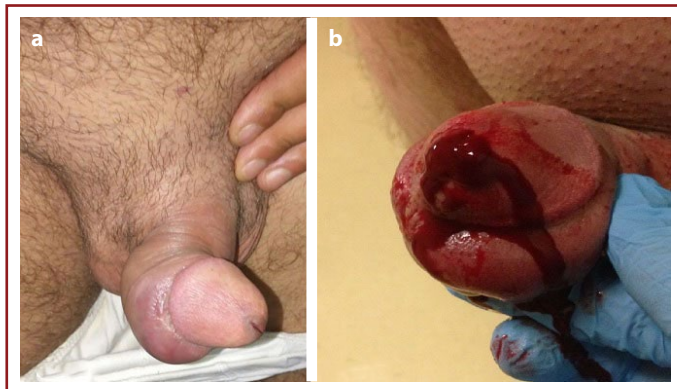


is approximately 2 mm in the flaccid state but this thickness decreases to 0.25–0.5 mm in the erect penis<sup>[6]</sup>. The other factor is the increase in the intracavernosal pressure during erection, reaching up to 1500 mmHg<sup>[7]</sup>. These two factors may facilitate traumatic urethral injury and penile fracture. Urethral injury should be considered, especially in patients with urinary retention, blood in the urethral meatus, and hematuria. Penile fracture is a diagnosis based on the clinical history and physical examination, but methods such as retrograde urethrography (RUG), ultrasonography, and flexible cystoscopy have been suggested to detect the tear in tunica and accompanying urethral injury<sup>[8–10]</sup>. In cases with penile fracture and concomitant urethral injury, early repair is important for the preservation of sexual potency and normal lower urinary tract function<sup>[11]</sup>. This study aims to evaluate the etiology, treatment, and long-term results of the patients who were operated on for penile fracture and concomitant urethral injury.

## Materials and Methods

The present study was conducted according to the principles of the 2008 Helsinki Declaration. Following the approval of the institutional Ethics Committee (2021/184), patients who were operated on for penile fracture between the years 2015 and 2020 were retrospectively analyzed and a total of 5 patients with concomitant complete urethral rupture were included in the study.

Patient age, cause of penile fracture, physical examination findings, symptoms, perioperative data, and postoperative complications were noted. Four of the patients had complaints of hearing a cracking sound, swelling, and urethrorrhagia (Fig. 1a, b). Only 2 patients had urinary retention. Diagnosis of penile fracture and urethral rupture was performed by history, physical examination, and RUG. Urgent surgical intervention was performed in all patients within 24 h.



**Figure 1.** (a, b) Penil swelling, and urethrorrhagia.

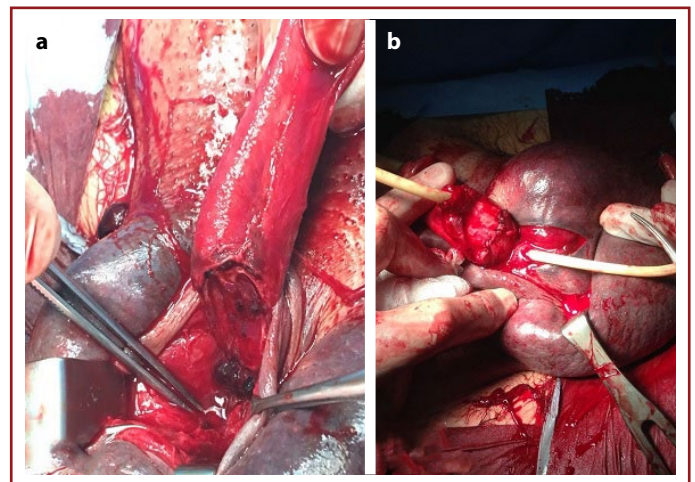
## Surgical Technique

Following perioperative antibiotic prophylaxis, the penis was degloved after a subcoronal circumferential incision. Bilateral rupture of corpus cavernosum on the ventral side and concomitant complete urethral rupture at the mid-penile location were observed in all patients (Fig. 2a, b). Following urethral mobilization, the edges of the urethra were spatulated and a tension-free, end-to-end anastomosis was performed with interrupted sutures over an 18 F silicone foley catheter. The urethral anastomosis was performed with 4/0 absorbable (polyglactin) sutures, and corpus cavernosum repair was performed with 3/0 absorbable (polydioxanone) interrupted sutures.

In the postoperative follow-up, erectile function was evaluated by the International Index of Erectile Function questionnaire with five questions (IIEF-5) and lower urinary tract evaluation was performed by uroflowmetry, International Prostate Symptom Score questionnaire, and post-micturition residual volume measurement. We did not routinely perform RUG to assess urethral recovery after catheter removal, it was reserved only for patients with voiding symptoms.

## Results

Five patients with penile fracture and concomitant complete urethral rupture were included in this study. The mean age of the patients was  $35.6 \pm 6.3$  (25–42) years. The most common cause of penile fracture was sexual intercourse and it was present in 3 (60%) patients. One patient (20%) had a history of masturbation and one patient (20%) had a history of rolling over in bed during sleep. Bilateral rupture of corpus cavernosum on the ventral side at the



**Figure 2.** (a, b) Bilateral rupture of corpus cavernosum and concomitant complete urethral rupture.

mid-penile location was detected in all patients. Four (80%) patients heard a cracking sound with penile fracture and subsequently, ecchymosis and swelling developed. This was compatible with the egg-plant deformity mentioned in the literature. Although all patients had a complete rupture of the urethra, urinary retention at the first admission was present in only 2 (40%) patients (Table 1). Hematoma was detected as an important finding in 3 (60%) patients with ecchymosis. Urethrorrhagia was observed as a clinical finding in four of five patients. RUG was performed in all patients and contrast extravasation and impaired urethral patency were detected at the site of injury. Urethral rupture was located in the mid-penile urethra and tear in the tunica albuginea was at the same level in all cases.

The mean operative time and the mean hospital stay were  $125\pm 26$  min and  $1.6\pm 0.8$  days, respectively. The Foley catheter was removed 3 weeks after the surgery in 4 patients, and 2 weeks after the surgery in one patient. No medical treatment was given to the patients to prevent spontaneous erections and sexual intercourse was forbidden for 8 weeks. The mean follow-up period was  $18.4\pm 9.9$  months (Table 2). The mean IIEF-5 and IPSS scores at the 3rd month postoperative follow-up were  $23\pm 1.8$  and  $9.6\pm 10.5$ , respectively (Table 3). Nine months after the surgery the IPSS score of one patient was found as 28, RUG was performed and a stricture in the mid-penile urethra was detected. He was treated with an internal urethrotomy. One patient had a  $15^\circ$  ventral curvature and no additional intervention was required.

**Table 1.** Clinical findings

History of sexual intercourse	3 (60%)
History of masturbation	1 (20%)
Rolling over during sleep	1 (20%)
Cracking sound	4 (80%)
Swelling	4 (80%)
Pain	3 (60%)
Urinary retention	2 (40%)
Hematoma	3 (60%)
Ecchymosis	3 (60%)
Urethrorrhagia	4 (80%)

**Table 2.** Perioperative findings

Fracture localization (mid-penil)	5 (100%)
Operation time (mean, min)	$125\pm 26$
Hospitalization (mean, day)	$1.6\pm 0.8$
Foley catheter duration (mean, day)	$20.2\pm 3$
Follow up (mean, month)	$18.4\pm 9.9$

**Table 3.** Post-operative results

IIEF-5	$23\pm 1.8$
IPSS	$9.6\pm 10.5$
Qmax (ml/sc)	$21.8\pm 12$
PMR (ml)	$45\pm 70$
Fibrosis (patient)	None
Penile curvature (patient)	1
Urethral stricture (patient)	1

PMR: Post-micturition residual.

## Discussion

Few studies in the literature evaluated the long-term results of penile fracture cases accompanied by urethral injury. Mostly, case reports with short-term results were reported. Long-term urinary and sexual functions of five patients who were operated on for a complete urethral rupture with concomitant penile fracture were evaluated in this study.

Studies showed that partial or complete urethral injury co-existing with penile fracture has an incidence of 1–38%<sup>[2]</sup>. This incidence is much lower in eastern European countries, Asia, and Africa where the most common cause of fracture is penile manipulation, and higher in western countries where the main cause is sexual intercourse<sup>[12]</sup>. Urethral injury is the result of the trauma that occurs during vigorous sexual intercourse and its severity is directly proportional to the severity of the fracture<sup>[13]</sup>. There is strong evidence in the literature showing that bilateral corporal rupture is highly associated with urethral injury<sup>[12,14]</sup>. Similar to the data in the literature, in our study, all patients had bilateral corporal ruptures. Blood in the urethral meatus and urinary retention in addition to the penile fracture symptoms such as pain, swelling, and cracking sound indicates the presence of urethral injury. In a retrospective study of 12 cases conducted by Kasaraneni et al.,<sup>[15]</sup> rates of urethrorrhagia and acute urinary retention were reported as 91.66% and 25%, respectively. Raheem et al.<sup>[13]</sup> reported that all patients with penile fracture and concomitant complete urethral rupture had urethrorrhagia, 25% of the patients had urinary retention and 33% of the patients had voiding difficulties. In this study, the incidence of urethrorrhagia was 80%, and 2 (40%) patients had acute urinary retention. Depending on the severity of the injury, urethral rupture can be asymptomatic and incidentally diagnosed during surgery or ultrasonography<sup>[9]</sup>. Furthermore, in cases with large hematoma and edema, urinary retention can be seen without urethral injury because of external compression to the urethra<sup>[16]</sup>.

It has been reported in the literature that the sensitivity of RUG is between 50% and 100% and false-negative results can be observed in 28.5% of patients<sup>[6,13]</sup>. The role of RUG as a diagnostic tool is controversial. Some authors suggest that RUG should be performed in cases with a suspicion of urethral injury on the other hand some authors suggest that it is unnecessary as the urethral injury is located at the same level as the tear in the tunica and it can be recognized easily during surgery<sup>[2,11,17,18]</sup>. In the current European Association of Urology guideline, flexible cystoscopy is recommended to determine the location and degree of urethral injury before repair<sup>[8]</sup>. Ultrasonography is another imaging modality that can be used in detecting the site of the tear and presence of concomitant urethral injury but requires experienced radiologists<sup>[19]</sup>. MRI is very effective in detecting penile fracture but it is less effective in detecting urethral lesions and it has the disadvantages of high cost and availability<sup>[20,21]</sup>. We prefer using RUG if there is a suspicion of urethral injury, we did not use flexible cystoscopy, ultrasonography, or MRI in our series. RUG detected all injuries in our study, there was no false-negative result but it should be kept in mind that patients in this study had complete urethral ruptures.

Degloving was performed after a subcoronal circumferential incision during the surgical intervention in all patients. The advantage of degloving has been emphasized in several studies, as it allows the evaluation of the entire corpus cavernosum and urethra. Interrupted end-to-end or continue anastomosis techniques are encountered in literature for urethroplasty<sup>[22]</sup>. A direct incision was performed just above the level of the tear by some authors to avoid the morbidity of degloving. De Luca et al.<sup>[19]</sup> used preoperative ultrasonography as a diagnostic tool to confirm the location of the tear, made a small incision at the penoscrotal junction as most of the ruptures are located in the proximal third of the shaft, and successfully treated rupture in tunica albuginea and urethral injury if present. However, there is not enough data about the effects of spatulation, suture material, and suturing techniques in the literature. We performed spatulation in all cases, and in one patient urethral stricture was observed 9 months after surgery. Although we cannot make a clear recommendation due to the limitations of our study, it can be said that spatulation gives successful results if sufficient urethral length is provided after urethral mobilization. The catheterization period varied between studies, ranging from 13 to 21 days. Some authors place a suprapubic cystostomy in cases with complete urethral rupture but there is no evidence in the literature supporting its usage<sup>[14]</sup>. We did not place supra-

pubic cystostomy in any patient. Patients were advised to avoid sexual intercourse for 8 weeks and no medical treatment was given to prevent erection.

In a retrospective study of 11 cases with complete urethral rupture, Raheem et al.<sup>[13]</sup> detected worsening in IPSS and uroflowmetry parameters in only one patient in the post-operative period and urethrography revealed urethral stricture in this patient. He has been treated with regular urethral dilatation. In this study, stricture was observed in one patient during the mean follow-up period of 18.4 months and he was treated with internal urethrotomy. No recurrence was detected during follow-up. Other studies and case reports in the literature also report that immediate surgery yields good results in terms of postoperative urinary functions. In a meta-analysis evaluating penile fracture, complication rates of immediate surgery and conservative treatment were compared. Erectile dysfunction rates were 1.94% and 22%, penile curvature rates were 2.7% and 13%, palpable plaque or nodule rates were 13.9% and 19.1% for surgical and conservative treatment methods, respectively, and it was concluded that complication rates were lower in immediate surgical repair<sup>[23]</sup>. Kozacioglu et al.<sup>[24]</sup> evaluated 54 patients with penile fracture who were surgically treated. Patients were divided into 3 groups based on the time interval from penile fracture to the surgery: Group 1: 0–6 h, Group 2: 6.1–12 h, and Group 3: 12.1–24 h. No statistically significant difference was detected between the groups in terms of IIEF scores and complication rates. Sharma et al.<sup>[25]</sup> evaluated 68 patients with penile fracture. All patients were operated and degloving was performed after a subcoronal circumferential incision. Erectile dysfunction was observed in 7 (11.3%) patients during follow-up and they reported that age >50 years and bilateral corporal involvement were significant risk factors for erectile dysfunction. Mild penile curvature not affecting penetration (<20°) was detected in 2 (3.2%) patients and small penile plaques (4–5 mm) were found in 4 (6.5%) patients. In our study, the mean IIEF-5 score of the patients was 23 (21–25) 3 months after the surgery, and no palpable plaque was detected in any of the patients. In only one patient, mild curvature (15°) was detected that did not prevent intercourse.

The relationship between sexual position and penile fracture has been evaluated in several studies. Reis et al.<sup>[26]</sup> stated that the “woman-on-top” position is a major risk factor for penile fracture whereas Amer et al.<sup>[23]</sup> reported that there was no relationship between sexual position and penile fracture. Unfortunately, we do not have the data about the sexual position at the time of the fracture.



This study has some limitations. It is a retrospective study and included a small number of patients. When considering the number of patients, it should be taken into account that the largest study evaluating penile fracture and concomitant complete urethral rupture involves 11 patients.

## Conclusion

It can be said that penile fracture cases accompanied by complete urethral injury are rarely observed and have complications such as urethral stricture, fibrosis, penile curvature, and erectile dysfunction. The incidence of these complications is lower in immediate surgery. Urethrorrhagia is the most important finding of urethral injury. RUG should be carried out in suspicious cases. Degloving should be performed in surgery. We recommend performing an end-to-end urethral anastomosis with spatulation, if possible. Further, large-scale and prospective studies are required about this subject.

**Ethics Committee Approval:** The present study was conducted according to the principles of the 2008 Helsinki Declaration. Following the approval of the institutional Ethics Committee (2021/184), patients who were operated on for penile fracture between the years 2015 and 2020 were retrospectively analyzed and a total of 5 patients with concomitant complete urethral rupture were included in the study.

**Peer-review:** Externally peer-reviewed.

**Authorship Contributions:** Concept: C.E., S.K.; Design: C.E.; Data Collection or Processing: C.E.; Analysis or Interpretation: A.İ., A.Ş.; Literature Search: S.K., Y.Ç.; Writing: C.E., A.İ.

**Conflict of Interest:** None declared.

**Financial Disclosure:** The authors declared that this study received no financial support.

## References

- Godec CJ, Reiser R, Logush AZ. The erect penis - injury prone organ. *J Trauma* 1988;28:124–6. [CrossRef]
- Derouiche A, Belhaj K, Hentati H, Hafsia G, Slama MR, Chebil M. Management of penile fractures complicated by urethral rupture. *Int J Impot Res* 2008;20:111–4. [CrossRef]
- Mydlo JH. Surgeon experience with penile fracture. *J Urol* 2001;166:526–8; discussion 528–9. [CrossRef]
- Zargooshi J. Penile fracture in Kermanshah, Iran: Report of 172 cases. *J Urol* 2000;164:364–6. [CrossRef]
- McAninch JW, Santucci RA. Genitourinary trauma. In: Walsh PC, Retik AB, Vaughan ED, Wein AJ editor. *Campbell's Urology* 8th ed. Philadelphia, PA: WB Saunders; 2002. p.3707–44.
- Mydlo JH, Hayyeri M, Macchia RJ. Urethrography and cavernosography imaging in a small series of penile fractures: A comparison with surgical findings. *Urology* 1998;51:616–9. [CrossRef]
- De Rose AF, Giglio M, Carmignani G. Traumatic rupture of the corpora cavernosa: New physiopathologic acquisitions. *Urology* 2001;57:319–22. [CrossRef]
- Kitrey ND, Djakovic N, Hallscheidt P, Kuehhas FE, Lumen N, Serafetinidis E, et al. Guidelines on urological trauma. European Association of Urology Arnhem 2021. Available at: <https://uroweb.org/guideline/urological-trauma/>. Accessed Dec 23, 2021.
- Falcone M, Garaffa G, Castiglione F, Ralph DJ. Current management of penile fracture: An up-to-date systematic review. *Sex Med Rev* 2018;6:253–60. [CrossRef]
- Gontero P, Muir GH, Frea B. Pathological findings of penile fractures and their surgical management. *Urol Int* 2003;71:77–82. [CrossRef]
- Barros R, Silva M, Antonucci V, Schulze L, Koifman L, Favorito LA. Primary urethral reconstruction results in penile fracture. *Ann R Coll Surg Engl* 2018;100:21–5. [CrossRef]
- Barros R, Schulze L, Ornellas AA, Koifman L, Favorito LA. Relationship between sexual position and severity of penile fracture. *Int J Impot Res* 2017;29:207–9. [CrossRef]
- Raheem AA, El-Tatawy H, Eissa A, Elbahnasy AH, Elbendary M. Urinary and sexual functions after surgical treatment of penile fracture concomitant with complete urethral disruption. *Arch Ital Urol Androl* 2014;86:15–9. [CrossRef]
- El-Assmy A, El-Tholoth HS, Mohsen T, Ibrahim el HI. Long-term outcome of surgical treatment of penile fracture complicated by urethral rupture. *J Sex Med* 2010;7:3784–8. [CrossRef]
- Kasaraneni P, Mylarappa P, Gowda RD, Puvvada S, Kasaraneni D. Penile fracture with urethral injury: Our experience in a tertiary care hospital. *Arch Ital Urol Androl* 2019;90:283–7. [CrossRef]
- Davies DM, Mitchell I. Fracture of the penis. *Br J Urol* 1978;50:426. [CrossRef]
- Ganem JP, Kennelly MJ.; Ruptured Mondor's disease of the penis mimicking penile fracture. *J Urol* 1998;159:1302. [CrossRef]
- Ahmadnia H, Younesi Rostami M, Kamalati A, Imani MM. Penile fracture and its treatment: Is retrograde urethrography necessary for management of penile fracture? *Chin J Traumatol* 2014;17:338–40.
- De Luca F, Garaffa G, Falcone M, Raheem A, Zacharakis E, Shabbir M, et al. Functional outcomes following immediate repair of penile fracture: A tertiary referral centre experience with 76 consecutive patients. *Scand J Urol* 2017;51:170–5. [CrossRef]
- Sokolakis I, Schubert T, Oelschlaeger M, Krebs M, Gschwend JE, Holzapfel K, et al. The role of magnetic resonance imaging in the diagnosis of penile fracture in real-life emergency settings: Comparative analysis with intraoperative findings. *J Urol* 2019;202:552–7. [CrossRef]
- Guler I, Ödev K, Kalkan H, Simsek C, Keskin S, Kiliç M. The value of magnetic resonance imaging in the diagnosis of penile fracture. *Int Braz J Urol* 2015;41:325–8. [CrossRef]
- Kominsky H, Beebe S, Shah N, Jenkins LC. Surgical reconstruction for penile fracture: A systematic review. *Int J Impot Res* 2020;32:75–80. [CrossRef]

23. Amer T, Wilson R, Chlosta P, AlBuheissi S, Qazi H, Fraser M, et al. Penile fracture: A meta-analysis. *Urol Int* 2016;96:315–29.
24. Kozacıoğlu Z, Ceylan Y, Aydoğdu Ö, Bolat D, Günlüsoy B, Minareci S. An update of Penile Fractures: Long-term significance of the number of hours elapsed till surgical repair on long-term significance. *Turk J Urol* 2017;43:25–9. [\[CrossRef\]](#)
25. Sharma G, Mandal S, Bhowmik P, Gupta P, Bahal B, Sharma PK. Sexual function outcomes and risk factors of erectile dysfunction after surgical repair of penile fracture. *Turk J Urol* 2021;47:106–12. [\[CrossRef\]](#)
26. Reis LO, Cartapatti M, Marmioli R, de Oliveira Júnior EJ, Saade RD, Fregonesi A. Mechanisms predisposing penile fracture and long-term outcomes on erectile and voiding functions. *Adv Urol* 2014;2014:768158. [\[CrossRef\]](#)