

CASE REPORT

A Case of Necrotizing Fasciitis After Pneumococcal Septic Arthritis

 Bekir Karagöz,  Levent Adıyeko,  Murat Bakır

Department of Orthopedics and Traumatology, University of Health Sciences, Hamidiye Faculty of Medicine, Haydarpaşa Numune Health Application and Research Center, İstanbul, Türkiye

Abstract

Septic arthritis is the inflammation of the synovial membrane and synovial fluid in the joints with bacterial, viral, or fungal agents. It is most commonly spread by hematogenous way. In cases that are not treated, it can cause permanent and serious disabilities. The most common factor in all age groups was "*Staphylococcus aureus*". We report a case of necrotizing fasciitis after septic arthritis due to *Streptococcus pneumoniae*, resulting in hip disarticulation.

Keywords: Amputation; bacterial infection; necrosis; necrotizing fasciitis; pneumococcal septic arthritis.

Septic arthritis is an inflammation of the synovial membrane and synovial fluid in the joints caused by bacterial, viral, or fungal agents^[1]. It is more common under the age of 15–55^[2]. The presence of risk factors such as diabetes, chronic liver disease, rheumatoid arthritis, cancer, chronic kidney disease, alcoholism, having undergone joint puncture, or joint surgery and suppression of the immune system increases the risk of developing septic arthritis^[3,4]. *Staphylococcus aureus* is the most common agent in adult and different risk groups. Streptococcus and other Gram-positive bacteria are other common agents. Factors can be changed according to risk factors. *Streptococcus pneumoniae*, for example, is the fourth most common cause of childhood septic arthritis, but infections in adult patients are rare^[5].

Necrotizing fasciitis is a rare, progressive, and fatal bacterial infection presenting with necrosis of the skin and subcutaneous tissue^[6]. Amputation can be life-saving in cases of necrotizing fasciitis on the extremities. The most important

factor in diagnosis is the suspicion of necrotizing fasciitis based on clinical findings.

Septic arthritis is a disease that can be healed without sequelae in a timely and appropriate treatment approach. In this study, we present a case of septic arthritis with *S. pneumoniae* causing hip disarticulation due to necrotizing fasciitis despite timely interventions.

Case Report

A 66-year-old male patient, with no history of systemic disease other than known diabetes mellitus, presented to our hospital emergency department with complaints of right knee pain, swelling, redness, and heat increase for 1 week. On physical examination, the right knee was swollen and hyperemic, and the right knee range of motion (ROM) was painful and limited in all directions. Laboratory findings at the time of admission were leukocyte: 8600 (4000–10000), hemoglobin: 12 (13–17), glucose: 367 (<100), and CRP: >34 mg/L (0–0.8 mg/L). Lots of leukocytes were observed in all

Correspondence (İletişim): Bekir Karagöz, M.D. Ortopedi ve Travmatoloji Anabilim Dalı, Sağlık Bilimleri Üniversitesi, Hamidiye Tıp Fakültesi, Haydarpaşa Numune Sağlık Uygulama ve Araştırma Merkezi, İstanbul, Türkiye

Phone (Telefon): +90 545 646 89 14 **E-mail (E-posta):** drbkr71@gmail.com

Submitted Date (Başvuru Tarihi): 05.12.2019 **Revised Date (Revize Tarihi):** 24.02.2020 **Accepted Date (Kabul Tarihi):** 24.11.2020

Copyright 2022 Haydarpaşa Numune Medical Journal

OPEN ACCESS This is an open access article under the CC BY-NC license (<http://creativecommons.org/licenses/by-nc/4.0/>).



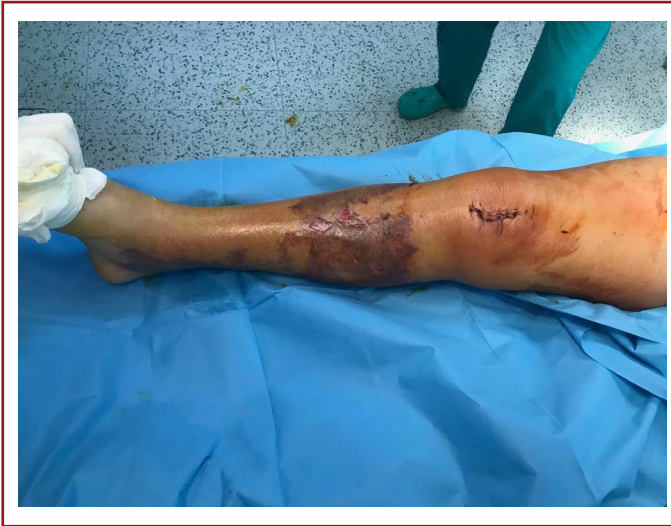

Figure 1. Bullous formations appearing in the midline of the crus on the postoperative 4th day.

areas as a result of microscopic examination of the joint puncture fluid. Gram staining showed Gram-positive diplococci. The patient who was compatible with septic arthritis as a result of puncture material was hospitalized and underwent emergency surgery. Intraoperative debridement and 6000 cc washing with 0.9% sodium chloride were performed. We consulted infectious disease department for starting antibiotherapy. Antibiotic treatment was started on the patient with ceftriaxone 1×2 g, teicoplanin 400 mg 12 h intervals, and three doses after 24 h intervals. In the culture taken during surgery, "*S. pneumoniae*" grew. "Bullous," crepitating lesions extending from the midline to the proximal right crus, occurred on the 4th post-operative day while under antibiotic therapy (Fig. 1). X-rays and computer tomography (CT) angiography revealed diffuse "emphysematous" changes under the skin (Fig. 2a and b). Laboratory tests revealed leukocyte: 23800 (4000–10000),

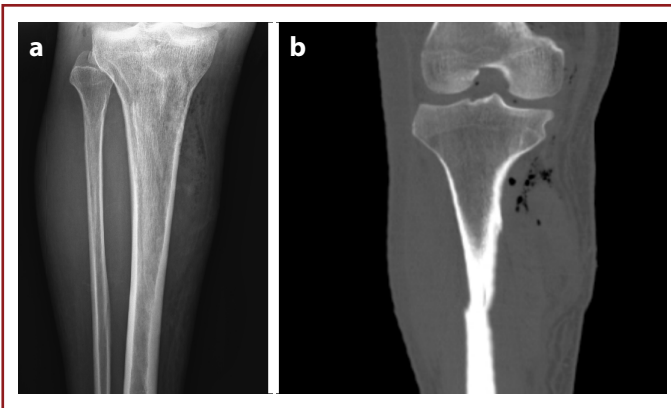


Figure 2. (a) Emphysematous changes detected on X-ray images, (b) emphysematous changes detected on computed tomography.

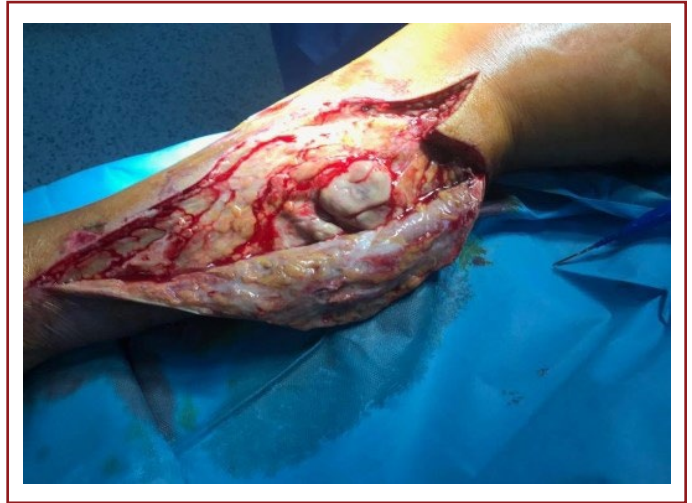

Figure 3. Infective image of the surgical area recorded intraoperatively.

hemoglobin: 10.7 (13–17), glucose: 170 (<100), CRP: 16.9 mg/L (0–0.8), ALT: 98 U/L (0–50 U/L), and AST: 100 U/L (0–50 U/L). As the present "bullous" lesions progressed rapidly in the following hours, the patient underwent emergency surgery with the diagnosis of necrotizing fasciitis (Fig. 3). Aggressive debridement was performed (Fig. 4). There were no aerobic and anaerobic growths in the cultures taken during surgery. When the patient's liver function tests were found to be elevated, the current antibiotherapy was changed to meropenem and teicoplanin. Since the necrotic areas of the right lower extremity continued to progress after the second operation, aggressive debridement was performed twice more at 3-day intervals. After deterioration of metabolic values and general condition of the patient, right hip disarticulation was performed 9 days after bullous lesions. Post-operative laboratory values were

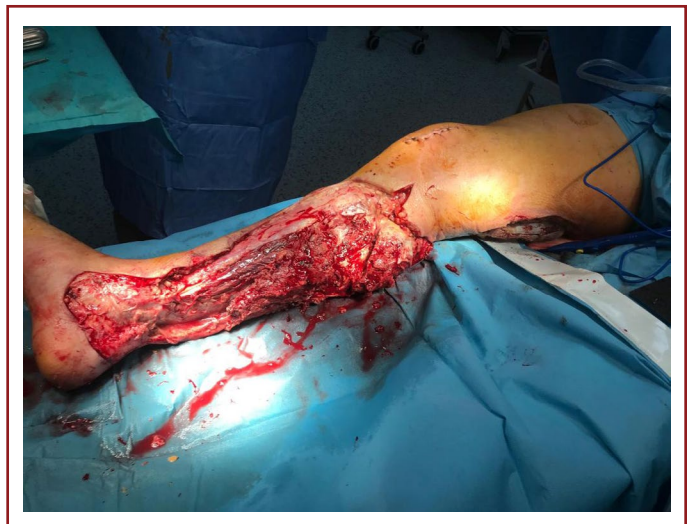

Figure 4. Image of the surgical area after aggressive debridement.

leukocyte: 6220 (4000–10000), hemoglobin: 10.9 (13–17), glucose: 148 (<100), CRP: 9.2 mg/L (0–0.8 mg/L), ALT: 63 U/L (0–50 U/L), and AST: 55 U/L (0–50 U/L). As the patient's general condition improved, metabolic values returned to normal limits and there was no growth in the culture taken at the last surgery, the patient's current antibiotherapy was terminated by infectious diseases on the 23th day of treatment and he was discharged.

Discussion

Joint involvement of "*S. pneumoniae*" is rare. Pneumococcal arthritis outside of childhood develops in middle or advanced age and predominantly in the presence of a predisposing factor such as alcoholism, trauma, diabetes, osteoarthritis, long-term steroid use, or malignancy. The prevalence of pneumococcal septic arthritis in adults is between 3 and 5%^[7]. Pneumococcal arthritis has been shown to involve more knee, shoulder, and elbow joints, respectively^[8]. In our case, diabetes mellitus was the only predisposing factor. There is no known history of infection.

Arthralgia is usually the first symptom in pneumococcal septic arthritis. In the acute period, there is an enlargement of the joint distance on X-ray radiographs^[9]. Demonstration of the causative agent by stained microscopic examinations with intensive polymorphonuclear leukocytes (PMNL) infiltration and culture and bacterial isolation in arthrocentesis fluid is important in the definitive diagnosis^[10]. Complications such as joint damage, osteomyelitis, and periarticular calcification develop in untreated cases^[9]. Despite surgical intervention and appropriate antibiotic treatment in our case, septic arthritis progressed to necrotizing fasciitis and resulted in hip disarticulation.

Primary pneumococcal septic arthritis may be the focus of primary infection in only half of the patients^[9]. Although the clinical presentation is septic arthritis, 23% of patients have negative blood cultures^[9]. In the case presented here, "*S. pneumoniae*" was detected, but the primary infection focus was not detected.

Penicillin is the first choice antibiotic in pneumococcal septic arthritis^[10]. The third generation of cephalosporins, quinolones, and vancomycin as a last option is the other options recommended for treatment due to the increased resistance in recent years. Although there is no need for antibiotic combination in uncomplicated infections, in case of excessive pus accumulation in the joint, discharge of the fluid by arthrocentesis reduces both the enzyme load that has negative effects on the cartilage within the joint and provides more effective antibiotic^[8]. Although drainage

and washing performed in this case are a generally accepted treatment approach, it was not sufficient^[3].

Necrotizing fasciitis is a rare, progressive, and fatal bacterial infection manifested by necrosis of skin and subcutaneous tissue^[6]. Incidence is 0.4 in 100 thousand cases^[11,12]. Rapidly spreading necrosis in tissues can cause systemic sepsis, toxic shock syndrome, and multiorgan failure^[13]. Overall mortality was reported between 15% and 52%^[14,15]. Delayed initial surgical debridement may increase mortality up to 71%^[16]. Sepsis occurred due to rapid tissue destruction in our presented case.

In most cases of necrotizing fasciitis, the causative Group A is the virulent form of streptococci^[6,13]. Bacterial agents are often microorganisms such as Group A streptococci, *Vibrio vulnificus*, *Clostridium*, *Bacteroides fragilis*, and less frequently *Pseudomonas aeruginosa*^[6,13]. Regardless of the causative pathogen, early diagnosis is very difficult since there is no involvement of the skin over the necrosis area during the initial period^[12]. Early diagnosis and extensive surgical debridement are very important in treatment^[17]. Delay in surgical treatment increases mortality^[17]. Early diagnosis and rapid treatment of this rare form of necrotizing fasciitis presented here prevented the patient's life-threatening condition.

As a result, pneumococcal septic arthritis is not common in adult patients. Care should be taken in terms of complications that may occur in elderly and predisposing patients. As in this case, necrotizing fasciitis may develop after septic arthritis, although it is rare and early diagnosis and intervention can prevent fatal complications.

Informed Consent: Approval was obtained from the patients.

Peer-review: Externally peer-reviewed.

Conflict of Interest: None declared.

Authorship Contributions: Concept: B.K.; Design: B.K., L.A.; Data Collection or Processing: M.B.; Analysis or Interpretation: L.A., M.B.; Literature Search: B.K., L.A., M.B.; Writing: B.K.

Financial Disclosure: The authors declared that this study received no financial support.

References

1. Ross JJ. Septic arthritis. *Infect Dis Clin North Am* 2005;19:799–817. [\[CrossRef\]](#)
2. Tarkowski A. Infection and musculoskeletal conditions: Infectious arthritis. *Best Pract Res Clin Rheumatol* 2006;20:1029–44. [\[CrossRef\]](#)
3. Goodman SB, Chou LB, Schurman DJ. Management arthritis. In: Chapman MW, editor. *Chapman's orthopaedic surgery*. 3rd ed. Philadelphia: Lippincott Williams&Wilkins; 2001. p.3561–77.

4. Mathews CJ, Coakley G. Septic arthritis: Current diagnostic and therapeutic algorithm. *Curr Opin Rheumatol* 2008;20:457–62.
5. Moumille K, Merckx J, Glorion C, Pouliquen JC, Berche P, Ferroni A. Bacterial aetiology of acute osteoarticular infections in children. *Acta Paediatr* 2005;94:419–22. [\[CrossRef\]](#)
6. Yagmur O, Erkokcak EU, Sonmez H, Alparslan A, Demircan O, Dalay C. Necrotizing fasciitis. *Dig Surg* 1995;12:106–10. [\[CrossRef\]](#)
7. Goldenberg DL, Reed JI. Bacterial arthritis. *N Engl J Med* 1985;312:764–71. [\[CrossRef\]](#)
8. Baraboutis I, Skoutelis A. Streptococcus pneumoniae septic arthritis in adults. *Clin Microbiol Infect* 2004;10:1037–9. [\[CrossRef\]](#)
9. Ross JJ, Saltzman CL, Carling P, Shapiro DS. Pneumococcal septic arthritis: Review of 190 cases. *Clin Infect Dis* 2003;36:319–27. [\[CrossRef\]](#)
10. Yakupoğulları Y, Karakurt L, Dilek AR. Multiple Myelomalı hastada gelişen bir pnömokok septik artrit. *Fırat Med J* 2007;12:243–4.
11. Trent JT, Kirsner RS. Diagnosing necrotizing fasciitis. *Adv Skin Wound Care* 2002;15:135–8. [\[CrossRef\]](#)
12. File TM Jr, Tan JS, DiPersio JR. Group A streptococcal necrotizing fasciitis. Diagnosing and treating the "flesh-eating bacteria syndrome". *Cleve Clin J Med* 1998;65:241–9. [\[CrossRef\]](#)
13. Fichev G, Kostov V, Marina M, Tzankova M. Fournier's Gangrene: A clinical and bacteriological study. *Anaerobe* 1997;3:195–7.
14. Eke N. Fournier's gangrene: A review of 1726 cases. *Br J Surg* 2000;87:718–28. [\[CrossRef\]](#)
15. Faucher LD, Morris SE, Edelman LS, Saffle JR. Burn center management of necrotizing soft-tissue surgical infections in unburned patients. *Am J Surg* 2001;182:563–9. [\[CrossRef\]](#)
16. Kuncir EJ, Tillou A, St Hill CR, Petrone P, Kimbrell B, Asensio JA. Necrotizing soft-tissue infections. *Emerg Med Clin North Am* 2003;21:1075–87. [\[CrossRef\]](#)
17. Donaldson PM, Naylor B, Lowe JW, Gouldsbrough DR. Rapidly fatal necrotizing fasciitis caused by Streptococcus pyogenes. *J Clin Pathol* 1993;46:617–20. [\[CrossRef\]](#)