

## ORIGINAL ARTICLE

## Surgical Treatment of Cerebral Hydatid Cysts

 Ali Erhan Kayalar<sup>1</sup>,  Ersin Hacıyakupoğlu<sup>2</sup>,  Mustafa Efendioğlu<sup>1</sup>,  Derviş Mansuri Yılmaz<sup>3</sup>

<sup>1</sup>Department of Neurosurgery, University of Health Sciences Turkey, Haydarpaşa Numune Health Application and Research Center, İstanbul, Türkiye

<sup>2</sup>Department of Neurosurgery, Heinrich-Braun-Klinikum Zwickau

<sup>3</sup>Department of Neurosurgery, University of Cukurova, Adana, Türkiye

## Abstract

**Introduction:** Cerebral hydatid cysts are caused by the cranial intraparenchymal settlement and growth of tenia echinococcus embryo. CT reveals well-circumscribed, non-contrast enhanced, intraparenchymal homogenous cystic mass. Cyst fluid is isointense like cerebrospinal fluid (CSF). Operation is the most preferred therapeutic approach in cerebral hydatid cyst. We presented four cases that underwent operation at the past 5 years to attract attention to cerebral hydatid cyst which became evident in our country recently.

**Methods:** We had four cases with cerebral hydatid cyst that underwent operation between 2015 and 2020.

**Results:** We had three male one female patient. Their age was between 9 and 16 and mean age was 13. Three of them had solitary; one patient had multiple hydatid cyst. Common complaint of our cases was headache. The patients had seizure, diplopia, homonim hemianopia, and strabismus due to bilateral 6<sup>th</sup> nerve palsy.

**Discussion and Conclusion:** Cerebral hydatid cyst is most commonly seen in childhood (70%). All of our cases had headache and papillary stasis. In addition, our 2<sup>nd</sup> case had epilepsy, 3<sup>rd</sup> case had right homonim hemianopsia, and 4<sup>th</sup> case had diplopia. Recently, due to the situations in the middle east, lots of immigrants left their countries and live abroad, some of those were already contaminated. We can state that we have to refresh our knowledge about hydatid cysts and be aware that new cases may arise due to immigration patterns.

**Keywords:** Embryo; larva; multiple intracerebral hidatik kist; solitere intracerebral hidatik kist.

Cerebral hydatid cysts are caused by the cranial intraparenchymal settlement and growth of tenia echinococcus embryo. The life cycle of tenia echinococcus larvae starts in intestines of pets. Humans and animals are contaminated with feces. It reaches to human intestines with contaminated food and intermediate phase of growth is completed in human intestines and embryo develops. It penetrates to gastrointestinal mucosa and transmits to lymph and portal system. It settles in lymph node, liver,

and lungs. Especially, in children capillary and pulmonary barrier is more permeable in comparison to adults and results with systemic infusion and location and growth in all organs that are supplied with blood. It inoculates in liver (75%), in lungs (15%) other organs (8%) and brain (2%). Intracranial lesions constitute 0.05% of cases in developed countries, whereas the radioist is 0.09–2.2% in endemic countries. It is usually located in frontalis and parietal lobe and solitary lesion is common<sup>[1,2]</sup>.

**Correspondence (İletişim):** Ali Erhan Kayalar, M.D. Nöroşürüji Anabilim Dalı, Sağlık Bilimleri Üniversitesi, Haydarpaşa Numune Sağlık Uygulama ve Araştırma Merkezi, İstanbul, Türkiye

**Phone (Telefon):** +90 312 336 09 09 **E-mail (E-posta):** draekayalar@gmail.com

**Submitted Date (Başvuru Tarihi):** 05.05.2021 **Revised Date (Revize Tarihi):** 12.08.2021 **Accepted Date (Kabul Tarihi):** 18.08.2021

Copyright 2022 Haydarpaşa Numune Medical Journal

**OPEN ACCESS** This is an open access article under the CC BY-NC license (<http://creativecommons.org/licenses/by-nc/4.0/>).



Cases present with signs of increased intracranial pressure (ICP), seizure, strabismus, and focal neurologic symptoms. Brain antibody response is known to be weak in comparison to other organs; therefore, serologic tests used for other organs involvement such as casoni, weinberg, and hemagglutination tests are mostly negative. Before the past 30 years as a result of uncontrolled agricultural and sheep raising communities, intracerebral hydatid cyst was common in our country, whereas it tremendously decreased following the control and vaccination of domestic animals. However, nowadays, new cases appeared again due to immigration patterns. Computed tomography (CT) and magnetic resonance imaging (MRI) is essential in cerebral hydatid cyst diagnosis<sup>[1,3]</sup>.

CT reveals well-circumscribed, non-contrast enhanced, and intraparenchymal homogenous cystic mass. Cyst fluid is isointense like cerebrospinal fluid (CSF). Intra-axial sharp margin and mixed intensity ring like peripheral enhancement is detected in MRI. Cyst includes membrane detachments. Peripheric edema does not exist<sup>[1,3,4]</sup>.

Operation is the most preferred therapeutic approach in cerebral hydatid cyst. Mebendazole and albendazole are not effective but can be applied postoperatively for a short period in cases with probable other organ involvement, contamination, and dissemination<sup>[5,6]</sup>.

We presented four cases that underwent operation at the past 5 years to attract attention to cerebral hydatid cyst which became evident in our country recently.

## Materials and Methods

We had four cases with cerebral hydatid cyst that underwent operation between 2015 and 2020. We had three male one female patient. Their age was between 9 and 16 and mean age was 13. Three of them had solitary; one patient had multiple hydatid cyst. Common complaint of our cases was headache. The patients had seizure, diplopia, homonim hemianopia, and strabismus due to bilateral 6<sup>th</sup> nerve palsy. Demographics of the patients are shown in Table 1.

Computer tomography of lungs and liver, abdomen ultrasonography, and echocardiography were found to be normal. Serological tests and indirect hemoglobin tests were negative.

## Radiological Images of Patients

MRI and CT cannot distinguish primary from secondary cysts. In general, multiple cysts point to the diagnosis of secondary cysts and should prompt a search for a primary source elsewhere. Both modalities characteristically show hydatid cyst as a spherical homogenous, well-defined, and non-enhancing cystic lesion without peripheral edema. The fluid density is generally similar to that of CSF on both MRI and CT. MRI provides comprehensive information for accurate diagnosis. A fine rim of peripheral enhancement with minimal perilesional edema may be seen in the presence of active inflammation. MRI may show a low-density cyst membrane and relations with surrounding structures are more delineated than on the CT scan. Case sample are demonstrated as figure (Figs. 1-4).

## Surgical Procedure

All of our cases underwent wide craniotomy with incision compatible with the localization of the lesion and dura was opened.

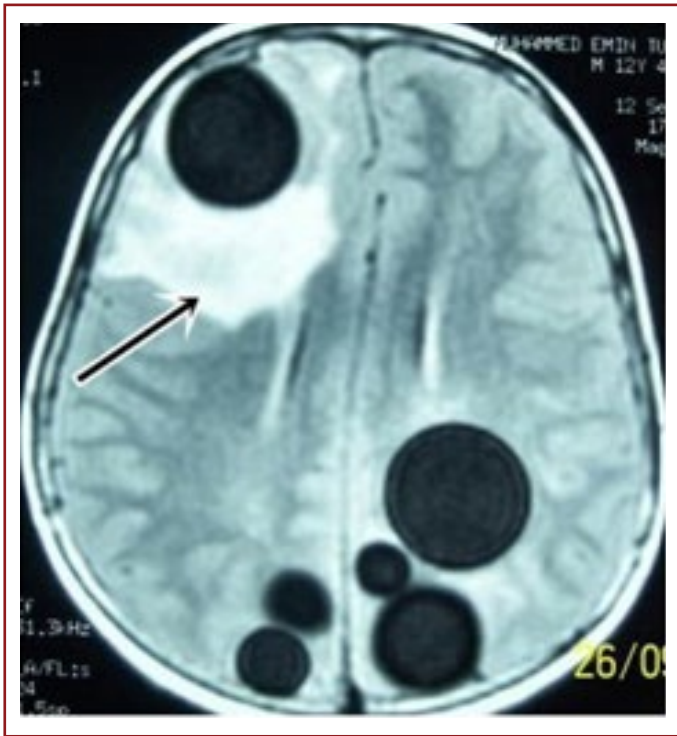
We reached to the thin glial layer surrounding the cyst 2–3 mm below the cortical surface through cortical incision of 3 cm. This layer is carefully opened and cyst capsule is visualized, we did not detect adherence with glial layer and was easily detached. We placed rubber catheter between the cyst and the glial layer and injected warm saline solution (Dowling’s water hydrodissection technique)<sup>[7]</sup>. We applied the same technique and did not detect postoperative complication in our cases. Turning the head upside down results with easy deliver of the cyst to the cup with saline solution through the incision (Fig. 5).

## Discussion

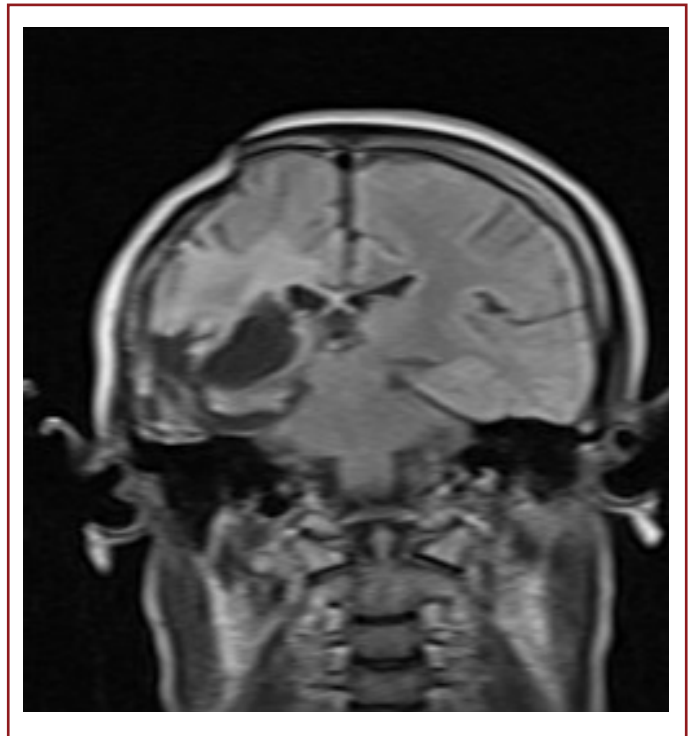
Cerebral hydatid cyst is most commonly seen in childhood (%70). It is frequently located at the supratentorial

**Table 1.** Demographics of the patients

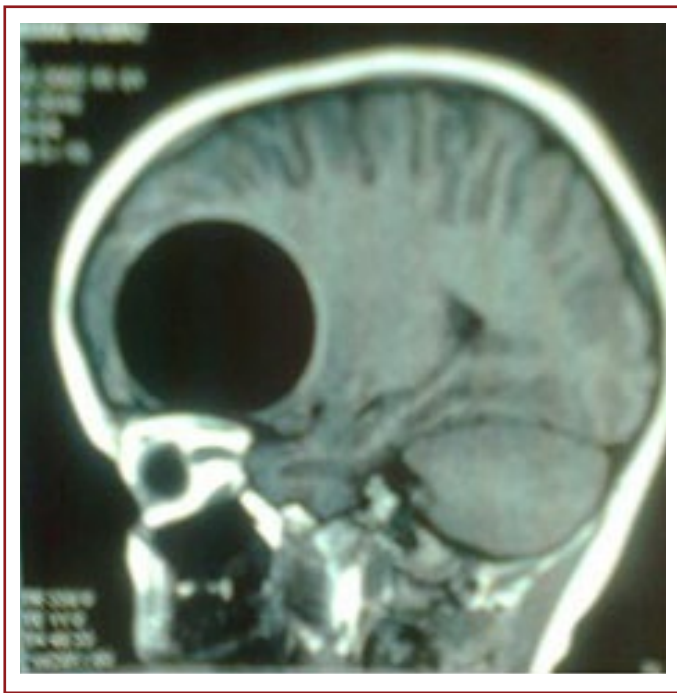	Age	Gender	Size	Area	Solitary/multiple	Symptoms and signs
Patient 1	9	M	5 cm	Frontal	Solitary	Headache
Patient 2	16	F	5 cm	Temporal	Solitary	Headache, seizure
Patient 3	16	M	5 cm	Occipital	Solitary	Headache, homonim hemianopia, strabismus (6. nerve palsy)
Patient 4	14	M	0.5–4 cm	Both hemispheres	Multiple	Headache, diplopia



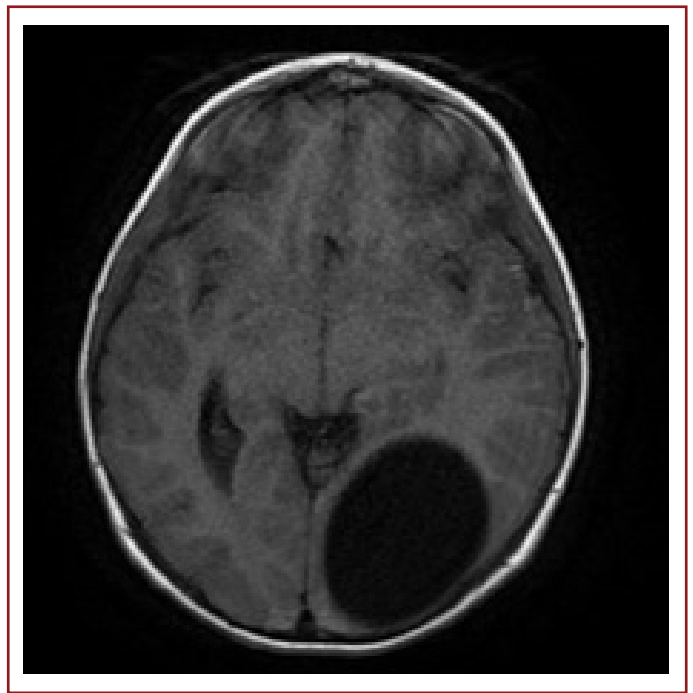
**Figure 1.** Case 4; T1 axial FLAIR magnetic resonance imaging revealed multilocated hydatid cyst with frontal vasogenic edema around the cyst.



**Figure 3.** Case 2; T1 MR coronal non-contrast postoperative magnetic resonance imaging.



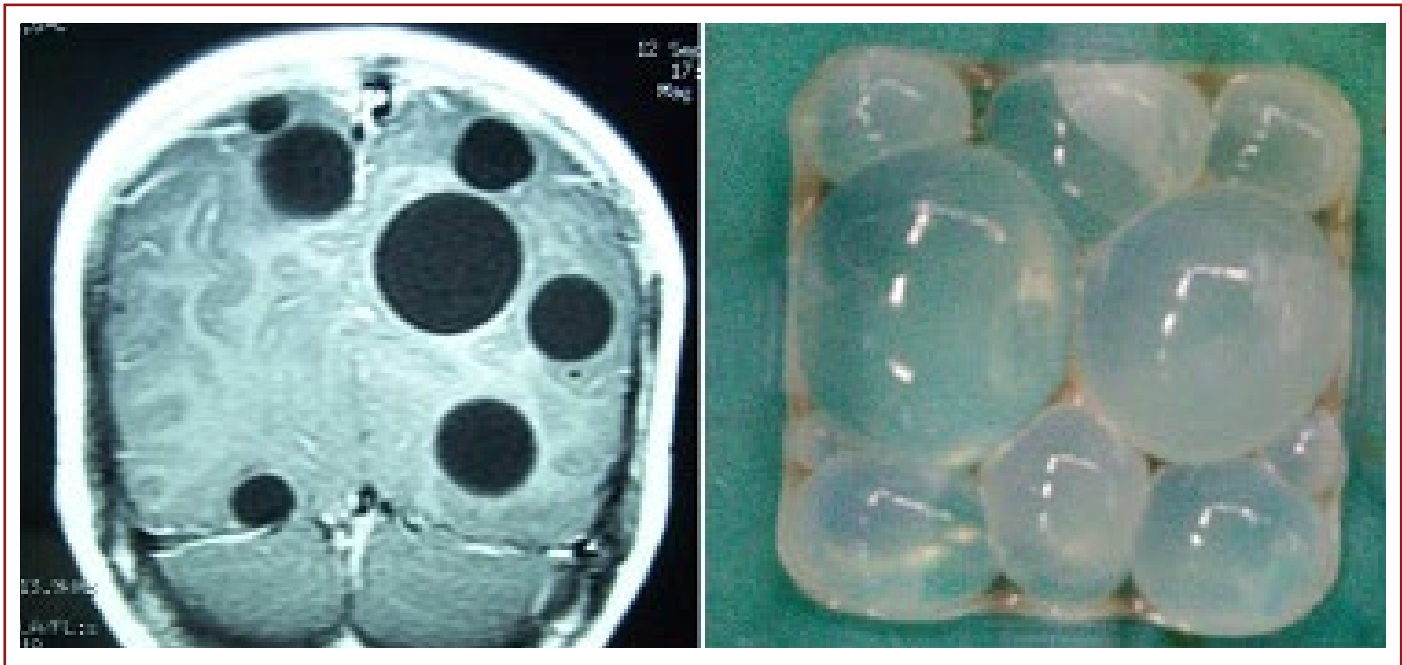
**Figure 2.** Case 1; T1 coronal non-contrast magnetic resonance imaging revealed frontal lobe hydatid cyst.



**Figure 4.** Case 3; T1 coronal non-contrast magnetic resonance imaging revealed occipital lobe hydatid cyst.

area whereas location at the posterior fossa, 4<sup>th</sup> ventricle, medulla spinalis is unusual (the majority of the lesions in medulla spinalis appear as extradural multiple lesions).

Cerebral solitary hydatid cyst is common, whereas multiple cerebral hydatid cysts are quite rare. Calcification of the capsule or the whole of the cyst is occasional. As a result of



**Figure 5.** Case 4; T1 coronal contrast-enhanced magnetic resonance imaging revealed multilocated hydatid cyst and macroscopic image of the resected cysts.

low growth rate of 1 cm/year, brain tissue easily adjusts to mass effect and symptoms do not appear until the mass reaches big size<sup>[8,9]</sup>.

All of our cases had headache and papillary stasis. In addition, our 2<sup>nd</sup> case had epilepsy, 3<sup>rd</sup> case had right homonym hemianopsia, and 4<sup>th</sup> case had diplopia.

Existence of papillary edema is reported to be relatively in low rates as 20%. This can be attributed to well adaptation of brain tissue to the growth of hydatid cyst or inducement of inflammation/optic arachnoiditis by the agent in embryo form during the implantation to the brain. Whereas in children due to highly permeable pulmonary capillary and blood brain barrier, it can easily settle and grow in brain parenchyme. It is reported that headache presents in 40% of cases with cerebral hydatid cyst and this rate improves with age. All of our cases had headache. It is also reported that headache without a reason appears in 20% of children. Existence of papillary edema in all of our cases reveals that severe increase in intracranial pressure is to get her with headache<sup>[10,11]</sup>.

The thickness of the hydatid cyst capsule is a few millimeters and usually looks like grey wash leather. The capsule is composed of fibrous tissue (pericystic layer), laminated chitin on material (intermediate layer) and germinal tissue (inner layer). Worm heads (scolices) inside the cyst fluid are attached to the inner layer. The cyst is colorless and watery and includes cholesterol, scolices, and sometimes daughter cyst. Usually, scolices area lives there for eruption of the cyst

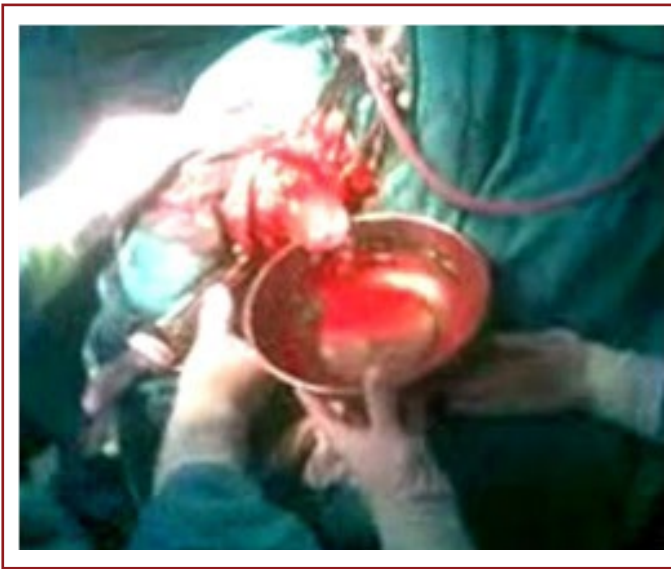at operation results with the contamination of the operation area and infestation. During the progression of the hydatid cyst in brain, thin glial tissue surrounds the capsule<sup>[8,9,12]</sup>.

Cyst capsule is permeable for nutrition of scolices but impermeable for bacteria. Break down of this structure results with intracystic diffusion of the infection and degenerates germinal layer and the cyst collapse. Eventually, inflammatory changes in cholesterol, calcification, and death of scolices with auto sterilization results with natural healing. Since, elements of immune system cannot pass the capsule, meet the antigen and produce anticor; serologic tests are negative and do not have diagnostic value in brain hydatid cysts but in cases with infection of external brain tissue that these tests are positive in 80%. CT and MRI are important in diagnosis. MRI reveals intracystic membrane and membrane detachment, but pericystic edema does not develop<sup>[3,4,13]</sup>. We detected edema around the cyst localized at the right frontal region in our 4<sup>th</sup> case with multiple hydatid cyst (Fig. 6).

## Conclusion

Recently, due to the situations in the middle-east, lots of immigrants left their countries, and live abroad, some of those were already contaminated.

We can state that we have to refresh our knowledge about hydatid cysts and be aware that new cases may arise due to immigration patterns.



**Figure 6.** Case 1; Delivery of the frontal hydatid cyst.

**Ethics Committee Approval:** The Ethics Committee of Ümraniye Training and Research Hospital provided the ethics committee approval for this study (23.06.2021-2213).

**Peer-review:** Externally peer-reviewed.

**Authorship Contributions:** Concept: E.H.; Design: M.E.; Data Collection or Processing: A.E.K.; Analysis or Interpretation: M.E.; Literature Search: A.E.K.; Writing: A.E.K., E.H.

**Conflict of Interest:** None declared.

**Financial Disclosure:** The authors declared that this study received no financial support.

## References

1. Abbassioun K, Rahmat H, Ameli NO, Tafazoli M. Computerized tomography in hydatid cyst of the brain. *J Neurosurg* 1978;49:408–11. [\[CrossRef\]](#)
2. Akinoğlu A, Bilgin I, Erkoçak EU. Surgical management of hydatid disease of the liver. *Can J Surg* 1985;28:171–4.
3. Menku A, Kurtsoy A, Tucar B, Durak CA, Akdemir H. Calcified cerebral hydatid cyst following head trauma: Case report. *Turk Neurosurg* 2004;14:36–40.
4. Yaka U, Aras Y, Aydoseli A, Akcakaya MO, Sencer A, Imer M, et al. Primary multiple cerebral hydatid disease: Still symptomatic despite pathologically confirmed death of the cyst. *Turk Neurosurg* 2013;23:505–8. [\[CrossRef\]](#)
5. Özgen T, Erbeni A, Bertan V, Sağlam S, Gürçay O, Pınar T. The use of computerized tomography in the diagnosis of cerebral hydatid cysts. *J Neurosurg* 1979;50:339–42. [\[CrossRef\]](#)
6. Peterson E, Thoren G, Begquist R. Mebendazole treatment of echinococcus granulosum infection. *Am J Trop Med Hyg* 1983;32:1071–4. [\[CrossRef\]](#)
7. Carrea R, Dowling E Jr, Guevara JA. Surgical treatment of hydatid cysts of the central nervous system in the pediatric age (Dowling's technique). *Childs Brain* 1975;1:4–21. [\[CrossRef\]](#)
8. Köktekir E, Erdem Y, Gökçek C, Karatay M, Yılmaz A, Bayar MA, et al. Calcified intracranial hydatid cyst: Case report. *Türkiye Parazitol Derg* 2011;35:220–3. [\[CrossRef\]](#)
9. Northfield CWD. The surgery of central nervous system. London: Blackwell Scientific Publications; 1973. p.217–9.
10. Kaya U, Ozden B, Türker K, Tarcan B. Intracranial hydatid cysts. Study of 17 cases. *J Neurosurg* 1975;42:580–4. [\[CrossRef\]](#)
11. Roth J, Constantini S, Rosenfeld US. Management of the brain tumors in the pediatric patient. In: Kaya HA, Larws R, editors. *Brain Tumors*. Edinburgh: Elsevier; 2012. p.329–41. [\[CrossRef\]](#)
12. Sharma A, Abraham J. Multiple giant hydatid cysts of the brain. Case report. *J Neurosurg* 1982;57:413–5. [\[CrossRef\]](#)
13. Cavoşoğlu H, Tuncer C, Ozdilmaç A, Aydın Y. Multiple intracranial hydatid cysts in a boy. *Turk Neurosurg* 2009;19:203–7.