

Closed Reduction and Cannulated Screw Fixation for Pediatric Femoral Neck Fractures

Pediyatrik Femur Boyun Kırıklarının Kapalı Redüksiyon ve Kanüle Vida İle Fiksasyonu

Hakan Cici¹®, Sabahaddin Kılıç²®

¹Department of Orthopedics and Traumatology, Izmir Katip Celebi University Atatürk Education and Training Hospital, Izmir, Turkey

²Department of Orthopedics and Traumatology, Siirt State Hospital, Siirt, Turkey

Received: 31.01.2021 / Accepted: 14.02.2021 / Published Online: 31.03.2021

Cite as: Cici H, Kılıç S. Closed reduction and cannulated screw fixation for pediatric femoral neck fractures. Turk J Hip Surg 2021;1(1):21-6.

ABSTRACT

Objective: Pediatric femoral neck fractures are uncommon injuries. Accurate early reduction and fixation is recommended to avoid serious long-term complications. The aim of this study was to analyze the clinical and radiological outcomes of 12 children with femoral neck fractures who were treated with closed reduction and cannulated screw fixation.

Method: Between November 2015 and December 2019, 12 children (4 males, 8 females) with an average age of 9.7 were operated by closed reduction and cannulated screw fixation for femoral neck fractures. We evaluated the medical records of all patients, including age, gender, injury mechanism, fracture type, initial displacement, postoperative reduction, follow-up roentgenograms and Ratliff's scores.

Results: The mean follow-up was 22.3 months (range 12–47 months). Six Delbett type 2, five Delbett type 3 and one Delbett type 4 fractures were operated with an average time to surgery of 12.5 (range: 1-75 hours). Satisfactory outcomes according to Ratliff's criteria were obtained in 10 (%83.3) children. Coxa vara occurred in 2 cases. Any avascular necrosis was not seen during the follow-up period.

Conclusion: Early closed reduction and cannulated screw fixation may be effective to avoid long-term complications in pediatric femoral neck fractures.

Keywords: Femoral neck fracture, Pediatric, Closed reduction

Öz

Amaç: Pediyatrik femur boyun kırıkları nadir görülen yaralanmalardır. Uzun dönemde gelişebilecek ciddi komplikasyonların önlenmesi amacıyla erken dönemde uygun redüksiyon ve fiksasyon önerilmektedir. Bu çalışma, femur boyun kırığı nedeniyle kapalı redüksiyon ve kanüle vida ile fiksasyon uygulanan 12 çocuğun klinik ve radyolojik sonuçlarını analiz etmek amacıyla planlanmıştır.

Yöntem: Kasım 2015-Aralık 2019 tarihleri arasında ortalama yaşları 9.7 olan 12 çocuk hastaya (4 erkek, 8 kız) femur boyun kırığı sebebiyle kapalı redüksiyon ve kanüle vida ile fiksasyon uygulandı. Olguların yaş, cinsiyet, yaralanma mekanizması, kırık tipi, kırık deplasmanı, postoperatif redüksiyon, takipteki radyolojik görüntülemeleri ve Ratliff skorları kayıt altına alındı.

Bulgular: Ortalama takip süresi 22.3 aydı. Altı Delbett tip 2, beş Delbett tip 3 ve bir Delbett tip 4 femur boyun kırığı olan hasta yaralanma sonrası ortalama 12.5 saatte (1-75 saat arası) opere edildi. Takiplerde Ratliff skorlarına göre 10 hastada (%83.3) tatmin edici sonuçlar gözlemlendi. 2 hastada koxa vara gelişti. Takip süresinde hiçbir hastada avasküler nekroz görülmedi.

Sonuç: Pediyatrik femur boyun kırıklarında erken kapalı redüksiyon ve kanüle vida ile fiksasyon uzun dönem komplikasyonların önlenmesinde etkili olabilir.

Anahtar Kelimeler: Femur boyun kırığı, Pediyatrik, Kapalı Redüksiyon

Corresponding Author:

✉ ortocici@outlook.com

H. Cici 0000-0002-9511-4865

S. Kılıç 0000-0001-7730-6030

INTRODUCTION

Pediatric femoral neck fractures (PFNFs) are extremely rare but devastating types of injury. Incidence of PFNFs is less than 1% among all pediatric fractures.⁽¹⁾ The primary treatment of these fractures, which are mostly induced by high-energy traumas, is reduction and fixation as early as possible.^(2,3) Complications such as avascular necrosis, pseudoarthrosis, coxa vara deformity, and premature physeal closure may develop in children based on anatomical factors such as vascular structure of the proximal femur and the presence of an open epiphysis.⁽²⁾ There are limited number of case series in the literature due to their low prevalence rates. In this retrospective study, we presented the clinical and radiological results of patients who underwent closed reduction and fixation for PFNF in the light of current literature.

MATERIALS AND METHODS

We retrospectively reviewed all pediatric patients aged till 16 years of age with femur neck fractures operated by closed reduction and cannulated screw (**Figure 1**) in Siirt State Hospital from November 2015

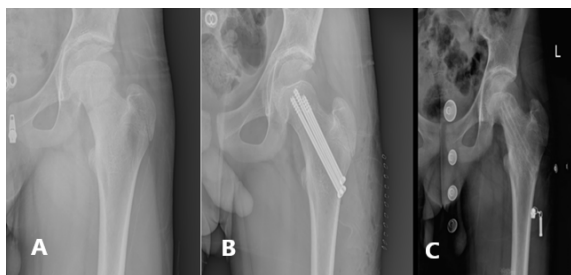


Fig 1. Delbett type 2 nondisplaced fracture in a 12 year- old boy. A. Preoperative roentgenogram. B. Postoperative roentgenogram showing fixation with cannulated screws C. Final roentgenogram after 14 months with no complication.

to December 2019. The first surgical step consisted of gentle closed reduction under fluoroscopy with the patient in supine position. Then the patients underwent internal fixation of fracture with two or three titanium- cannulated screws with 4.0 to 6.5 mm in diameter and varying lengths. We included the patients who had been clinically monitored with a minimum follow-up of 1 year in the study. Patients were excluded if they had pathologic fractures or subtrochanteric fractures and if they had metabolic and cerebrospinal diseases. Ethics committee approval and informed consent for participation from each parents were obtained.

Table 1. Delbett fracture classification.

Type 1	<i>Transepiphyseal separation</i>
Type 2	<i>Transcervical fracture</i>
Type 3	<i>Cervicotrochanteric fracture</i>
Type 4	<i>Intertrochanteric fracture</i>

Patient demographics, mechanism of injury, time to surgery and complications were recorded according to the medical archives. Initial roentgenograms were obtained for the classification of fracture types according to the Delbet fracture classification system modified by Colonna⁽⁴⁾ (**Table 1**). Quality of postoperative reduction was evaluated on early postoperative roentgenograms by the following scale: < 2-mm step-off and no angulation = excellent, < 4-mm step-off and < 5 angulation = good, > 4-mm step-off and < 10 angulation = fair, and > 5-mm step-off and > 10 angulation = poor as described in a previous study.⁽⁵⁾ Final clinical and radiological outcomes were evaluated through the assesment system described by Ratliff⁽¹⁾ (**Table 2**).

Table 2. Ratliff's Clinical and Radiological Assessment System.

	Good	Fair	Poor
Pain	<i>No or Negligible Pain</i>	<i>Occasional pain</i>	<i>Disabling pain</i>
Range of mobility	<i>Full or minimal restriction</i>	<i>Restriction less than %50</i>	<i>Restriction more than %50</i>
Activity	<i>Normal or patient avoid games</i>	<i>Normal or patient avoid games</i>	<i>Restricted activity</i>
Roentgenogram	<i>Normal or minimal deformity</i>	<i>Severe deformity and mild avascular necrosis</i>	<i>Severe avascular necrosis, degenerative arthritis or arthrodesis</i>

Table 3. Patient data.

Case No	Age	Gender	Mechanism	Delbet Type	Displacement	Reduction	Ratliff	Complication
1	11	M	High	3	Displaced	Good	Fair	Varus
2	12	F	High	4	Displaced	Excellent	Good	-
3	6	F	Low	2	-	Excellent	Good	-
4	4	F	High	3	Displaced	Fair	Good	-
5	6	F	Low	3	-	Excellent	Good	-
6	10	M	High	2	-	Excellent	Good	-
7	11	F	High	3	Displaced	Fair	Fair	Varus
8	14	F	High	2	-	Excellent	Good	-
9	9	M	Low	2	Displaced	Fair	Good	-
10	11	F	High	3	-	Excellent	Good	-
11	11	F	Low	2	-	Excellent	Good	-
12	12	M	High	2	-	Excellent	Good	-

RESULTS

Twelve children (four males, eight females) operated for 12 femur neck fractures (six Delbett type 2, five Delbett type 3 and one Delbett type 4) within a period of 4 years were included in the present study (**Table 3**). The average age of the patients at the time of fracture was 9.7 years (range 4-14 years). The average follow up period was 22.3 months (range 12-47 months). Six femur neck fractures (%50) occurred on the right side and six (%50) on the left side. Mechanism of high-energy injury was detected in eight cases (%66.7) due to falls from height. Closed reduction and internal fixation with cannulated screws was performed for all cases with an average time to surgery of 12.5 hours (range 1-75 hours). Fractures were a part of polytrauma in two cases, and these two children could be operated relatively late (more than 24 hours after initial trauma). Postoperative immobilisation with cast was not applied and partial weight bearing was not allowed before postoperative sixth week for all children. Postoperative reduction was excellent in eight (%66.7), good in 1 (%8.3) and fair in three fractures (%25). Using the Ratliff's criteria, ten children had good (%83.3) and two (%16.7) had fair outcomes. Of the two fair outcomes, moderate varus and early closure of the growth plate were detected on

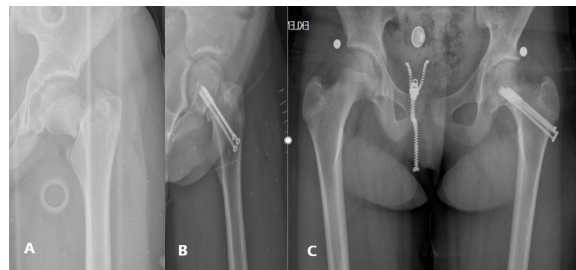


Fig 2. 11 year-old female with Delbett type 3 displaced left hip fracture following fall from height A. Preoperative roentgenogram B. Postoperative roentgenogram showing good (<4mm displacement and <5 degree angulation) reduction and fixation C. 15 months after initial trauma showing moderate varus and early closure of the growth plate

the X-rays at final visit (**Figure 2**). Any avascular necrosis of the hip was not detected during the follow up period.

DISCUSSION

Pediatric femoral neck fractures (PFNFs) are extremely rare. A relatively dense and hard architecture of the proximal femur in children compared to adults is an important factor for this rarity.⁽⁶⁾ Moreover, due to this structural difference, high-energy injury mechanisms such as traffic accidents and falls from height often play a role in the etiology.^(7, 8) In line with the literature, the fractures of most of our patients (66.7%) were caused by high-energy injury mechanisms, and all of

these patients fell from a height. We think that these fractures are due to the fact that people residing in our region spend a considerable portion of their daily lives on house roofs and balconies because of their socio-cultural habits.

PFNFs are classified by the Delbett system, an anatomical classification popularized by Colonna⁽⁴⁾ in 1929. According to this classification, type II (intraarticular transcervical) fractures are the most common type followed by type III (cervicotrochanteric), IV (intertrochanteric), and I (transepiphyseal) fractures. The results of our study are also consistent with this information. (type II: 50%, type III: 41.7%, and type IV: 8.3%). We did not encounter an extremely rare transepiphyseal type I fracture during this period.

Surgical fixation is the main treatment approach recommended for pediatric femoral neck fractures due to the high risk of loss of reduction in patients treated conservatively. Surgical treatment is important for the maintenance of anatomical reduction.⁽⁹⁾ The issue of performing anatomical reduction with open or closed techniques is debatable. In the literature, especially in studies suggesting an open reduction of displaced Delbet type II and III fractures, it is argued that capsular decompression can be performed, a safer anatomic reduction can be achieved, thus avascular necrosis can be prevented.⁽⁹⁻¹¹⁾ However, these studies consist of a retrospective case series of small groups. In addition, the fact that all patients undergoing decompression in these studies consisted of patients who were already treated within 24 hours, may introduce bias. It appears that the preference of treatment for PFNFs other than type I transepiphyseal fractures is often closed reduction (66% for type II, 54% for type III, and 72% for type IV PFNFs).⁽³⁾ Delayed surgery may increase the requirement for open reduction due to the fact that PFNFs can be a part of a polytrauma or due to late admissions of patients.

Since we were able to achieve reasonable reduction (including fair reduction) with gentle manipulations in our patients, we did not need to perform open reduction. To our opinion, a notable remodelling capacity can be expected in younger children. **(Figure 3)**

There is no evidence in the literature showing the effect of the diameter, and number of screws on postoperative complications. Age, gender, skeletal maturity, and type of fracture are factors to be considered when deciding on this matter. We believe that two or three cancellous screws of 4-6.5 mm to be placed in accordance with the principles of basic fracture fixation provide sufficient fixation. Also, the issue of transphyseal screw placement is not clear. Patterson et al. recommended refraining from transphyseal screw methods in patients aged less than 10 years.⁽¹²⁾ However, stable fixation with transphyseal screws should not be compromised in unstable, small medial fragmented and vertical type fractures in older children.

Regardless of the type of reduction and fixation, it is obvious that the most important controllable factor in the development of avascular necrosis is time to surgery.⁽¹³⁻¹⁶⁾ Patients receiving delayed treatment (> 24 hours) have been found to develop avascular necrosis 4.2 times more frequently than patients treated definitively in the first 24 hours.⁽³⁾ Also timing of surgery may affect time to union. Delayed union can be expected in patients operated more than 24 hours after admission.⁽¹⁷⁾ We think that providing definitive fixation in the first 6 hours in all of our patients-except for two children with polytrauma-was the key point to prevent avascular necrosis.

Serious complications may develop after PFNF, with rates varying between 20% and 60% in different series.^(18, 19) Avascular necrosis is the most common complication among these, and its incidence has been reported in the literature in a wide range from 0% to 92%.⁽²⁰⁾ Age, time to surgery, initial

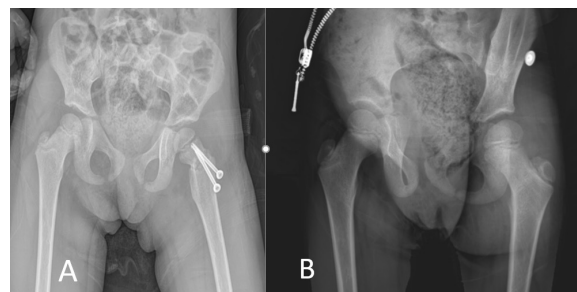


Fig 3. 4 year-old female operated following Delbett type 3 displaced left hip fracture A. Postoperative early roentgenogram showing fair reduction(<10 degree angulation) and fixation with 2 cannulated screws B. Final roentgenogram 23 months after treatment showing union and no complication

displacement, and fracture type are factors that can affect the development of avascular necrosis.^(2, 8, 16, 18) The incidence of avascular necrosis increases with age which is thought to be associated with the lower femoral head revascularization capacity in older children. Due to similar reasons, an increased incidence of avascular necrosis has been observed in intracapsular and more proximal fractures. Compared with type IV fractures, avascular necrosis has been reported to develop 15, 6, and 4 times more frequently in type I, type II, and type III fractures, respectively.^(20, 21) Fracture displacement is thought to be a critical predisposing factor for the development of avascular necrosis through damage on vessels supplying the femoral head.^(16, 18) Also, high intracapsular pressure in nondisplaced fractures may even be effective in avascular necrosis by indirectly impairing the blood supply to the femoral head. Therefore, a few studies have supported routine drainage of intracapsular hematoma by needle aspiration or open capsulotomy technique for intracapsular fractures.^(10, 11, 14) In contrast, Inan et al. reported in their series of 39 cases that routine open reduction and hematoma drainage had no significant effect on preventing postoperative complications.⁽²²⁾ Open capsulotomy may be a radical intervention to reduce intracapsular pressure only, as long as closed reduction can be achieved in PFNFs. Furthermore, we doubt the persistence of low intracapsular pressure to be achieved by needle aspiration without capsulotomy. Certainly, surgeons must avoid attempting forceful and repeated closed reduction maneuvers and they should be able to decide timing for open reduction.

There are very limited data in the literature regarding time interval between injury and avascular necrosis. Although it has been mentioned that radiological findings can usually be observed within the first year after trauma⁽¹⁾, Pavone et al. reported patients with avascular necrosis developed at 14 and 16 months postoperatively.⁽²¹⁾ From this point of view, the minimum follow-up period of 12 months in our series can be considered as a limitation of the study. Long-term follow-up of children is important in terms of potential late complications.

Other serious complications include nonunion, premature closure of the physeal plate, and coxa

vara. Fracture fixation techniques with low maintainability such as immobilization with a plaster cast, Kirsher wires or fixation with threaded pins are considered to be important risk factors for nonunion.^(23, 24)

In different studies, the incidence of coxa vara after PFNFs has been reported in the range of 7-32%.^(14, 16, 25) The incidence of coxa vara in our cases (16.7%) is consistent with the literature. It has been stated that there are factors such as nonoperative treatment, insufficient fixation, and early closure of the physeal plate in the etiology of coxa vara. Internal fixation with screws has been recommended to avoid this complication.⁽⁸⁾ It is also important to avoid early weight-bearing protocols, especially in adolescents with vertically extending fractures.⁽²⁶⁾ Fixation by screws exceeding the growth plate can prevent the development of coxa vara in vertical Delbet type II PFNFs with small medial fragment.⁽²⁷⁾ In our patients, we avoided early weight-bearing protocols to prevent loss of reduction. It was a notable finding that both of our patients who developed coxa vara were older than other patients, had Delbet type II fractures with vertical extension and early closure of the physeal plate in their follow-ups. However, we don't have enough statistical data to clearly state which of these factors played the key role in coxa vara etiology. Coxa vara is a significant complication in terms of unsatisfactory results.^(2, 25) Our 2 patients with coxa vara had already low Ratliff scores. Our study has several limitations. Small sample size and lack of control group limited definitive statistical measurements. Other limitations of the study are mainly related to be retrospective and to the relatively shorter minimum follow-up period. Multicenter prospective studies with a large number of patients are needed to determine the optimal surgical technique that will affect long-term results.

CONCLUSION

PFNFs are extremely rare injuries that can lead to serious complications. When we evaluate our experience with the current literature, we are of the opinion that the early closed reduction and fixation of these fractures may be effective to improve results and prevent long-term complications.

Conflict of Interest: The authors declare that they have no conflict of interest.

Funding: The authors report no source of funding.

Informed Consent: Informed consent for participation from each parents were obtained.

REFERENCES

- Ratliff, A., Fractures of the neck of the femur in children. The Journal of bone and joint surgery. British volume, 1962. 44(3): p. 528-542.
<https://doi.org/10.1302/0301-620X.44B3.528>
- Ratliff, A., Complications after fractures of the femoral neck in children and their treatment. . The Journal of bone and joint surgery. British volume, 1970. 52: p. 8.
- Yeranosian, M., et al., Factors affecting the outcome of fractures of the femoral neck in children and adolescents: a systematic review. The bone & joint journal, 2013. 95(1): p. 135-142.
<https://doi.org/10.1302/0301-620X.95B1.30161>
- Colonna, P.C., Fractures of the neck of the femur in children. The American Journal of Surgery, 1929. 6: p. 6.
[https://doi.org/10.1016/S0002-9610\(29\)90726-1](https://doi.org/10.1016/S0002-9610(29)90726-1)
- Dhar, S.A., et al., Delayed fixation of the transcervical fracture of the neck of the femur in the pediatric population: results and complications. Journal of children's orthopaedics, 2009. 3(6): p. 473-477.
<https://doi.org/10.1007/s11832-009-0209-2>
- Quinlan, W., P. Brady, and B. Regan, Fracture of the neck of the femur in childhood. Injury, 1980. 11(3): p. 242-247.
[https://doi.org/10.1016/S0020-1383\(80\)80051-9](https://doi.org/10.1016/S0020-1383(80)80051-9)
- Smith, L., Hip fractures: the role of muscle contraction or intrinsic forces in the causation of fractures of the femoral neck. JBJS, 1953. 35(2): p. 367-383.
<https://doi.org/10.2106/00004623-195335020-00009>
- Togru, E., et al., Fractures of the femoral neck in children: long-term follow-up in 62 hip fractures. Injury, 2005. 36(1): p. 123-130.
<https://doi.org/10.1016/j.injury.2004.04.010>
- Bali, K., et al., Pediatric femoral neck fractures: our 10 years of experience. Clinics in orthopedic surgery, 2011. 3(4): p. 302-308.
<https://doi.org/10.4055/cios.2011.3.4.302>
- Song, K.-S., Displaced fracture of the femoral neck in children: open versus closed reduction. The Journal of bone and joint surgery. British volume, 2010. 92(8): p. 1148-1151.
<https://doi.org/10.1302/0301-620X.92B8.24482>
- Cheng, J.C. and N. Tang, Decompression and stable internal fixation of femoral neck fractures in children can affect the outcome. Journal of Pediatric Orthopaedics, 1999. 19(3): p. 338-343.
<https://doi.org/10.1097/01241398-199905000-00010>
- Patterson, J.T., J. Tangtiphaibontana, and N.K. Pandya, Management of pediatric femoral neck fracture. JAAOS-Journal of the American Academy of Orthopaedic Surgeons, 2018. 26(12): p. 411-419.
<https://doi.org/10.5435/JAAOS-D-16-00362>
- Bombaci, H., et al., Evaluation of complications of femoral neck fractures in children operated on at least 24 hours after initial trauma. Acta Orthop Traumatol Turc, 2006. 40(1): p. 6-14.
- Ng, G. and W. Cole, Effect of early hip decompression on the frequency of avascular necrosis in children with fractures of the neck of the femur. Injury, 1996. 27(6): p. 419-421.
[https://doi.org/10.1016/0020-1383\(96\)00025-3](https://doi.org/10.1016/0020-1383(96)00025-3)
- Varshney, M.K., et al., Functional and radiological outcome after delayed fixation of femoral neck fractures in pediatric patients. Journal of Orthopaedics and Traumatology, 2009. 10(4): p. 211-216.
<https://doi.org/10.1007/s10195-009-0072-4>
- Canale, S.T. and W. Bourland, Fracture of the neck and intertrochanteric region of the femur in children. JBJS, 1977. 59(4): p. 431-443.
<https://doi.org/10.2106/00004623-197759040-00001>
- Singh, K.A., V. Chandankere, and H. Shah, Does the timing of treatment affect complications of pediatric femoral neck fractures? Journal of Orthopaedics, 2020.
<https://doi.org/10.1016/j.jor.2020.04.023>
- Dendane, M., et al., Displaced femoral neck fractures in children: are complications predictable? Orthopaedics & Traumatology: Surgery & Research, 2010. 96(2): p. 161-165.
<https://doi.org/10.1016/j.otsr.2009.11.007>
- DrCh, H.A.M., Complications of fracture of the neck of the femur in children. A long-term follow-up study. Injury, 2001. 32(1): p. 45-51.
[https://doi.org/10.1016/S0020-1383\(00\)00109-1](https://doi.org/10.1016/S0020-1383(00)00109-1)
- Moon, E.S. and C.T. Mehlman, Risk factors for avascular necrosis after femoral neck fractures in children: 25 Cincinnati cases and meta-analysis of 360 cases. Journal of orthopaedic trauma, 2006. 20(5): p. 323-329.
<https://doi.org/10.1097/00005131-200605000-00005>
- Pavone, V., et al., Surgical treatment with cannulated screws for pediatric femoral neck fractures: A case series. Injury, 2019. 50: p. S40-S44.
<https://doi.org/10.1016/j.injury.2019.01.043>
- Inan, U., N. Köse, and H. Omeroğlu, Pediatric femur neck fractures: a retrospective analysis of 39 hips. Journal of children's orthopaedics, 2009. 3(4): p. 259-264.
<https://doi.org/10.1007/s11832-009-0180-y>
- Forlin, E., et al., Complications associated with fracture of the neck of the femur in children. Journal of Pediatric Orthopaedics, 1992. 12(4): p. 503-509.
<https://doi.org/10.1097/01241398-199207000-00017>
- Neto, P.F.T., et al., Nonunion of fractures of the femoral neck in children. Journal of children's orthopaedics, 2008. 2(2): p. 97-103.
<https://doi.org/10.1007/s11832-008-0078-0>
- Lam, S.F., Fractures of the neck of the femur in children. Journal of bone and joint surgery, 1971. 53(6): p. 11.
<https://doi.org/10.2106/00004623-197153060-00013>
- Estrada, L.S., et al., Fixation failure in femoral neck fractures. Clinical Orthopaedics and Related Research®, 2002. 399: p. 110-118.
<https://doi.org/10.1097/00003086-200206000-00013>
- Eberl, R., et al., Post-traumatic coxa vara in children following screw fixation of the femoral neck. Acta orthopaedica, 2010. 81(4): p. 442-445.
<https://doi.org/10.3109/17453674.2010.501744>