



Comparison of Ultrasonography Guidance Versus Direct Palpation Technique for Central Venous Catheterization in Children Undergoing Cardiac Surgery

Esra Aktiz Bıçak,¹ Deniz Elmastaş,¹ Fikret Salık,² Yiğit Kılıç,³ Cem Kıvılcım Kaçar,¹ Mustafa Bıçak¹

¹Department of Anesthesiology and Reanimation, Diyarbakır University of Health Sciences, Gazi Yaşargil Training and Research Hospital, Diyarbakır, Türkiye

²Department of Anesthesiology and Reanimation, Dicle University Faculty of Medicine, Diyarbakır, Türkiye

³Department of Pediatric Cardiovascular Surgery, Diyarbakır University of Health Sciences, Gazi Yaşargil Training and Research Hospital, Diyarbakır, Türkiye

ABSTRACT

Objectives: We aimed to compare the success rates, procedure times, and complication rates of the Landmark technique with ultrasonography-guided (USG) central venous catheterization (CVC) in children undergoing cardiac surgery.

Methods: This study included 52 patients divided into two equal groups: the CVC with Landmark technique group (Group-1) and the USG CVC group (Group-2). Demographic and clinical characteristics of the patients, internal jugular vein (IJV) diameters, and central venous pressures were measured. Each needle penetration of the skin, defined as one "attempt," was recorded. The success rate, number of first-attempt successful cannulations, number of cannulas used, successful cannulation time, and all observed complications were recorded.

Results: The groups had similar age, weight, height, sex, and diagnosis. There were no differences in IJV diameter, IJV intervention history, and basal central venous pressure between the groups. The successful cannulation time was short, and the number of attempts was low in Group-2. The number of successful cannulations and first-attempt success rate were high in Group-2. The number of cannulas was lower in Group-2 than in Group-1. Failed cannulations occurred in no patients in Group-2 and in seven patients in Group-1. The failed cannulations in five of the patients in Group-1 were subsequently successfully achieved with USG. The complication rates were high in Group-1.

Conclusion: USG CVC catheterization increased the number of successful cannulations and chance of first-attempt success on the, shortened the procedure time, and reduced the incidence rate of complications.

Keywords: Cardiac surgery, central venous catheter, children, palpation technique, ultrasound guidance

Please cite this article as: "Aktiz Bıçak E, Elmastaş D, Salık F, Kılıç Y, Kaçar CK, Bıçak M. Comparison of Ultrasonography Guidance Versus Direct Palpation Technique for Central Venous Catheterization in Children Undergoing Cardiac Surgery. GKDA Derg 2023;29(2):88-94".

Introduction

Percutaneous central venous catheter (CVC) placement is routinely performed for hemodynamic and central venous pressure monitoring, drug administration, and blood transfusion in the anesthetic management of pediatric patients scheduled for congenital cardiac surgery.^[1,2] CVC placement in these patients is more difficult than in adult patients due to factors such as small vessel diameter, history of multiple interventions, and more frequent anatomical

variations.^[3] As the diameter of the intervened vessel increases, the chance of success increases and complication rates decrease. Therefore, in the pediatric patient group scheduled for CVC placement, the internal jugular vein (IJV) is preferred over the subclavian and femoral veins because of its relatively larger vessel diameter.^[4]

With the Landmark technique, which is still routinely used in many centers today, even in the most experienced centers, the complication rates in CVC placement remain consider-

Address for correspondence: Esra Aktiz Bıçak, MD. Diyarbakır Gazi Yaşargil Eğitim ve Araştırma Hastanesi, Anesteziyoloji ve Reanimasyon Kliniği, Diyarbakır, Türkiye

Phone: +90 412 258 00 71 **E-mail:** dresraaktizbicak@gmail.com

Submitted: January 24, 2023 **Revised:** January 25, 2023 **Accepted:** May 22, 2023 **Available Online:** May 31, 2023

The Cardiovascular Thoracic Anaesthesia and Intensive Care - Available online at www.gkdaybd.org

OPEN ACCESS This is an open access article under the CC BY-NC license (<http://creativecommons.org/licenses/by-nc/4.0/>).



ably high.^[5] Repeated unsuccessful punctures in patients may cause simple complications such as local hematoma and arterial puncture as well as serious complications such as pneumothorax, chylothorax, hemothorax, and mediastinitis. Therefore, to reduce the incidence of complications and increase the rate of success, current guidelines recommend providing ultrasonography-guided (USG) vascular access.^[6] Vein diameter, localization, congenital anomalies, and anatomical variations are easily detected with US guidance. In addition, simultaneous visualization of the needle during the procedure leads to higher success, fewer needle insertions, shorter catheterization time, and fewer complications.^[7]

This study aimed to compare the success rates, procedure times, and complication rates of the Landmark technique with USG CVC.

Methods

The hospital's ethics committee approval was obtained for this prospective randomized study (#20.12.2019-402). The study included 52 pediatric patients with an American Society of Anesthesiologists score of 3–4 who underwent congenital cardiac surgery between January 1, 2020 and January 1, 2021. Parental consent was obtained for each patient. The study was conducted in accordance with the 2008 Helsinki Declaration.

The exclusion criteria were as follows: parental refusal of the patient to participate in the study, hemodynamic instability, history of allergy to US gel, thrombocytopenia <50,000 cells/ml, international normalized ratio value >1.5, and emergency surgery (Fig. 1).

For the patient selection, sealed envelopes were placed in patient files during preoperative anesthetic evaluation. Patient randomization was determined according to the envelopes placed in the patient files at the time of the preoperative evaluation immediately before the procedure. The patients were divided into two groups: those who underwent USG-guided CVC (Group-1, n=26) and those who underwent CVC with the Landmark technique (Group-2, n=26). In both groups, the right IJV was primarily preferred for CVC. However, if there was a contraindication, such as hematoma, infection, or thrombosis at the intervention site, catheterization was performed on the left side. All catheterizations were performed by the same anesthesiologist who was experienced in pediatric cardiac anesthesia (anesthesiologist with >50 catheterizations) and had experience in USG catheterization in children and adults.

Electrocardiography, pulse oximetry, and blood-pressure monitoring were performed after the patients were taken to the operating table. Patients received 0.1 mg/kg midazolam (Dormicum® 5 mg/5 ml, Roche, Türkiye), 2 mcg/kg fentanyl

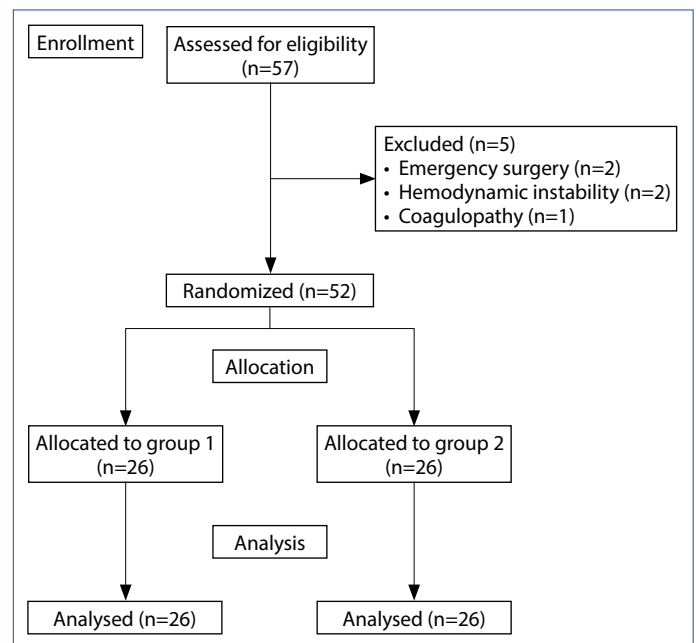


Figure 1. Flow diagram.

(Talinat, Vem, Istanbul, Türkiye), 2–3 mg/kg propofol (propofol 1% Fresenius®; Fresenius Kabi Medicine, Istanbul, Türkiye), and 0.6 mg/kg rocuronium (Esmeron®, Merck Sharpoo Dohme Pharmaceuticals Ltd., Germany) for induction. After adequate muscle relaxation was achieved, orotracheal intubation was performed using an appropriately-sized endotracheal tube, and the patient was connected to a mechanical ventilator (Dräger Primus; Dräger AG, Lübeck, Germany).

Before the procedure, a linear USG probe (5–12 MHz, Esaote, MyLab Six, the Netherlands) was used to measure the anterior–posterior IJV diameter in both groups. The catheter diameters to be used did not exceed 1/3 of the measured vein diameter as a general rule.^[8] Before the procedure, the neck area was cleaned with 10% povidone iodine and covered with a sterile perforated drape. All patients were placed in a 20°–30° Trendelenburg position before catheterization. The head was turned 45°–60° to the opposite side of the jugular vein to be intervened. A shoulder roll was used to expose the puncture site.

A linear probe was used for catheterization in Group-1. The probe was wrapped in a sterile sheath and placed in the short axis between the cricoid cartilage and the clavicle in the neck. To obtain the widest cross-section of the IJV, the optimal position was determined by proximal and distal movements with minimal pressure. Out-of-plane and short axis approaches were applied during the procedure. After the aspiration of venous blood, the Seldinger technique was used to send the guide wire through the needle. The position of the guide wire in the IJV was confirmed with the USG probe using the short and long axes. After dilatation,

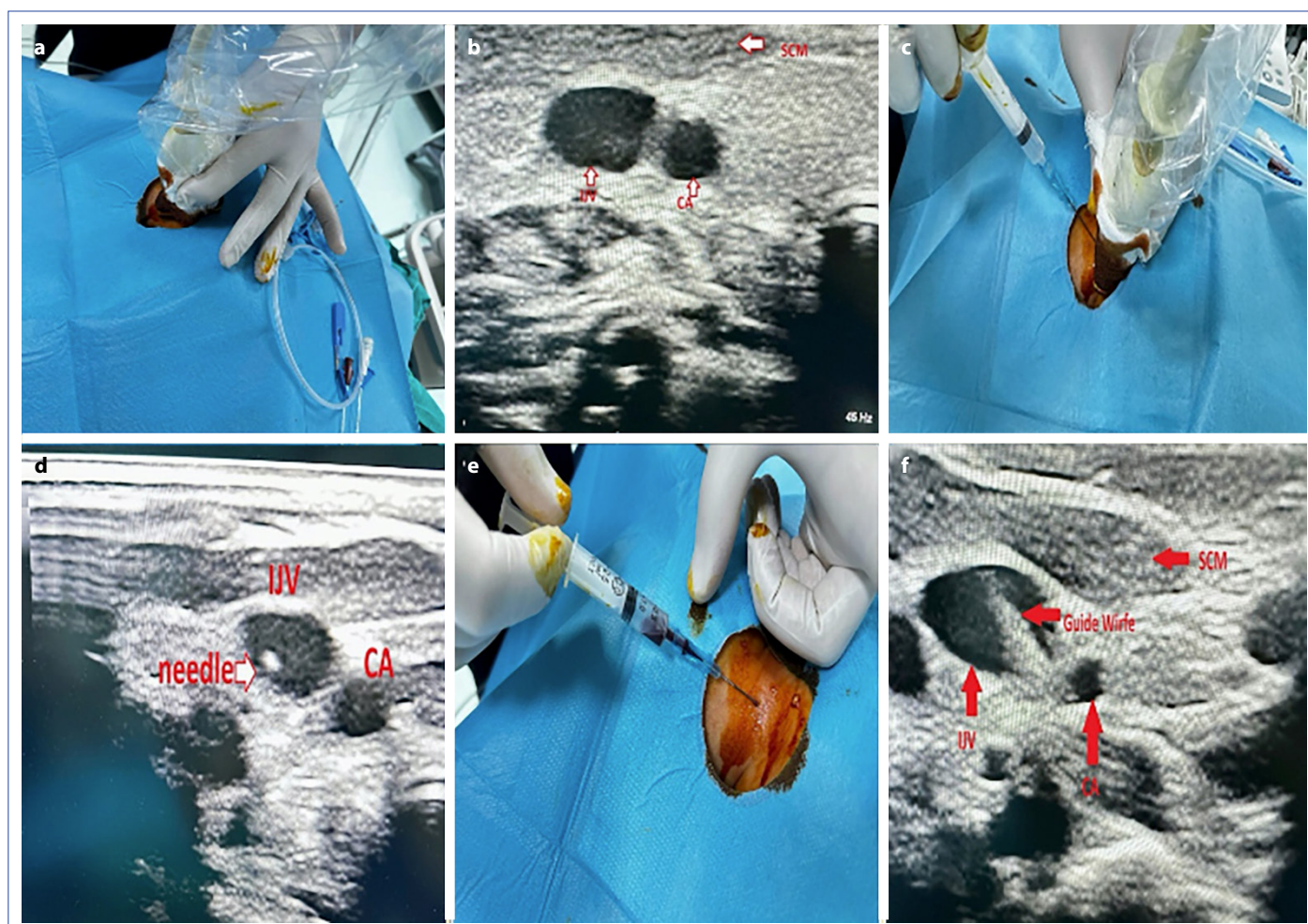


Figure 2. Procedure for ultrasonography-guided central venous catheterization. (a) Probe positioning for short axis (transverse) view, (b) short axis ultrasound view of internal jugular vein (IJV), carotis artery (CA) and sternocleidomastoid muscle (SCM), (c) needle insertion, (d) short axis real-time ultrasound image for needle view within internal jugular vein, (e) venous puncture, (f) long axis real-time ultrasound image for guide wire view within internal jugular vein.

a central catheter was inserted into the vein through the guide wire and then fixed therein (Fig. 2).

In Group-2, the apex of the triangle formed by the sternal and clavicular heads of the sternocleidomastoid muscle with the clavicle was determined to be the entry site. The needle was directed toward the ipsilateral nipple. After monitoring the aspiration of venous blood, the Seldinger technique was used to send a guide wire through the needle, and the needle was then removed. Following dilatation performed with the help of a dilator of appropriate size over the wire, a central catheter with its lumen washed with saline was inserted and fixed with a 2/0 silk suture.

In both groups, if cannulation could not be achieved after three attempts or within 15 min, the method was considered to have failed, and we switched to the alternative method. The reasons for failure were recorded. When cannulation could not be achieved with the alternative technique, surgical cannulation using the cut-down technique was performed.

The demographic and clinical characteristics of the patients were recorded. IJV diameters and central venous pressures measured in both groups were recorded. Patients with a history of intervention at the same site were reported. Each skin penetration with the needle was considered as one "attempt" and recorded. The success rate, number of first-attempt successful cannulations, number of cannulas used, and time until successful cannulation were recorded. All observed complications were recorded.

Statistical Analysis

For statistical analysis, the program SPSS v.22.0 for Windows (IBM SPSS Statistics for Windows, IBM Corp., Armonk, NY) was used. Numerical data were expressed as the mean and standard deviation and categorical data as the frequency and percentage. The Kolmogorov–Smirnov test was performed to test for normality of the distribution of the noncategorical data. Student's t-test was per-

Table 1. Patient characteristics

	Group 1 (n=26)	Group 2 (n=26)	p
Age (month)	13.8±14.6	15.6±17.3	0.680
Weight (kg)	7.3±2.9	7.9±3.9	0.575
Height (cm)	69.8±11.6	71.7±13.1	0.579
Sex			
Male	16	14	0.575
Female	10	12	
Diagnosis			0.394
TOF	7	4	
VSD	8	6	
AVSD	3	6	
TAPVD	0	3	
Coarctation of the aorta	1	1	
Others	7	6	
Baseline heart rate	124±12	123±14	0.894
Baseline systolic blood pressure (mmHg)	87±14	82±14	0.222
Baseline diastolic blood pressure (mmHg)	50±10	46±8	0.118
Baseline central venous pressure (mmHg)	4.6±3.5	4.3±3.0	0.737
IJV diameter (mm)	5.7±1.2	6.1±0.9	0.219
Previous cannulation, n (%)	6 (23.1)	6 (23.1)	1.000

*: Statistically significant. Data are means±SD or numbers. TOF: Tetralogy of fallot; VSD: Ventricular septal defect; AVSD: Atrioventricular septal defect; TAPVD: Total anomalous pulmonary venous drainage; IJV: Internal jugular vein.

formed to compare normally distributed data, and the results were given as the mean±SD. The Mann–Whitney U-test was performed to compare the data that was not normally distributed, and the results were presented as the mean±SD. The chi-square or Fisher's exact test was performed to compare the categorical data in the groups,

and the results were presented as n %. In all comparisons, $p < 0.05$ was accepted as indicating statistical significance.

Results

The demographic characteristics of the patients are shown in Table 1. The two groups were similar in age, weight, height, sex, and diagnosis. There were no differences in the IJV diameter and history of interventions on the IJV between the two groups. There was no difference in basal central venous pressure between the groups.

The cannulation success results are presented in Table 2. Compared with Group-2, the time until successful cannulation was shorter ($p < 0.001$), and the number of attempts was lower ($p = 0.002$) in Group-1 than Group-2. The number of successful cannulations and first-attempt success rate were significantly higher in Group-1 ($p = 0.012$ and 0.002 , respectively). Fewer cannulas were used in Group-1 than in Group-2 ($p = 0.004$).

There were 0 and 7 failed cannulations in Groups 1 and 2, respectively. The failed cannulations in Group-2 were caused by unsuccessful venipuncture in one patient and inability to advance the guide wire in six patients. In five of the patients with failed cannulations in Group-2, subsequent cannulations were successfully performed under USG. The numbers of patients who underwent surgical cut-down following failed cannulations were similar between the two groups.

No complication developed in any patient in Group-1. In Group-2, hematoma occurred in two patients, thrombus occurred in one patient, hemothorax occurred in one patient, pneumothorax occurred in one patient, and chylothorax occurred in one patient postoperatively (Figs 3–5). The complication rates were significantly higher in Group-2 than in Group-1 ($p = 0.034$).

Table 2. Outcome data

	Group 1 (n=26)		Group 2 (n=26)		p
	n	%	n	%	
Time of attempted cannulation (min)	4.6±1.8		8.8±4.1		<0.001*
Number of attempts (n)	1.1±0.3		1.7±0.9		0.002*
Successful cannulation on first attempt	23	88.5	15	57.7	0.012*
Patients with successful cannulation	26	100	19	73.1	0.004*
Causes of failure					0.018*
Failure to puncture vessel	0		1		
Failure to place guide wire	0		6		
Number of cannulae used (n)	1.0±0.0		1.2±0.4		0.004*
Surgical cutdown	0		2		0.149
Complications	0		6		0.034*

*Statistically significant

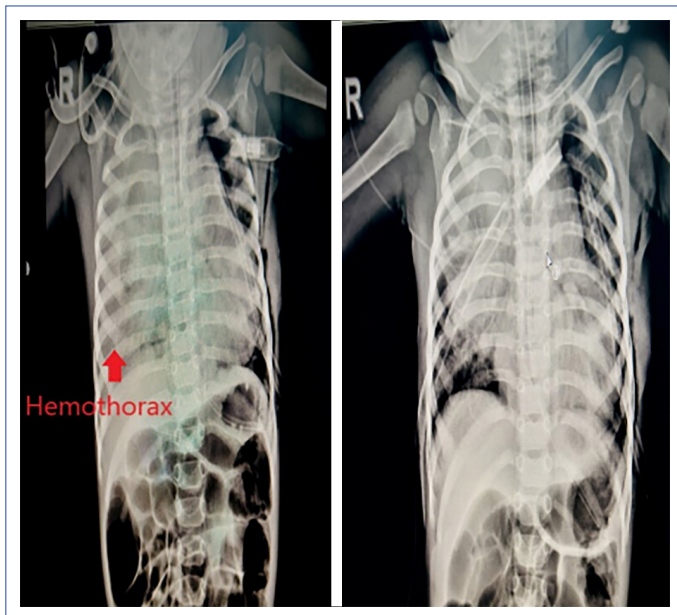

Figure 3. Hemothorax.

Discussion

According to our study, compared with the Landmark technique, USG increased the success rate, shortened access times, and decreased the frequency of complications in CVC applications for pediatric patients undergoing cardiac surgery.

In their prospective study of 179 pediatric patients, Vafek et al.^[9] compared USG CVC application with the Landmark technique and found that the rate of success and number of successful first attempts were higher in the USG group, but the difference was not significant. In a study by Froehlich et al.^[10] that included 212 patients hospitalized in the pediatric anesthesia intensive care unit, the researchers found no difference in the success rate and procedure duration between the Landmark technique and USG. When we examined the methodologies in the studies, we found that the practitioners in the two studies had varying levels of experience, and venous intervention sites were not standardized on a single site. Catheterization success in CVC applications is affected by many factors, such as the diameter and tracing of the veins in the venous access site. In addition, in the applications performed using USG, it is obvious that the success rate increases with higher levels of experience. We believe that the lack of standardization of all these variables, which may affect the results of the studies, is a limitation in the methodology of these studies and affects their results.

In their study of 150 pediatric patients, Bruzoni et al.^[11] compared USG with the Landmark technique in CVC cannulation and found that USG increased the chance of successful first attempts. In their meta-analysis of 15 studies,

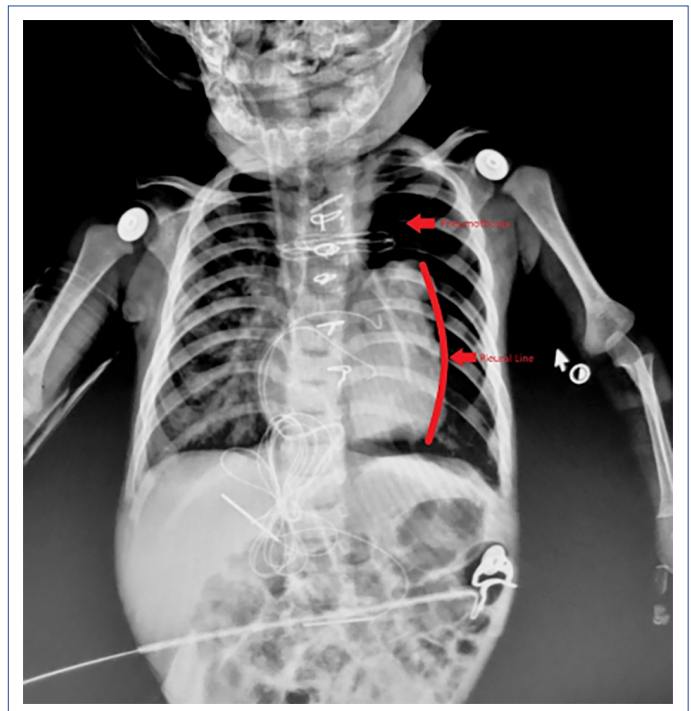


Figure 4. Pneumothorax.

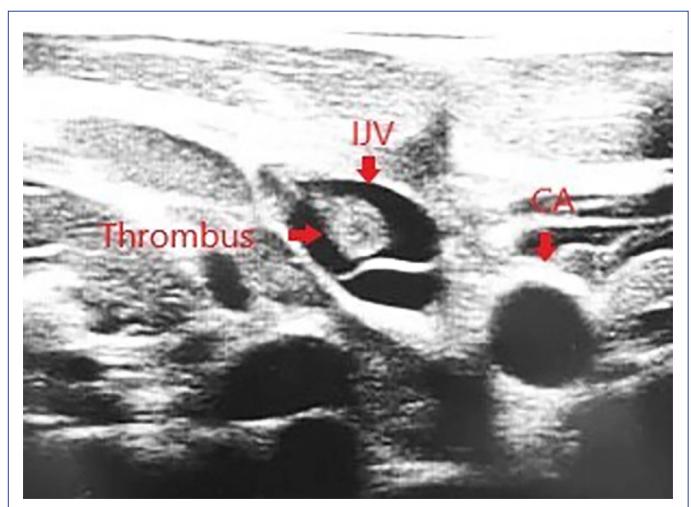


Figure 5. Thrombus.

IJV: Internal jugular vein; CA: Carotid artery.

Lau et al.^[12] found that, compared with the Landmark technique, USG significantly reduced the incidence of failed CVC cannulation in a pediatric patient population. In their meta-analysis of 760 pediatric patients, Lau et al.^[12] found that USG reduced the failure rates in CVC cannulation. Consistent with many studies in the literature, our study also showed that the use of USG in CVC cannulation by an experienced practitioner in the pediatric patient group increased the success rates by shortening the access time.

In a study by Deny et al.^[13] involving 200 patients to determine vascular malposition in the IJV in adult patients, it

was reported that 5.5% of patients had malposition. In the study of Alderson et al.^[14] in a pediatric patient group, this rate was 18%. No matter how experienced the practitioners are in CVC cannulation in the pediatric patient group, failure rates will be higher due to the high incidence of malposition for the Landmark technique (based on blind estimation of the normal anatomy) than for USG-guided CVC cannulation for which detailed anatomical visualization is available. Our study results are consistent with those in the literature.

One of the important factors determining the chance of success in cannulation is the diameter of the vessel to be intervened. Studies have shown that as the patient weight and surface area decrease, the vessel diameter decreases, and therefore, the chance of successful CVC application is lower in pediatric patients than in adults.^[10,15] When we analyzed the reasons for failure in our patients, we found that the most common reason was the inability to advance the guide wire. We believe that this is because the needle is not fully inserted into the lumen of the vessel and the guide wire cannot be placed correctly in children with small vessel diameters in applications performed with the blind technique. We attributed the fact that we did not encounter this problem in the USG group to not being able to determine the needle and catheter locations more accurately by USG. Another reason for failure in our study was unsuccessful venipuncture. Many studies have emphasized that venous anatomical malrotation are more common in pediatric patients in adults. The incidence of this malrotation in patients scheduled for cardiovascular surgery is even higher than in the normal pediatric population.^[10,14] Therefore, especially in this patient group, USG helps identify malrotation and increases the chance of success by allowing more accurate artery-vein anatomical localization than does the Landmark technique.

Similar to our results, the meta-analysis of de Souza et al.^[16] showed that the incidence of complications, such as arterial puncture, was reduced by USG relative to that by the Landmark technique. A meta-analysis of 354 patients by Oulego-Eroz et al.^[3] showed a decrease in all complication rates when USG was used. Another noteworthy point in this study is that practitioners were divided into three groups according to their experience: low, medium, and high. Although the proportion of highly experienced practitioners was higher in the group using the Landmark technique, the first-attempt and overall success rates were higher and the total number of attempts and overall complications incidence rate were lower in the USG group. These results further indicate how successful USG was versus the Landmark technique.

In our study results, consistent with the literature reports, we found fewer complications in the USG group. When we evaluated the complications in the group cannulated with the Landmark technique, we found that the most com-

mon complications were hematoma and arterial puncture, whereas there were no complications in the USG group. We also found that one patient in the Landmark technique group developed chylothorax in the postoperative period. When we reviewed the patient records, we found that the puncture was performed primarily from the right jugular vein in this patient, and cannulation was then performed from the left side upon development of hematoma. Therefore, especially in CVC applications on the left IJV, ductus thoracicus injury should be kept in mind as a very rare complication (1%) that may lead to mortal consequences without early intervention.^[17] We believe that a preference for the right jugular region and the use of USG can help prevent this rare complication.

Limitations

Our study's limitations include its single-center nature, the frequency of catheter-related infections was not determined due to perioperative broad-spectrum antibiotherapy, and the USG preparation time was excluded from the procedure time in the USG group.

Conclusion

Our study results showed that in patients undergoing pediatric cardiovascular surgery, USG CVC catheterization increased the number of successful cannulations, increased the chance of first-attempt success, shortened the procedure time, and reduced the complications incidence rate. Therefore, we recommend the widespread use of USG in CVC applications in pediatric patients scheduled for cardiovascular surgery and that training should be provided to clinics that do not have experience in the routine use of USG. In this way, we believe that more successful cannulation procedures can be performed with a lower incidence rate of complications.

Disclosures

Ethics Committee Approval: The study was approved by The Diyarbakır University of Health Sciences, Gazi Yaşargil Training and Research Hospital Clinical Research Ethics Committee (Date: 20/12/2019, No: 402).

Informed Consent: Written informed consent was obtained from all patients.

Peer-review: Externally peer-reviewed.

Conflict of Interest: None declared.

Financial Disclosure: The authors declared that this study has received no financial support.

Authorship Contributions: Concept – D.E., F.S., Y.K.; Design – E.A.B., D.E., F.S., M.B.; Supervision – D.E., M.B., C.K.K.; Fundings – F.S., M.B., Y.K.; Materials – E.A.B., M.B., C.K.K.; Data collection &/or processing – D.E., Y.K., C.K.K.; Analysis and/or interpretation – F.S., M.B., E.A.B.; Literature search – E.A.B., Y.K., C.K.K.; Writing – E.A.B., M.B., Y.K.; Critical review – D.E., F.S., E.A.B.

References

1. Alten JA, Borasino S, Gurley WQ, Law MA, Toms R, Dabal RJ. Ultrasound-guided femoral vein catheterization in neonates with cardiac disease*. *Pediatr Crit Care Med* 2012;13:654–9.
2. Silveti S, Aloisio T, Cazzaniga A, Ranucci M. Jugular vs femoral vein for central venous catheterization in pediatric cardiac surgery (PRECISE): Study protocol for a randomized controlled trial. *Trials* 2018;19:329.
3. Oulego-Eroz I, González-Cortes R, García-Soler P, Balaguer-Gargallo M, Frías-Pérez M, Mayordomo-Colunga J, et al. Ultrasound-guided or landmark techniques for central venous catheter placement in critically ill children. *Intensive Care Med* 2018;44:61–72.
4. Breschan C, Platzer M, Jost R, Stettner H, Likar R. Size of internal jugular vs subclavian vein in small infants: An observational, anatomical evaluation with ultrasound. *Br J Anaesth* 2010;105:179–84.
5. Augoustides JG, Horak J, Ochroch AE, Vernick WJ, Gambone AJ, Weiner J, et al. A randomized controlled clinical trial of real-time needle-guided ultrasound for internal jugular venous cannulation in a large university anesthesia department. *J Cardiothorac Vasc Anesth* 2005;19:310–5.
6. Bodenham Chair A, Babu S, Bennett J, Binks R, Fee P, Fox B, et al. Association of anaesthetists of Great Britain and Ireland: Safe vascular access 2016. *Anaesthesia* 2016;71:573–85.
7. Hoffman T, Du Plessis M, Prekupec MP, Gielecki J, Zurada A, Tubbs RS, et al. Ultrasound-guided central venous catheterization: A review of the relevant anatomy, technique, complications, and anatomical variations. *Clin Anat* 2017;30:237–50.
8. Tanabe H, Takahashi T, Murayama R, Yabunaka K, Oe M, Matsui Y, et al. Using ultrasonography for vessel diameter assessment to prevent infiltration. *J Infus Nurs* 2016;39:105–11.
9. Vafek V, Skříšiovská T, Kosinová M, Klabusayová E, Musilová T, Kramplová T, et al. Central venous catheter cannulation in pediatric anesthesia and intensive care: A prospective observational trial. *Children (Basel)* 2022;9:1611.
10. Froehlich CD, Rigby MR, Rosenberg ES, Li R, Roerig PL, Easley KA, et al. Ultrasound-guided central venous catheter placement decreases complications and decreases placement attempts compared with the landmark technique in patients in a pediatric intensive care unit. *Crit Care Med* 2009;37:1090–6.
11. Bruzoni M, Slater BJ, Wall J, St Peter SD, Dutta S. A prospective randomized trial of ultrasound- vs landmark-guided central venous access in the pediatric population. *J Am Coll Surg* 2013;216:939–43.
12. Lau CS, Chamberlain RS. Ultrasound-guided central venous catheter placement increases success rates in pediatric patients: A meta-analysis. *Pediatr Res* 2016;80:178–84.
13. Denys BG, Uretsky BF. Anatomical variations of internal jugular vein location: Impact on central venous access. *Crit Care Med* 1991;19:1516–9.
14. Alderson PJ, Burrows FA, Stemp LI, Holtby HM. Use of ultrasound to evaluate internal jugular vein anatomy and to facilitate central venous cannulation in paediatric patients. *Br J Anaesth* 1993;70:145–8.
15. Mortensen JD, Talbot S, Burkart JA. Cross-sectional internal diameters of human cervical and femoral blood vessels: Relationship to subject's sex, age, body size. *Anat Rec* 1990;226:115–24.
16. de Souza TH, Brandão MB, Nadal JAH, Nogueira RJN. Ultrasound guidance for pediatric central venous catheterization: A meta-analysis. *Pediatrics* 2018;142:e20181719.
17. Anestis N, Christos FC, Ioannis P, Christos I, Lampros P, Stephanos P. Thoracic duct injury due to left subclavicular vein catheterization: A new conservative approach to a chyle fistula using biological glue. *Int J Surg Case Rep* 2012;3:330–2.