



Simultaneous Visualization of an Iatrogenic Cuff Rupture in a Patient Intubated with a Video-Double Lumen Tube

Hija Yazıcıoğlu,¹ Bilfer Özler,¹ Alkın Yazıcıoğlu,² Mahmut Subaşı,² Ayşegül Özgök¹

¹Department of Anesthesiology and Reanimation, University of Health Sciences, Ankara Bilkent City Hospital, Ankara, Türkiye

²Department of Thoracic Surgery, University of Health Sciences, Ankara Bilkent City Hospital, Ankara, Türkiye

ABSTRACT

VivaSight™ Video-Double Lumen Tube (V-DLT) is a new DLT with an embedded camera. It is connected to a monitor that continuously demonstrates the position of the tube relative to that of the carina. It is very effective for the rapid placement of the DLT. Additionally, it recognizes tube repositioning and maintains one-lung ventilation. There is no risk of contamination because it is disposable. Herein, we present the case of a patient where simultaneous visualization allowed the detection of an iatrogenic cuff rupture in a patient intubated with VivaSight V-DLT and the challenging anesthetic management following air leakage during remainder of the procedure.

Keywords: One-lung ventilation, thoracic anesthesia, video-double lumen tube, VivaSight

Please cite this article as: "Yazıcıoğlu H, Özler B, Yazıcıoğlu A, Subaşı M, Özgök A. Simultaneous Visualization of an Iatrogenic Cuff Rupture in a Patient Intubated with a Video-Double Lumen Tube. GKDA Derg 2024;30(1):50-52."

Introduction

VivaSight™ Video-Double Lumen Tube (V-DLT) (VivaSight 2DL; Ambu, Ballerup, Denmark) is a new double-lumen tube (DLT) with an embedded camera (Fig. 1). It is connected to a monitor that continuously shows the position of the tube relative to that of the carina. It is very effective for the rapid placement of a DLT; it recognizes tube repositioning and maintains one-lung ventilation (OLV).^[1-4] There is no risk of contamination as it is disposable.^[1,3] Herein, we have presented this case to draw attention to the simultaneous visualization of an iatrogenic cuff rupture in a patient intubated using VivaSight V-DLT and the anesthetic management of air leakage during the surgical procedure.

Case Report

A 63-year-old male weighing 70 kg was hospitalized with bronchial cancer following the detection of a mass in the left upper lobe of the lung. Left upper sleeve lobectomy and lymph node dissection were planned. The patient had

previously undergone ileal loop operation and had been classified as American Society of Anesthesiologists (ASA) III. Premedication (1 mg midazolam) was administered, and routine beside monitoring, BIS, and intra-arterial cannulation were performed. Anesthesia was induced using lidocaine (1 mg/kg), fentanyl (1µg/kg), propofol (2.5 mg/kg) and rocuronium (0.7 mg/kg). He was intubated using a left-sided V-DLT (VivaSight) (Fig. 2), while continuously observing the whole intervention on a video monitor. The tube location was confirmed by auscultation of the chest. Anesthesia was maintained as TIVA using propofol and remifentanyl infusions, with intermittent rocuronium boluses.

Intraoperatively, the surgeons decided to perform a complete lobectomy instead of a sleeve resection the tumor had spread more than estimated. While performing the left upper lobe bronchial anastomosis following upper lobe resection, the surgeon accidentally punctured the endobronchial cuff with the suture needle before the anesthetist could withdraw the endobronchial lumen to the level of the carina. This was clearly visible on the video monitors. Following cuff

This study was presented as an oral presentation at the 25th congress of GKDA and YB (20–23 April 2019).

Address for correspondence: Hija Yazıcıoğlu, MD. Sağlık Bilimleri Üniversitesi, Ankara Bilkent Şehir Hastanesi, Anesteziyoloji ve Reanimasyon Kliniği, Ankara

Phone: +90 312 552 60 00/701008 **E-mail:** hija001@hotmail.com

Submitted: April 04, 2023 **Revised:** May 30, 2023 **Accepted:** June 16, 2023 **Available Online:** March 22, 2024

The Cardiovascular Thoracic Anaesthesia and Intensive Care - Available online at www.gkdaybd.org

OPEN ACCESS This is an open access article under the CC BY-NC license (<http://creativecommons.org/licenses/by-nc/4.0/>).



deflation and air leakage, the peripheral oxygen saturation (SpO₂) decreased to 90–92% for about 20–30 seconds. The patients were manually ventilated using high-pressure 100% oxygen until the upper lobe bronchial anastomosis was quickly sutured. The patient was ventilated continuously while inflating the balloon with the cuff injector to prevent air leakage from the pinhole created. Subsequently, the DLT was withdrawn and the surgery was completed with single-lumen ventilation. The patient was extubated uneventfully and transported to the ICU.

Conclusion

Double-lumen tubes enable OLV, which is required in almost all thoracic surgeries. A left-sided DLT is frequently preferred for OLV, if it is not contraindicated. When the use of a right-sided DLT for OLV is imperative, such as patients with suppurative bronchial lung disease, displacement of the Murphy's eye from the right apical upper lobe is not rare. Therefore, the use of right-sided DLTs almost always necessitates the use of a FOB multiple times. Hence, a left-sided DLT is often used unless contraindicated.

The relatively new V-DLT is superior to the conventional DLT. It eliminates the need for an FOB during tube insertion.^[1–4] Additionally, it can detect tube displacements during patient positioning in real-time.^[1–4] Readjustment of a malpositioned DLT during surgical manipulation is quick due to the continuous tracheal visualization.^[2–4] An unusual iatrogenic surgical injury, such as the puncture of a tube cuff by a surgical needle, can be easily recognized due to the constant airway monitoring, as was seen in our case. Oxygen desaturation is a common consequence of tube malpositioning or surgical manipulation. Thus, the use of a V-DLT reduces the risk of hypoxemia to nearly zero. This has been explained in detail in a recent study by Wang et al.^[5] By eliminating the use of an FOB multiple times, V-DLT makes contamination impossible.^[2–4] Additionally, infection due to inoculation of a micro-organism in the trachea or endobronchial lumen is avoidable as the V-DLT is disposable. The relatively high price of the V-DLT makes it unaffordable for use in developing countries.^[6] However, taking into account the need for sterilization after every use of FOB and its maintenance, the cost of the conventional DLT increases. Future cost analyses may reveal a more compelling economic justification for the use of a V-DLT. In conclusion, the VivaSight™ V-DLT is one of the best technological equipment that ensures quick and correct placement of the DLT. Additionally, it allows for real-time detection of tube malpositioning. V-DLT significantly reduces the use of an FOB. Furthermore, the risk of contamination or infection is nearly impossible because it is disposable. Because it allows the continuous monitoring of airway security, an iatrogenic surgical complication can be immediately detected, as seen in this case report. We believe it will be used more frequently if it is made more affordable.

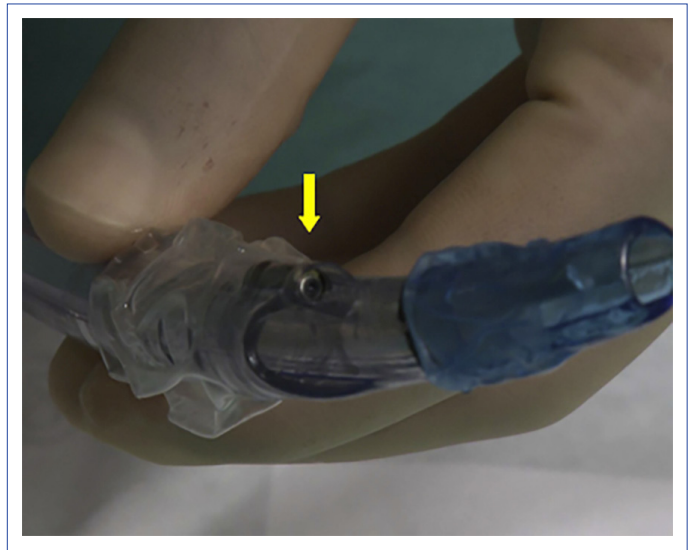


Figure 1. VivaSight™ Video-Double Lumen Tube. The yellow arrow depicts the location of the embedded camera.

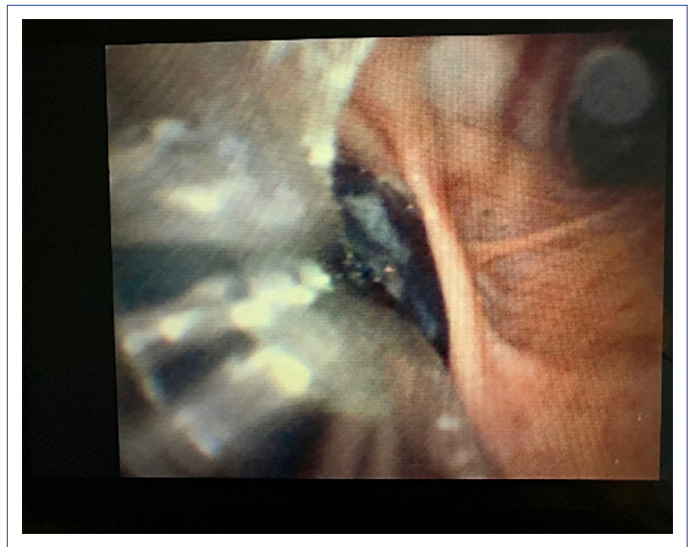


Figure 2. Simultaneous visualization of endobronchial intubation.

Disclosures

Informed Consent: Written informed consent was obtained from the patient for the publication of the case report and the accompanying images.

Authorship Contributions: Concept – H.Y.; Design – H.Y., B.Ö.; Supervision – H.Y., A.Ö.; Data collection &/or processing – H.Y., B.Ö., A.Y., M.S.; Analysis and/or interpretation – H.Y., B.Ö.; Literature search – H.Y., B.Ö., A.Y., M.S.; Writing – H.Y., B.Ö., A.Ö.; Critical review – H.Y., A.Ö.

Conflict of Interest: All authors declared no conflict of interest.

Use of AI for Writing Assistance: not used.

Financial Disclosure: The authors declared that this study has received no financial support.

Peer-review: Externally peer-reviewed.

References

1. Rapchuk IL, Kunju SAM, Smith IJ, Faulke DJ. A six-month evaluation of the VivaSight™ video double-lumen endotracheal tube after introduction into thoracic anaesthetic practice at a single institution. *Anaesth Intensive Care* 2017;45:189–95.
2. Heir JS, Purugganan R, Jackson TA, Norman PH, Cata JP, Kosturakis A, et al. A retrospective evaluation of the use of video-capable double-lumen endotracheal tubes in thoracic surgery. *J Cardiothorac Vasc Anesth* 2014;28:870–2.
3. Palaczynski P, Misiolek H, Bialka S, Owczarek AJ, Gola W, Szarpak Ł, et al. A randomized comparison between the VivaSight double-lumen tube and standard double-lumen tube intubation in thoracic surgery patients. *J Thorac Dis* 2022;14:3903–14.
4. Heir JS, Guo SL, Purugganan R, Jackson TA, Sekhon AK, Mirza K, et al. A randomized controlled study of the use of video double-lumen endobronchial tubes versus double-lumen endobronchial tubes in thoracic surgery. *J Cardiothorac Vasc Anesth* 2018;32:267–74.
5. Wang W, Gong Z, Zhao M, Zhang Z, Qiu Y, Jiang Q, et al. Hypoxemia in thoracoscopic lung resection surgery using a video double-lumen tube versus a conventional double-lumen tube: A propensity score-matched analysis. *Front Surg* 2023;10:1090233.
6. Onifade A, Lemon-Riggs D, Smith A, Pak T, Pruszynski J, Reznik S, et al. Comparing the rate of fiberoptic bronchoscopy use with a video double lumen tube versus a conventional double lumen tube—a randomized controlled trial. *J Thorac Dis* 2020;12:6533–41.