

Anesthesia for Tracheal Stenosis in a Heart Transplant Patient

Yücel Özgür

Kalp Transplantlı Hastada Trakeal Darlık İçin Anestezi Uygulaması

Finansal destek: Yoktur.
Hasta onamı: Hastadan onam alınmıştır.

Funding: None
Informed consent: Informed consent was obtained from the patient.

Cite as: Özgür Y. Anesthesia for tracheal stenosis in a heart transplant patient. GKDA Derg. 2020;26(1):39-44.

ABSTRACT

Tracheal stenosis after intubation is an important clinical condition. It has been estimated that it is observed in approximately 5%-20% of the patients with intubation and tracheostomy. In patients undergoing heart transplantation, tracheal stenosis may develop due to prolonged intubation in the pre-, and post-transplant period. In this study, anesthesia experience in the patient who had a history of intubation for 2 weeks before heart transplantation, and underwent tracheal resection and anastomosis due to the development of tracheal stenosis is presented.

Keywords: anesthesia, heart transplantation, tracheal stenosis surgery

Öz

Entübasyon sonrası trakeal stenoz önemli bir klinik durumdur. Entübe ve trakeostomize hastaların yaklaşık %5-%20'sinde görüldüğü tahmin edilmektedir. Kalp transplantasyonu uygulanan hastalarda nakil öncesi ve sonrası dönemde, uzun süre entübe kalmaya bağlı olarak trakeal stenoz gelişebilir. Bu çalışmada, kalp nakli öncesi 2 hafta süreyle entübe kalma öyküsü olan, trakeal darlık gelişmesi nedeniyle trakeal rezeksiyon ve anastomoz uygulanan hastada, anestezi deneyimi sunulmuştur.

Anahtar kelimeler: anestezi, kalp nakli, trakeal stenoz operasyonu

Received: 24 June 2019

Accepted: 27 November 2019

Publication date: 31 March 2020

Yücel Özgür

Yedikule Göğüs Hastalıkları ve Cerrahisi
Eğitim Araştırma Hastanesi
Anestezi ve Reanimasyon Kliniği
Zeytinburnu - Türkiye
✉ anstz@hotmail.com
ORCID: 0000-0003-2203-4802

INTRODUCTION

Since the first human heart transplantation (Ozinsky, 1967) its success as a treatment has been established for selected patients with end-stage heart failure. Non-cardiac surgical procedures are required for 15-30% of patients at various times after heart transplantation. Tracheal stenosis after intubation is an important clinical condition. In patients undergoing heart transplantation, tracheal stenosis may develop due to prolonged intubation in the pre-, and post-transplant period^[1]. In the literature, no cases of

tracheal stenosis followed by tracheal resection were found during the heart transplantation operation. This case report aims to review the anesthetic management of a heart transplant recipient undergoing a tracheal stenosis surgery.

CASE REPORT

A 32-year-old male patient who had undergone cardiac transplantation due to idiopathic dilated cardiomyopathy in 2017 had a history of intubation in intensive care unit for 2 weeks before transplanta-



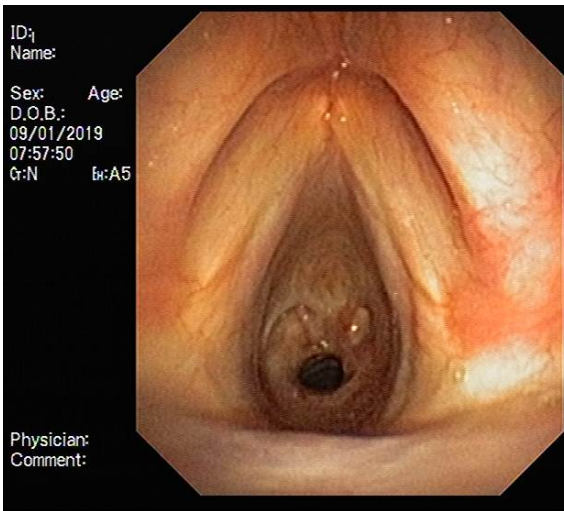


Figure 1. Trachea view of patient before operation.

tion. After transplantation, the patient was discharged with prescription of immunosuppressive treatment. After a short time shortness of breath developed. In the bronchoscopy, a complex type of 1 cm-long stenotic segment that involved approximately 1.5 cm distal part of the vocal cords and obliterated the trachea lumen by 95% was observed (Figure 1). The procedure was completed by providing an optimal opening of the trachea with a silicone stent during bronchoscopy. The patient was followed with tracheal stent for 1.5 years. Upon the renewal of the complaints, surgery was planned for stenosis by thoracic surgery. A written informed consent was obtained from the patient.

In the preoperative evaluation, the physical examination findings of the patient were within normal limits, and the patient were taking mycophenolate mofetil, tacrolimus, clopidogrel hydrogen sulphate, atorvastatin and everolimus drugs regularly. Cardiology department evaluated the patient preoperatively. Cardiac functions were normal, no signs of rejection and heart failure were observed. The electrocardiography (ECG) was unremarkable, the cardiothoracic ratio was normal on the chest X-ray, and the left ventricular wall movements were not pathologic, and ejection fraction (EF) was 55% in echocar-

Table 1. Hemodynamic parameters of the patient.

	HR (beat/min)	SAP (mmHg)	DAP (mmHg)	SpO ₂ %
Preop	80	135	90	97
End of ind	85	125	75	99
End of intub	96	137	88	99
30. min	75	110	66	100
1. h	76	115	70	99
2. h	78	117	72	98
3. h	80	125	75	99
4. h	82	130	76	98

diography. Pulmonary function test results were as follows: FEV1: 2.89, FVC: 3.64 FEV1/FVC: 79%. Preoperative blood biochemistry, hemogram, hemostasis panel and blood gas measurements of the patient did not yield any abnormal results.

The patient in the ASA III risk group who was informed about the procedure was taken to the operation room, ECG and noninvasive blood pressures were monitored. The patient was premedicated with midazolam (2 mg iv) to allay anxiety. Antibiotic prophylaxis (ceftriaxone disodium 1 g iv) was given 30 minutes prior to surgery. Prior to induction of anesthesia, 500 ml of isotonic iv was administered. For anesthesia induction, propofol (200 mg IV) fentanyl (100 mg IV) and rocuronium bromide (50 mg IV) were administered following 5 minutes of preoxygenation. After adequate muscle relaxation, intubation with endobronchial tube No. 5 was performed. Anesthesia was maintained with 50% O₂ / air, 1.5-2% sevoflurane and remifentanyl infusion. Then, catheterization from the right subclavian vein and cannulation from the right radial artery were performed. During the operation; heart rate, systolic and diastolic arterial pressures, central venous pressure (CVP), invasive blood pressure measurement, end-tidal CO₂, peripheral oxygen saturation, hourly urine output and bleeding (if any) were recorded. Arterial blood gas measurements were performed

every hour (Table 1). The first measured CVP value was 1 mmHg and intraoperative fluid requirement was maintained in order to attain the CVP value of 8-10 mmHg. Endobronchial tube was replaced by 6G spiral tube during tracheal resection. The surgery lasted for 5 hours. Then 1 g paracetamol, 6 mg morphine iv was administered. The patient was transported to surgical intensive care unit after extubation. In the intensive care unit, the cardiologist reassessed the patient, performed echocardiography, and did not observe any signs of heart failure.

DISCUSSION

Intraoperative and early postoperative period of patients undergoing heart transplantation poses a high risk for anesthesia [2]. Cardiac transplantation involves removing the diseased heart and leaving an atrial cuff. The aorta and the main pulmonary arteries are transected, the cardiac plexus is interrupted and the heart is denervated. At rest, the heart rate reflects the intrinsic rate of depolarization at the donor sino-atrial node and in the absence of any vagal tone heart rate is faster than normal at about 90-100 bpm. The transplanted heart responds to hypovolemia with an exaggerated drop in blood pressure due to loss of baroreceptor reflex. This is followed by an exaggerated hypertensive response to catecholema. The increase in cardiac output is dependent on venous return, with mediates an increase in stroke volume and ejection fraction by means of the Frank-Starling mechanism. That is why heart transplant patients are said to be "preload dependent". Rhythm disturbances and increased catecholema are observed in more than 50% of patients due to loss of vagal tone [3-5]. Effects of cardio-selective drugs are altered due to denervation. Drugs that show indirect effects by means of autonomic fibers (atropine, pancuronium) cannot reveal their classical effects after transplantation, whereas direct-acting agents (Isoproterenol, adrenaline, ephedrine) may have pharmacological effects on myocardium or stimuli conducting tissues of the heart [3]. Therefore, the titration of anesthetic agents

that may reduce systemic vascular resistance, adequate fluid loading before induction and invasive monitoring are recommended. In our case, no hemodynamic instability was observed during the operation. CVP values were kept between 8-10 mmHg. In such cases, due to preload-dependent graft, volume loss should be carefully monitored and normal or high preload volumes should be targeted.

In the literature, CVP and arterial cannulation is frequently used for non-cardiac surgery in patients with heart transplantation, whereas pulmonary artery catheter, Pulse Contour Cardiac Output (PiCCO) and Transesophageal Echocardiography (TEE) are not commonly used [3-6]. Direct arterial blood pressure monitoring can also show heart-lung interactions and patient's response to fluid resuscitation [7,8]. Choudhury et al. predict that invasive blood pressure measurement and transesophageal echocardiography may be necessary if major surgery is to be performed in patients after heart transplantation [9]. Since pulmonary artery catheter, echo-Doppler or transpulmonary thermodilution methods provide static data, guided fluid resuscitation is beneficial in a limited number of patients, and it is stated that it is aggravated by the fluid load it creates in nearly half of the intensive care patients [10]. In a study by Aybek et al. 28 patients who underwent cardiac transplantation had undergone anesthesia management, only 3 patients had cardiac output and intrathoracic fluid monitoring with the PiCCO device, but it was not used routinely because of the problem of supplying the device in the later period, and the authors emphasized that it had been applied in patients with severe risk of serious postoperative problems but it was not adopted as a standard practice [11]. Mullens stated that given the cost, potential complications, and the lack of demonstrable benefits in routine use, the incidence of hemodynamic assessment via pulmonary artery catheters has decreased substantially over the last decade [12]. The guideline of European Society of Anesthesiology published in 2014 does not recommend routine pulmonary and right heart catheterization as there is little evidence to demon-

strate the benefit of perioperative there is little evidence to demonstrate the benefit of perioperative survival ^[13]. Again according to the same guideline, there is no evidence that the cardiac risk is correctly stratified or the outcome is predicted correctly by hemodynamic monitoring with TEE. We did not choose this method to avoid complications such as arrhythmia, complete heart block, endobronchial hemorrhage, and valve injury that may occur due to pulmonary artery catheterization. There were technical shortcomings for TEE and PiCCO.

The choice of anesthesia method in non-cardiac surgery in heart transplant patients is determined by the patient and the surgical procedure to be performed. A variety of anesthetic techniques (local, regional, neuroleptic and general) have been used successfully in these patients ^[9]. In general anesthesia, for the prevention of preoperative anxiety dormicum; as hypnotic agents thiopental, propofol and etomidate, as analgesics fentanyl, and as muscle relaxants remifentanyl; atrocurium, rocuronium, vecuronium may be preferred; in the maintenance of anesthesia, sevoflurane, isoflurane and nitrogenprotioxide may be preferred ^[3,4,9]. Swami et al. reported arthroplasty surgery in a heart transplant patient. They preferred isoflurane, oxygen / nitrous oxide in the maintenance of propofol / fentanyl / midazolam / vecuronium in anesthesia induction ^[4]. Valerio et al performed anesthesia induction with fentanyl, propofol and succinylcholine after premedication with dormicum in the patient who was scheduled for inguinal hernia operation ^[6]. In our patient, dormicum was administered to prevent preoperative anxiety. There was tracheal stenosis and propofol was preferred as an anesthetic agent which strongly suppressed upper respiratory airway reflexes. Possible postoperative organ failure should be evaluated for postoperative pain management. Morphine and nonsteroidal anti-inflammatory drugs should be avoided because of the possibility of renal failure due to immunosuppressant use ^[5,6]. Furthermore, morphine can cause histamine release and consequent hypotension. Meperidine administration is

associated with decreased myocardial contractility and can cause significant decreases in blood pressure and significant decrease in cardiac output following its intravenous administration. In our patient, heart, liver and renal failure findings were not observed. However, high doses of tramadol may cause serotonin syndrome. Studies have shown that morphine is still the most preferred analgesic agent, especially in patients with heart failure ^[14,15].

Immunosuppressive drugs are used indefinitely in heart transplant patients and infection remains a major cause of death. Early postoperative, bacterial infections (e.g., mediastinitis) and opportunistic infections (e.g., CMV, pneumocystis carinii, toxoplasma and legionella) are most common. The leading cause of infection is direct contact with contaminated material. Thus, invasive monitoring techniques and all forms of instrumentation should be kept to the minimum consistent with safe anesthesia ^[5]. Appropriate perioperative antibiotic prophylaxis should be used. In our case, antibiotic prophylaxis was applied half an hour before the operation. To prevent postoperative sepsis, attention should be paid to maintain aseptical conditions, appropriate respiratory care, CVP / arterial line and early removal of urinary catheter.

Tracheal stenosis is associated with many etiologic factors such as surgery-related trauma, intubation, inhalation injury and inflammatory diseases. Nowadays, the most common cause is the prolonged intubation and tracheostomy. Cuffs of endotracheal or tracheostomy tubes lead to mucosal trauma by applying pressure to the airway. The probability of stenosis is higher than 11%, even if high-volume, and low-pressure is applied in endotracheal tubes and intubation time is shorter than 24 hours. Excessively inflated cuff (>30 mmHg) causes mucosal ischemia, chondritis, granulation tissue and consequently stenosis following development of scar tissue ^[16]. The reported incidence of tracheal stenosis following tracheostomy and laryngotracheal intubation ranges from 0.6% to 21% and 6% to 21%,

respectively ^[1]. The eventually resulting 100% stenosis, leads to full occlusion, according to the Meyer-Cotton classification ^[5]. Symptoms in more than 70% stenosis occur such as dyspnea with increasing respiratory stress accompanied by stridor and wheezing ^[17]. In our case, stent was applied twice at different times due to the stenosis of 95% detected in the first bronchoscopy examination. Stenosis should be considered when there are unsuccessful extubation stories of intubated patients or respiratory findings after extubation ^[17]. Grillo stated that the risk increased in patients intubated longer than 48 hours and that they had findings before 2 years ^[18]. Medical, endoscopic or surgical options are available for the treatment of tracheal stenosis. Treatments of stenosis after intubation are surgery and endoscopy; the chance of success increases to 95% ^[17]. Tracheal resection followed by end-to-end anastomosis is now a well-established technique performed under well-established indications ^[1]. In order to avoid tracheal stenosis, it is important that intubation time and tube cuff pressures are closely followed and repetitive intubations should be avoided in order to prevent tracheal damage in the operating room and intensive care conditions.

As a result, following heart transplantation, the patient will perhaps have an adequate cardiac function similar to this case report. However, due to the alterations in the physiology of the transplanted heart, major consequences related to the denervation of the heart can occur perioperatively. The anesthetics risk for post-transplantation morbidity in the denervated heart, rejection, infection, hypertension and renal dysfunction must be considered carefully for the optimal perioperative care of these patients.

REFERENCES

1. Sarper A, Ayten A, Eser I, Ozbudak O. Tracheal Stenosis After Tracheostomy or Intubation. *Tex Heart Inst J*, 2005;32:154-8.
2. Ergenoğlu MU, Ercan S, Yerebakan H. Perioperative Airway Management and Posttransplant Successful Tracheal Resection and Reconstruction in a Heart Transplant Candidate with Post-intubation Stenosis. *Thorac Cardiovasc Surg*, 2012 Jun; 60(4):295-8. <https://doi.org/10.1055/s-0030-1271014>
3. Karabeyoğlu et al. Anesthesia for Non-cardiac Surgery in a Heart Transplant Patient: Case Report. *Turkey Clinics J Anesth Reanim*. 2005;3:105-8.
4. Adarsh C Swami, Amit Kumar, Sunny Rupal, and Sneha Lata. Anesthesia for non-cardiac surgery in a cardiac transplant recipient. *Indian J Anesth*. 2011;55(4): 405-7. <https://doi.org/10.4103/0019-5049.84849>
5. Cheng DC, Ong DD. Anesthesia for non-cardiac surgery in heart-transplanted patients. *Can J Anesth*. 1993; 40/10:981-6. <https://doi.org/10.1007/BF03010103>
6. Valerio R Jr, Durra O, Gold M. Anesthetic consideration for an adult heart transplant recipient undergoing non-cardiac surgery: A Case Report. *AANA Journal*. 2014; Vol. 82, No.4.
7. Micherd F, Chemia D, Richard D, et al. Clinical use of respiratory changes in arterial pulse pressure to monitor to hemodynamic effects of PEEP. *Am J Respir Crit Care Med*. 1999;159:935-9. <https://doi.org/10.1164/ajrccm.159.3.9805077>
8. Micherd F, Boussat S et al. Relation between respiratory changes in arterial pulse pressure and fluid responsiveness in septic patients with acute circulatory failure. *Am J Respir Crit Care Med*. 2000;162:134-8. <https://doi.org/10.1164/ajrccm.162.1.9903035>
9. Choudhury M. Postcardiac transplant recipient: implications for anesthesia. *Indian journal of anesthesia*. 2019; Vol 61. Issue 9. https://doi.org/10.4103/ija.IJA_390_17
10. Pinsky MR. Assessment of indices of preload and volume responsiveness. *Curr Op Crit Care*. 2005-11:235-9. <https://doi.org/10.1097/01.ccx.0000158848.56107.b1>
11. Akbek E, Dönmez A, Camkiran A, Sarıtaş B. Our early experience with anesthetic management of heart transplantation patients. *Journal of Anesthesia*. 2009; 17(3):154-8.
12. Mullens W1, Borowski AG, Curtin RJ, Thomas JD, Tang WH. Tissue Doppler imaging in the estimation of intracardiac filling pressure in decompensated patients with advanced systolic heart failure. *Circulation* 2009;119(1):62-70. <https://doi.org/10.1161/CIRCULATIONAHA.108.779223>
13. 2014 European Cardiology Association / European Anesthesiology Association: Non-cardiac surgery guide: Cardiovascular Evaluation and Management. Pg 35-36.
14. Chen A, Ashburn MA. Ashburn M. Cardiac effects of opioid therapy. *Pain Medicine*. 2015;16:27-31. <https://doi.org/10.1111/pme.12915>
15. Demas K. Anesthesia for heart transplantation: A ret-

- rospective study and review. *Br J Anesth.* 1986;58:1357-64.
<https://doi.org/10.1093/bja/58.12.1357>
16. Melkane AE, Matar NE, Haddad AC, Nassar MN, Almoutran HG, Rohayem Z, et al. Management of postintubation tracheal stenosis: appropriate indications make outcome differences. *Respiration* 2010;79:395-401.
<https://doi.org/10.1159/000279225>
17. Gökçe Ş, Koç F, Aydın D, Akşit S. A case report: Acquired tracheal stenosis. *The journal of pediatric research* 2015;2(3):164-6.
<https://doi.org/10.4274/jpr.42713>
18. Grillo HC. Bening and malignant disease of the trachea. *General thoracic surgery*. 3rd ed Philadelphia PA; Lea & Febiger, 1989; 667-79.