

Single-Center Outcomes of Vacuum-Assisted Closure Therapy for Mediastinitis After Pediatric Cardiac Surgery

Murat Çiçek,¹ Mehmet Akif Önalın²

¹Division of Pediatric Cardiovascular Surgery, Department of Cardiovascular Surgery, University of Health Sciences, Dr. Siyami Ersek Thoracic and Cardiovascular Surgery Training and Research Hospital, İstanbul, Türkiye

²Division of Pediatric Cardiovascular Surgery, Department of Cardiovascular Surgery, University of Health Sciences, Basaksehir Cam ve Sakura City Hospital, İstanbul, Türkiye

ABSTRACT

Objectives: Vacuum-assisted closure therapy is useful in treating mediastinitis, which is related to high mortality and morbidity rates after cardiac surgery. This study aimed to present our experience with vacuum-assisted closure therapy in mediastinitis after pediatric cardiac surgery.

Methods: This retrospective review included 10 patients who underwent vacuum-assisted closure therapy for mediastinitis in a single institution from 2020 to 2022. Patients with wound discharge or abscess, sternal dehiscence, fever, and positive wound culture were considered to have mediastinitis. The vacuum sponge was cut at the appropriate size for the mediastinal defect and the skin edges were approximated with prolene sutures. The vacuuming continuously started at -50 mm Hg.

Results: Six (60%) patients were female and the median age during therapy was 1.9 months (range: 0.1–54 months). Five (50%) patients were neonates. The median duration of vacuum-assisted closure therapy was 14.5 days (range: 4–78). The median duration to obtain negative mediastinal culture was 14.5 days (range: 6–76). The sternum could be closed without difficulty in all patients except one who died due to low cardiac output. Hospital mortality occurred in 3 (30%) patients who needed extracorporeal membrane oxygenation support postoperatively. The median duration of follow-up was 10 months (range: 2–28).

Conclusion: Mediastinitis is an important problem associated with high morbidity and mortality rates after pediatric cardiac surgery. Data suggest that vacuum-assisted closure therapy can safely treat mediastinal infections without recurrence.

Keywords: Congenital heart disease, mediastinitis, pediatric cardiac surgery, vacuum-assisted closure

Please cite this article as: "Çiçek M, Önalın MA. Single-Center Outcomes of Vacuum-Assisted Closure Therapy for Mediastinitis After Pediatric Cardiac Surgery. GKDA Derg 2023;29(1):33-38".

Introduction

The treatment for deep sternal wound infection and mediastinitis after pediatric cardiac surgery remained associated with a high risk of morbidity and mortality rates.^[1,2] Median sternotomy is the usual approach in pediatric cardiac surgery, and mediastinitis after sternotomy affects approximately 1% of children.^[3,4] Additionally, the incidence of mediastinitis seems higher, especially in neonate patients.^[5] Open chest and delayed sternal closure techniques have a high risk of mediastinal infections.^[6]

Mediastinitis provokes several problems, including prolonged hospital stay, prolonged antibiotic use, and increased healthcare costs.^[6] Surgical debridement, drainage and irrigation, antibiotic therapy, and direct or secondary closure with a pectoral muscle flap are the recommended treatment techniques for treating deep sternal wound infections.^[7,8] However, the best treatment option still has no consensus.

A subatmospheric pressure with vacuum-assisted closure (VAC) system in chronic wound care was first used in 1997.^[9] The VAC system advances wound healing by extract-

Address for correspondence: Murat Çiçek, MD. Sağlık Bilimleri Üniversitesi, Dr. Siyami Ersek Göğüs Kalp ve Damar Cerrahisi Eğitim ve Araştırma Hastanesi, Kalp Damar Cerrahisi Anabilim Dalı, Çocuk Kalp Cerrahisi Bilim Dalı, İstanbul, Türkiye

Phone: +90 505 813 40 76 **E-mail:** drmcicek@gmail.com

Submitted: January 08, 2023 **Revised:** January 08, 2023 **Accepted:** January 12, 2023 **Available Online:** March 29, 2023

The Cardiovascular Thoracic Anaesthesia and Intensive Care - Available online at www.gkdaybd.org

OPEN ACCESS This is an open access article under the CC BY-NC license (<http://creativecommons.org/licenses/by-nc/4.0/>).



ing localized edema, develops vascular circulation, and improves granular tissue formation.^[10,11] This report aims to present our experience of managing children with VAC therapy after cardiac surgery.

Methods

This study retrospectively reviewed the medical records of 10 consecutive patients who underwent VAC therapy for mediastinitis after congenital cardiac surgery from January 2020 to January 2022. Patients with wound discharge or abscess, sternal dehiscence, fever, and positive wound culture were considered to have mediastinitis. The suspected patients were diagnosed using computed tomography. Patients who had wound infections without mediastinitis were excluded from the study. Data were retrospectively collected from the patient's previous hospital records. Our study (numbered E-28001928-604.01.01-330) was approved by the institution on November 29, 2022, and was conducted following the principles of the Declaration of Helsinki.

Collected data included patient demographic characteristics, preoperative cardiac pathology diagnosis, type of operations, and use of extracorporeal membrane oxygenation (ECMO) support, as shown in Table 1. Additionally, the type of microorganisms, the antibiotics used, the presence of delayed sternal closure, the number of VAC changes, and the duration are shown in Table 2.

Surgical Technique

Antibiotic treatment was started in all patients according to antibiograms before VAC treatment. Mediastinal or deep wound culture samples were obtained from all patients before starting the VAC application. The VAC sponge was cut at the appropriate size and depth for the wound geometry and placed in the mediastinal defect after careful hemostasis. Prolene sutures were used to approximate the skin edges to prevent the VAC sponge from overflowing and eroding the skin. The sponge was covered with a transparent adherent drape, and the VAC system was attached to it by making a hole in the drape. This drape was cut as small as possible so that it would not erode the healthy skin. The VAC system began to continuously vacuum the wound at -50 mm Hg. The VAC sponge was changed every 72/96 h. Two culture samples were taken from the mediastinum at each system change. A smaller sponge was inserted as the wound got smaller at each VAC change (Fig. 1). The VAC system was terminated and the chest cavity was closed when wound healing was observed and the culture was negative.

Statistical Analysis

Continuous variables were reported as median±range. Categorical variables were reported as n(%). IBM Statistical Package for the Social Sciences Statistics Software version 21 (SPSS Inc., Chicago, IL, USA) was used for statistical analyses.

Table 1. Demographic characteristics and operative data of patients

Patient	Age (month)	Weight (kg)	Sex	Preoperative diagnosis	Previous operation	Last operation	Postop events
1	3	3.5	M	TGA	ASO	Supralvalvar AS repair	ECMO
2	54	15	M	IAA+VSD+RV hypoplasia	Bilateral PA banding, Comprehensive stage 2 operation	SVC Graft inter-position for SVC occlusion	
3	3	6	F	Pulmonary artery sling	Pulmonary artery sling repair	Tracheoplasty	ECMO
4	14	7.5	M	TGA+VSD+PS	MBT shunt	Rastelli operation	ECMO
5	0.8	2.7	M	Supracardiac TAPVD	Supracardiac TAPVD repair	Right PV reanastomosis	
6	0.2	2.8	F	HLHS		Norwood procedure	
7	60	12.5	F	TOF	MBT shunt	TOF repair	Revision for bleeding
8	0.1	3.1	F	Arcus hypoplasia+VSD	Arcus reconstruction+PAB	Supralvalvar AS repair	ECMO
9	0.2	3.4	F	IAA+VSD		Arcus reconstruction+PAB	Revision for bleeding
10	0.2	3	F	Arcus hypoplasia+VSD		Arcus reconstruction+PAB	ECMO (twice)

AS: aortic stenosis; ASO: arterial switch operation; ECMO: extracorporeal membrane oxygenation; HLHS: hypoplastic left heart syndrome; MBT: modified Blalock-Taussig; PA: pulmonary artery; PAB: pulmonary artery banding; PS: pulmonary stenosis; RV: right ventricle; TAPVD: total anomalous pulmonary venous drainage; TGA: transposition of great arteries; TOF: tetralogy of Fallot; VSD: ventricular septal defect.

Table 2. Microbiological data of patients

Microorganism	Antibiotics	Delayed sternal closure	Number of VAC changes	Time VAC (day)
Acinetobacter baumannii, Klebsiella oxytoca	Colimycin, piperasilin/ tazobactam	yes	26	78
Klebsiella pneumonia	Colimycin, meropenem, vancomycin	yes	8	35
Escheria coli	Linezolid, meropenem	yes	5	15
Klebsiella pneumonia	Colimycin, meropenem	yes	3	8
Candida albicans	Anidulafungin, meropenem	yes	5	14
Klebsiella pneumonia	Ertapenem, vancomycin, meropenem	yes	3	8
Staphylococcus epidermid-is	Vancomycin, amikacin	yes	2	4
Enterobacter aerogenes	Ciprofloxacin, vancomycin, meropenem	yes	2	6
Serratia marcescens, Klebsiella pneumonia	Fluconazole, colimycin, meropenem, vancomycin	yes	17	51
Sterile	Vancomycin, meropenem	yes	12	35

VAC: vacuum-assisted closure.

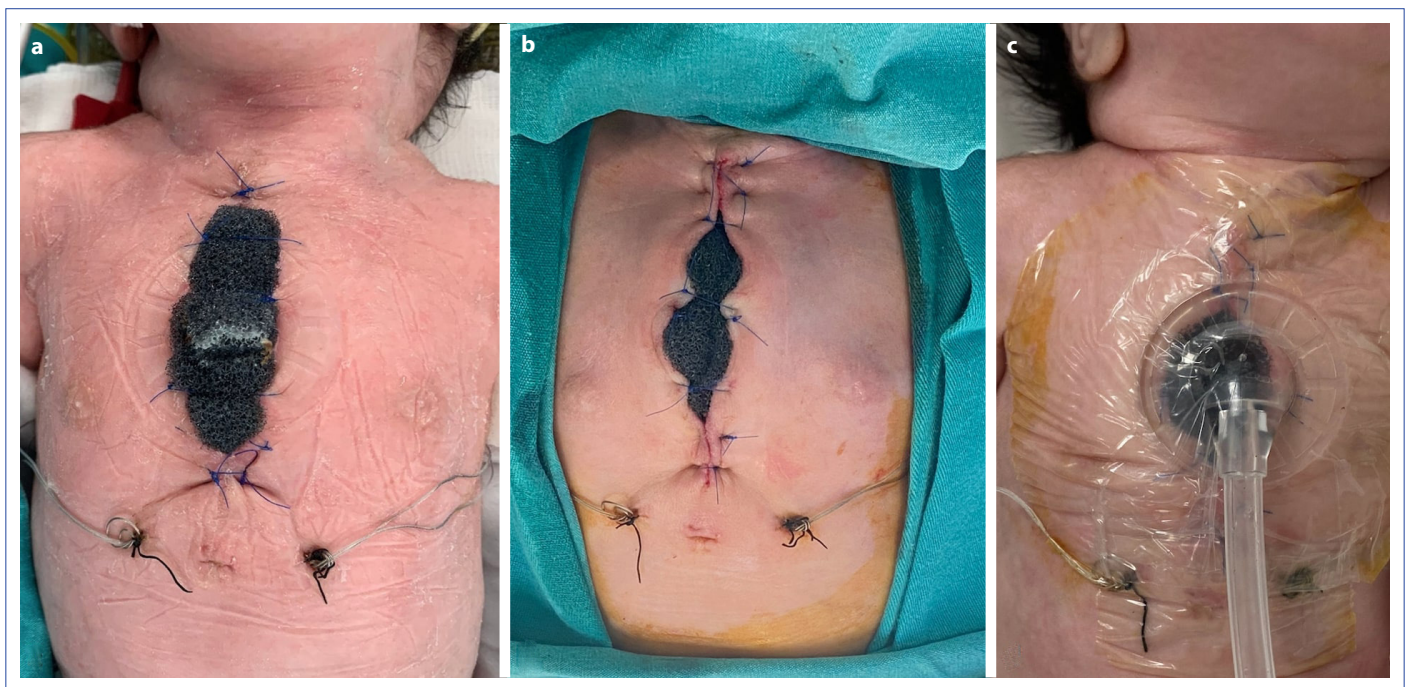


Figure 1. The image shows the placement of the VAC sponge with prolene sutures (a). The images show the inserted smaller sponge at each VAC exchange as the wound granulation is present (b, c).

Results

During our study, 10 patients, including 6 females and 4 males, with mediastinitis after pediatric cardiac surgery were treated with VAC therapy. The median age of the patients was 1.9 months (range: 0.1–54 months) and the median weight was 3.45 kg (range: 3–15 kg). Of the patients, five were neonates, three were infants, and two were children.

The primary diagnosis included interrupted aortic arch (IAA) and ventricular septal defect (VSD) in two patients, aortic arch hypoplasia and VSD in two patients, hypoplastic left heart syndrome (HLHS) in one patient, transposition of

the great arteries (TGA) in one patient, supracardiac total anomalous pulmonary venous drainage (TAPVD) in one patient, TGA, VSD, and pulmonary stenosis (PS) in one patient, pulmonary artery sling in one patient, and tetralogy of the Fallot (TOF) in one patient. Functional biventricle and single ventricle were observed in 8 and 2 patients, respectively.

Seven (70%) patients were not operated on for the first time, and cardiac surgery was performed after redo sternotomy. It was the second operation of six patients, while the fourth operation of one. The sternum was left open in the early postoperative period due to myocardial dysfunction or edema in 9 (90%) patients. Central veno-arte-

rial ECMO support after cardiac surgery was required in 5 (50%) patients, and one of them needed ECMO twice. The median ECMO support duration was 6 days (range: 2–12 days). Surgical revision was required in two patients due to bleeding.

VAC therapy was applied after a median of 10 days (range: 1–27 days) from the cardiac surgery. The median VAC therapy duration was 14.5 days (range: 4–78), and the median change of VAC therapy was five times (range: 2–26). *Klebsiella pneumonia* (n=3), *Acinetobacter baumannii* (n=1), *Escherichia coli* (n=1), *Candida albicans* (n=1), *Staphylococcus epidermidis* (n=1), *Enterobacter aerogenes* (n=1), and *Serratia marcescens* (n=1) were obtained from the mediastinum cultures. Only one patient had sterile culture despite the wound abscess and the sternal dehiscence. Antibiotic treatments were changed by the infectious diseases specialist following the culture antibiogram. The median duration to obtain negative mediastinal culture was 14.5 days (range: 6–76). The sternum could be closed without difficulty in all patients except one after VAC treatment, and no revision was required. The sternum could not be closed due to significant myocardial edema in this patient, who died due to sepsis.

Hospital mortality occurred in 3 (30%) patients. One of them, who underwent a Rastelli procedure for TGA-VSD-PS, required ECMO support caused by low cardiac output syndrome (LCOS). This patient had *Klebsiella pneumonia* mediastinitis and died due to sepsis despite the VAC therapy on postoperative day 30. This patient was the only patient whose sternum could not be closed after the VAC therapy. Another patient, who underwent aortic arch reconstruction and pulmonary banding operations for aortic arch hypoplasia and VSD, required a second operation due to supra-valvar aortic stenosis. This patient needed ECMO support after the second operation and died due to multiorgan failure on postoperative day 125. The last patient, who underwent aortic arch reconstruction and pulmonary banding operations for aortic arch hypoplasia and large VSD, underwent extracorporeal cardiopulmonary resuscitation due to sudden cardiac arrest. This patient required ECMO again caused by low cardiac output despite weaning from ECMO. This patient died because of septic shock on postoperative day 77. The median duration of intensive care unit (ICU) and hospital stay postoperatively were 96 days (range: 30–510) and 98.5 days (range: 10–510), respectively.

The median duration of follow-up was 10 months (range: 2–28) in the surviving patients.

One patient died after hospital discharge and the other one died after being transferred to another ICU, thus the overall mortality occurred in 5 (50%) patients. The first pa-

tient underwent a total repair operation for TOF and died after 5 months from hospital discharge due to right heart failure and LCOS at another center. The second patient underwent pulmonary sling repair and tracheoplasty operations (twice) and was transferred to the general pediatric ICU after 510 days of cardiac ICU hospitalization and died due to respiratory distress and sepsis although tracheal patency was demonstrated in bronchoscopy controls. This patient and three patients who died in the early postoperative period needed ECMO support in the postoperative period.

Discussion

Herein, we present our experience with 10 patients with mediastinitis treated with VAC. Our management in patients who develop mediastinitis after cardiac surgery mainly aimed to obtain a wound or mediastinal culture, extend antibiotherapy, and start mediastinal VAC treatment. Their antibiotic therapies were changed after the consultation with the infectious diseases specialist according to the culture results.

Mediastinitis and sternal wound problems may develop after pediatric cardiac surgery especially in low-weight neonates due to biochemical and nutritional imbalances, long cardiopulmonary bypass times, myocardial edema, low cardiac output syndromes, and central ECMO application.^[2,12] Additionally, the age and weight of patients and re-exploration for postoperative bleeding are important in the course of infection.^[6,13] The risk of mediastinitis increases with these factors.^[13] The VAC system guards the mediastinum or wound against contamination and supports blood circulation and tissue granulation. Moreover, VAC therapy reduces bacterial cell count and intercepts tissue fluid retention.^[14] This technology has been used in the last two decades for wound closure in children and neonates with sternal problems after cardiac surgery.^[4,15] Herein, we used the VAC system in neonates, infants, and children to achieve sternal closure in mediastinitis.

Diagnostic criteria for mediastinitis differ from institution to institution and among clinicians.^[16] Wound microbiological cultures demonstrate a wide variety of organisms such as *Klebsiella pneumonia*, *Escherichia coli*, *Acinetobacter baumannii*, *Serratia marcescens*, *Staphylococcus aureus*, *Staphylococcus epidermidis*, *coagulase-negative Staphylococcus*, *enterococcus species*, *Pseudomonas aeruginosa*, *Proteus vulgaris*, and *Corynebacterium*.^[16] Most of these microorganisms in our study were acquired from wound cultures, except for one patient. Additionally, VAC treatment was applied in this patient because of sternal dehiscence and abscess.

Surgical debridement, drainage and irrigation, and direct or secondary closure with a pec-toral muscle flap are the traditional surgical treatment strategies for mediastinitis.^[6] We did not prefer any of these methods, especially because they are ineffective in neonates.^[6] Half of our patients were neonates and the results of VAC therapy, especially in neonates, have been very successful in the literature.^[6,12] We think that approximating the wound edges with prolene sutures, small dressings, and smaller sponges as the granulation in-creases are important in terms of VAC time shortening and wound healing acceleration. The sternum and wound site of all patients were closed except for one, and they did not need a muscle flap, and with no wound problems in their follow-up.

Empirical antibiotic therapy given preoperatively for prophylaxis is an effective way of dealing with postsurgical wound infections. However, empirical treatments cannot isolate every microorganism, especially resistant strains.^[6] Children undergoing complex cardiac surgery are often given many antibiotics in the postoperative course and are at increased risk of infection by resistant and fungal pathogens. Our study indicated the effectiveness of our mediastinitis treatment strategy with the VAC system against fungal and resistant microorganisms.

The most important detail of using VAC is adjusting the pressures. High negative pressure in the mediastinum can be a risk for direct cardiac structure or conduit compression and may decrease cardiac output, particularly in cases of severe mediastinitis and or cardiac dysfunction.^[17,18] Thus, we prefer to use lower negative pressure (–50 mm Hg) in our study. VAC treatment can be performed with higher pressures in case of sternal closure because there will be no direct contact with cardiac structures. Filipelli et al.^[12] conducted a study on six neonates who underwent VAC therapy for mediastinitis after cardiac surgery. They preferred high negative pressure (–125 mm Hg) because they applied a VAC system on the closed sternum. Conversely, some studies reported that low pressures re-cover the mediastinum, sternum, and wound as efficiently as high negative pressures without complications such as insufficient drainage or tissue damage.^[3,19]

Literature reported various mortality rates after VAC therapy. Filippelli et al.^[12] reported zero early mortality rate in six patients, Onan et al.^[6] reported a 14% early mortality rate in 14 patients, and Aydin et al.^[13] reported a 22% early mortality rate in nine patients.^[6,12,13] We believe that mortality in this patient group is especially associated with primary cardiac pathology or cardiac functions. The early mortality rate was 30% in 10 patients in our study. All of these patients needed ECMO support during the postoper-

ative period and were weaned from ECMO. One of our two patients who died during the follow-up period underwent ECMO support in the postoperative period. Thus, patients who needed ECMO support in the postoperative period accounted for 80% of our total mortality.

Hemodynamic parameters should be cautiously monitored in patients undergoing sternal VAC therapy.^[17,18] Petzina et al.^[17] reported that negative pressure on the chest decreases left ventricular end-diastolic volume, stroke volume, and so cardiac output. They suggested that VAC compression damages the diastolic filling of the ventricles.^[17] More negative effects of this negative pressure can be seen, especially in operations, such as Rastelli and Fontan, where conduits are used.^[20] Our study revealed no adverse hemodynamic effects of VAC treatment. However, the only patient whose chest could not be closed after VAC treatment was our patient who underwent a Rastelli operation. Therefore, more attention should be paid to hemodynamic parameters, especially in patients using conduits.

The major limitations of this study are the single-center, limited-patient, and retrospective design. Studies with multiple centers, more patients, and long-term outcomes are needed to demonstrate the VAC therapy outcomes.

In conclusion, mediastinitis is a rare but serious problem with increased mortality and morbidity rates after pediatric cardiac surgery. The VAC system is a confident treatment for mediastinitis and sternal wound problems after pediatric cardiac surgery. It provides high-quality and rapid healing of surgical wounds and can be safely applied in the treatment of mediastinitis after cardiac surgery.

Disclosures

Ethics Committee Approval: The study was approved by The institutional Ethics Committee (Date: 29.11.2022, No: E-28001928-604.01.01).

Informed Consent: Written informed consent was obtained from all patients.

Peer-review: Externally peer-reviewed.

Conflict of Interest: None declared.

Financial Disclosure: The authors declared that this study has received no financial support.

Authorship Contributions: Concept – M.Ç., M.A.Ö.; Design – M.Ç., M.A.Ö.; Supervision – M.Ç.; Materials – M.A.Ö.; Data collection&/or processing – M.A.Ö.; Analysis and/or interpretation – M.Ç.; Literature search – M.A.Ö.; Writing – M.A.Ö.; Critical review – M.Ç.

References

- Gummert JF, Barten MJ, Hans C, Kluge M, Doll N, Walther T, et al. Mediastinitis and cardiac surgery--an updated risk factor analysis in 10,373 consecutive adult patients. *Thorac Cardiovasc Surg*

- 2002;50:87–91.
2. Salazard B, Niddam J, Ghez O, Metras D, Magalon G. Vacuum-assisted closure in the treatment of poststernotomy mediastinitis in the paediatric patient. *J Plast Reconstr Aesthet Surg* 2008;61:302–5.
 3. Kadohama T, Akasaka N, Nagamine A, Nakanishi K, Kiyokawa K, Goh K, et al. Vacuum-assisted closure for pediatric post-sternotomy mediastinitis: Are low negative pressures sufficient? *Ann Thorac Surg* 2008;85:1094–6.
 4. Fleck T, Simon P, Burda G, Wolner E, Wollenek G. Vacuum assisted closure therapy for the treatment of sternal wound infections in neonates and small infants. *Interact Cardiovasc Thorac Surg* 2006;5:285–8.
 5. Erez E, Katz M, Sharoni E, Katz Y, Leviav A, Vidne BA, et al. Pectoralis major muscle flap for deep sternal wound infection in neonates. *Ann Thorac Surg* 2000;69:572–7.
 6. Onan IS, Yildiz O, Tüzün B, Timur B, Haydin S. Vacuum-assisted closure for mediastinitis in pediatric cardiac surgery: A single-center experience. *Artif Organs* 2019;43:119–24.
 7. Ohye RG, Maniker RB, Graves HL, Devaney EJ, Bove EL. Primary closure for postoperative mediastinitis in children. *J Thorac Cardiovasc Surg* 2004;128:480–6.
 8. Brandt C, Alvarez JM. First-line treatment of deep sternal infection by a plastic surgical approach: Superior results compared with conventional cardiac surgical orthodoxy. *Plast Reconstr Surg* 2002;109:2231–7.
 9. Morykwas MJ, Argenta LC, Shelton-Brown EI, McGuirt W. Vacuum-assisted closure: A new method for wound control and treatment: Animal studies and basic foundation. *Ann Plast Surg* 1997;38:553–62.
 10. Huddleston CB. Mediastinal wound infections following pediatric cardiac surgery. *Semin Thorac Cardiovasc Surg* 2004;16:108–12.
 11. Fuchs U, Zittermann A, Stuetzgen B, Groening A, Minami K, Koerfer R. Clinical outcome of patients with deep sternal wound infection managed by vacuum-assisted closure compared to conventional therapy with open packing: A retro-spective analysis. *Ann Thorac Surg* 2005;79:526–31.
 12. Filippelli S, Perri G, Brancaccio G, Iodice FG, Albanese SB, Trimarchi E, et al. Vacuum-assisted closure system in newborns after cardiac surgery. *J Card Surg* 2015;30:190–3.
 13. Aydın S, Temur B, Suzan D, Kirat B, Demir IH, Ozen M, et al. Mediastinal vacuum-assisted therapy following pediatric congenital cardiac surgery. *Turk J Thorac Cardiovasc Surg* 2017; 25:174–9.
 14. Obdeijn MC, de Lange MY, Lichtendahl DH, de Boer WJ. Vacuum-assisted closure in the treatment of poststernotomy mediastinitis. *Ann Thorac Surg* 1999;68:2358–60.
 15. Oeltjen JC, Panos AL, Salerno TA, Ricci M. Complete vacuum-assisted sternal closure following neonatal cardiac surgery. *J Card Surg* 2009;24:748–50.
 16. Costello JP, Amling JK, Emerson DA, Peer SM, Afflu DK, Zurkowski D, et al. Negative pressure wound therapy for sternal wound infections following congenital heart surgery. *J Wound Care* 2014;23:31–6.
 17. Petzina R, Ugander M, Gustafsson L, Engblom H, Sjögren J, Hetzer R, et al. Hemodynamic effects of vacuum-assisted closure therapy in cardiac surgery: Assessment using magnetic resonance imaging. *J Thorac Cardiovasc Surg* 2007;133:1154–62.
 18. Steigelman MB, Norbury KC, Kilpadi DV, McNeil JD. Cardiopulmonary effects of continuous negative pressure wound therapy in swine. *Ann Thorac Surg* 2009;88:1277–83.
 19. Mokhtari A, Petzina R, Gustafsson L, Sjögren J, Malmjö M, Ingemansson R. Sternal stability at different negative pressures during vacuum-assisted closure therapy. *Ann Thorac Surg* 2006;82:1063–7.
 20. Ugaki S, Kasahara S, Arai S, Takagaki M, Sano S. Combination of continuous irrigation and vacuum-assisted closure is effective for mediastinitis after cardiac surgery in small children. *Interact Cardiovasc Thorac Surg* 2010;11:247–51.