

Olgu Sunumu

A Rare Cause of Acute Respiratory Distress Syndrome: Chylothorax

Beliz BİLGİLİ*, Fethi GÜL*, İsmail CİNEL*

ABSTRACT

Chylothorax is the disruption or obstruction of thoracic duct as a result of trauma or neoplasms. It is a rare cause of pleural effusion characterized by high triglyceride and low cholesterol concentrations. Chylothorax-related acute respiratory distress syndrome is an uncommon condition. Herein, we report and discuss a patient who developed acute respiratory distress syndrome (ARDS) due to high flow chylothorax, which was treated by protective mechanical ventilation strategies, prolonged prone position and thoracic duct ligation.

Keywords: chylothorax, prone position, acute respiratory distress syndrome

ÖZ

Akut Sıkıntılı Solunum Sendromunun Ender Nedeni: Şilotoraks

Şilotoraks, ductus torasikusun travma veya altta yatan kansere bağlı olarak kesilmesi veya tıkanması sonucu meydana gelmektedir. Yüksek trigliserid ve düşük kolestrol ile karakterize plevral efüzyonun ender nedenidir. Şilotoraks ilişkili akut sıkıntılı solunum sendromu (Acute Respiratory Distress Syndrome; ARDS) ender görülen bir durumdur. Olgu sunumunda, koruyucu mekanik ventilasyon stratejileri, uzun süreli pron pozisyon ve ductus torasikus ligasyonu ile tedavi edilen, yüksek akım şilotoraksa bağlı gelişen ARDS hastası aktarılmıştır.

Anahtar kelimeler: şilotoraks, pron pozisyon, akut sıkıntılı solunum sendromu

INTRODUCTION

Chylothorax is the disruption or obstruction of thoracic duct as a result of trauma or neoplasms. It is a rare cause of pleural effusion characterized by high triglyceride and low cholesterol concentrations [1]. Treatment options of chylothorax include conservative (parenteral nutrition or a special diet including medium-chain triglycerides, thoracentesis, somatostatin), surgical (thoracic duct ligation, pleurodesis, pleurotomy), irradiation and interventional radiological techniques (lymphography, TIPS) [2]. Chylothorax-related acute respiratory failure is a rare condition [3,4].

Chylothorax leads to high morbidity and mortality as a result of respiratory distress, and also immunodeficiency, which is caused by loss of lymphocytes, proteins and immunoglobulins [5]. Early diagnosis and appropriate treatment are essential [6]. Herein, we report and discuss a case related to chylothorax.

CASE REPORT

A 17-year-old male was admitted to the emergency department with the complaint of shortness of breath. He had no fever, chest pain, cough or night sweats. The patient's resting pulse rate and blood pressures were 102/min and 100/50 mmHg respectively. There was an absence of breath sounds throughout his left hemithorax. There was no palpable enlargement of liver or spleen. All other systems were unremarkable. The history of the patient reflected that he had suffered from tuberculosis at the age of 5 and exposed to a trauma six months ago. His chest X-ray revealed left pleural effusion. After the insertion of

Alındığı tarih: 29.09.2015

Kabul tarihi: 01.12.2015

*Marmara Üniversitesi Pendik Eğitim ve Araştırma Hastanesi, Anesteziyoloji ve Reanimasyon Anabilim Dalı

Yazışma adresi: Yard. Doç. Dr. Beliz Bilgili, Marmara Üniversitesi Pendik Eğitim ve Araştırma Hastanesi, Anesteziyoloji ve Reanimasyon Anabilim Dalı, Fevzi Çakmak Mah. Muhsin Yazıcıoğlu Cad. No: 10 Üst Kaynarca / Pendik 34899 İstanbul
e-mail: belizbilgili@gmail.com

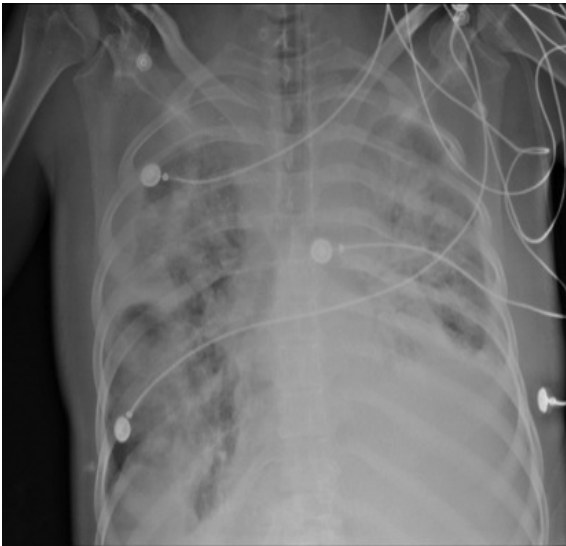


Figure 1. Posteroanterior chest radiograph on hospital day 20. Widespread infiltration present in both lungs.

a chest tube, his dyspnea diminished. Pleural fluid aspirate showed a milky white fluid and the microscopic examination of the fluid reported the presence of triglyceride. It was negative for bacteria, and the cytological examination was also negative for malignant cells. Biochemical analysis of the fluid revealed triglyceride content of 526 mg/dL and cholesterol of 12.1 mg/dL. All these findings confirmed the diagnosis chylothorax. Total parenteral nutrition with medium-chain triglycerides was initialized before the surgical therapy as a conservative treatment after which the ongoing abundant chylous drainage still continued. He underwent sequential unsuccessful bilateral thoracotomies in an attempt for en bloc ligation of the thoracic duct. Radiotherapy was applied on his chest as a final attempt to obliterate thoracic duct. Despite these attempts, he still had a high output chylothorax and was referred to our hospital for further treatment. On the 20th day of his hospitalization, he developed high fever (38.8°C) and severe dyspnea. At his admission to the intensive care unit, his blood pressure (100/60 mmHg), heart rate (144 bpm, respiratory rate (40/min) and peripheral oxygen saturation in room air (85%) were measured. He was intubated and mechanically ventilated by P-SIMV mode (PEEP: 14 cmH₂O, Pcontrol: 16 cmH₂O, respiratory rate 16 / min, fiO₂: 80%). Thirty minutes after the intubation, the arterial blood gas values of the patient showed deep respiratory acidosis (pH: 7.09 PO₂: 71 PCO₂:

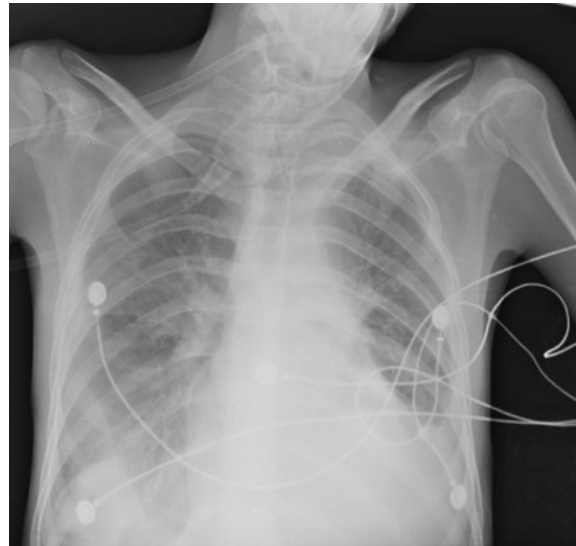


Figure 2. Posteroanterior chest radiograph following removal of the chest tube on hospital day 25.

119, HCO₃: 35.3, mEq/L sPO₂: 85%, lactate: 0.7U/L, BE: 2.5). Chest radiogram showed bilateral infiltration. The patient was diagnosed with severe acute respiratory distress syndrome (ARDS) related to chylothorax and nosocomial pneumonia. Empirical antibiotic therapy was initiated (meropenem, teicoplanin, colimycin) after the obtainment of the blood, urine, tracheal aspirate and pleural fluid cultures. Recruitment maneuver was applied, and mechanical ventilation settings were adjusted according to the results of the arterial blood gas analyses. Since the patient remained hypoxemic and hypercarbic after the recruitment maneuvers, he was positioned prone for 16 hours. Arterial blood gas analyses are shown in Table 1. On the 21st day of his hospitalization, due to high-volume chylothorax (> 1.5 L/day) mass ligation of the thoracic duct just above the cisterna chyli was performed through an upper midline laparotomy incision. After the operation, bilateral lung infiltration declined as observed on patient's chest X-ray (Figure 2), and arterial blood gas values were normalized. Chylous drainage from his chest tube diminished. Empirical antibiotic therapy was terminated on the fifth day; since the blood, urine, tracheal aspirate and pleural fluid cultures returned negative. On his 26th day of hospitalization sedation was stopped, the patient was extubated and discharged from the intensive care unit on the 28th day of his admission.

Table 1. Arterial blood gases analysis.

Arterial blood gases	Admission (Before prone position)	30min after prone position	4h after prone position	8h after prone position	12h after prone position	16h after prone position
Ph	7.098	7.309	7.267	7.30	7.348	7.528
PCO ₂	119	67.4	78.8	71.5	67.6	41.6
PO ₂	71.9	73.9	107	95.7	91.5	93.5
HCO ₃	35.3	32.8	34.8	34.5	36.2	34.5
Lactate (mmol/L)	0.7	0.8	0.8	1.1	1.2	1.7
BE	2.5	5.7	8	8.3	10.3	10.8
Spo2	85.4	93.6	96.8	96.8	99.7	98

DISCUSSION

Chylothorax is a rare disease caused by neoplasm, trauma (surgical or nonsurgical) or congenital factors [7,8]. Etiology of chylothorax should be ascertained since the initial approach is to treat the underlying condition. Clinical and radiological studies are inadequate for the diagnosis of chylothorax. Although a triglyceride concentration of >110 mg/dL is almost diagnostic; the definitive diagnosis is based on the presence of chylomicrons in the pleural fluid.

Chylothorax is treated by conventional (a fat-free diet with medium-chain triglycerides, radiotherapy, percutaneous ductus thoracicus embolization) and surgical methods (chest tube drainage, chemical pleurodesis, ductal ligation). The first line of therapy should be the drainage of the fluid in the pleural space by chest tube. Surgical ductal ligation is essential and indicative if chylothorax persists more than four weeks [9-11]. Secondary infection can develop in chylothorax due to the loss of fluid that contains protein, fat and lymphocytes [12]. Total parenteral nutrition, central venous catheterization, multiple chest tube insertions and surgical procedures are risks for morbidity.

Experimental and clinical studies have shown a positive relationship between the application of high positive end-expiratory pressure (PEEP) ventilation and decreasing lymphatic flow in the case of chylothorax [13,14]. Usage of mechanical ventilation with high PEEP decreases the accumulation of lymphatics in the central venous pool by increasing the lymph flow through the thoracic duct. Mechanical ventilation and high PEEP approximate visceral pleura to parietal pleura [15]. In the early phase of ARDS with a diffuse pattern and severe hypoxemia; higher PEEP contributes to lung recruitment and minimizes the repeated

opening and closure with no significant overdistension. Early administration of high PEEP with low VT is beneficial in cases of severely hypoxemic ARDS patients [16]. High PEEP levels are associated with lower hospital mortality compared to lower PEEP levels in ARDS [17].

Prone positioning is a good method to improve oxygenation and decrease the ventilation/perfusion mismatch in severe ARDS [18]. Early prolonged application of prone positioning with high PEEP improves survival during this period [19]. Prone positioning improves recruitment of the lung and reduces alveolar instability and hyperinflation seen at high PEEP levels in patients with ARDS [20]. The prone position with low tidal volume (≤ 8 ml/kg) reduces mortality significantly, especially in high-dose (>12h/day) group [21]. The length of prone positioning has been suggested to correlate with survival [22].

Our patient revealed signs of chylothorax which was confirmed by the aspiration of milky fluid and its biochemical analysis. Etiological causes were multifactorial (history of tuberculosis, trauma) in our patient but the exact cause could not be identified. High flow chylothorax resulted in acute respiratory failure that then led to a more complicated case of ARDS. Before the surgical intervention; protective mechanical ventilation strategies and prolonged prone positioning were applied to treat the severe case of ARDS. Thoracic duct ligation was done because of high-flow chylothorax. Chylous drainage diminished after the surgery. Nosocomial pneumonia was also suspected, and empirical antibiotic therapy was initiated. When the cultures of blood, urine, tracheal aspirate and pleural fluid did not show significant bacterial growth, empirical antibiotic therapy was terminated. Both lungs were recovered through the application of early

prolonged prone positioning, protective mechanical ventilation strategies and recruitment maneuvers with high PEEP. The patient was extubated on the fifth day of his intensive care stay and subsequently discharged from the intensive care unit.

REFERENCES

1. **Surya K, Sanjay KV, Sunish CA, et al.** Development of bilateral chylothorax in younger female secondary to tuberculosis. *Lung India* 2011;28(1):56-9. <http://dx.doi.org/10.4103/0970-2113.76303>
2. **Hans HS, Christian PS, Armin W, et al.** Treatment options in patients with chylothorax. *Deutsches Arzteblatt International* 2013;110(48):819-26.
3. **Doerr CH, Allen MS, Nichols FC III, et al.** Etiology of chylothorax in 203 patients. *Mayo Clin Proc* 2005;80:867-70. <http://dx.doi.org/10.4065/80.7.867>
4. **Hooper C, Gary Lee YC, Maskell N.** Investigation of a unilateral pleural effusion in adults: British Thoracic Society pleural disease guideline 2010. *Thorax* 2010; 65(2):417.2010.136978
5. **Misook S, Won-Jung S, In-Gu J.** Central venous catheter-related superior vena cava syndrome following renal transplantation -A case report-. *Korean J Anesthesiol* 2012;63(6):550-4. <http://dx.doi.org/10.4097/kjae.2012.63.6.550>
6. **Mallick A, Bodenham M.** Disorders of the lymph circulation: their relevance to anaesthesia and intensive care. *Br J Anaesth* 2003;91(2):265-72. <http://dx.doi.org/10.1093/bja/aeg155>
7. **Nair SK, Petko M, Hayward MP.** Aetiology and management of chylothorax in adults. *Eur J Cardiothorac Surg* 2007;32:382-69. <http://dx.doi.org/10.1016/j.ejcts.2007.04.024>
8. **Büttiker V, Fanconi S, Burger R.** Chylothorax in children: guidelines for diagnosis and treatment. *Chest* 1999;116:682-87. <http://dx.doi.org/10.1378/chest.116.3.682>
9. **Paul S, Altroki NK, Port JL, et al.** Surgical management of chylothorax. *Thorac Cardiovasc Surg* 2009; 57:226-8. <http://dx.doi.org/10.1055/s-0029-1185457>
10. **Epaud R, Dubern B, Larroquet M, et al.** Therapeutic strategies for idiopathic chylothorax. *J Pediatr Surg* 2008;43:461-5. <http://dx.doi.org/10.1016/j.jpedsurg.2007.10.024>
11. **Browse NL, Allen DR, Wilson NM.** Management of chylothorax. *Br J Surg* 1997;84:1711-6. <http://dx.doi.org/10.1002/bjs.1800841218>
12. **Hillerdal G.** Chylothorax and pseudochylothorax. *Eur Respir J* 1997;10:1157-62. <http://dx.doi.org/10.1183/09031936.97.10051157>
13. **Lindhorst E, Miller HA, Taylor GA, et al.** On the possible role of positive end-expiratory pressure ventilation in the treatment of chylothorax caused by blunt chest trauma. *J Trauma* 1998;44(3):540-2. <http://dx.doi.org/10.1097/00005373-199803000-00023>
14. **Robert NP.** Treatment of chylothorax. *Arch Surg* 1980;115(9):1137. <http://dx.doi.org/10.1001/archsurg.1980.01380090101028>
15. **Mallick A, Bodenham AR.** Disorders of the lymph circulation: their relevance to anaesthesia and intensive care. *Br J Anaesth* 2003;91(2):265-72. <http://dx.doi.org/10.1093/bja/aeg155>
16. **Guerin C.** The preventive role of higher PEEP in treating severely hypoxemic ARDS. *Minerva Anesthesiol* 2011;77:835-45.
17. **Briel M, Meade M, Mercat A, et al.** Higher vs lower positive end-expiratory pressure in patients with acute lung injury and acute respiratory distress syndrome. *JAMA* 2010;303(9):865-73. <http://dx.doi.org/10.1001/jama.2010.218>
18. **Pelosi P, Brazzi L, Gattioni L.** Prone position in acute respiratory distress syndrome. *Eur Respir J* 2002;20(4):1017-28. <http://dx.doi.org/10.1183/09031936.02.00401702>
19. **Claude G, Jean R, Jean CR, et al.** Prone positioning in Severe Acute Respiratory Distress Syndrome. *N Engl J Med* 2013;368:2159-68. <http://dx.doi.org/10.1056/NEJMoa1214103>
20. **Cornejo RA, Diaz JC, Tobar EA, et al.** Effects of prone positioning on lung protection in patients with acute respiratory distress syndrome. *Am J Respir Crit Care Med* 2013;188(4):440-8. <http://dx.doi.org/10.1164/rccm.201207-1279OC>
21. **Beitler JR, Shaeff S, Montesi SB, et al.** Prone positioning reduces mortality from acute respiratory distress syndrome in the low tidal volume era: a meta-analysis. *Intensive Care Med* 2014;40(3):332-41. <http://dx.doi.org/10.1007/s00134-013-3194-3>
22. **Abroug F, Ouanes-Besbes L, Dachraoui F, et al.** An updated study-level meta-analysis of randomized controlled trials on proning in ARDS and acute lung injury. *Crit Care* 2011;15:R16. <http://dx.doi.org/10.1186/cc9403>