

# Are You Sure it is a Sexual Abuse? Cinsel İstismar Olduğuna Emin misiniz?

© Yavuz DEMİRÇELİK<sup>1</sup>, © Selcen KUNDAK<sup>2</sup>, © Özlem BAĞ<sup>3</sup>

<sup>1</sup>İzmir Bayraklı City Hospital, Clinic of Pediatrics, İzmir, Türkiye

<sup>2</sup>University of Health Sciences Türkiye, Dr. Behçet Uz Pediatric Diseases and Surgery Training and Research Hospital, Clinic of Dermatology, İzmir, Türkiye

<sup>3</sup>University of Health Sciences Türkiye, Dr. Behçet Uz Pediatric Diseases and Surgery Training and Research Hospital, Clinic of Pediatrics, İzmir, Türkiye

Cite as: Demirçelik Y, Kundak S, Bağ Ö. Are You Sure it is a Sexual Abuse? Forbes J Med 2024;5(1):76-8

## ABSTRACT

Vulvar lichen sclerosis is a rare dermatosis in childhood. Clinical signs may be confused with sexual abuse, so differential diagnosis requires careful evaluation, especially during childhood. In this report, we present a case of lichen sclerosis who was referred to Child Advocacy Center with an initial diagnosis of sexual abuse. The diagnostic work-up included a multidisciplinary approach.

**Keywords:** Lichen sclerosis, childhood, sexual abuse

## ÖZ

Vulvar liken skleroz, çocukluk çağında nadir görülen bir dermatoz türüdür. Klinik bulguları, cinsel istismarla karışabilme olasılığı nedeniyle özellikle çocukluk döneminde ayırıcı tanının titizlikle yapılmasını gerektirir. Bu yazıda, Çocuk İzlem Merkezi'ne cinsel istismar ön tanısıyla başvuran bir liken skleroz olgusu sunulmaktadır. Teşhis süreci, multidisipliner bir yaklaşımı içermektedir.

**Anahtar Kelimeler:** Liken skleroz, çocukluk çağı, cinsel istismar

Received/Geliş: 12.03.2024

Accepted/Kabul: 27.03.2024

Corresponding Author/  
Sorumlu Yazar:

Yavuz DEMİRÇELİK MD,

İzmir Bayraklı City Hospital, Clinic  
of Pediatrics, İzmir, Türkiye

Phone: +90 554 804 00 48

✉ yavuzdemircelik@gmail.com

ORCID: 0000-0002-5047-6969

## INTRODUCTION

Child sexual abuse is a diagnostic challenge for clinicians because of the lack of knowledge about anogenital findings of sexual assault and the legal obligation to refer the case to the prosecutor in case of suspicion of sexual abuse. According to Turkish laws, a healthcare professional who does not report the situation to the competent authorities or delays in doing so, despite encountering an indication that a crime has been committed while performing his/her duty, is punished with imprisonment for up to one year.<sup>1</sup> Thus, healthcare professionals prefer reporting any anogenital finding as 'suspicious' for sexual abuse and make unnecessary reporting rather than being claimed to have underdiagnosed and underreported the case. However, misdiagnosis of sexual abuse can be traumatic for everyone involved.<sup>2</sup> In the absence of any disclosure or witnessing, normal or nonspecific findings should be

well evaluated before reporting the child as a victim of sexual abuse. Healthcare professionals may interpret some vulvar skin lesions, such as lichen sclerosis, as sexual abuse because of insufficient medical knowledge or clinical experience.

In this report, we present the case of a 7-year-old girl who was referred to the local Child Advocacy Center (CAC) for suspected child sexual abuse due to anogenital lesions and diagnosed with lichen sclerosis following a diagnostic work-up.

## CASE REPORT

A seven-year-old girl was brought to the pediatric outpatient department with lesions in the anogenital area. Her mother reported observing her daughter scratching the vulvar region the night before and noticing redness the following morning. Concerned, the pediatrician



Copyright© 2024 The Author. Published by Galenos Publishing House on behalf of Buca Seyfi Demirsoy Training and Research Hospital. This is an open access article under the Creative Commons AttributionNonCommercial 4.0 International (CC BY-NC 4.0) License.

Copyright© 2024 Yazar. Buca Seyfi Demirsoy Eğitim ve Araştırma Hastanesi adına Galenos Yayınevi tarafından yayımlanmıştır. Creative Commons Atif-GayriTicari 4.0 Uluslararası (CC BY-NC 4.0) Uluslararası Lisansı ile lisanslanmış, açık erişimli bir makaledir.

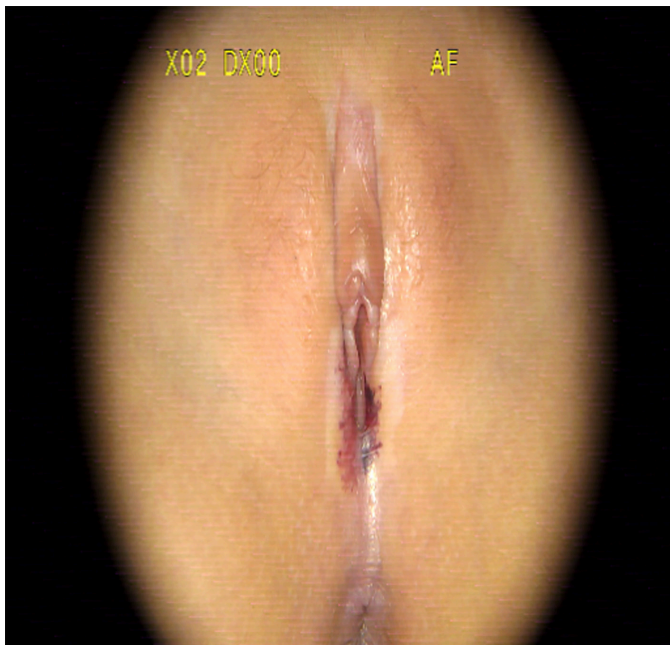


considered these lesions indicative of sexual exploitation and sought consultation from an obstetrician. The following examination, they concluded that the lesions were consistent with findings of child sexual abuse and referred the child to CAC, which was in another pediatric hospital.

During the preliminary interview at the CAC, the child exhibited age-appropriate developmental characteristics and demonstrated ease and proficiency in social interaction. In the subsequent forensic interview, she expressed herself fluently and did not provide any statements that raised suspicion of child sexual abuse. She was able to differentiate between "good touch" and "bad touch" and positively identified figures from Johnson's chart.<sup>3</sup>

Physical examination revealed sharply circumscribed, hypopigmented, atrophic, and hemorrhagic lesions in the labia major, labia minor, and introitus vagina (Figure 1). When examined carefully, it was noticed that these hemorrhagic lesions developed on a symmetrically hypopigmented and atrophic, parchment-like, wrinkled, and slightly depressed plaque in the labia majora and introitus vagina. The hymen was intact, and both the hymen and vaginal mucosa were free from lesions (Figure 2). The mother told us that the white depressed plaque had existed since she was 6 months old, and that the lesions were mildly itchy but sometimes extremely itchy, but that she had not noticed a hemorrhagic lesion before.

Due to the patient history and physical findings, the child was supposed to have lichen sclerosis other than 'victim of sexual abuse' and consulted with a dermatologist. The



**Figure 1.** Lesions in vulvar lichen sclerosis

lesions were diagnostic for lichen sclerosis, which is a vulvar condition in prepubertal children. Local corticosteroid therapy was initiated after dermatologist confirmed and was followed up for lichen sclerosis.

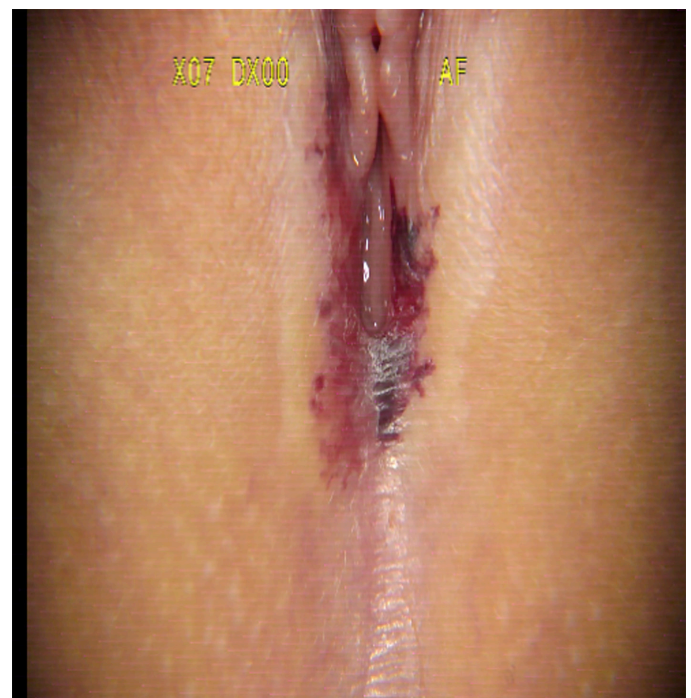
## DISCUSSION

This case involves lichen sclerosis, which was misinterpreted as childhood sexual abuse and reported to legal authorities without necessity because of inadequate medical understanding of vulvar lesions in prepubertal children.

Many complaints that could signal sexual abuse are non-specific, and diagnosing sexual abuse relies on the physician's approach to consider it as a potential cause.<sup>4</sup> Some children present with medical or behavioral concerns that are not obviously related to the abuse. However, careful history taking and meticulous physical examination may reveal skin conditions other than sexual abuse.

Lichen sclerosis is a rare skin condition influenced by various genetic, physiological, and environmental factors. Its occurrence in childhood is uncommon, estimated at 1 in 900 cases.<sup>5,6</sup> Flat, ivory to white papules coalesce to form plaques of varying size and shape.

These papules develop follicular plugging and progressive atrophy that leads to parchment-like, wrinkled, flat, or slightly depressed lesions called 'cigarette paper atrophy'. Vulvar lesions may have pruritus-related scratching



**Figure 2.** Hymen and vaginal mucosa without lesions

and hemorrhagic lesions. Factors such as infection and moisture can intensify symptoms.

The presence of ecchymotic and purpuric lesions in the anogenital area may raise suspicion of child sexual abuse among clinicians. Hence, when observing lesions possibly linked to anogenital trauma, clinicians should consider child sexual abuse and report suspected cases for evaluation, as child sexual abuse assessments require a specialized, multidisciplinary approach. CACs are specialized facilities where suspected child sexual abuse cases undergo evaluation, addressing legal, social, and health concerns.

In our case, the child exhibited appropriate development during the initial interview and did not disclose any history or signs suggestive of sexual abuse during the forensic assessment. Physical examination revealed white plaques and intact hymen and vaginal mucous membranes, consistent with lichen sclerosis rather than child sexual abuse findings. In cases of child sexual abuse, acute traumatic injuries to the anogenital region typically involve hymenal and/or vaginal injuries.<sup>3</sup> However, it is important to acknowledge that sexual abuse may act as a trigger in lichen sclerosis cases, and child sexual abuse evaluation should not be disregarded.<sup>7,8</sup>

Lichen sclerosis diagnosis is primarily clinical, with debate regarding the necessity of pathological confirmation. While some argue for biopsy in every case, experienced clinicians often find clinical presentation sufficient for diagnosis, and histological evidence is not always mandatory.<sup>9</sup> Biopsy is usually reserved for cases with diagnostic uncertainty, suspicion of neoplastic changes, treatment resistance, or atypical extragenital presentations.<sup>10</sup> In this study, the dermatologist deemed the lesions to be typical of lichen sclerosis, eliminating the need for histological evaluation. If biopsy is warranted, it is recommended either before initiating topical corticosteroid treatment or after 4 weeks of treatment cessation.

## CONCLUSION

In summary, lichen sclerosis is a rare condition in childhood that may elude recognition by clinicians, with clinical features sometimes mistaken for signs of sexual abuse. A thorough differential diagnosis should be conducted through detailed history-taking and physical examination in children presenting with such findings. Biopsy is not always essential for diagnosis, as detailed clinical assessment suffices to initiate diagnosis and treatment. Candidiasis, contact dermatitis, psoriasis, herpes simplex virus, varicella, cellulitis, irritants, trauma, constipation, poor hygiene, pinworms, etc., can mimic signs of sexual abuse when presenting as perianal lesions, making diagnosis challenging. Therefore, the assessment

of sexual abuse requires a multidisciplinary approach. When gathering a patient's history and conducting a physical examination, clinicians should possess proficiency in appropriate interview techniques, childhood developmental milestones, typical and atypical childhood sexual behaviors, and normal pediatric genital anatomy. Future study protocols could incorporate a checklist of recognized mimics to enhance the comprehensive identification and documentation of such cases.

## Ethics

**Informed Consent:** Informed consent was obtained from the legally responsible person of the patient.

## Authorship Contributions

Medical Practices: Y.D., S.K., Ö.B., Concept: Y.D., S.K., Ö.B., Design: Y.D., Ö.B., Data Collection or Processing: Y.D., Ö.B., Analysis or Interpretation: Y.D., S.K., Ö.B., Literature Search: Y.D., Ö.B., Writing: Y.D.

**Conflict of Interest:** No conflict of interest was declared by the authors.

**Financial Disclosure:** The authors declared that this study received no financial support.

## REFERENCES

1. Karahan AB. Sağlık Mesleği Mensuplarının Suçu Bildirmemesi Suçu (TCK m. 280). Marmara Üniversitesi Hukuk Fakültesi Hukuk Araştırmaları Dergisi. 2019;25:948-78.
2. Adams JA. Evaluating children for possible sexual abuse. Am Fam Physician. 2001;63:843-6.
3. Gallion HR, Milam LJ, Littrell LL. Genital Findings in Cases of Child Sexual Abuse: Genital vs Vaginal Penetration. J Pediatr Adolesc Gynecol. 2016;29:604-11.
4. Kellogg N; American Academy of Pediatrics Committee on Child Abuse and Neglect. The evaluation of sexual abuse in children. Pediatrics. 2005;116:506-12.
5. Powell J, Wojnarowska F. Childhood vulvar lichen sclerosis: an increasingly common problem. J Am Acad Dermatol. 2001;44:803-6.
6. Goldstein AT, Marinoff SC, Christopher K, Srodon M. Prevalence of vulvar lichen sclerosis in a general gynecology practice. J Reprod Med. 2005;50:477-80.
7. Delmarre E, Delteil C, Mallet S, Boval C, Capasso F, Piercecchi-Marti MD. Vulvar lichen sclerosis in children misdiagnosed as sexual abuse. Arch Pediatr. 2015;22:383-6.
8. Navarro-Crummenauer B, Pickhardt CP, Urban R. Lichen sclerosis Mistaken for Sexual Abuse--Prevention of Victimization. Klin Padiatr. 2015;227:239-42.
9. Lee A, Bradford J, Fischer G. Long-term Management of Adult Vulvar Lichen Sclerosis: A Prospective Cohort Study of 507 Women. JAMA Dermatol. 2015;151:1061-7.
10. Winfield H, Jaworsky C. Connective Tissue Diseases. In: Elder D, Elenitsas R, Johnson B, et al. Lever's Histopathology of the Skin. 10th ed. Philadelphia, PA: Lippincott Williams & Wilkins;2009;303-7.