

Predictor Mandibular Dentoalveolar Features on the Occurrence of 1-Rooted/C-Shaped Mandibular Second Molar Teeth

 Hakan AYDIN

Private Practice, Antalya, Türkiye

ABSTRACT

Objective: This study aimed to examine the mandible form features of the mandible, such as inter-second molar width, anteroposterior length, arch perimeter length, arch breadth, corpus height/width in the mandibular second molars (MnSM) region, and arch form, and the relation for the occasion of the 1-rooted/C-shaped.

Methods: The study analyzed cone-beam computed tomography images of 215 male and 215 female Turkish patients to determine the prevalence of 1-rooted and C-shaped MnSM. Mandibular dentoalveolar characteristics of individuals with bilateral (1R-1R group) and unilateral (1R-2R group) 1-rooted MnSM were examined and compared with those with bilateral 2-roots (2R-2R group) MnSM. Statistical tests were performed using Chi-square, one-way ANOVA, Tukey, and binary logistic regression analysis at the 5% significance level.

Results: The prevalence of 1-rooted and 1-rooted/C-shaped MnSM was 12.79% and 9.65%, respectively. Root fusion was more commonly present in females ($p < 0.05$). In the 1R-1R group, the anteroposterior length was shorter than in the 2R-2R group ($p < 0.05$). There was no difference between the groups for other features ($p > 0.05$).

Conclusion: Although the study found a shorter anteroposterior length in the 1R-1R group, no feature was a predictive variable for 1-rooted/C-shaped MnSM.

Keywords: Cone-beam computed tomography, C-shaped, mandibular arch, mandibular morphology, mandibular second molar

This study was presented as an oral presentation at the 26th Turkish Dental Association International Dentistry Congress, September 8–11, 2022, Istanbul Congress Center.

The current affiliation of the author:
Department of Endodontics, Antalya Bilim University Faculty of Dentistry, Antalya, Türkiye

Please cite this article as:

Aydın H. Predictor Mandibular Dentoalveolar Features on the Occurrence of 1-Rooted/C-Shaped Mandibular Second Molar Teeth. Eur Endod J 2024; 9: 65-72

Address for correspondence:

Hakan Aydın
Private Practice, Antalya, Türkiye
E-mail: vugas07@gmail.com

Received May 09, 2023,
Revised July 01, 2023,
Accepted August 01, 2023

Published online: November 14, 2023
DOI 10.14744/ej.2023.91886

This work is licensed under a Creative Commons Attribution-NonCommercial 4.0 International License.



HIGHLIGHTS

- The prevalence of 1-rooted teeth in MnSM was 12.8%. For 1-root types, a C-shaped configuration was most predominant (9.65%).
- A prevalence of 15.81% was observed in females, which was higher than that in males (9.76) ($p < 0.05$).
- Symmetrical involvement rate was 64% in 1-rooted MnSM teeth.
- Anteroposterior length of the mandible was measured as the shortest in patients with bilateral 1-rooted MnSM teeth.
- In 1-rooted/C-shaped MnSM, which complicates endodontic treatment, variability in the mandibular basal arch is limited, and the effects of craniofacial structures on the predictive variables of this root type should be investigated in further studies.

INTRODUCTION

Mandibular second molars (MnSM) have more variable root morphology when compared to adjacent first molars and more variations in internal root canal anatomy; researchers have shown great interest and extensively studied

these teeth (1, 2). Although MnSM usually exhibit two separate root structures, they are rarely 3-rooted with an additional root (1, 3). Fusion between roots may occur more frequently than an increase in root number, and they may exhibit a single root morphotype with

more characteristic radicular deviation (3). C-shaped root and canal configuration is the most common root canal system in single-rooted mandibular molars (4, 5). Roots with longitudinal grooves on the buccal or lingual between the fused roots are called C-shaped (4). Although C-shaped root and canal morphology can also be present in maxillary molars (6) and mandibular premolars (7), the major involvement is in MnSM (8). C-shaped teeth exhibiting complex root canal systems have a number of technical challenges during root canal treatment (8). Fin or web communications between canals, multiple canal irregularities, ribbon-shaped canal orifices, narrow isthmuses, thin canal walls, complex root canal configurations, and deep-located canal orifices usually require modified techniques during instrumentation and root canal filling procedures (9, 10). Branching in the course of the canal can occur at any canal level between the canal orifice and apical foramen, resulting in missed main or branching canals. High frequency of transverse anastomosis, apical deltas, and accessory canals are additional anatomical challenges (9–11). The survival rate of such teeth, that are widely used as abutments for fixed prosthodontics, is of a critical concern (12).

The 1-rooted/C-shaped root canal morphology in MnSM, showing demographic heterogeneity, is observed with much higher frequencies in East-Asian countries than in other ethnicities, geographic regions, and populations and is characterized as a Mongoloid feature (2, 8). The 1-rooted configuration observed in over 40% of Asians is found in less than 15% of non-East Asian populations, with a significant difference (2, 4, 8). It is still unclear why regional and racial trends observed in MnSM morphology differ from the global trend. Mandibular phenotypic features of Mongoloids are shorter arc length and wider intercanine and intermolar width (13). Apart from this high rate of occurrence in Mongoloids, the mandible is routinely wider and longer in males than females (14); 1-rooted/C-shaped MnSM are more common in females than males (2). Failures in the fusion of Hertwig's epithelial root sheath on the lingual or buccal root surface are etiological mechanisms proposed for this unique root and canal feature; however, studies on this hypothesis have not been conducted. Although the approach that "bulky teeth require large jaws and wide jaws require a wide body" seems logical, the scenario does not always work out that way (15). The human genome results from the interactions between hereditary and environmental influences over time, and the shape and size of the jaws are ultimately affected (8). Anthropological research and studies in forensic dentistry have investigated correlations between different body structures and crown and root lengths of teeth. Correlations between root length and alveolar height, tooth and jaw size, tooth and skull size, body weight and anterior mandibular mesiodistal crown diameter, body height and mandibular length, total tooth/root length and stature, mandibular prognathism and canine tooth width, anterior root size and symphyseal/mandibular size relationships have been reported (15–18). However, there is no study investigated the effects and correlations of craniofacial structures on tooth root numbers and fused/C-shaped roots. Examining the epidemiological prevalence and non-metric and odontomet-

ric features of 1-root/C-shaped root and canal systems could bring interest to researchers and clinicians. However, there has been no empirical attempt to support studies in a biometric study by osteometric measurements suggesting that "root fusion is an adaptation for teeth to fit in smaller jaws" (8). It is unknown which of the morphometric parameters of the mandible increases the tendency for root fusion.

Therefore, this study aimed to examine mandible form features, such as inter-MnSM width, anteroposterior length, arch perimeter length, arch breadth, corpus height/width in the MnSM region, and arch form explanatory for 1-root form. The null hypothesis was that no difference exists between the parameters mentioned above in subjects with bilateral 1-rooted, unilateral 1-rooted, and bilateral 2-rooted MnSM.

MATERIALS AND METHODS

Sample Size Selection

The sample size of this retrospective study consisted of 430 Turkish participants; the sample size was accepted as the lower limit in epidemiological studies and provided a study power of 0.90 (Java Applets for power and sample size, <http://www.stat.uiowa.edu/~rlenth/Power>). Since the effects of sexual dimorphism on the root number of MnSM and the mandibular form are known, 215 individuals equally from both sexes were selected and obtained ethics committee approval (KA EK-381, dated 25/5/2022, Faculty of Medicine Clinical Trials Ethics Committee, Akdeniz University). Study procedures were carried out in accordance with the Helsinki Declaration. To identify individuals with inclusion criteria, sample size adequacy was achieved after examining 8018 of the cone-beam computed tomography (CBCT) images in a private dental clinical data system.

CBCT Acquisition and Processing

The images were taken using the CBCT device (Sirona Orthophos XG3D, Sirona Dental as Systems GmbH, Bensheim, Germany); the scan settings were as follows: 6.0 mA, 0.160 mm voxel size, 5 kV, full arch (8×8 field of view), and 14 seconds scan time/exposure time. Image processing was performed with Sidexis 4 (Sirona) software coupled to the CBCT device in multiplanar axial, sagittal, and coronal planes by a single operator (HA, 6 years of experience in endodontics) with a slice thickness of 0.1 mm. To eliminate inter-rater discrepancy, analyses were performed with a trained single observer, as followed in previous studies (1, 5, 6, 7, 10). Cases with low-quality CBCT scans were excluded. No additional images were obtained for the study. Preexisting images in the data pool were used with full screen, zoom, contrast, and rotation settings to increase visualization.

Inclusion and Exclusion Criteria

Inclusion criteria: The study included patients with bilateral MnSM and full dentition in the mandibular arch (cases with all mandibular teeth, except wisdom teeth). Subjects aged 18 years and above with fully developed roots and minimal change in mandibular morphology were included. Teeth with moderately large carious lesions and restorations or with root canal treated teeth in Class 1 cavities (in teeth other than MnSM) were included as they would not affect the measurements.

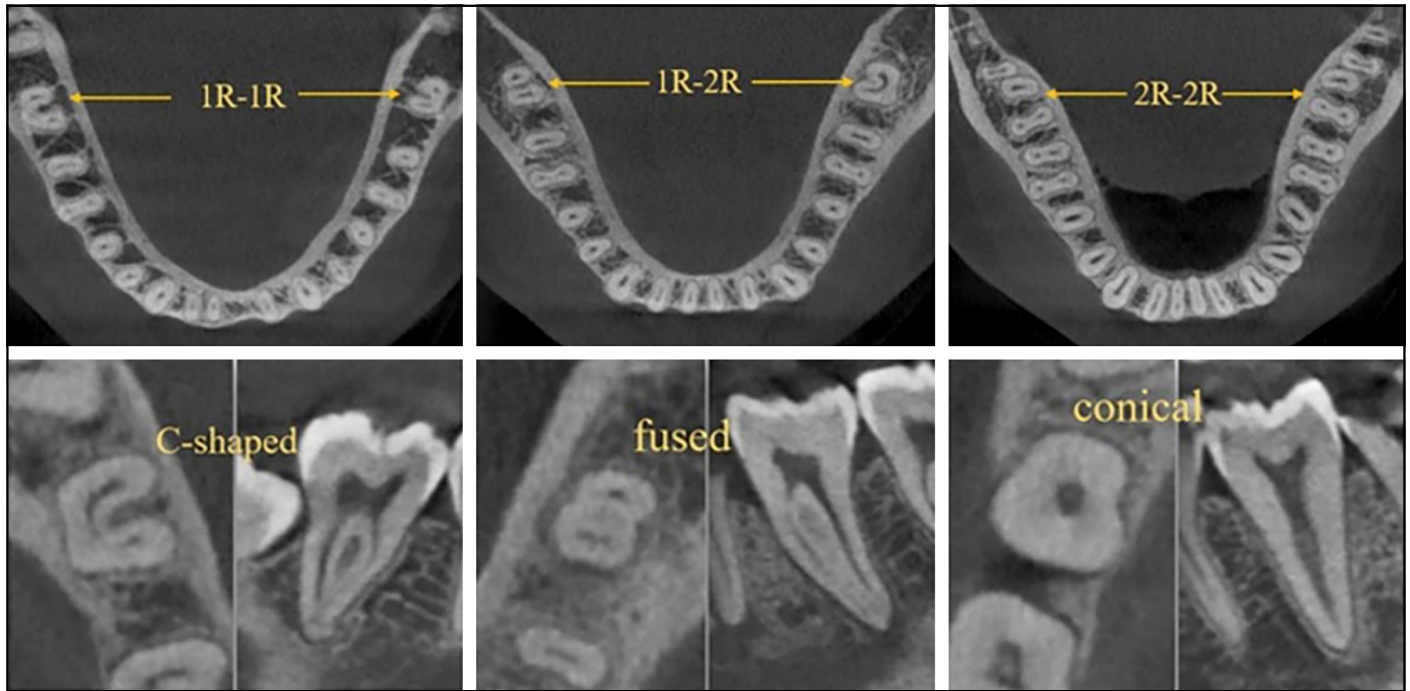


Figure 1. Examples of bilateral 1-rooted, unilateral 1-rooted, and bilateral 2-rooted subjects and 1-rooted types

Exclusion criteria: For MnSM, teeth with root canal treatment, extensive caries and fillings, prosthetic restorations, and posts were excluded. For other cases, teeth with large restorations and prostheses were excluded because the position of MnSM could have changed. Individuals with significant periodontal problems and decreased tooth length due to attrition and impairment of the integrity of the contact points were excluded from the study. Patients with a history of orthodontic treatment, missing or additional teeth, and those with retained deciduous teeth were excluded.

Root Numbers of Mandibular Second Molars and Subgroups of 1-Rooted Teeth

First, root anatomies of bilateral MnSM of 430 patients were examined. According to the number of roots, the teeth were divided into 1-, 2-, and 3-rooted. No further classification was made for 2- and 3-rooted teeth. 1-rooted teeth were divided into the following subgroups (Fig. 1):

- C-shaped: teeth with prominent radicular grooves extending longitudinally at the fusion border between roots and exhibit C1, C2, and C3 the root canal system configurations in cross-section (9).
- Fused: teeth with no obvious groove in the fusion line between roots; only a notch is present.
- Conical: teeth with a single large, round, or oval canal in the middle in cross-section from the canal orifice to the root apex. This group included teeth in the C-4 category in the C-shaped root canal configuration classification (9).

Groups According to the Symmetry Pattern of Root Numbers of Mandibular Second Molars

Subjects were divided into 3 groups according to the symmetry pattern of root numbers of MnSM. Statistical analysis was performed between these three groups (Fig. 1):

- 1R-1R group. Bilaterally, both MnSM had 1 root.
- 1R-2R group. Regardless of tooth position (right-left), MnSM had 1 root on one side and 2 roots on the other side.
- 2R-2R group. Bilateral MnSM had 2 roots.
- Teeth showing 3R-3R, 2R-3R, and 1R-3R symmetry patterns were identified but not included in the study groups.

Mandibular Form Elements Examined in Groups

Measurements made in the mandible were recorded with 0.01 mm accuracy. First, the center of resistance for each tooth was determined. The root length from the cemento-enamel junction of each tooth to the root tips was measured in the sagittal plane; the coronal 2/3 distance of this length formed the resistance center of the tooth, as in previous studies on single-rooted teeth (19). It was not possible to determine the furcation point in 1-rooted MnSM, and the furcation point in 2-rooted MnSM varied in each tooth (e.g., the presence of taurodontism), unlike studies that considered the furcation point as the center of resistance in mandibular molars (19). Therefore, the center of resistance in 2-rooted MnSM was considered the same as in 1-root teeth (that is the 2/3 coronary point of the root).

The features assessed in the CBCT image of the mandible were (14):

- Mandible basal bone width: These measurements represent bone width around MnSM (Fig. 2a). Measurements were made from the mid-point mesiodistally in the coronal plane. The vertical distance from the centers of resistance of the teeth to the lower border of the mandible was divided into three equal parts, and two horizontal lines were calculated. This measurement was applied to both MnSM, and the mean of 4 measurements constituted the width of the basal bone.

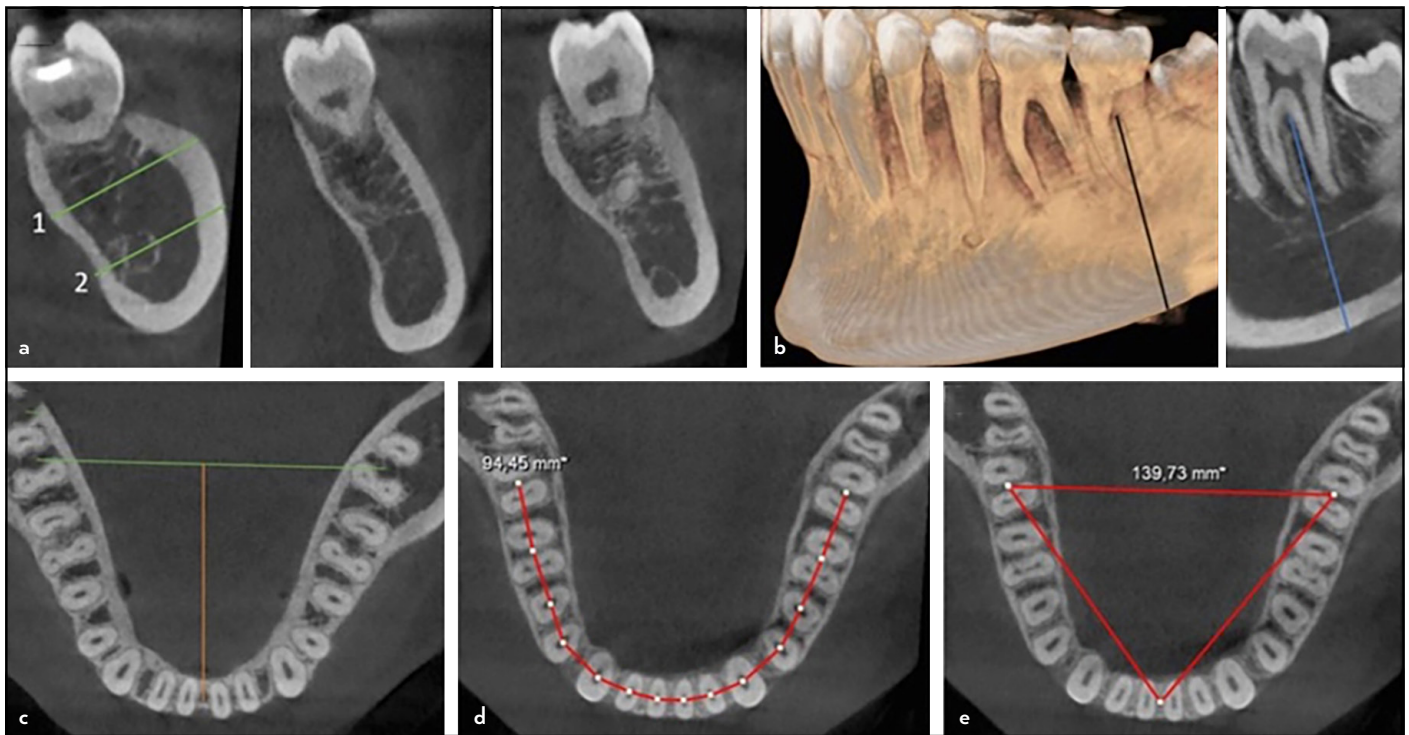


Figure 2. (a) Lines measured for mandibular basal bone width and basal bones in different morphology, (b) corpus height, (c) inter-second molar width and anteroposterior length, (d) arch perimeter, (e) arc breadth

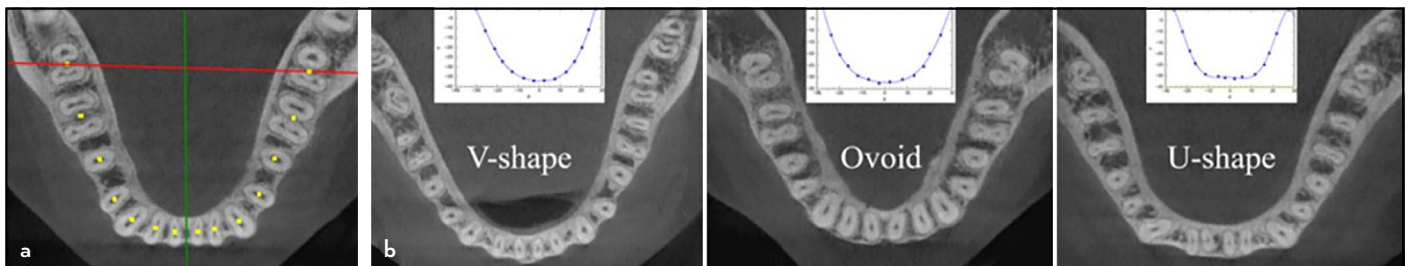


Figure 3. (a) X and Y planes and the coordinate plane formed by the resistance center points of each tooth, (b) examples of arch form types

- **Mandibular corpus height:** The vertical distance from the tooth center of both MnSM to the lower border of the mandible was measured in the sagittal plane (Fig. 2b). The average of these two values constituted the corpus height.
- **Inter-MnSM width/mandibular arch width:** Horizontal distance between the resistance centers of both MnSM in the axial plane (Fig. 2c).
- **Anteroposterior mandibular arch length:** The closest length from the midpoint of the tooth resistance centers of the mandibular central incisors to the line drawn between the tooth centers of the MnSM in the axial plane (Fig. 2c).
- **Mandibular arch perimeter:** The tooth centers of 14 teeth were marked, and the length between these points was collected, starting from the right MnSM tooth to the left MnSM tooth in the axial plane (Fig. 2d).
- **Mandibular breadth:** Three points were determined for this measurement, and the sum of the three lines formed by combining these three points was calculated in the axial plane. These three points were both MnSM tooth centers and the midpoint of tooth centers of the mandibular central incisors (Fig. 2e). Using this measurement variable, it was aimed to evaluate the arch width and anteroposterior lengths together in the same patient.
- **Mandibular arch form (13):** To determine the arch form, the positions of 14 tooth centers in the X and Y planes were found in the axial plane. Briefly, this process was performed as follows. The X-axis was formed by the line connecting the centers of resistance of the MnSM. The line drawn from the midpoint of the mandibular central incisors to the X-axis formed the Y point (Fig. 3a). The closest distance of each resistance center to the X- and Y-axis formed the coordinate planes of these points. These values were entered into a curve-expert program to determine the most suitable polynomial curve connecting these 14 points (CurveExpert Professional 2.7.3, Hyams Development, U.S.A). The 6th-degree polynomial function equation was used to determine the estimated locations other than 14 points. For arch forms, cases were divided into three groups (Fig. 3b): V-shaped, ovoid-shaped, and U-shaped.

TABLE 1. Number and percentages of roots in mandibular second molars and root type in 1-rooted teeth; distribution of these values by tooth position and sex

	Tooth location (n=860)						Sex (n=430)			
	Total (n=860)		Right (n=430)		Left (n=430)		Female (n=215)		Male (n=215)	
	n	%	n	%	n	%	n	%	n	%
Root numbers										
1-rooted	110	12.79	58	13.49	52	12.09	68	15.81*	42	9.77
2-rooted	724	84.19	358	83.29	366	85.12	349	81.16*	375	87.21
3-rooted	26	3.02	14	3.26	12	2.79	13	3.02	13	3.02
1-rooted type	110	12.79	58	13.49	52	12.09	68	15.81	42	9.76
C-shaped	83	9.65	44	10.23	39	9.07	45	10.47*	38	8.84
Conical	13	1.51	7	1.63	6	1.4	11	2.56	2	0.47
Fused	14	1.63	7	1.63	7	1.63	12	2.79*	2	0.47

*: Indicates statistically significant difference according to chi-square tests (p<0.05)

Since the sample numbers of the groups were unequal, 43 individuals were randomly selected in the 2R-2R group (using the SPSS-select cases-random samples of cases-exactly 43 sample size command). The evaluations were made on all individuals in the 1R-1R and 1R-2R groups. This sample size was chosen because it was outnumbered by the other two groups. Measurements and statistics were performed on this sample.

Statistical Analysis

All collected data were entered into a package program (SPSS version 22.0, IBM SPSS Statistics, Chicago, IL), and all statistical analyses were tested at a 5% significance level. Since all observations were made by a single examiner, only intra-rater reliability was considered for the reliability of measurements, and the second evaluation was made after 3 weeks. Cohen Cappa was preferred for reliability in categorical variables, such as root number, 1-root type, and arc form. The Intraclass Correlation Coefficient (ICC) test was preferred for scale-level measurements. For root and canal anatomy, approximately 20% of 1-rooted-, 2-rooted, and 3-rooted teeth were reevaluated separately; 20% of V-shaped-, Ovoid-shaped, and U-shaped teeth were evaluated separately for arch form. Approximately 20% of all three groups (1R-1R, 1R-2R, and 2R-2R) were measured again for scale measurements. For statistical differences, Chi-square tests were used for categorical variables, and one-way ANOVA and post hoc Tukey tests were applied between the three groups for numerical values. The predictor variable of the evaluated mandibular features of 1-rooted MnSM was determined by logistic regression analysis. Patients were divided into two groups depending on the presence or absence of a single-rooted tooth. Thus, the 1R-1R and 1R-2R groups were combined and reduced to a single group.

RESULTS

The study examined 860 teeth bilaterally from 430 patients. The mean age of 215 female (50%) and 215 male (50%) patients was 34.05±10.14 (range; 18–64). In the intra-rater reliability tests, the numbers of roots, 1-root type, and arch form type of all teeth examined in the second observation were the same as in the first observation, with full agreement. In ICC tests, correlations were found above 0.90 in all measurements and showed high reliability.

TABLE 2. Symmetry pattern of mandibular second molars

Symmetrical distribution	n	%	95% CI
2R-2R	340	79.07	74.98–82.65
1R-1R	43	10.0	7.51–13.2
1R-2R	24	5.58	3.78–8.17
2R-3R	21	4.88	3.22–7.35
3R-3R	2	0.47	0.13–1.68
1R-3R	–	–	–
Total	430	100	100

1R: 1-rooted, 2R: 2-rooted, 3R: 3-rooted, CI: Confidence interval

Root Numbers of Mandibular Second Molars and Root Types in 1-Rooted Teeth

Table 1 shows the number of roots in MnSM, the number and percentages of root types in 1-rooted teeth, and the distribution of these values according to tooth position and sex. The prevalence of 1-rooted teeth in MnSM was 12.79% (95% CI, 10.72%–15.19%). There was no difference in tooth position, but a prevalence of 15.81% (95% CI, 12.67%–19.56%) was observed in females, which was higher than that in males (9.76 [95% CI, 7.31%–12.94%]) (p<0.05). For 1-root types, a C-shaped configuration was most predominant (9.65% [95% CI, 7.85%–11.81%]).

Symmetry Pattern of Root Numbers in Mandibular Second Molars

The symmetry of root numbers in MnSM is shown in Table 2. Sixty-seven (15.58%) patients exhibited single-rooted teeth. Of these, 43 (64.18%) had bilateral 1-rooted MnSM.

Mandibular Morphology Measurements

Table 3 lists the measurement values of the inter-MnSM width, anteroposterior length, arch perimeter, arch breadth, basal bone width, height in the MnSM region, standard deviation, standard error values, and P-values of the statistical differences between groups. Only the anteroposterior length from the measured values differed between the groups (p<0.05). The 1R-1R group showed the shortest anteroposterior length.

TABLE 3. Mean, standard deviation, standard error, and p-values of inter-second molar width, anteroposterior length, arch perimeter, arch breadth, basal bone width, and height in 1R-1R, 1R-2R, and 2R-2R groups

	n	Mean	SD	SE	95% CI for mean		Min	Max	p
					Lower bound	Upper bound			
Inter-secondmolar width									
1R-1R	43	55.60	3.27	0.49	54.59	56.60	49.08	63.65	0.992
1R-2R	24	55.56	2.09	0.42	54.67	56.43	51.54	58.95	
2R-2R	43	55.52	3.11	0.47	54.56	56.47	49.78	61.19	
Total	110	55.56	2.96	0.28	55	56.11	49.08	63.65	
Antero-posterior length									
1R-1R	43	32.64 ^a	2.27	0.34	31.96	33.36	28.31	38.90	0.041
1R-2R	24	33.57 ^{a,b}	2.17	0.33	32.90	34.23	26.69	37.75	
2R-2R	43	34.01 ^b	2.23	0.45	33.06	34.95	30.79	38.66	
Total	110	33.31	2.27	0.21	32.88	33.74	28.31	38.90	
Arch perimeter									
1R-1R	43	94.29	4.7	0.71	92.84	95.73	86.02	105.29	0.184
1R-2R	24	96.12	3.94	0.80	94.45	97.78	90.22	102.87	
2R-2R	43	95.79	4.62	0.70	94.36	97.21	85.49	106.20	
Total	110	95.28	4.55	0.43	94.41	96.13	85.49	106.20	
Arch breadth									
1R-1R	43	142.18	7.08	1.07	139.99	144.35	13.30	159.66	0.420
1R-2R	24	144.03	5.55	1.13	141.69	146.37	13.94	154.50	
2R-2R	43	143.89	7.19	1.09	141.67	146.10	129.09	156.80	
Total	110	143.25	6.82	0.65	141.96	144.53	129.09	159.66	
Basal bone width									
1R-1R	43	12.12	1.61	0.24	11.62	12.61	9.07	16.99	0.339
1R-2R	24	12.53	1.32	0.26	11.97	13.08	9.75	15.54	
2R-2R	43	12.60	1.67	0.25	12.08	13.11	9.07	15.13	
Total	110	12.40	1.58	0.15	12.10	12.69	9.07	16.99	
Basal bone height									
1R-1R	43	21.60	2.64	0.40	20.78	22.41	16.22	26.50	0.061
1R-2R	24	21.61	2.85	0.58	20.40	22.81	15.52	27.31	
2R-2R	43	22.91	2.87	0.43	22.02	23.79	17.87	31.15	
Total	110	22.11	2.83	0.26	21.58	22.64	15.52	31.15	

The upper letters indicate a statistically significant difference ($p < 0.05$, ANOVA and Tukey tests). 1R: 1-rooted, 2R: 2-rooted, CI: Confidence interval, SD: Standard deviation, SE: Standard error

Arch Forms According to Groups

The number and percentage of arch forms encountered in the groups are shown in Table 4. There was no difference between the groups for arch forms ($p > 0.05$).

Explanatory Variables for Single-Rooted Mandibular Second Molars

According to the logistic regression analysis, none of the independent variables determined in this study were explanatory variables for single-rooted MnSM at the statistical significance level ($p > 0.05$).

DISCUSSION

The study aimed to examine the relationship of 1-rooted MnSM with the mandible based on C-shaped teeth and to determine which feature in the mandible can serve as a predictor of this clinical entity. Although C-shaped root and canal system has been the subject of many studies (2, 4, 20), the literature related to the aetiological factors are limited. In 1-rooted MnSM, in cases where the longitudinal groove is

TABLE 4. Number and percentage of arc forms in groups, n (%)

Group	Arch forms						Total
	V-shaped		Ovoid		U-shaped		
	n	%	n	%	n	%	
1R-1R	8	33.33	10	41.7	6	25	24
1R-2R	14	32.6	20	46.5	9	20.9	43
2R-2R	16	37.2	22	51.2	5	11.6	43
Total	38	34.55	52	47.27	20	8.18	110

1R: 1-rooted, 2R: 2-rooted

shallow, most studies are contradictory for considering such roots as C-shaped (9, 11). Wide, single-canal cases were categorized as conical in the present study (cases where root fusion showed further fusion of the pulps). Most teeth considered as C-shaped having a single canal configuration of varying lengths along the canal course. Therefore, all subgroups with 1 root were categorized in a single group. Preoperative

estimation and diagnosis of anatomical variability is the first step to overcoming intraoperative difficulties and improving treatment success. Due to the abundance of prevalence studies in MnSM, the primary purpose of this study was not to determine the prevalence of C-shaped root and canal anatomy based on tooth position, sex, and age factors or to record the change of canal configurations in the long axis of the tooth. The aim was to identify subjects with unilateral and bilateral 1-rooted MnSM, compare the determined mandibular morphological features with subjects with bilateral 2-root MnSM.

Although CBCT technology has been used since the 1980s, the clinical application has increased in recent decades; it has nondestructive, noninvasive, and provide precise characteristic features of anatomical structures with accurate measurements (21). In addition to multiplanar radiographic images, 3D volumetric data also allows general outline evaluation of the mandible (22). The advantages of CBCT, such as qualitative and quantitative analysis, access to demographic information (age, gender, and race), and details of a bilateral occurrence, have led to its frequent use in observational studies (23). Some cases classified as separate roots on orthopantomogram, or periapical films were C-shaped on CBCT. Similarly, some teeth placed in the C-shaped category on traditional 2-D radiographs showed separate and divergent roots on 3-D analysis (24). A definitive diagnosis is not always possible with 2-D radiographic methods, as root fusion and fine dentine fin can be confused with the trabecular pattern of the alveolar bone (24). With its clinical use for many years, many images have accumulated in data pools. Therefore, 430 patients with complete mandibular dentitions could be analyzed without the need for additional images.

In the current study, the prevalence of 1-root MnSM was 12.79% in the Turkish population similar to other Caucasian populations (2, 8). Genes are important determinants in root development and regulate dental anatomical features, while environmental factors are assumed to be minimally effective (25). However, on the high correlation of this radicular morphotype with ethnicity, Martins et al. (8) drew attention to tracing the genetic ancestry of humanity tens of thousands of years ago. They argued that with prehistoric human migration, Caucasians, Africans, and Asians acquired different phenotypic features, resulting in changes in the shape of jaws and teeth. It is widely believed that root fusion occurs as an adaptation to fit teeth in small jaws. Anthropological studies show changes in dental characteristics, such as prognathism in the jaws, a decrease in jaw length, fewer cusps in the molars, decreased tooth size, and an increase in the agenesis of wisdom teeth in modern humans due to diet change and agricultural variability (18). The development that facilitates survival can have an adaptive character by affecting both the teeth and the surrounding support tissues as pleiotropic (16, 18). This feature results from decreased skeletal support and tooth adaptation. The shape of the mandible is established at the genus phase before dental development is complete. However, skeletal growth and dental development are driven by different growth factors; therefore, there may be relative independence (25). Notably, a study on prehistoric and living

Chinese individuals showed the 1-root/C-shaped root phenomenon with a higher C-shaped frequency of 51.47% in the prehistoric cohort, even higher than today's control group (26). Reports showed heterogeneity in other geographic regions in the ancients as well (27). Thus, the ethnic background thousands of years ago presented a higher rate of C-shaped MnSMs in Mongoloids compared to nowadays.

Of the mandibular features examined in the current study, only the anteroposterior length differed between the groups, and the shortest length was measured in the bilateral 1R group. The null hypothesis was rejected for anteroposterior length and accepted for other features. Other morphological variations were recorded with similar linear measurements in all groups. Regression analysis showed that no independent variable was an explanatory variable for 1-rooted MnSM. Therefore, the anteroposterior length difference should also be interpreted with caution.

The present study had some limitations. The study did not aim to examine the entire mandible, including the ramus, but to evaluate the mandibular features, including the alveolar arch. Therefore, the dentoalveolar basal arch, corpus height, and width in the MnSM region were analyzed. Further studies, including the wisdom teeth of the mandibular arch, are necessary to investigate the effect of 1-rooted MnSM. Because wisdom teeth are very close to the ramus and reduction in arch length may not affect arch lengths up to MnSM, while the shorter arch length may cause wisdom teeth to remain impacted. Situations in which the post-MnSM region decreases to the distance from the ramus may cause a 1-rooted radicular morphotype of MnSM. Another reason that none of the variables (including sex) examined in the regression analysis were predictive variables could be that the morphology of the entire mandible was not evaluated by including the ramus. Measurements evaluating the overall morphology of the mandible, such as Condylion-Gonion, Gonion-Gnathion, right Condylion-left Condylion, right Gonion-left Gonion, right coronoid process-left coronoid process distances, and Gonial angle, could be evaluated in future studies by including both the ramus and corpus of the mandible because, in addition to the craniofacial structures, there are differences in the arch size and width of the mandible in short, average, and long face types (14). The mandibular gonial angle is greater in the long face type (14). The short face type has a short, broad, square mandible and a wider dental arch (28). Another limitation of the current study was that it targeted only skeletal features and not dental dimensions. Future studies may consider the covariate effect of tooth sizes.

CONCLUSION

The prevalence of 1-rooted MnSM was 12.78%, and C-shaped MnSM was 9.65% in the Turkish population, with higher prevalence in females. Individuals with bilateral 1-rooted MnSM exhibited a shorter anteroposterior length than individuals with bilateral 2-rooted MnSM. The inter-second molar width, arch perimeter length, arch breadth, height, and width of the corpus in the MnSM region were similar in all groups. None of the traits examined was a predictive variable for 1-rooted MnSM.

Disclosures

Conflict of interest: The authors deny any conflict of interest.

Ethics Committee Approval: This study was approved by The Faculty of Medicine Clinical Trials Ethics Committee, Akdeniz University (Date: 25/05/2022, Number: KAEK-381).

Peer-review: Externally peer-reviewed.

Financial Disclosure: This study did not receive any financial support.

REFERENCES

- Martins JNR, Marques D, Mata A, J Caramês. Root, and root canal morphology of the permanent dentition in a Caucasian population: a cone-beam computed tomography study. *Int Endod J* 2017; 50(11):1013–26.
- von Zuben M, Martins JNR, Berti L, Cassim I, Flynn D, Gonzalez JA, et al. Worldwide prevalence of mandibular second molar C-shaped morphologies evaluated by cone-beam computed tomography. *J Endod* 2017; 43(9):1442–7. [\[CrossRef\]](#)
- Kim SY, Kim BS, Kim Y. Mandibular second molar root canal morphology and variants in a Korean subpopulation. *Int Endod J* 2016; 49(2):136–44.
- Zheng Q, Zhang L, Zhou X, Wang Q, Wang Y, Tang L, et al. C-shaped root canal system in mandibular second molars in a Chinese population evaluated by cone-beam computed tomography. *Int Endod J* 2011; 44(9):857–62. [\[CrossRef\]](#)
- Aydin H, Mobaraki S. Comparison of root and canal anatomy of taurodont and normal molar teeth: a retrospective cone-beam computed tomography study. *Arch Oral Biol* 2021; 130:105242. [\[CrossRef\]](#)
- Aydin H. Analysis of root and canal morphology of fused and separate rooted maxillary molar teeth in Turkish population. *Niger J Clin Pract* 2021; 24(3):435–42. [\[CrossRef\]](#)
- Aydin H. Correlations between additional roots in maxillary second molars, maxillary first premolars, mandibular first molars and mandibular first premolars: a retrospective cone-beam computed tomography analysis. *Odontology* 2022; 110(3):584–95. [\[CrossRef\]](#)
- Martins JNR, Marques D, Silva EJNL, Caramês J, Mata A, Versiani MA. Prevalence of C-shaped canal morphology using cone beam computed tomography - A systematic review with meta-analysis. *Int Endod J* 2019; 52(11):1556–72. [\[CrossRef\]](#)
- Fan B, Cheung GS, Fan M, Gutmann JL, Bian Z. C-shaped canal system in mandibular second molars: part I-Anatomical features. *J Endod* 2004; 30(12):899–903. [\[CrossRef\]](#)
- Mashyakhly MH, Chourasia HR, Jabali AH, Bajawi HA, Jamal H, Testarelli L, et al. C-shaped canal configuration in mandibular premolars and molars: Prevalence, correlation, and differences: an *in vivo* study using cone-beam computed tomography. *Niger J Clin Pract* 2020; 23(2):232–9.
- Fan B, Min Y, Lu G, Yang J, Cheung GSP, Gutmann JL. Negotiation of C-shaped canal systems in mandibular second molars. *J Endod* 2009; 35(7):1003–8.
- al-Rafee MA, Fayyad MA. Failure of dental bridges. I. Age and sex of patients and distribution of replaced and abutment teeth. *J Oral Rehabil* 1996; 23(4):280–2. [\[CrossRef\]](#)
- Park SJ, Leesungbok R, Song JW, Chang SH, Lee SW, Ahn SJ. Analysis of dimensions and shapes of maxillary and mandibular dental arch in Korean young adults. *J Adv Prosthodont* 2017; 9(5):321–7. [\[CrossRef\]](#)
- Swasty D, Lee J, Huang JC, Maki K, Gansky SA, Hatcher D, et al. Cross-sectional human mandibular morphology as assessed *in vivo* by cone-beam computed tomography in patients with different vertical facial dimensions. *Am J Orthod Dentofacial Orthop* 2011; 139:e377–89. [\[CrossRef\]](#)
- Hikita Y, Yamaguchi T, Tomita D, Adel M, Nakawaki T, Katayama K, et al. Relationship between tooth length and three-dimensional mandibular morphology. *Angle Orthod* 2018; 88(4):403–9. [\[CrossRef\]](#)
- Le Cabec A, Kupczik K, Gunz P, Braga J, Hublin JJ. Long anterior mandibular tooth roots in Neanderthals are not the result of their large jaws. *J Hum Evol* 2012; 63(5):667–81. [\[CrossRef\]](#)
- Hossain MZ, Munawar KM, Rahim ZH, Bakri MM. Can stature be estimated from tooth crown dimensions? A study in a sample of South-East Asians. *Arch Oral Biol* 2016; 64:85–91. [\[CrossRef\]](#)
- Anderson BL, Thompson GW, Popovich F. Evolutionary dental changes. *Am J Phys Anthropol* 1975; 43(1):95–102. [\[CrossRef\]](#)
- Suk KE, Park JH, Bayome M, Nam YO, Sameshima GT, Kook YA. Comparison between dental and basal arch forms in normal occlusion and Class III malocclusions utilizing cone-beam computed tomography. *Korean J Orthod* 2013; 43(1):15–22. [\[CrossRef\]](#)
- Cooke HG, Cox FL. C-shaped canal configurations in mandibular molars. *J Am Dent Assoc* 1979; 99(5):836–9. [\[CrossRef\]](#)
- Baumgaertel S, Palomo JM, Palomo L, Hans MG. Reliability and accuracy of cone-beam computed tomography dental measurements. *Am J Orthod Dentofacial Orthop* 2009; 136(1):19–25. [\[CrossRef\]](#)
- Aydin H. Relationship between crown and root canal anatomy of four-rooted maxillary molar teeth. *Aust Endod J* 2021; 47(2):298–306.
- Aydin H, Çiloğlu Ö. Relationship between root canal merging and presence of C-shaped canal in fused rooted maxillary molar teeth. *Braz Dent Sci* 2022; 25(2):e2964. [\[CrossRef\]](#)
- Sinanoglu A, Helvacioğlu-Yigit D. Analysis of C-shaped canals by panoramic radiography and cone-beam computed tomography: Root-type specificity by longitudinal distribution. *J Endod* 2014; 40(7):917–21.
- Coquerelle M, Bookstein FL, Braga J, Halazonetis DJ, Weber GW, Mitteroecker P. Sexual dimorphism of the human mandible and its association with dental development. *Am J Phys Anthropol* 2011; 145(2):192–202.
- Ren HY, Zhao YS, Yoo YJ, Zhang XW, Fang H, Wang F, et al. Mandibular molar C-shaped root canals in 5th millennium BC China. *Arch Oral Biol* 2020; 117:104773. [\[CrossRef\]](#)
- Ceperuelo D, Lozano M, Duran-Sindreu F, Mercadé M. Root canal morphology of Chalcolithic and early bronze age human populations of El Mirador Cave (Sierra de Atapuerca, Spain). *Anat Rec (Hoboken)* 2014; 297(12):2342–8. [\[CrossRef\]](#)
- Tsunori M, Mashita M, Kasai K. Relationship between facial types and tooth and bone characteristics of the mandible obtained by CT scanning. *Angle Orthod* 1998; 68(6):557–62.