

The Study and Relevance of Pulp Chamber Anatomy in Endodontics – A Comprehensive Review

 Hany Mohamed Aly AHMED,¹  Thomas Gerhard WOLF,²  Giampiero ROSSI-FEDELE,³
 Paul Michael Howell DUMMER⁴

¹Department of Restorative Dentistry, Universiti Malaya, Faculty of Dentistry, Kuala Lumpur, Malaysia

²Department of Restorative, Preventive and Pediatric Dentistry, University of Bern, School of Dental Medicine, Luzern, Switzerland

³Adelaide Dental School, Adelaide University, Adelaide, Australia

⁴College of Biomedical and Life Sciences, School of Dentistry, Cardiff University, Cardiff, United Kingdom

ABSTRACT

With the ever-increasing understanding of tooth anatomy, there is a renewed focus on the pulp chamber as an important component of the root canal system. For example, the pulp chamber is of critical relevance during diagnostic procedures such as pulp sensibility tests, deep caries removal, vital pulp treatments, access cavity preparation, tooth whitening, tooth restoration as well as methods for examining the floor of the pulp chamber to aid the detection of root canal orifices or the presence of perforations and cracks. The more recent concept of minimal invasive endodontics has also created a need to understand better the anatomy of the pulp chamber. The purpose of this article is to discuss the research methods used to study pulp chamber anatomy and the significance of the pulp chamber in endodontic research and clinical practice. In addition, directions for future research are emphasised.

Keywords: Critical analysis, coronal pulp tissue, pulp chamber anatomy, pulp chamber floor, pulp horn, review

HIGHLIGHTS

- Similar to roots and canals, considerable research, using a wide range of laboratory and clinical methods, has been undertaken on the anatomy of the pulp chamber in the human dentition.
- The significance of pulp chamber anatomy is becoming more evident with the recent trends for minimal invasive endodontics including vital pulp therapy and modern access cavity preparation techniques.
- The study of the 2D and 3D morphological features of the pulp chamber including the pulp horns in different tooth types, requires further investigations.

INTRODUCTION

Accurate diagnosis and effective dental treatment require a thorough knowledge of tooth anatomy. The pulp is the soft tissue encapsulated within the space of the crown and root often referred to as the root canal system or pulp cavity (1). The root canal system has a coronal portion (pulp chamber) and a root portion (root canal), which are surrounded by dentine (coronal and radicular) (1). The dental pulp within this

cavity originates from the mesenchyme, and has a range of functions involving formative, nutritive, sensory, and defensive mechanisms (1, 2).

Understanding the anatomy of the pulp chamber and coronal pulp tissue is essential as it has a substantial impact on diagnosis and treatment (3). The shape, size and position of the pulp chamber and the type, thickness and quality of the hard tissues surrounding

Please cite this article as: Ahmed HMA, Wolf TG, Rossi-Fedele G, Dummer PMH. The Study and Relevance of Pulp Chamber Anatomy in Endodontics – A Comprehensive Review. *Eur Endod J* 2024; 9: 18-34

Address for correspondence:
Hany Mohamed Aly Ahmed
Department of Restorative
Dentistry, Universiti Malaya,
Faculty of Dentistry, Kuala Lumpur,
Malaysia
E-mail:
hanyendodontist@um.edu.my

Received August 01, 2023,
Accepted August 25, 2023

Published online: November 22, 2023
DOI 10.14744/eej.2023.76598

This work is licensed under
a Creative Commons
Attribution-NonCommercial
4.0 International License.



it have an impact on a range of diagnostic and treatment modalities. For example, pulp tissue response to various diagnostic procedures, such as pulp sensibility tests (4–7). It also has a specific influence and impact on a wide range of dental procedures in operative dentistry (8, 9), root canal treatment procedures (10), and prosthodontic procedures (such as crown preparations and fabrication of endocrowns) (11, 12). Failure to appreciate the anatomical variations and the relevance of the quality and quantity of the hard tissues surrounding the pulp chamber can lead to diagnostic inaccuracy, procedural errors and treatment failure (6, 9, 10, 13).

With the ever-increasing understanding of the tooth anatomy, there is a renewed focus on the pulp chamber as an important component of the root canal system. This article discusses the research methods used to study pulp chamber anatomy, and explores its significance in endodontic research and clinical practice. In addition, it discusses directions for future research.

The Study of Pulp Chamber Anatomy

Similar to roots and canals, considerable research has been undertaken on the anatomy of the pulp chamber in the human dentition. The description of pulp chamber anatomy and its physiological age changes together with responses of the coronal pulp tissues to occlusal wear and carious lesions have been discussed in seminal studies (14–16). This section discusses the different methods used to study the anatomy of the pulp chamber.

Staining methods

In contrast to root canal anatomy, staining is not a common method to study pulp chamber anatomy because an access cavity is required for injection of the dye, thus compromising the study of the pulp chamber roof and horns. However, staining methods (with or without decalcification and clearing procedures) have been used to study the prevalence of chamber canals (also named furcation canals, inter-radicular canals) in the pulp chamber floor which exit in the root furcation of multi-rooted teeth (17–23).

In general, there is a degree of controversy over the incidence of chamber canals using staining and clearing methods. A number of studies reported the presence of chamber canals in premolar and molar teeth, with the highest percentage in first molars (17, 20), reaching up to 13% in mandibular first molars (17); this was consistent with one study on primary molars (24). However, other studies did not identify furcation canals (18, 22). Indeed, staining followed by decalcification has technical limitations such as inconsistent demineralisation for samples of different weight/volume and sample loss because of cracking, deterioration and pulp dissolution after immersion in strong acids (22, 25).

The staining method has also been applied for detection of chamber canals without decalcification and clearing procedures (19, 21, 23). This was performed by applying a vacuum to the external furcation area after staining of the pulp chamber (19), or storage of the teeth in a dye for one week followed by sectioning the crown to examine the pulp chamber floor (21),

or by staining the pulp chamber followed by centrifugation and sectioning (23). Such sectioning methods after staining allows the differentiation of patent and blind (diverticulum) chamber canals (23). However, being an invasive method, it may not reveal fine details of the chamber canals compared to micro-computed tomography (micro-CT). In addition, the loss of tooth structure (using 0.2 mm diamond strips) when cutting the teeth by this invasive method is comparatively greater than the section thickness itself (0.145 mm), which is a clear disadvantage of this method. Compared to micro-CT, fine details of chamber canals may therefore be lost and not visible (23).

Sectioning method and 2D radiographic imaging

Researchers examined secondary dentine formation and its impact on the size of the pulp chamber using 2D radiographic imaging and ground sectioning (26–30), and they reported significant reduction of the pulp chamber space by age. From a total of 252 sectioned permanent human teeth with an age range from 28 to 37 years, Stambaugh & Wittrock (11) examined the relation of the pulp chamber to the external tooth surface, and reported findings relevant for crown preparations and pin-retained restorations.

Using bitewing radiographic images, Shaw and Jones (8) explored the morphological measurements (height and mesio-distal width) of the pulp chamber in sound, carious and restored teeth in 259 school children at the age of 14 years compared with their radiographic images taken at the age of 11 years. Results revealed a significant reduction in the height of the pulp chamber compared to the mesio-distal width in mandibular first molars, which was explained by the increase of the pulp floor thickness. One study examined the height of pulp horns, chamber width at the cemento-enamel junction (CEJ) and area of the chamber on bitewing radiographic images in 121 individuals of different ethnic groups. Teeth with large crowns were associated with large pulp chambers, which also varied amongst different populations (3). It was also found that teeth restored with occlusal and proximal restorations had significantly smaller pulps (3), in contrast to the findings reported by Shaw and Jones (8).

The pulp chamber has been the focus for studies on age estimation in forensic science based on linear measurements of the pulp chamber width and height on bitewing radiographic images (31), distances from the CEJ to the tip of the highest pulp horn (32), and height ratios of the pulp chamber, crown and root trunk (33) on digital panoramic images. A number of studies reported different morphological measurements of the pulp chamber in a range of tooth types using either manually processed radiographic films (34), or digital periapical radiographs (35, 36), to provide clinical recommendations during access cavity preparations. Figure 1 sets out the various measurements that can be obtained from 2D bitewing radiographic views.

A considerable volume of research has been performed to study the landmarks of the pulp chamber floor and the location of root canal orifices (37–39). Acosta Vigouroux and Trugeda Bosaans (37) examined the anatomy of the pulp chamber floor in 134 sectioned maxillary first molars, and categorized them into several types according to the grooves between root

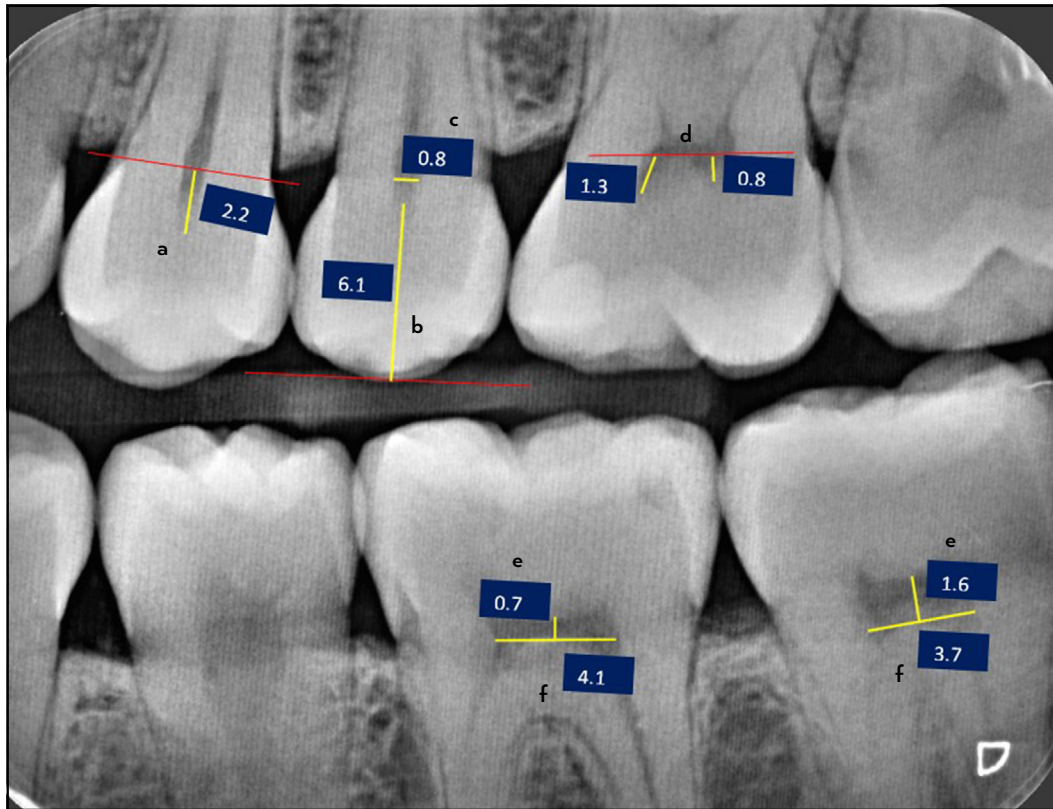


Figure 1. Morphological measurements (in millimetres) related to the pulp chamber using a 2D bitewing radiographic image – (a) Distance between the level of CEJ to highest pulp horn. (b) Distance from occlusal plane to pulp horn area. (c) Mesio-distal width of the pulp chamber at CEJ of a single-rooted tooth. (d) Distance from lowest level of the pulp roof to the highest point of the pulp horns. (e) Distance from highest point of pulp chamber floor to the lowest point of the pulp roof. (f) Mesio-distal width of the pulp chamber at level of the highest point of the pulp chamber floor in mandibular molars

CEJ: Cemento-enamel junction

canal orifices (Y-shaped, 7-shaped, etc. according to the depth of grooves and shapes). With a concept similar to that proposed by Acosta Vigouroux and Trugeda Bosaans (37), Pawar and Singh (39) proposed a classification to describe the morphology of the pulp chamber floor in maxillary and mandibular molars using alphabetical letters reflecting the lines joining the canal orifices (K, Y, I, etc. for maxillary molars, H, Y, I, etc. for mandibular molars). Krasner and Rankow (38) examined the pulp chambers of 500 sectioned teeth, and proposed laws to

identify the anatomical landmarks of the pulp chamber and their relation to the crown as well as the anatomy of the pulp chamber floor and locations of root canal orifices (Table 1).

Scanning electron microscopy

The furcation area of primary molars is of special significance because of its close anatomical relationship with the follicle of the permanent successor, and thus, it is one of the main pathways for the development of pathological bone changes

TABLE 1. Laws proposed by Krasner and Rankow (38) for pulp chamber anatomy

Law	Definition
Law of centrality	The floor of the pulp chamber is always located in the center of the tooth at the level of the CEJ.
Law of concentricity	The walls of the pulp chamber are always concentric to the external surface of the tooth at the level of the CEJ.
Law of the CEJ	The CEJ is the most consistent, repeatable landmark for locating the position of the pulp chamber.
Law of symmetry 1	Except for maxillary molars, the orifices of the canals are equidistant from a line drawn in a mesial-distal direction, through the pulp chamber floor.
Law of symmetry 2	Except for the maxillary molars, the orifices of the canals lie on a line perpendicular to a line drawn in a mesial-distal direction across the center of the floor of the pulp chamber.
Law of colour change	The colour of the pulp-chamber floor is always darker than the walls.
Law of orifice location 1	The orifices of the root canals are always located at the junction of the walls and the floor.
Law of orifice location 2	The orifices of the root canals are located at the angles in the floor-wall junction.
Law of orifice location 3	The orifices of the root canals are located at the terminus of the root developmental fusion lines.

CEJ: Cemento-enamel junction

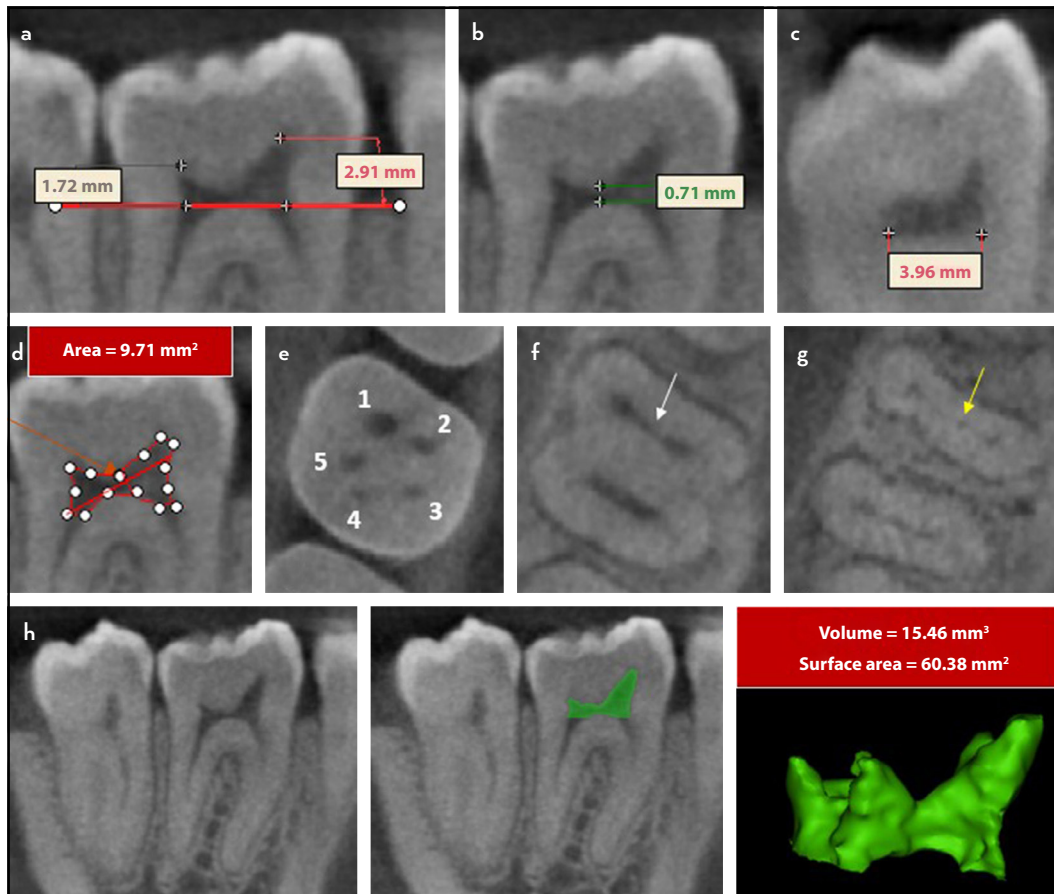


Figure 2. 2D and 3D morphological measurements of the pulp chamber in a mandibular first molar scanned using CBCT. (a) Distance between highest point of the pulp chamber floor and highest point of the pulp horn (sagittal view). (b) Distance between lowest point of the roof and highest point of the pulp chamber floor. (c) Bucco-lingual width of the pulp floor. (d) Pulp chamber area. (e) Number of the pulp horns (five). (f, g) Association between the presence of isthmus in the pulp chamber floor between the mesio-buccal and mesio-lingual canals (f) with the occasion of middle mesial canals (g). (h) Volume and surface area of a 3D reconstructed image of the coronal pulp tissue from a CBCT scan

CBCT: Cone beam computed tomography

through chamber canals (40, 41). Scanning electron microscopy (SEM) has been used to study the furcation in primary molars (40, 42–45), and permanent molars (43, 46–48). Nonetheless, since SEM provides only topographic information of the pulp chamber floor (in addition to 2D measurements such as diameter of the chamber canal orifice), it cannot identify the type of chamber canals (either patent, blind or loop) (45).

Magnetic resonance imaging

Lockhart et al. (49) applied magnetic resonance imaging (MRI) (as a less invasive approach compared to radiographic methods) for accurate presentation of the tooth, pulp chamber and canal anatomy. Sustercic and Sersa (50) presented an accurate 3D visualisation of the shape and size of pulp chamber and canal anatomy. A recent study reported 91 out of 100 root canals in anterior and premolar teeth were successfully scouted after MRI-guided access cavity preparation (51). Such promising results, however, require further validation. Indeed, to date, MRI devices are not available in dental clinics, which also have limitations because of their high cost and longer scanning time compared to CBCT (51).

Cone beam computed tomography

The more recent application of high-resolution 3D cone beam computed tomography (CBCT) imaging for the study of the pulp chamber in clinical settings has been described, such as 2D measurements in axial, coronal and sagittal planes (52), and pulp volume measurements in different age groups (53–55) (Fig. 2). One CBCT study reported an association between the presence of middle mesial canals and anatomic landmarks of the pulp chamber floor (such as presence of isthmuses between mesio-buccal and mesio-lingual canal orifices) in the mesial root of mandibular first molars (56). CBCT has also been used to investigate the prevalence of pulp chamber calcifications/stones in different population groups (57–59) as well as evaluating the morphological features of the pulp chamber in teeth with dental anomalies such as taurodontism (60). Recent studies have examined the application of CBCT to develop navigation systems for locating obliterated root canals through guided drilling into calcified pulp chambers to preserve more tooth tissue compared to conventional manual access cavity preparation (61–63).

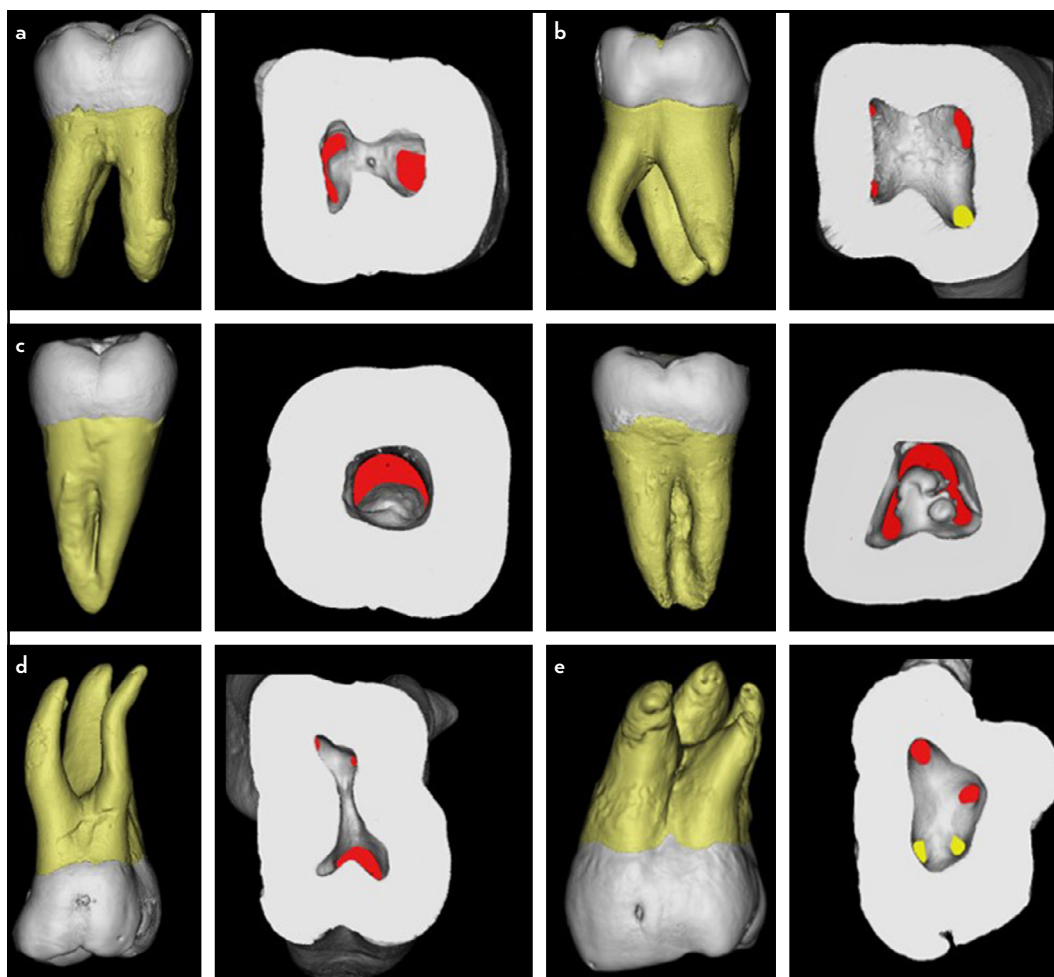


Figure 3. 3D reconstructed images from micro-CT scanned molars showing different anatomical variations of the pulp chamber floor. (a) Double rooted mandibular molar, (b) Three rooted mandibular molar (yellow – orifice of the DL root canal), (c) Variations in the pulp chamber floor of mandibular molars with fused roots and C-shaped canals. (d) Three-rooted maxillary molar, (e) Four-rooted maxillary molar with two palatal roots (yellow – orifices of the palatal canals)

Micro-CT: Micro-computed tomography, DL: Distolingual

Micro-computed tomography

Micro-CT imaging has also been used to investigate pulp chamber anatomy including 2D and volumetric measurement analysis in laboratory studies (9, 64–69). Many of the studies examined the correlation of pulp chamber volumetric measurements with age (64, 65, 67, 69, 70). Despite differences in scanning parameters and methods of interpretation, there is a general agreement that the degree of reduction in the pulp cavity vol-

ume (including horn, orifice and floor regions) from the mean age of 20 to 40 years was greater than that from the 40 to 60 years (64, 65). A recent study developed a new approach for age estimation using micro-CT to analyse the secondary dentine segmented from the primary dentine in the pulp chamber (71).

Micro-CT has also been used to study the pulp chamber floor anatomy in teeth with root and canal anomalies (Fig. 3). Min

TABLE 2. Classification proposed by Min et al. (66) for the pulp chamber floor in teeth with C-shaped canals

Types	Description
Type I	A peninsula-like floor with a continuous C-shaped orifice.
Type II	A buccal, strip-like dentin connection exists between the peninsula-like floor and the buccal wall of the pulp chamber that separates the C-shaped groove into mesial (M) and distal (D) orifices. Sometimes the mesial orifice was separated into a mesio-buccal (MB) and a mesiolingual (ML) orifice by another strip-like dentin between the peninsula-like floor and the mesial wall of the pulp chamber.
Type III	Only one mesial, strip-like dentin connection exists between the peninsula-like floor and the M wall, which separates the C-shaped groove into a small ML orifice and a large MB-D orifice. The MB-D orifice was formed by the merging of the MB orifice and the D orifice.
Type IV	Non-C-shaped floors. One distal canal orifice and one oval or two round mesial canal orifices are present.

et al. (66) investigated the anatomy of the pulp chamber floor in forty-four mandibular second molar teeth with C-shaped canals using micro-CT, and classified them into four types (Table 2). Gu et al. (72) reported differences in the anatomy of pulp chamber floor in double and three-rooted mandibular molars (Fig. 3a, b). They explained the challenges of detecting the distolingual (DL) canal orifice in three-rooted variants as a consequence of the continuous deposition of secondary dentine, and the formation of a dentine shelf on the lingual edge of the DL orifice that prevented direct vision. Similar observations were reported in two micro-CT studies (73, 74) – such morphological variations have an impact on the configurations of access cavity preparations (changing from triangular to trapezoidal). Versiani et al. (75) classified the spatial configurations of the orifices in relation to the pulp chamber floor in four-rooted maxillary molars into four types [type A (irregular quadrilateral), type B (trapezoid-shaped), type C (lozenge-shaped) and type D (kite-shaped)]. Other studies investigated the configuration of the pulp chamber floor in mandibular premolars with three root canals (76), and maxillary molars with three mesio-buccal canals (77).

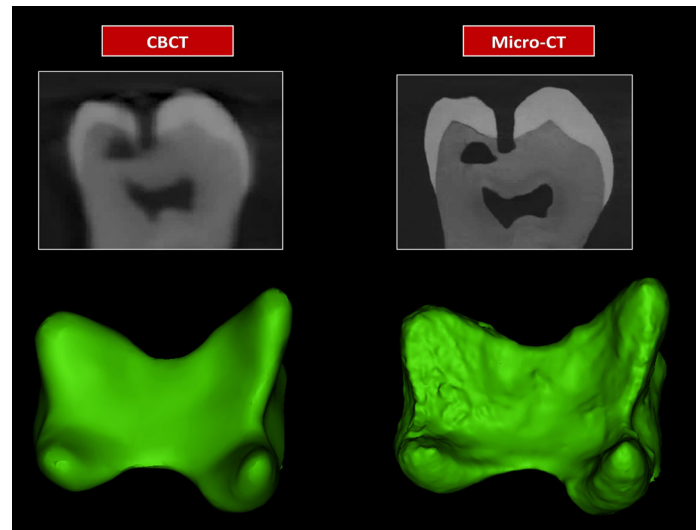


Figure 4. Illustration for the difference between the accuracy of CBCT and micro-CT scans for defining the details of the pulp chamber. For normal pulp chamber sizes, both CBCT and micro-CT can show similar details of the gross morphological features, but micro-CT is able to reveal more detailed topographic features of the pulp chamber compared to CBCT

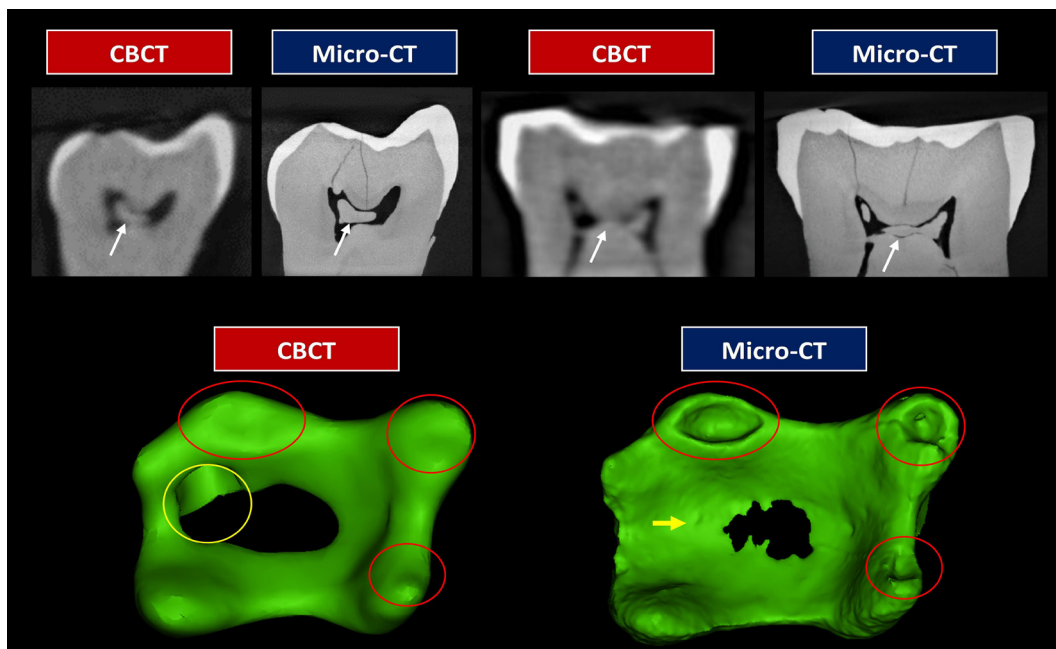


Figure 5. Illustration of the difference between the accuracy of CBCT and micro-CT scans for defining the details of the pulp chamber. First row: 2D images from CBCT and micro-CT scanned mandibular molar. Second row: After 3D reconstruction. The CBCT may not show flattened areas and fine topographic features of the pulp chamber including the pulp horns (red circles) and floor (yellow circle and arrow)

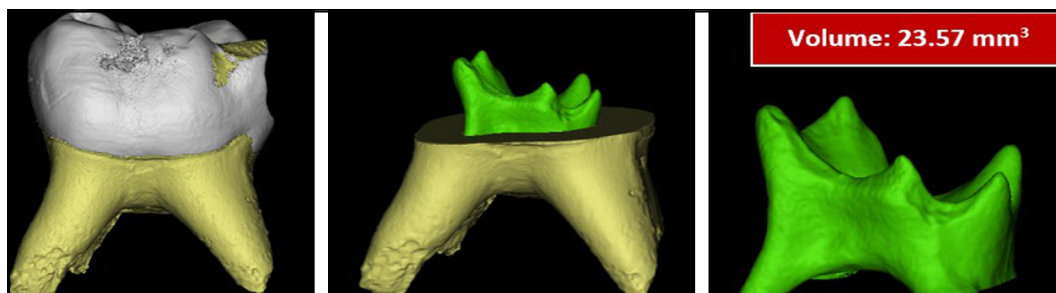


Figure 6. Micro-CT reconstructed images of a deciduous mandibular molar showing the morphological features and volume of the pulp chamber

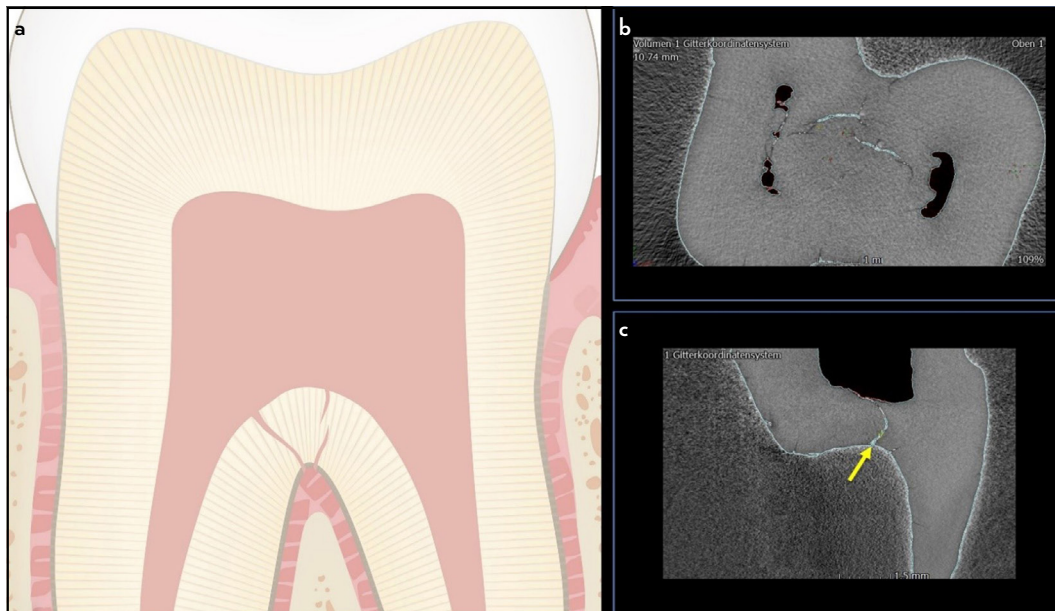


Figure 7. (a) Schematic illustration of the bifurcation (trifurcation) region of a molar showing a patent chamber canal (interradicular canal) and diverticula originating from the pulp chamber floor and the furcation area. (b), (c) Micro-CT scanned mandibular second molar with diverticula and patent chamber canal (yellow arrow)

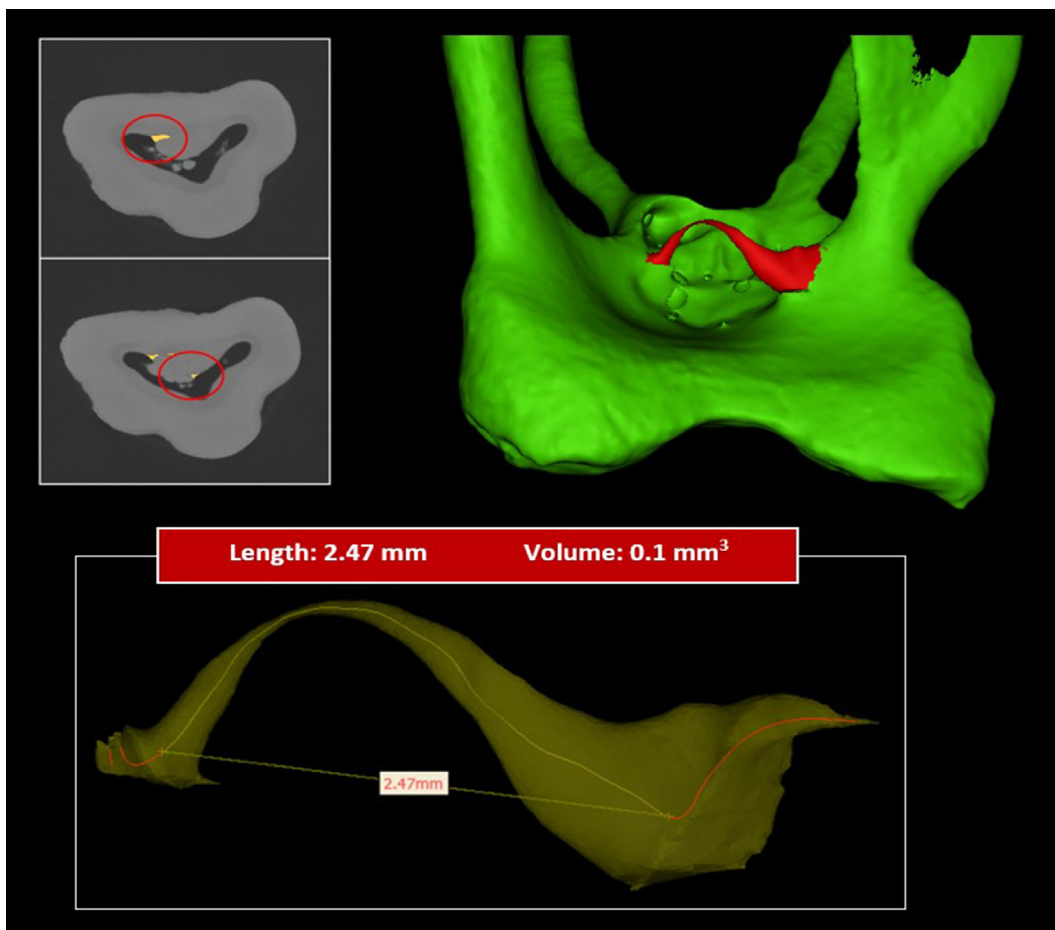


Figure 8. Micro-CT reconstructed images of a maxillary molar with chamber canal (loop type) with 2D (length – along the centreline) and 3D (volume) measurements along the centreline

Because of the high resolution and accuracy of micro-CT compared to other imaging devices, it allows more accurate visualisation of the details of pulp chambers (69, 78),

especially for flattened, narrow spaces in the pulp chamber caused mainly by calcification/pulp stone formation (Fig. 4, 5) (79, 80), along with the continuous deposition of sec-

TABLE 3. Nomenclature for access cavity designs introduced by Silva et al. (91)

Term	Definition
Traditional access cavity	In posterior teeth, complete removal of the pulp chamber roof followed by achieving straight-line access to the canal orifices, with smoothly divergent axial walls, so that all orifices can be seen within the outline form. In anterior teeth, the straight-line access is obtained by removing the pulp chamber roof, the pulp horns, the lingual shoulder of dentine, and further extending the access cavity to the incisal edge.
Conservative access cavity	In posterior teeth, preparation usually starts at the central fossa of the occlusal surface and extends, with smoothly convergent axial walls to the occlusal surface, only as far as necessary to detect the canal orifices, preserving part of the pulp chamber roof. This access type can be also performed with divergent walls (ConsAC.DW). In anterior teeth, this access involves moving the entry point away from the cingulum towards the incisal edge, on the lingual or palatal surface, by creating a small triangular-shape or oval-shape cavity, conserving the pulp horns and the maximum pericervical dentine.
Ultraconservative access cavity	Also known as 'ninja' access, such cavities start out as described in the ConsAC, but with no further extensions, maintaining as much of the pulp chamber roof as possible. In anterior teeth, when there is attrition or a deep concavity in the lingual aspect of the crown, the access can be performed in the middle of the incisal edge, parallel to the long axis of the tooth.
Truss access cavity	It aims to preserve the dentinal bridge between two or more small cavities prepared to access the canal orifice(s) in each root of multi-rooted teeth. In mandibular molars, for example, two or three individual cavities can be created to access the mesial and distal canals.
Caries-driven access cavity	The access to the pulp chamber is performed by removing caries and preserving all remaining tooth structures, including the soffit structure, described as the underside of an architectural feature such as the ceiling, the corner of the ceiling and the wall.
Restorative-driven access cavity	In restored teeth with no caries, access to the pulp chamber is performed by totally or partially removing existing restorations and by preserving all possible remaining tooth structures.

ondary dentine. The 3D reconstruction of the pulp chamber space reflects the morphological features of the coronal pulp tissue, including the body and horns (if present), which varies when the tooth is scanned using micro-CT compared to CBCT (Figs. 4, 5).

The anatomy of the pulp chamber in the primary dentition varies from the permanent counterparts, and the chamber is larger in size in relation to the crown:volume ratio compared to the permanent dentition (81) (Fig. 6). Two micro-CT studies investigated the pulp chamber anatomy in primary molars and reported a wide range of variations in the morphological measurements, size of the chamber in relation to the crown, location and number of the pulp horns as well as the pulp chamber floor. These anatomical features require careful attention to prevent procedural errors such as furcal perforations (45, 82).

A recent micro-CT study investigated the frequency of patent chamber canals (named also as interradicular canals)

and diverticula (defined as blind accessory canals originating from either the pulp chamber or furcation) (Fig. 7), in first and second mandibular and maxillary molars (83); patent chamber canals were observed in 2.8% and 0.3% of the mandibular and maxillary molars, respectively. The frequency of diverticula (originating from the pulp chamber) observed in mandibular molars was 3.3%. 3D reconstructed images from micro-CT scanned teeth provide additional information on the type of chamber canals, which cannot be identified using other methods such as SEM (Fig. 8). Indeed, micro-CT may be compromised by artifacts (in the form of cracks that may look like accessory canals) because of structural changes and storage (25, 83).

Other methods

A number of other methods have also been reported to study the anatomy of pulp chambers such as injection of low-viscosity resin material to develop a replica of the pulp chamber (84). Another study introduced low-viscos-

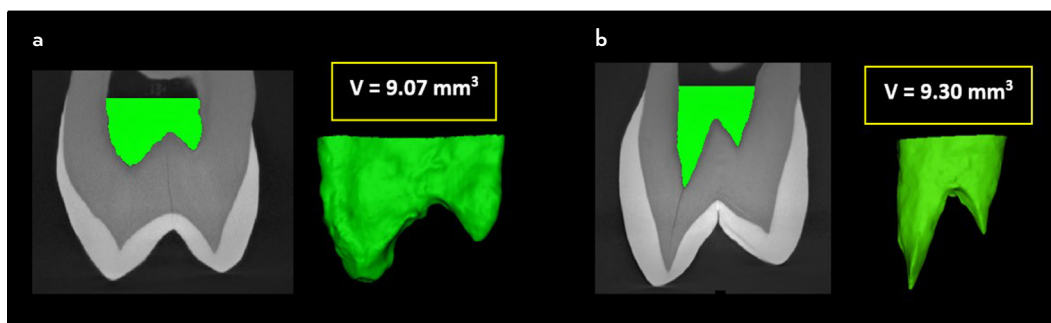


Figure 9. Micro-CT reconstructed images showing pulp chambers in double-rooted maxillary premolars with close volumetric values but with different pulp horn anatomy – the pulp horns in (b) are more prominent and pointed compared to the pulp horns in (a)

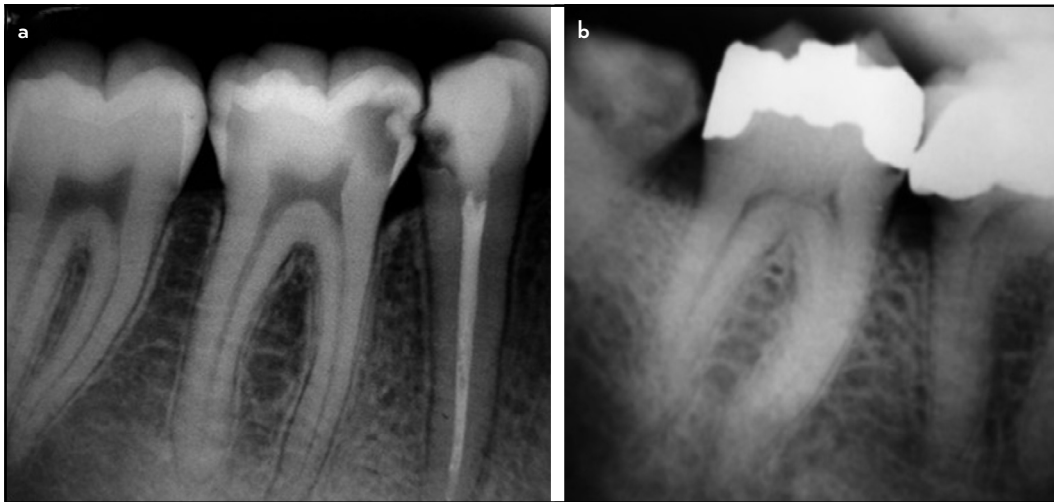


Figure 10. Examples of mandibular molars with (a) prominent and (b) receded pulp horns identified on periapical radiographs

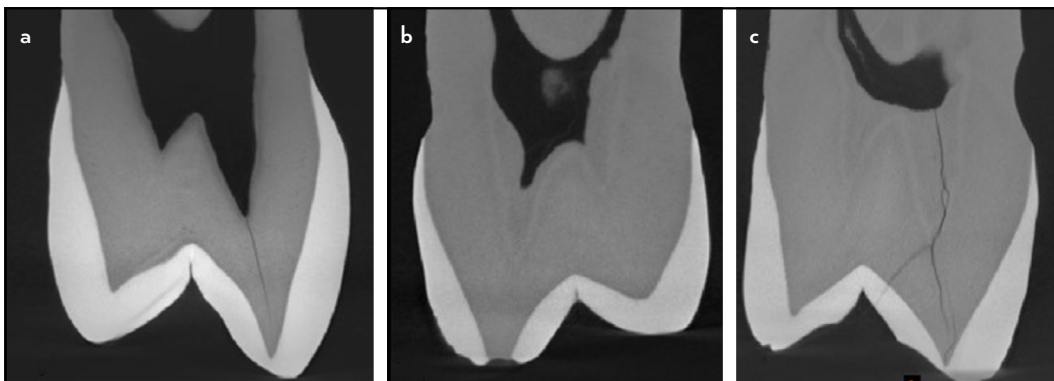


Figure 11. Different forms of pulp chamber sizes in maxillary premolars. During access cavity preparation, the operator would feel the dropping effect of the bur more in (a) and (b) compared to (c)

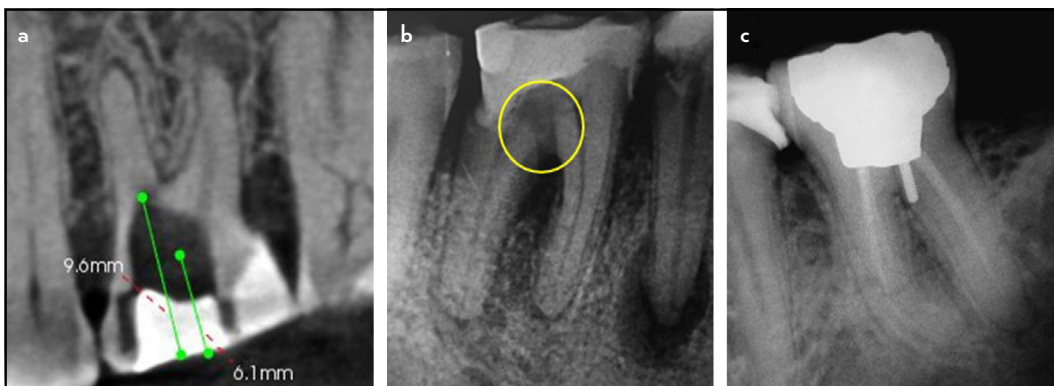


Figure 12. Procedural errors that can occur from inadequate understanding of pulp chamber anatomy and alignment of the tooth. (a) Gouging of the pulp chamber floor. (b) Perforation of the pulp chamber floor. (c) Improper post placement gouging the distal aspect of the pulp chamber floor

ity latex material into the pulp chamber to investigate the frequency of chamber canals (85). Swept-Source Optical Coherence Tomography (a 3D non-radiating, non-invasive imaging technique that generates cross-sectional images of the internal microstructure of biological tissues and materials) was also used to study the anatomy of the pulp chamber and horns (86).

Significance of the Pulp Chamber in Current Endodontic Research

The enamel and coronal dentine are subject to high masticatory forces. Therefore, the roof of the pulp chamber is an important structural component that distributes occlusal forces (87). The last two decades have witnessed a growing interest on conservative access cavity designs (88–94). This trend was mainly based

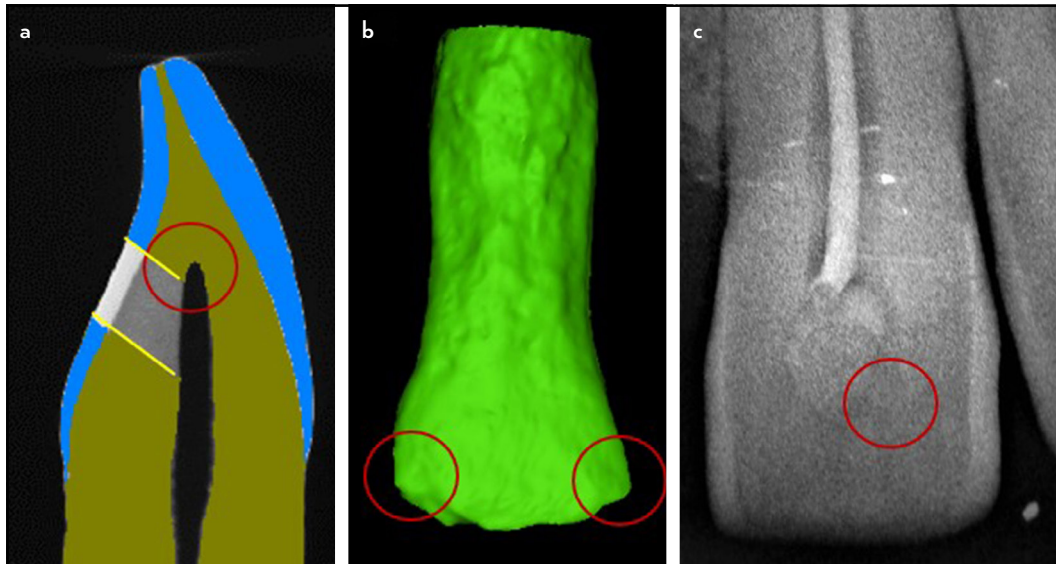


Figure 13. (a-c) Inadequate access cavity preparations may leave pulp tissues below unroofed pulp extensions (or horn areas), which are commonly present in the mesial and distal aspects of incisors (b, c)

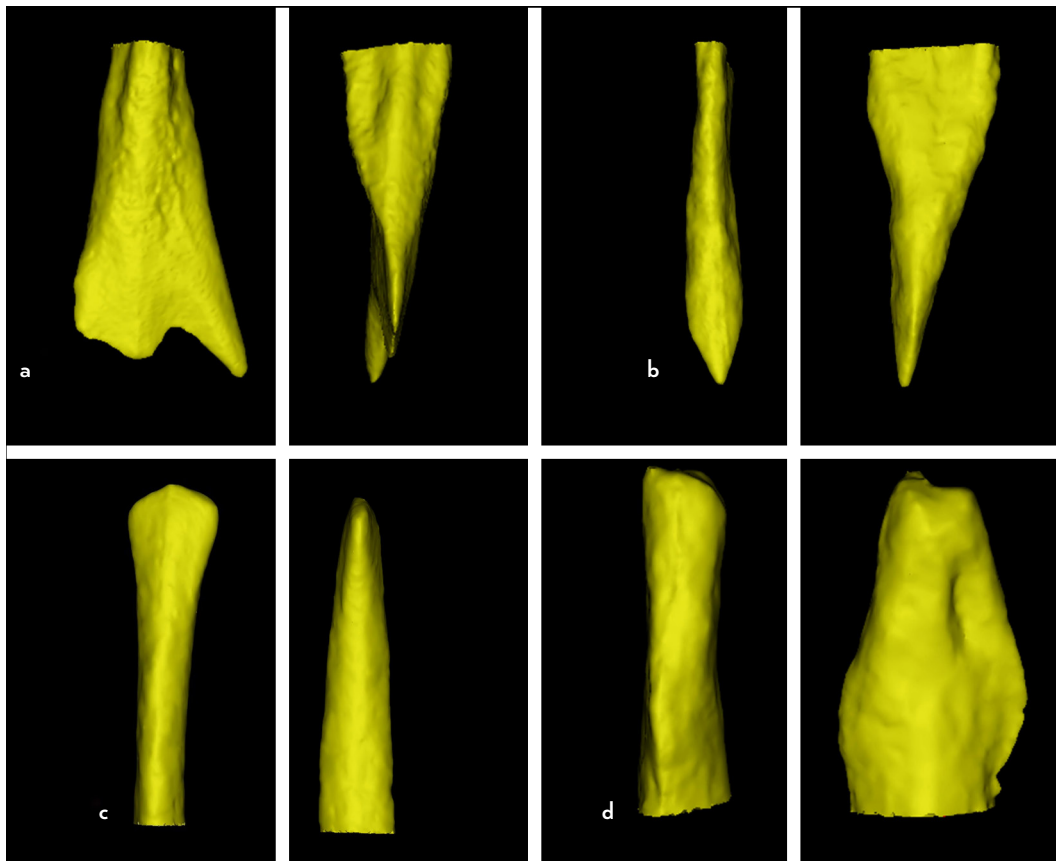


Figure 14. Reconstructed images of micro-CT scanned teeth showing different morphological variations (mesio-distal and bucco-lingual views) of the pulp chamber anatomy in the anterior dentition (a) Maxillary incisor, (b) Maxillary canine, (c) Mandibular incisor, (d) Mandibular canine

on the assumption that preservation of tooth structure during endodontic access cavity preparation would improve the load capacity of teeth (88, 89). However, a number of concerns has been discussed in a recent systematic review, especially in relation to very small access cavity designs such as Truss-access and ultra-conservative access cavity designs (89). Silva and colleagues

(91) introduced a nomenclature for access cavity designs, and divided them into six main categories as shown in Table 3. A similar list of definitions has been presented in another report (95).

With regards to the pulp chamber, studies investigated the ability of different access cavity designs to allow the removal

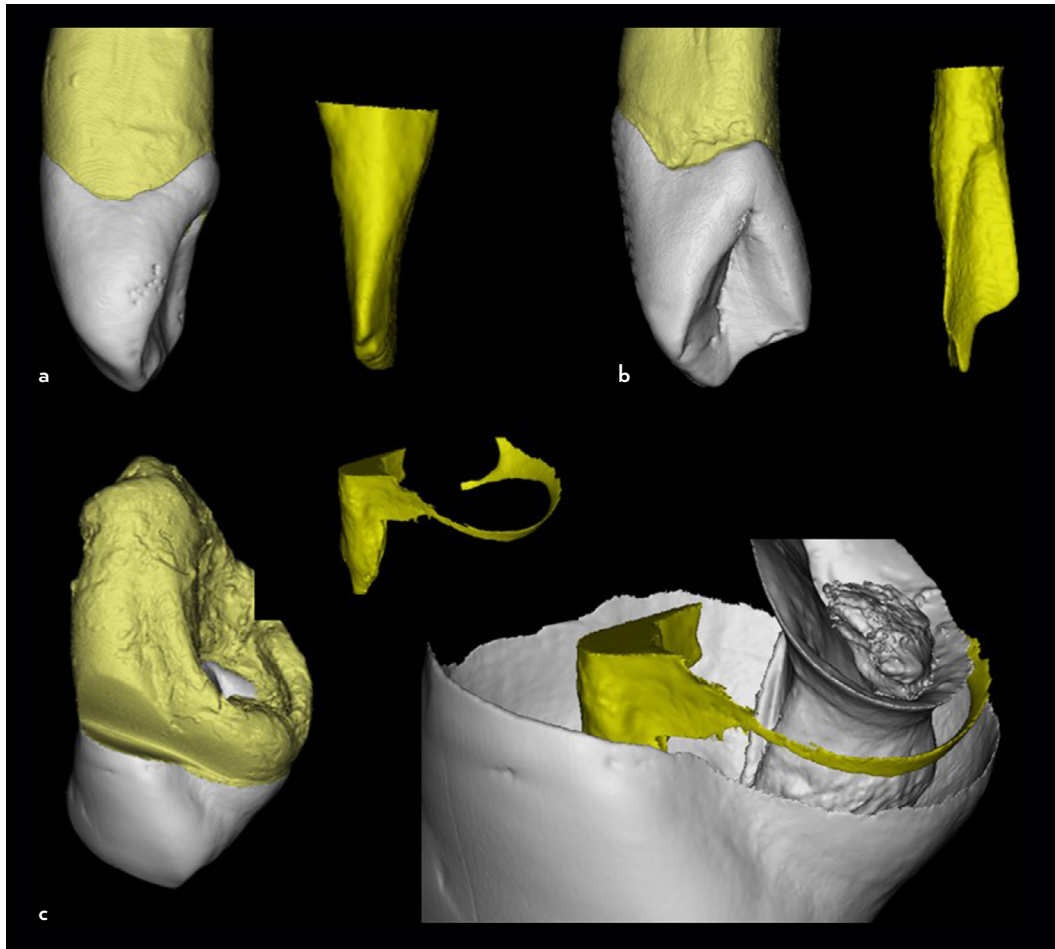


Figure 15. Variations in the pulp chamber anatomy in teeth with dental anomalies. (a) Normal maxillary incisor, (b) Maxillary incisor with Dens Evaginatus (talon cusp), (c) Maxillary incisor with type III Dens Invaginatus

of either remaining tissues in the pulp chamber (96) and root canal filling materials from the pulp chamber space (92, 97, 98) as well as the presence of voids in the coronal restoration (98). One study found that more pulp tissue remnants were observed in the pulp chamber of mandibular molars with Truss access cavies compared to traditional and conservative access cavity designs (96). Another study found that ultraconservative access cavities complicated the cleaning of the pulp chamber in maxillary premolars resulting in residual root canal filling material near the pulp horn areas and pulp chamber walls (92, 98), and between layers of the post-endodontic restorative material (98), in addition to void formation in the coronal restoration (93, 98). Apart from that, minimally invasive access cavities may make accurate mapping of the pulp chamber floor impossible, thus increasing the chances for missed canals (94), especially for ultraconservative access cavities in maxillary molars with second mesio-buccal canals (99). With the technological advances and evolving concepts for minimal invasive treatment approaches, up to now, there is no clinical evidence to support the concept that minimally invasive access cavities improve the long-term survival of root filled teeth.

It is important to highlight that the volume of the pulp chamber and root canal(s) (92, 100) and dimensions (96, 97),

have been used for standardisation of experimental samples in several studies related to minimally invasive access preparations. Using such methodological measurements for sample selection would reduce the potential confounding factors related to the variation in pulp chamber anatomy in the same tooth type. However, in some situations, teeth with similar pulp chamber volumes may have different pulp horn anatomy (Fig. 9). Further studies are needed to examine whether pulp horn anatomy (a common area for pulp tissue remnants and root canal filling material) would also have an impact on studies assessing pulp tissue remnants associated with access cavity designs, void formation in post-endodontic restorations and coronal discolouration caused by restorative materials as well as stress distribution and fracture resistance of the crown.

Significance of the Pulp Chamber in Clinical Endodontics

Diagnostic procedures

The pulp horns within the pulp chamber have numerous neural elements (101), that correspond to the incisal edge or major cusps of the crown in anterior and posterior teeth, respectively (2). In general, pulp horns are more prominent in young compared to older patients (2). Despite the inherent limitations of 2D imaging, several morphological features can

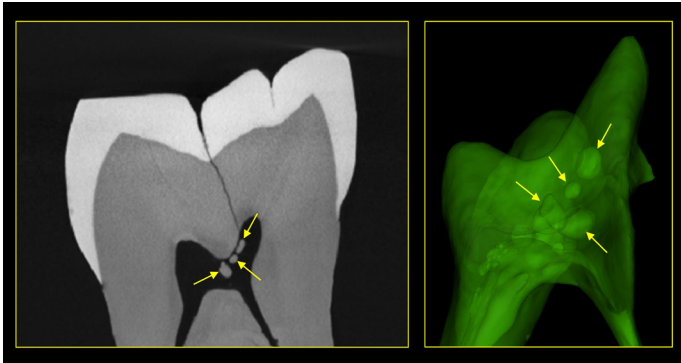

Figure 16. 2D micro-CT scanned and 3D reconstructed images of a mandibular molar with pulp stones (yellow arrows)

be identified on periapical radiographs such as proximity of the pulp horns to the external tooth surface (Fig. 10), which may have an impact on the location where pulp sensibility tests (thermal and electric pulp testing) should be applied (4–7), or the expected response since teeth with calcified pulp horns in pulp chambers with reduced size may have a delayed response in teeth with vital pulps compared to teeth with normal pulp chamber size (6, 102).

Access cavity preparation

Understanding the anatomy of the pulp chamber has other important clinical consideration. If the pulp chamber space is large, during access cavity preparation, the operator will have the tactile feedback of the bur entering the pulp chamber (usually the depth is pre-measured from the pre-operative radiographic view) (13) (Fig. 11). However, if the pulp chamber is calcified, the operator may not have the necessary tactile feedback to be aware of the position of the tip of the bur potentially leading to unnecessary gouging of the walls and/or floor, or even perforation (13) (Fig. 12). This is more evident in elderly patients (103). Therefore, the bur should only penetrate to a pre-measured distance, and if the chamber is not found, the access should be extended under magnification with good illumination to look for signs of the chamber (13), with the bur directed parallel to the long axis of the tooth to prevent lateral perforation (104), which would complicate the treatment and outcome (105). The supplemental use of ultrasonic tips can also be helpful to reduce the risk of perforations, as well as the use of burs with a non-cutting tip.

Exploration of the pulp chamber floor

Inspection of the pulp chamber floor under magnification assisted by illumination and exploration using DG16 explorers are important for identifying the configuration of the pulp floor, which facilitates the detection of the root canal orifices. The operator has to be aware of the different anatomical variations in the pulp chamber floor in normal teeth and teeth with anomalies. On rare occasions, patent chamber canals can also be identified, instrumented and filled similar to root canals (106).

Tooth discolouration

Tooth discolouration is one possible consequence if the extension of the access cavity is inadequate when remnants of pulp tissues are left in the horn area (107) (Fig. 13). The pulp horn varies morphologically in every tooth type, which also varies by

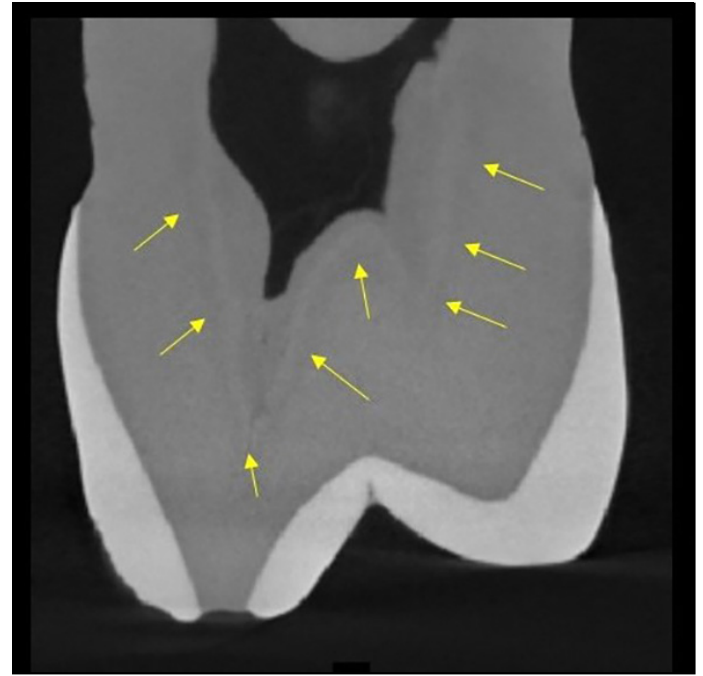


Figure 17. A micro-CT scanned maxillary premolar showing the outline of the secondary dentine from the primary dentine and reduced space of the pulp chamber

age and progression of dental caries (2, 6). Therefore, successful detection, with the aid of a contra-angled (cow-horn) probe/explorer, and removal of any “catch” from the roof of the pulp chamber [using a round bur in pulling motions (for blunt pulp horn areas) or ultrasonic tips (for pointed pulp horn areas)] will ensure complete removal of pulp tissue, particularly from the mesial and distal pulp extensions (or horns) in maxillary incisors which are also a location for sealer remnants that can also add to the discolouration (13, 107, 108) (Fig. 13). In addition, the adaptation of the final tooth-coloured restoration to this area could be compromised. Therefore, adequate knowledge of pulp horn and coronal extensions in different tooth types is important to ensure appropriate diagnostic and treatment procedures.

Minimal invasive procedures

Recent years have seen an increased interest in diagnostic procedures, and new concepts have been introduced for the classification of pulp inflammation with the aim of relating diagnosis to specific minimally invasive vital pulp treatments. The focus has been on the removal of the irreversibly inflamed pulp tissue only, thereby leaving the uninflamed or reversibly inflamed tissue in place, which then has the potential to heal if it is managed correctly (109). With accurate diagnosis, direct pulp capping and partial pulpotomy procedures can be performed safely by the dental practitioner. However, carrying out full pulpotomy procedures requires meticulous understanding of the pulp chamber anatomy, which varies from tooth to tooth (8, 34–36, 38), and also requires adequate training of the operator (110). Practitioners should be aware of the alignment of teeth, pulp chamber outline, size and the distance between the pulp chamber roof and floor, to prevent iatrogenic errors. A number of case reports/series documented the management of calcified pulp chambers and root canals using guided ac-

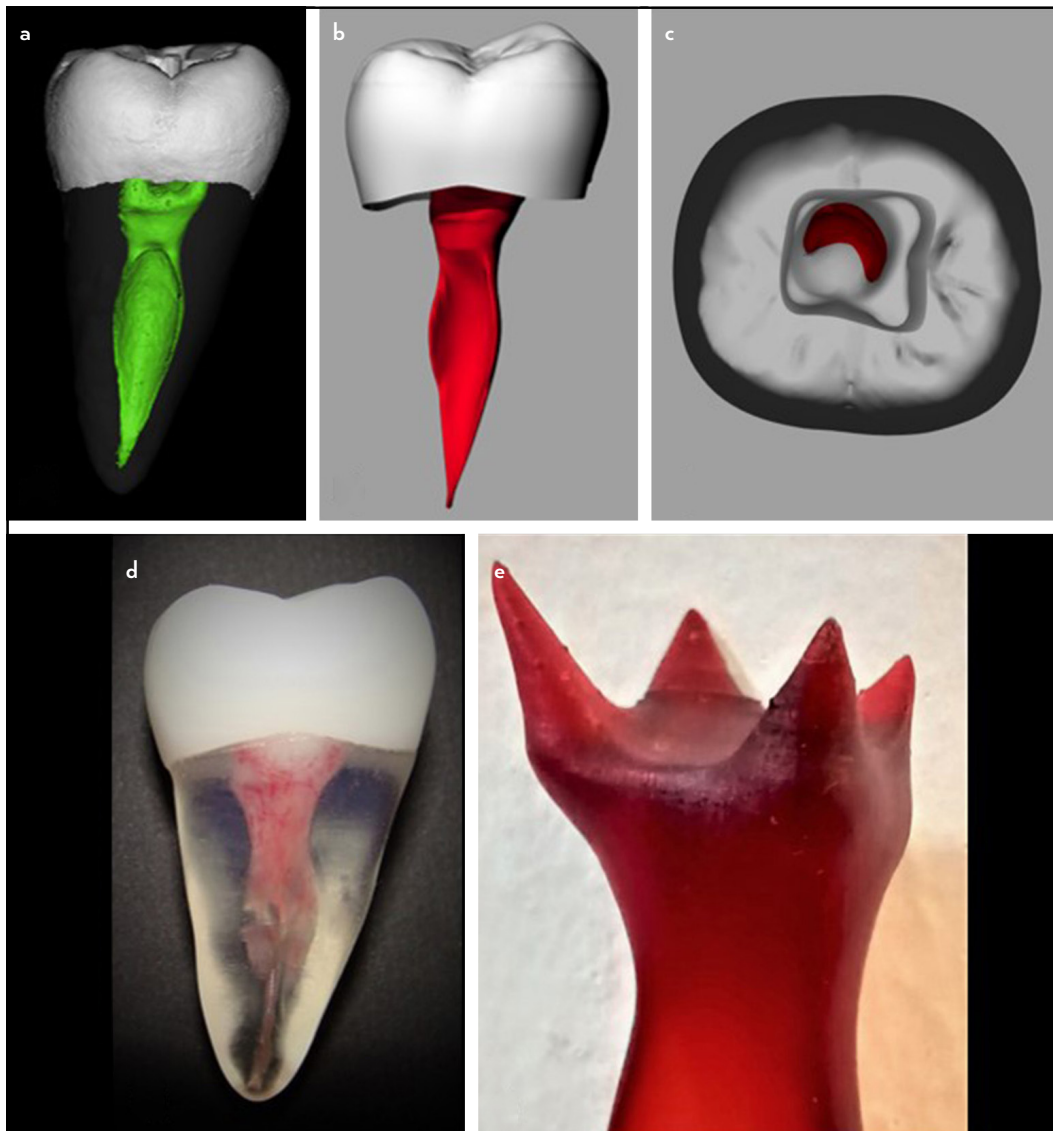


Figure 18. Fabrication of transparent tooth models for a mandibular second molar with fused roots and C-shaped canals scanned using micro-CT. (a) Micro-CT reconstructed images for the mandibular molar. (b) Conversion DICOM files to SLT files (DRSK, Sweden). (c) Morphology of the pulp chamber floor. (d) Fabrication of the transparent tooth models with opaque crown. (e) Fabrication of macro-models showing the anatomy of the pulp chamber and horns
DICOM: Digital Imaging and Communications in Medicine, SLT: Stereolithography

cess cavity preparation techniques with suitable access drills in the anterior (111, 112), and posterior (113, 114) dentitions.

Future directions

Previous research has focused on the study of pulp chamber anatomy using 2D radiographic imaging (bitewing, periapical and panoramic views) and 3D CBCT images. To date, the application of micro-CT technology for the study of pulp chamber anatomy is limited. Future research should focus on the following:

- The study of the 2D and 3D morphological features of the pulp chamber including pulp horns in different tooth types, requires further investigations (Fig. 14), as well as their impact on access cavity design, void formation in post-endodontic restorations and coronal discolouration potential in addition to stress distribution during mechanical loading. Future micro-CT studies should also focus on

the pulp chamber anatomy in dental anomalies such as taurodontism, dens invaginatus and others (Fig. 15).

- Pulp chamber calcification (secondary and tertiary dentine formation and pulp stones) is of a critical concern to the operator, considering the trend for increased tooth retention and the ageing population in many countries. Future investigations should focus on the incidence and prevalence of pulp chamber calcifications/pulp stones with (free, adherent, combined and diffuse) (115, 116). A recent study examined the frequency, position, and length of radicular root canal calcifications in three-rooted maxillary first molars using micro-CT (117). Similar studies can be performed in the pulp chamber of different tooth types (Fig. 16). One recent study examined the structural and aetiological factors involved in the development of pulp chamber calcifications in skeletal remains from various (pre)historic periods (118).

Such information can be translated to clinical practice for the most appropriate techniques to remove different types of pulp stones without excessive sacrifice of normal tooth structure (walls and pulp floor), in addition to the evaluation of different guided access preparation techniques in instances of calcified/obliterated pulp chambers and canals.

- It is well-known that micro-CT studies do not report demographic data (such as sex, age, ethnic groups) since the collected teeth are usually of unknown origin, which is a limitation (25). A recent micro-CT study developed a new approach using micro-CT to segment and quantify secondary dentine thus facilitating age estimation of fragmented and broken teeth (71). Given the fact that age plays an important role on the complexity of pulp chamber anatomy and root canals, future research should focus on the validity of this approach for age estimation of the study samples, especially whether secondary dentine can be differentiated from primary dentine in micro-CT planes (Fig. 17). However, segmentation of secondary from primary dentine is a complicated procedure, that requires further validation (71).
- There has been a recent increased interest in vital pulp therapy procedures. To date, it is unclear whether the age changes in pulp chamber anatomy (i.e. dimensions, size) would have an impact on clinical outcomes. Further studies are needed to correlate such morphological age changes of the coronal pulp tissue [e.g. with decreased pulp cell density (119)] on the pulp repair activity after vital pulp therapy procedures.
- Adding digital 3D resources to a traditional curriculum may have a positive effect on academic achievements and clinical outcomes. A recent study evaluated an online dental learning platform of 3D tooth models with pulp cavity fabricated after micro-CT scanning (120). Results revealed the positive attitude of participants towards the 3D models. Future research should also be directed towards understanding pulp chamber anatomy using similar approaches. Such models can also be used for training at different levels of difficulty – such as teeth with large and narrow pulp chamber spaces. Fabrication of customised models for education and training purposes also require further investigations (Fig. 18).
- Clinical studies are needed to validate the findings from laboratory studies in regards of outcome measures reported by clinicians and/or patients, such as tooth survival and discolouration.

CONCLUSION

It is obvious that the anatomy of the pulp chamber is dynamic, and varies widely by age. The significance of pulp chamber anatomy is becoming more evident with the recent trends for minimal invasive endodontics including vital pulp therapy and modern access cavity preparation techniques. The use of 3D, non-invasive imaging techniques paves the way for better understanding of pulp chamber anatomy. However, more research is needed on the application of micro-CT imaging for more detailed qualitative and quantitative analysis of pulp chamber anatomy.

Disclosures

Conflict of interest: The authors deny any conflict of interest.

Ethics Committee Approval: Not applicable.

Peer-review: Externally peer-reviewed.

Financial Disclosure: RU Grant (GPF017A-2020), Universiti Malaya, Malaysia – Principal Investigator: HMA Ahmed.

Authorship contributions: Concept – H.M.A.A.; Design – H.M.A.A., T.G.W., G.R.F., P.M.H.D.; Supervision – H.M.A.A., T.G.W., G.R.F., P.M.H.D.; Funding – H.M.A.A., T.G.W.; Data collection and/or processing – H.M.A.A., T.G.W.; Analysis and/or interpretation – H.M.A.A., T.G.W., G.R.F., P.M.H.D.; Literature search – H.M.A.A., T.G.W.; Writing – H.M.A.A., T.G.W., G.R.F., P.M.H.D.; Critical Review – H.M.A.A., T.G.W., G.R.F., P.M.H.D.

REFERENCES

1. Scheid RC, Weiss G. *Woelfel's Dental Anatomy*. 8th ed. Philadelphia: Lippincott Williams & Wilkins; 2012.
2. Nelson SJ, Ash MM Jr. *Wheeler's Dental Anatomy, Physiology, and Occlusion*. 9th ed. St. Louis: Saunders Elsevier; 2010. p. 209–55.
3. Chandler NP, Pitt Ford TR, Monteith BD. Coronal pulp size in molars: a study of bitewing radiographs. *Int Endod J* 2003; 36(11):757–63.
4. Peters DD, Baumgartner JC, Lorton L. Adult pulpal diagnosis. I. Evaluation of the positive and negative responses to cold and electrical pulp tests. *J Endod* 1994; 20(10): 506–11. [\[CrossRef\]](#)
5. Udoye CI, Jafarzadeh H, Okechi UC, Aguwa EN. Appropriate electrode placement site for electric pulp testing of anterior teeth in Nigerian adults: a clinical study. *J Oral Sci* 2010; 52(2):287–92. [\[CrossRef\]](#)
6. Jafarzadeh H, Abbott PV. Review of pulp sensibility tests. Part I: general information and thermal tests. *Int Endod J* 2010; 43(9):738–62. [\[CrossRef\]](#)
7. Filippatos CG, Tsatsoulis IN, Floratos S, Kontakiotis EG. The variability of electric pulp response threshold in premolars: a clinical study. *J Endod* 2012; 38(2):144–7. [\[CrossRef\]](#)
8. Shaw L, Jones AD. Morphological considerations of the dental pulp chamber from radiographs of molar and premolar teeth. *J Dent* 1984; 12(2):139–45. [\[CrossRef\]](#)
9. Baltacıoğlu IH, Demirel G, Kolsuz ME, Orhan K. *In-vitro* analysis of maxillary first molars morphology using three dimensional micro-CT imaging: considerations for restorative dentistry. *Eur Oral Res* 2018; 52(2):75–81.
10. Gutmann JL, Fan B. Tooth morphology and pulpal access cavities. In: Berman LH, Hargreaves K, eds. *Cohen's Pathways of the Pulp*. 12th ed. St. Louis: Elsevier; 2021. p. 192–303.
11. Stambaugh RV, Wittrock JW. The relationship of the pulp chamber to the external surface of the tooth. *J Prosthet Dent* 1977; 37(5):537–46.
12. Hayes A, Duvall N, Wajdowicz M, Roberts H. Effect of endocrown pulp chamber extension depth on molar fracture resistance. *Oper Dent* 2017; 42(3):327–34. [\[CrossRef\]](#)
13. Peters OA. Accessing root canal systems: knowledge base and clinical techniques. *ENDO* 2008; 2:87–104.
14. Black GV. *Descriptive Anatomy of the Human Teeth*. Philadelphia: Wilmington Dental Manufacturing Co.; 1892.
15. Bodecker CF. A consideration of some of the changes in the teeth from young to old age. *Dental Cosmos* 1925; 67:543–9.
16. Benzer, S. The development and morphology of physiological secondary dentin. *J Dent Res* 1948; 27(5):640–6. [\[CrossRef\]](#)
17. Vertucci FJ, Williams RG. Furcation canals in the human mandibular first molar. *Oral Surg Oral Med Oral Pathol* 1974; 38(2):308–14. [\[CrossRef\]](#)
18. De Deus QD. Frequency, location, and direction of the lateral, secondary, and accessory canals. *J Endod* 1975; 1(11):361–6. [\[CrossRef\]](#)
19. Gutmann JL. Prevalence, location, and patency of accessory canals in the furcation region of permanent molars. *J Periodontol* 1978; 49(1):21–6.
20. Vertucci FJ. Root canal anatomy of the human permanent teeth. *Oral Surg Oral Med Oral Pathol* 1984; 58(5):589–99. [\[CrossRef\]](#)
21. Haznedaroğlu F, Ersev H, Odabaşı H, Yetkin G, Batur B, Aşçı S, et al. Incidence of patent furcal accessory canals in permanent molars of a Turkish population. *Int Endod J* 2003; 36(8):515–9. [\[CrossRef\]](#)

22. Harb LJ, Ramos FL, Pires CW, Carvalho MG, Braun KO. Evaluation of accessory furcation canals of permanent mandibular molars using radiography and clearing. *Rev Odonto Ciênc* 2010; 25(4):395–400. [CrossRef]
23. Wolf TG, Wentaschek S, Wierichs RJ, Briseño-Marroquín B. Interradicular root canals in mandibular first molars: a literature review and *ex vivo* study. *J Endod* 2019; 45(2):129–35. [CrossRef]
24. Poornima P, Subba Reddy VV. Comparison of digital radiography, decalcification, and histologic sectioning in the detection of accessory canals in furcation areas of human primary molars. *J Indian Soc Pedod Prev Dent* 2008; 26(2):49–52. [CrossRef]
25. Ahmed HMA. A critical analysis of laboratory and clinical research methods to study root and canal anatomy. *Int Endod J* 2022; 55 (Suppl 2):229–80.
26. Philippas GG. Effects of function on healthy teeth: the evidence of ancient Athenian remains. *J Am Dent Assoc* 1952; 45(4):443–53. [CrossRef]
27. Philippas GG. Influence of occlusal wear and age on formation of dentin and size of pulp chamber. *J Dent Res* 1961; 40:1186–98. [CrossRef]
28. Philippas GG, Applebaum E. Age factor in secondary dentin formation. *J Dent Res* 1966; 45(3):778–89. [CrossRef]
29. Philippas GG, Applebaum E. Location of irregular secondary dentin formation. *J Dent Res* 1968; 47(5):769–78. [CrossRef]
30. Philippas GG, Applebaum E. Age change in the permanent upper canine teeth. *J Dent Res* 1968; 47(3):411–7. [CrossRef]
31. Prapanpoch S, Dove SB, Cottone JA. Morphometric analysis of the dental pulp chamber as a method of age determination in humans. *Am J Forensic Med Pathol* 1992; 13(1):50–5. [CrossRef]
32. Talabani RM, Baban MT, Mahmood MA. Age estimation using lower permanent first molars on a panoramic radiograph: a digital image analysis. *J Forensic Dent Sci* 2015; 7(2):158–62. [CrossRef]
33. Jain S, Nagi R, Daga M, Shandilya A, Shukla A, Parakh A, et al. Tooth coronal index and pulp/tooth ratio in dental age estimation on digital panoramic radiographs-A comparative study. *Forensic Sci Int* 2017; 277:115–21.
34. Deutsch AS, Musikant BL. Morphological measurements of anatomic landmarks in human maxillary and mandibular molar pulp chambers. *J Endod* 2004; 30(6):388–90. [CrossRef]
35. Deutsch AS, Musikant BL, Gu S, Isidro M. Morphological measurements of anatomic landmarks in pulp chambers of human maxillary furcated bicuspid. *J Endod* 2005; 31(8):570–3. [CrossRef]
36. Lee MM, Rasimick BJ, Turner AM, Shah RP, Musikant BL, Deutsch AS. Morphological measurements of anatomic landmarks in pulp chambers of human anterior teeth. *J Endod* 2007; 33(2):129–31. [CrossRef]
37. Acosta Vigouroux SA, Trugeda Bosaans SA. Anatomy of the pulp chamber floor of the permanent maxillary first molar. *J Endod* 1978; 4(7):214–9.
38. Krasner P, Rankow HJ. Anatomy of the pulp-chamber floor. *J Endod* 2004; 30(1):5–16. [CrossRef]
39. Pawar AM, Singh S. New classification for pulp chamber floor anatomy of human molars. *J Conserv Dent* 2020; 23(5):430–5. [CrossRef]
40. Kumar VD. A scanning electron microscope study of prevalence of accessory canals on the pulpal floor of deciduous molars. *J Indian Soc Pedod Prev Dent* 2009; 27(2):85–9. [CrossRef]
41. Ahmed HMA. Anatomical challenges, electronic working length determination and current developments in root canal preparation of primary molar teeth. *Int Endod J* 2013; 46(11):1011–22. [CrossRef]
42. Paras LG, Rapp R, Piesco NP, Zeichner SJ, Zullo TG. An investigation of accessory foramina in furcation areas of human primary molars: part 1. SEM observations of frequency, size and location of accessory foramina in the internal and external furcation areas. *J Clin Pediatr Dent* 1993; 17(2):65–9.
43. Dammaschke T, Witt M, Ott K, Schäfer E. Scanning electron microscopic investigation of incidence, location, and size of accessory foramina in primary and permanent molars. *Quintessence Int* 2004; 35(9):699–705.
44. Sharma U, Gulati A, Gill N. An investigation of accessory canals in primary molars - an analytical study. *Int J Paediatr Dent* 2016; 26(2):149–56.
45. Bandeira AVL, de Lima M de DM, Lima CCB, de Moura MS, Cury AADB, de Deus Moura L de F. Topography of primary molar pulp chamber floor: a scanning electron microscopy and micro-computed tomography analysis. *Pesqui Bras Odontopediatria Clin Integr* 2021; 21:e0033. [CrossRef]
46. Perlich MA, Reader A, Foreman DW. A scanning electron microscopic investigation of accessory foramina on the pulpal floor of human molars. *J Endod* 1981; 7(9):402–6. [CrossRef]
47. Vertucci FJ, Anthony RL. A scanning electron microscopic investigation of accessory foramina in the furcation and pulp chamber floor of molar teeth. *Oral Surg Oral Med Oral Pathol* 1986; 62(3):319–26. [CrossRef]
48. Goldberg F, Massone EJ, Soares I, Bittencourt AZ. Accessory orifices: anatomical relationship between the pulp chamber floor and the furcation. *J Endod* 1987; 13(4):176–81. [CrossRef]
49. Lockhart PB, Kim S, Lund NL. Magnetic resonance imaging of human teeth. *J Endod* 1992; 18(5): 237–44. [CrossRef]
50. Sustercic D, Sersa I. Human tooth pulp anatomy visualization by 3D magnetic resonance microscopy. *Radiol Oncol* 2012; 46(1):1–7. [CrossRef]
51. Leontiev W, Bieri O, Madörin P, Dagassan-Berndt D, Kühl S, Krastl G, et al. Suitability of magnetic resonance imaging for guided endodontics: proof of principle. *J Endod* 2021; 47(6):954–60. [CrossRef]
52. Azim AA, Azim KA, Deutsch AS, Huang GT. Acquisition of anatomic parameters concerning molar pulp chamber landmarks using cone-beam computed tomography. *J Endod* 2014; 40(9):1298–302. [CrossRef]
53. Ge ZP, Ma RH, Li G, Zhang JZ, Ma XC. Age estimation based on pulp chamber volume of first molars from cone-beam computed tomography images. *Forensic Sci Int* 2015; 253:133. [CrossRef]
54. Kavas AA, Tümen EC. Volumetric pulp chambers measurements in mandibular and maxillary permanent first molar using cone-beam computed tomography by age and gender. *Int Dent Res* 2019; 9(1):30–40.
55. Helmy MA, Osama M, Elhindawy MM, Mowafey B. Volume analysis of second molar pulp chamber using cone beam computed tomography for age estimation in Egyptian adults. *J Forensic Odontostomatol* 2020; 38(3):25–34.
56. Akbarzadeh N, Aminoshariae A, Khalighinejad N, Palomo JM, Syed A, Kulild JC, et al. The association between the anatomic landmarks of the pulp chamber floor and the prevalence of middle mesial canals in mandibular first molars: an *in vivo* analysis. *J Endod* 2017; 43(11):1797–801.
57. da Silva EJNL, Prado MC, Queiroz PM, Nejaim Y, Brasil DM, Groppo FC, et al. Assessing pulp stones by cone-beam computed tomography. *Clin Oral Investig* 2017; 21(7):2327–33. [CrossRef]
58. Patil SR, Ghani HA, Almuhaiza M, Al-Zoubi IA, Anil KN, Misra N, et al. Prevalence of pulp stones in a Saudi Arabian subpopulation: a cone-beam computed tomography study. *Saudi Endod J* 2018; 8:93–8. [CrossRef]
59. Tassoker M, Magat G, Sener S. A comparative study of cone-beam computed tomography and digital panoramic radiography for detecting pulp stones. *Imaging Sci Dent* 2018; 48(3):201–12. [CrossRef]
60. Aydin H, Mobaraki S. Comparison of root and canal anatomy of taurodont and normal molar teeth: a retrospective cone-beam computed tomography study. *Arch Oral Biol* 2021; 130:105242. [CrossRef]
61. Dianat O, Nosrat A, Tordik PA, Aldahmash SA, Romberg E, Price JB, et al. Accuracy and efficiency of a dynamic navigation system for locating calcified canals. *J Endod* 2020; 46(11):1719–25. [CrossRef]
62. Chaniotis A, Ordinola-Zapata R. Present status and future directions: management of curved and calcified root canals. *Int Endod J* 2022; 55(Suppl 3):656–84. [CrossRef]
63. Peña-Bengoa F, Valenzuela M, Flores MJ, Dufey N, Pinto KP, Silva EJNL. Effectiveness of guided endodontics in locating calcified root canals: a systematic review. *Clin Oral Investig* 2023; 27(5):2359–74. [CrossRef]
64. Oi T, Saka H, Ide Y. Three-dimensional observation of pulp cavities in the maxillary first premolar tooth using micro-CT. *Int Endod J* 2004; 37(1):46–51. [CrossRef]
65. Iwaka Y. Three-dimensional observation of the pulp cavity of mandibular first molars by micro-CT. *J Oral Biosci* 2006; 48(2):94–102. [CrossRef]
66. Min Y, Fan B, Cheung GS, Gutmann JL, Fan M. C-shaped canal system in mandibular second molars Part III: the morphology of the pulp chamber floor. *J Endod* 2006; 32(12):1155–9. [CrossRef]
67. Aboshi H, Takahashi T, Komuro T. Age estimation using microfocus X-ray computed tomography of lower premolars. *Forensic Sci Int* 2010; 200(1-3):35–40. [CrossRef]
68. Tomaszewska IM, Leszczyński B, Wróbel A, Gładysz T, Duncan HF. A micro-computed tomographic (micro-CT) analysis of the root canal morphology of maxillary third molar teeth. *Ann Anat* 2018; 215:83–92.
69. Asami R, Aboshi H, Iwawaki A, Ohtaka Y, Odaka K, Abe S, et al. Age estimation based on the volume change in the maxillary premolar crown using micro CT. *Leg Med (Tokyo)* 2019; 37:18–24. [CrossRef]

70. Serindere G, Belgin CA, Orhan K. Observation of the pulp chamber of maxillary first premolars: a micro-computed tomographic study. *Curr Med Imaging 2020*; 16(3):224–30. [\[CrossRef\]](#)
71. Nudel I, Pokhojaev A, Hausman BS, Bitterman Y, Shpack N, May H, et al. Age estimation of fragmented human dental remains by secondary dentin virtual analysis. *Int J Legal Med 2020*; 134(5):1853–60. [\[CrossRef\]](#)
72. Gu Y, Lu Q, Wang H, Ding Y, Wang P, Ni L. Root canal morphology of permanent three-rooted mandibular first molars--part I: pulp floor and root canal system. *J Endod 2010*; 36(6):990–4. [\[CrossRef\]](#)
73. Souza-Flamini LE, Leoni GB, Chaves JF, Versiani MA, Cruz-Filho AM, Pécora JD, et al. The radix entomolaris and paramolaris: a micro-computed tomographic study of 3-rooted mandibular first molars. *J Endod 2014*; 40(10):1616–21. [\[CrossRef\]](#)
74. Rodrigues CT, Oliveira-Santos C, Bernardineli N, Duarte MA, Bramante CM, Minotti-Bonfante PG, et al. Prevalence and morphometric analysis of three-rooted mandibular first molars in a Brazilian subpopulation. *J Appl Oral Sci 2016*; 24(5):535–42. [\[CrossRef\]](#)
75. Versiani MA, Pécora JD, de Sousa-Neto MD. Root and root canal morphology of four-rooted maxillary second molars: a micro-computed tomography study. *J Endod 2012*; 38(7):977–82. [\[CrossRef\]](#)
76. Ordinola-Zapata R, Bramante CM, Villas-Boas MH, Cavenago BC, Duarte MH, Versiani MA. Morphologic micro-computed tomography analysis of mandibular premolars with three root canals. *J Endod 2013*; 39(9):1130–5.
77. Ordinola-Zapata R, Martins JNR, Plascencia H, Versiani MA, Bramante CM. The MB3 canal in maxillary molars: a micro-CT study. *Clin Oral Investig 2020*; 24(11):4109–21. [\[CrossRef\]](#)
78. Sakakibara K, Kawano Y, Yamamoto H, Iwahori M, Sugiura Y, Miyao M. Variations in the configuration of pulp chambers subjacent to proto-stylids. *J Oral Sci 2021*; 63(3):236–41. [\[CrossRef\]](#)
79. Sener S, Cobankara FK, Akgünlü F. Calcifications of the pulp chamber: prevalence and implicated factors. *Clin Oral Investig 2009*; 13(2):209–15.
80. Kannan S, Kannepady SK, Muthu K, Jeevan MB, Thapasum A. Radiographic assessment of the prevalence of pulp stones in Malaysians. *J Endod 2015*; 41(3):333–7. [\[CrossRef\]](#)
81. Cleghorn BM, Boorberg NB, Christie WH. Primary human teeth and their root canal systems. *Endod Topics 2010*; 23(1):6–33. [\[CrossRef\]](#)
82. Diéguez-Pérez M, Ticona-Flores JM. Three-dimensional analysis of the pulp chamber and coronal tooth of primary molars: an *in vitro* study. *Int J Environ Res Public Health 2022*; 19(15):9279. [\[CrossRef\]](#)
83. Anderreg AL, Hajdarevic D, Wolf TG. Interradicular canals in 213 mandibular and 235 maxillary molars by means of micro-computed tomographic analysis: an *ex vivo* study. *J Endod 2022*; 48(2):234–9. [\[CrossRef\]](#)
84. Wakabayashi H, Matsumoto K, Shirasuka T, Funato A, Tsuzuki N. Scanning electron microscopic study of dentin walls of the pulp chamber by a replica technique. *Oral Surg Oral Med Oral Pathol 1988*; 66(2):236–42.
85. Paras LG, Rapp R, Piesco NP, Zeichner SJ, Zullo TG. An investigation of accessory canals in furcation areas of human primary molars: part 2. Latex perfusion studies of the internal and external furcation areas to demonstrate accessory canals. *J Clin Pediatr Dent 1993*; 17(2):71–7.
86. Rashed B, Iino Y, Komatsu K, Nishijo M, Hanada T, Ebihara A, et al. Evaluation of root canal anatomy of maxillary premolars using swept-source optical coherence tomography in comparison with dental operating microscope and cone beam computed tomography. *Photomed Laser Surg 2018*; 36(9):487–92. [\[CrossRef\]](#)
87. Jiang W, Bo H, Yongchun G, LongXing N. Stress distribution in molars restored with inlays or onlays with or without endodontic treatment: a three-dimensional finite element analysis. *J Prosthet Dent 2010*; 103(1):6–12. [\[CrossRef\]](#)
88. Clark D, Khademi J. Modern molar endodontic access and directed dentin conservation. *Dent Clin North Am 2010*; 54(2):249–73. [\[CrossRef\]](#)
89. Ballester B, Giraud T, Ahmed HMA, Nabhan MS, Bukiet F, Guivarc'h M. Current strategies for conservative endodontic access cavity preparation techniques-systematic review, meta-analysis, and decision-making protocol. *Clin Oral Investig 2021*; 25(11):6027–44. [\[CrossRef\]](#)
90. Chan MYC, Cheung V, Lee AHC, Zhang C. A literature review of minimally invasive endodontic access cavities - past, present and future. *Eur Endod J 2022*; 7(1):1–10. [\[CrossRef\]](#)
91. Silva EJNL, Pinto KP, Ferreira CM, Belladonna FG, De-Deus G, Dummer PMH, et al. Current status on minimal access cavity preparations: a critical analysis and a proposal for a universal nomenclature. *Int Endod J 2020*; 53(12):1618–35. [\[CrossRef\]](#)
92. Silva AA, Belladonna FG, Rover G, Lopes RT, Moreira E JL, De-Deus G, et al. Does ultraconservative access affect the efficacy of root canal treatment and the fracture resistance of two-rooted maxillary premolars? *Int Endod J 2020*; 53(2):265–75. [\[CrossRef\]](#)
93. Silva EJNL, Oliveira VB, Silva AA, Belladonna FG, Prado M, Antunes HS, et al. Effect of access cavity design on gaps and void formation in resin composite restorations following root canal treatment on extracted teeth. *Int Endod J 2020*; 53(11):1540–8. [\[CrossRef\]](#)
94. Silva EJNL, De-Deus G, Souza EM, Belladonna FG, Cavalcante DM, Simões-Carvalho M, et al. Present status and future directions - Minimal endodontic access cavities. *Int Endod J 2022*; 55(Suppl 3):531–87.
95. Shabbir J, Zehra T, Najmi N, Hasan A, Naz M, Piasecki L, et al. Access cavity preparations: classification and literature review of traditional and minimally invasive endodontic access cavity designs. *J Endod 2021*; 47(8):1229–44. [\[CrossRef\]](#)
96. Neelakantan P, Khan K, Hei Ng GP, Yip CY, Zhang C, Pan Cheung GS. Does the orifice-directed dentin conservation access design debride pulp chamber and mesial root canal systems of mandibular molars similar to a traditional access design? *J Endod 2018*; 44(2):274–9. [\[CrossRef\]](#)
97. Rover G, Belladonna FG, Bortoluzzi EA, De-Deus G, Silva EJNL, Teixeira CS. Influence of access cavity design on root canal detection, instrumentation efficacy, and fracture resistance assessed in maxillary molars. *J Endod 2017*; 43(10):1657–62. [\[CrossRef\]](#)
98. Pereira RD, Leoni GB, Silva-Sousa YT, Gomes EA, Dias TR, Brito-Júnior M, et al. Impact of conservative endodontic cavities on root canal preparation and biomechanical behavior of upper premolars restored with different materials. *J Endod 2021*; 47(6):989–99. [\[CrossRef\]](#)
99. Saygili G, Uysal B, Omar B, Ertas ET, Ertas H. Evaluation of relationship between endodontic access cavity types and secondary mesiobuccal canal detection. *BMC Oral Health 2018*; 18(1):121. [\[CrossRef\]](#)
100. Silva EJNL, Lima CO, Barbosa AFA, Augusto CM, Souza EM, Lopes RT, et al. Preserving dentine in minimally invasive access cavities does not strength fracture resistance of restored mandibular molars. *Int Endod J 2021*; 54(6):966–74. [\[CrossRef\]](#)
101. Byers MR. Dental sensory receptors. *Int Rev Neurobiol 1984*; 25:39–94.
102. Reynolds RL. The determination of pulp vitality by means of thermal and electrical stimuli. *Oral Surg Oral Med Oral Pathol 1966*; 22:231–40.
103. Johnstone M, Parashos P. Endodontics and the ageing patient. *Aust Dent J 2015*; 60(Suppl 1):20–7. [\[CrossRef\]](#)
104. Ngeow WC, Thong YL. Gaining access through a calcified pulp chamber: a clinical challenge. *Int Endod J 1998*; 31(5):367–71. [\[CrossRef\]](#)
105. Evans MD. A contemporary treatment of an iatrogenic root perforation: a case report. *J Endod 2021*; 47(3):520–5. [\[CrossRef\]](#)
106. Kuoch P, Duplan MB, Berès F, Bonte É, Couvrechel C. Clinical identification and endodontic management of furcation canals: a case series. *Braz Dent J 2023*; 34(1):132–8. [\[CrossRef\]](#)
107. Ahmed HMA, Krastl G, Zimmerli B, Amer M, Parashos P. Management of coronal discoloration. In: Ahmed HMA, Dummer PMH, eds. *Endodontic Advances and Evidence-Based Clinical Guidelines*. New York: John Wiley & Sons Ltd.; 2022. p. 617–44. [\[CrossRef\]](#)
108. Ahmed HMA, Abbott PV. Discolouration potential of endodontic procedures and materials: a review. *Int Endod J 2012*; 45(10):883–97. [\[CrossRef\]](#)
109. Wolters WJ, Duncan HF, Tomson PL, Karim IE, McKenna G, Dorri M, et al. Minimally invasive endodontics: a new diagnostic system for assessing pulpitis and subsequent treatment needs. *Int Endod J 2017*; 50(9):825–9.
110. Christofzik DW, Glandorf P, Conrad J, Fawzy El-Sayed KM, Großberg-Schreiber B, Dörfer CE. 2D radiographs, cone-beam computed tomography and 3D CBCT-based planning software in access cavity preparation: A single blinded randomised controlled *in vitro* study. *Aust Endod J 2022*; 48(2):283–96. [\[CrossRef\]](#)
111. Krastl G, Zehnder MS, Connert T, Weiger R, Kühl S. Guided endodontics: a novel treatment approach for teeth with pulp canal calcification and apical pathology. *Dent Traumatol 2016*; 32(3):240–6. [\[CrossRef\]](#)
112. Llaquet Pujol M, Vidal C, Mercadé M, Muñoz M, Ortolani-Seltenerich S. Guided endodontics for managing severely calcified canals. *J Endod 2021*; 47(2):315–21. [\[CrossRef\]](#)
113. Maia LM, de Carvalho Machado V, da Silva NRFA, Brito Júnior M, da Silveira RR, Moreira Júnior G, et al. Case reports in maxillary posterior teeth by guided endodontic access. *J Endod 2019*; 45(2):214–8. [\[CrossRef\]](#)

114. Krug R, Volland J, Reich S, Soliman S, Connert T, Krastl G. Guided endodontic treatment of multiple teeth with dentin dysplasia: a case report. *Head Face Med* 2020; 16(1):27. [\[CrossRef\]](#)
115. Goga R, Chandler NP, Oginni AO. Pulp stones: a review. *Int Endod J* 2008; 41(6):457–68. [\[CrossRef\]](#)
116. McCabe PS, Dummer PM. Pulp canal obliteration: an endodontic diagnosis and treatment challenge. *Int Endod J* 2012; 45(2):177–97. [\[CrossRef\]](#)
117. Keleş A, Keskin C, Versiani MA. Micro-CT assessment of radicular pulp calcifications in extracted maxillary first molar teeth. *Clin Oral Investig* 2022; 26(2):1353–60. [\[CrossRef\]](#)
118. Nicklisch N, Schierz O, Enzmann F, Knipper C, Held P, Vach W, et al. Dental pulp calcifications in prehistoric and historical skeletal remains. *Ann Anat* 2021; 235:151675. [\[CrossRef\]](#)
119. Murray PE, Stanley HR, Matthews JB, Sloan AJ, Smith AJ. Age-related odontometric changes of human teeth. *Oral Surg Oral Med Oral Pathol Oral Radiol Endod* 2002; 93(4):474–82. [\[CrossRef\]](#)
120. Sun W, Chen H, Zhong Y, Zhang W, Chu F, Li L, et al. Three-dimensional tooth models with pulp cavity enhance dental anatomy education. *Anat Sci Educ* 2022; 15(3):566–75. [\[CrossRef\]](#)