

Effects of Dimensions of Root-End Fillings and Peripheral Root Dentine on the Healing Outcome of Apical Surgery

 Thomas VON ARX,  Evodie MARWIK,  Michael M. BORNSTEIN

ABSTRACT

Objective: The objective of this study was to assess dimensions of root-end fillings (REFs), as well as peripheral root dentine (PRD) and their effects on the healing outcome of apical surgery.

Methods: Cone beam computed tomography (CBCT) scans were utilized to measure the REF length and width and the PRD thickness in 61 roots of 53 teeth 1 year after apical surgery. Measurements were taken in the mesio-distal as well as bucco-lingual directions. The REF alignment with respect to the root axis was also evaluated. In addition, the dimensions of REF and PRD were assessed for possible correlations with the healing outcome. Criteria for determining the healing outcome included clinical and radiographic parameters.

Results: The mean REF length was 2.02 ± 0.52 mm. No significant differences were observed with regard to tooth groups, but one-canal roots had a significantly longer mean REF than two-canal roots ($P=0.006$). The mean REF widths were 1.14 ± 0.24 mm mesio-distally and 2.61 ± 1.24 mm bucco-lingually. Roots with two canals presented a significantly wider REF ($P<0.001$) in the bucco-lingual dimension but had a significantly narrower REF in the mesio-distal direction ($P<0.001$) compared to roots with single canals. PRD measured on average 1.19 ± 0.23 mm at the resection level and 1.44 ± 0.27 mm at the coronal end of the REF. Almost all REFs were perfectly aligned with the longitudinal axis of the roots. With regard to healing outcomes, no correlations were found with REF and PRD values, respectively.

Conclusion: The mean REF length was 2.02 mm. On average, a thickness >1 mm of peripheral root dentine was maintained. The REF or PRD dimensions had no statistical effect on the healing outcome.

Keywords: Apical surgery, CBCT, healing outcome, peripheral root dentine, root-end filling

HIGHLIGHTS

- This CBCT study evaluated the dimensions of REF and the thicknesses of PRD.
- The mean lengths of the REF was 2.02 mm.
- The mean thicknesses of the PRD remained greater than 1 mm.
- The studied parameters did not affect the healing outcome.

INTRODUCTION

The aim of apical surgery is to maintain endodontically treated teeth with persistent or recurrent periradicular lesions that cannot be adequately managed by conventional root canal retreatment (1). In most cases of persistent or recurrent endodontic lesions, intraradicular micro-organisms and/or their toxins leaking from the root-canal system are the main cause of re-infection. Micro-organ-

isms may be located within apical ramifications or in the space between root-canal fillings and canal walls. Furthermore, the innermost portions of infected dentinal tubules may serve as a reservoir for endodontic re-infection (2). Hence, a key factor for successful healing after apical surgery is the apical seal, that is, the placement of a tight root-end filling (REF), to prevent periapical re-infection (3). As a consequence, the techniques of root-end cavity preparation and obturation, as well as the choice of root-end obturation materials, have generated a lot of interest (4).

The general consensus in periradicular surgery is to perform a root-end resection of approximately 3 mm to remove the apical delta and lateral canals. Subsequently, a root-end cavity is prepared with a recommended depth of 3 mm (1, 5). This cavity should encompass the full extension of the root canal at the resection level, that is, the main canal, accessory canals, and isthmus. The root-end preparation removes the remnants of pulpal tissue, debris, gutta-percha, and cement from the existing root-canal filling, as well as the innermost layer of dentine along the pulp canal space. While preparation of a root-end cavity is necessary for securing the apical seal, it may thin out and weaken the root dentine surrounding the prepared cavity.

Please cite this article as: Von Arx T, Marwik E, Bornstein MM. Apical Surgery: Effects of Dimensions of Root-End Fillings and Peripheral Root Dentine on the Healing Outcome. *Eur Endod J* 2019; 4: 49-56

From the Department of Oral Surgery and Stomatology (T.V.A.  thomas.vonarx@zmk.unibe.ch, E.M.) University of Bern, Switzerland; Department of Applied Oral Sciences Oral and Maxillofacial Radiology (M.M.B.), University of Hong Kong, China

Received 27 February 2019,
Accepted 07 May 2019

Published online: 18 July 2019
DOI 10.14744/ej.2019.76376

This work is licensed under a Creative Commons Attribution-NonCommercial 4.0 International License.



The primary objective of this study was to assess the dimensions of the REF using 3D-radiography following apical surgery. Secondary outcome measures included the evaluation of the thickness of the peripheral root dentine (PRD) adjacent to the REF and the alignment of the REF with the longitudinal axis of the treated root. The null hypothesis was that the REF and PRD dimensions had no effect on the healing outcome.

MATERIALS AND METHODS

Study design and population

Patients undergoing apical surgery were included in the present study when they gave their written consent to perform cone beam computed tomography (CBCT) pre-operatively and at the 1-year review. The CBCT scans taken by the referring dentist or at other institutions resulted in exclusion of the case from the study. The study was conducted fully in accordance with the Declaration of Helsinki 2013 (www.wma.net) and had been approved by the institutional review board (ethical committee of the canton Bern; approval number KEK-BE 098/11) (6). Patients had been recruited for this study from September 2011 until September 2013.

The preparation of the manuscript followed the guidelines presented in the STROBE (“Strengthening the Reporting of Observational Studies in Epidemiology”) statement for cohort studies (www.strobe-statement.org).

Surgical technique

Details of the surgical technique and outcome assessment have been previously reported (7). All surgeries were carried out with a surgical microscope by the same surgeon. After obtaining local anesthesia, a full mucoperiosteal flap was raised. Osteotomies were made with rotary burs to access the root apices. The periapical pathological tissue was curetted out with surgical spoons and excavators. Root apices were resected at 3 mm. The resection level was marked with a small round bur, and resection was accomplished with a fluted fissure bur. Following hemostasis, root-end cavities were prepared with 3 mm-long diamond-coated microtips (EndoSuccess Apical Surgery, Satelec/Acteon, Merignac, France) activated by an ultrasonic unit (Piezotome, Satelec/Acteon, Merignac, France). Root-end cavities were sealed with MTA (ProRoot Dentsply Tulsa Dental, Tulsa, OK, USA). An endoscope (Hopkins Tele Otoscope 70°; Karl Storz GmbH, Tuttlingen, Germany) was used for inspection after the following steps: root-end resection, root-end cavity preparation, and retrograde filling. Wound margins were re-approximated with single interrupted sutures. A gauze was placed for 30 minutes for wound compression. Sutures were usually removed 4 to 7 days postoperatively.

Radiographic assessment

The CBCT images were obtained with the 3D Accuitomo 170 (Morita, Kyoto, Japan). The size of FOV was either 4×4 cm (voxel size 0.080 mm) or 6×6 cm (voxel size 0.125 mm). The parameters of the recordings were 3.0 mA and 80 kV with an exposure time of 17.5 seconds. The CBCT images were assessed twice by a single observer at an interval of 4 weeks.

The observer was not involved in the surgeries. Metric measurements were performed with the inbuilt measurement tool (i-Dixel Version 1.8, Morita, Kyoto, Japan). The mean of the two measurements was used for the final analysis. The following radiographic parameters were determined on coronal and sagittal images of reformatted CBCT sections aligned longitudinally to the center axis of the root (Figs. 1 and 2).

Primary outcome parameters

Dimensions of REF and influencing factors (tooth group, number of canals per root, and presence/absence of a post/screw); the length (mm) of REF (distance from the resection plane to the “coronal” end of the REF); and the width (mm) of REF (measured at the resection plane and at the “coronal” end of the REF). Distances were assessed in mesio-distal as well as in

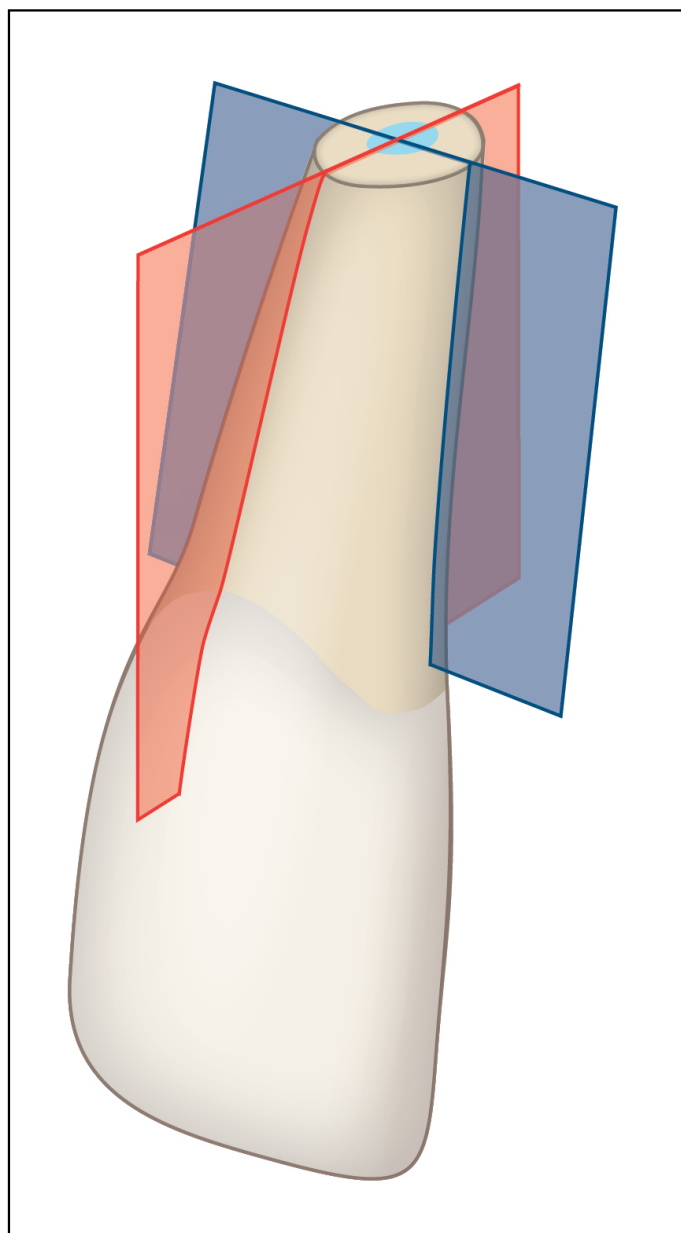


Figure 1. Schematic illustration of a maxillary incisor with mesio-distal (blue) and bucco-lingual (red) planes for the evaluation of study parameters

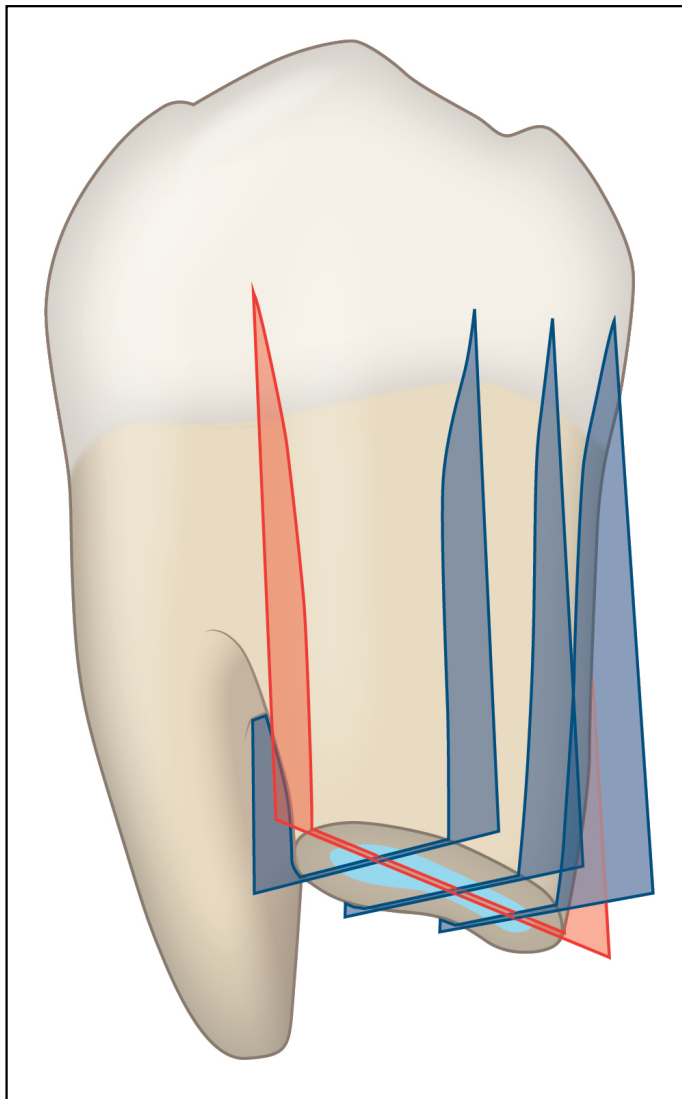


Figure 2. Schematic illustration showing the three mesio-distal planes (blue planes) of evaluation in roots with two canals

bucco-lingual planes (Figs. 3 and 4). All measurements were averaged to obtain the mean value per study parameter. In roots with two canals, three mesio-distal planes were assessed to account for the oblong cross section of the root: through buccal canal, through palatal or lingual canal, and halfway between the two canals (in the isthmus area) (Fig. 2). Again, all measurements were pooled, and means were calculated.

Secondary outcome parameters

- Thickness (mm) of PRD at the resection plane (apical thickness) and at the coronal end (coronal thickness) of the REF and influencing factors (tooth group, number of canals per root, and presence/absence of a post/screw) were assessed in bucco-lingual as well as in mesio-distal planes.
- Alignment of the REF relative to the longitudinal axis of the root canal (yes or no) in bucco-lingual as well as in mesio-distal planes, and influencing factors
- Assessment of null hypothesis that the REF and PRD values had no influence on the healing outcome

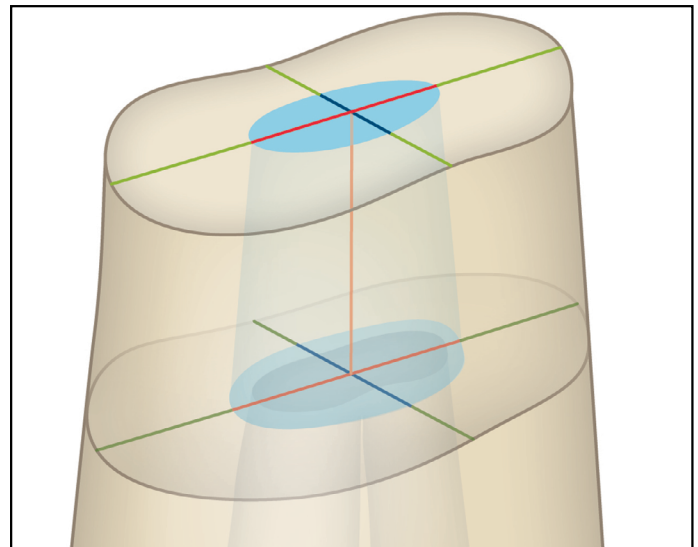


Figure 3. Schematic illustration of the evaluated REF and PRD dimensions: orange vertical line represents the REF length, while blue (bucco-lingual) and red (mesio-distal) lines represent REF widths; green lines represent the PRD thicknesses measured at four aspects at the level of the resection plane (apical thicknesses) and at the level of the end of the REF (coronal thicknesses)

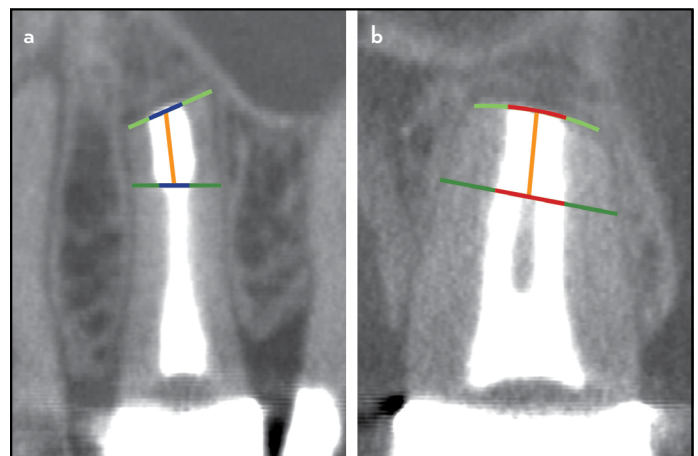


Figure 4. Measurements of REF and PRD in a left maxillary second premolar: (a) mesio-distal direction (sagittal CBCT); (b) bucco-lingual direction (coronal CBCT)

Vertical orange lines=length of REF
 Horizontal blue lines=mesio-distal width of REF
 Horizontal red lines=bucco-lingual width of REF
 Horizontal light-green lines=apical thicknesses of PRD
 Horizontal dark-green lines=coronal thicknesses of PRD

Healing assessment

The healing outcome was based on clinical and radiographic parameters recorded at the 1-year follow-up. Clinical signs and symptoms included pain, sensitivity to tooth percussion or palpation and the presence of a sinus tract, and a swelling or a communicating apicomarginal lesion. CBCT scans oriented along the longitudinal axis of the treated root were independently evaluated by three calibrated observers (7). Healing was categorized into three subgroups:

- Healed: no radiolucency present (apparently complete periapical healing with the formation of a new periodontal

ligament space of normal width at the cut root face) and the absence of clinical signs and symptoms

- Scar healed: radiolucency of “scar” type (persistent rarefaction of irregular shape, asymmetrically located at the cut root face) and the absence of clinical signs and symptoms
- Non-healed: radiolucency of “lesion” type (persistent rarefaction of circular or semicircular shape, typically located at the cut root face as a symmetrical, funnel-like extension of the periodontal ligament space) or the presence of clinical signs and symptoms

Statistical analysis

All data were first analyzed descriptively. The differences in continuous variables (such as the REF length, width, and PRD thickness) were assessed by a t-test or one-way analysis of variance with Bonferroni adjusted pairwise comparisons. For data not exhibiting normality, the Mann–Whitney U test or Kruskal–Wallis test (with Bonferroni adjusted pairwise comparisons) were applied. To compare the PRD thicknesses in the same tooth, paired t-tests were performed. The significance of categorical independent variables (such as REF alignment) was evaluated with Pearson's chi-squared or Fisher's exact tests. Potential correlations of REF and PRD values with healing outcomes were assessed using a logistic regression model. The significance level chosen for all statistical tests was $P \leq 0.05$. All analyses were performed in SPSS (Version 24.0, IBM Corp., Armonk, New York, USA).

RESULTS

Initially, a total of 63 patients were enrolled in the study. Study parameters could not be analyzed in 9 patients (1 patient was pregnant at the 1-year follow-up, therefore no CBCT was taken; 3 patients refused the CBCT imaging at the 1-year follow-up; 3 patients declined to be re-examined after 1 year; 1 patient had died before the 1-year control; and 1 patient could not be contacted). Thus, the final cohort included 54 patients (recall rate 85.7%) with a total of 61 treated roots in 54 teeth (34 maxillary teeth including 9 central incisors, 8 lateral incisors, 1 canine, 3 first premolars, 8 second premolars, and 5 first molars; 20 mandibular teeth including 2 canines, 2 second premolars, and 16 first molars). Patients comprised 25 males and 29 females with a mean age of 53.5 ± 10.1 years (range 24 to 73 years).

Length of REF (Table 1)

The mean length of REF was 2.02 ± 0.52 mm (range, 0.78–3.8 mm). It did not differ significantly across the three tooth groups ($P=0.092$). The REF length was not influenced by the presence of a post/screw ($P=0.872$). In contrast, one-canal roots (2.11 mm) had a significantly longer mean REF than two-canal roots (1.82 mm, $P=0.006$). No significant differences in the REF length were found across the three healing groups ($P>0.05$).

Width of REF in the mesio-distal direction (Table 1)

In the mesio-distal direction, the mean width of REF measured 1.14 ± 0.24 mm (range, 0.7–1.89 mm). Differences in REF widths were significant across tooth groups ($P=0.002$). The mean REF

TABLE 1. Dimensions (mm) of REF* per subgroups (n=61)

Subgroups	N roots	Length Mean±SD (range)	Width (mesio-distal) Mean±SD (range)	Width (bucco-lingual) Mean±SD (range)
All roots	61	2.02±0.52 (0.78–3.8)	1.14±0.24 (0.70–1.89)	2.61±1.24 (1.16–5.12)
Incisors/canines	20	2.19±0.6 (0.78–3.59)	^A 1.24±0.23 (0.87–1.73)	^{C,D} 1.56±0.22 (1.16–1.9)
Premolars	13	2.10±0.72 (1.18–3.8)	^B 1.21±0.29 (0.7–1.89)	^C 2.62±1.15 (1.28–5.11)
Molars	28	1.87±0.27 (1.26–2.57)	^{A,B} 1.03±0.18 (0.77–1.58)	^D 3.36±1.18 (1.18–5.12)
1-canal roots	43	^E 2.11±0.59 (0.78–3.8)	^F 1.21±0.24 (0.87–1.89)	^G 2.0±0.76 (1.16–4.34)
2-canal roots	18	^E 1.82±0.21 (1.53–2.19)	^F 0.97±0.14 (0.70–1.25)	^G 4.08±0.85 (2.35–5.12)
Presence of post/screw	22	2.04±0.78 (0.78–3.8)	1.18±0.26 (0.70–1.89)	2.10±0.95 (1.21–4.63)
Absence of post/screw	39	2.01±0.29 (1.53–2.72)	1.11±0.23 (0.77–1.73)	2.90±1.30 (1.16–5.12)
Healed	37	1.98±0.59 (0.78–3.8)	1.13±0.24 (0.70–1.89)	2.63±1.16 (1.18–5.12)
Scar-healed	19	2.06±0.42 (1.2–3.0)	1.15±0.26 (0.81–1.73)	2.74±1.39 (1.16–5.11)
Not-healed	5	2.24±0.30 (1.76–2.5)	1.15±0.22 (0.89–1.40)	2.00±1.31 (1.21–4.32)

*REF: Root-end filling, SD: Standard deviation

Same superscript letters denote statistically significant differences ($P<0.05$) across subgroups

TABLE 2. Thickness (mm) of PRD* per site (n=61)

Sites	"Apical" thickness Mean±SD (range)	"Coronal" thickness Mean±SD (range)
Overall	1.19±0.23 (0.73–1.7)	1.44±0.27 (0.74–2.08)
Mesial	0.98±0.28 (0.45–1.71)	1.19±0.29 (0.64–2.1)
Distal	1.03±0.27 (0.29–1.64)	1.12±0.29 (0.42–1.85)
Buccal	1.36±0.41 (0.55–2.72)	1.68±0.4 (0.93–2.97)
Lingual	1.39±0.41 (0.75–2.51)	1.78±0.52 (0.87–3.84)

*PRD: Peripheral root dentine, SD: Standard deviation
P<0.001 for all pairwise comparisons among and across subgroups

width in molars (1.03 mm) was significantly smaller than in incisor/canines (1.24 mm, P=0.003) or in premolars (1.21 mm, P=0.040). Similarly, the mean REF width in two-canal roots (0.97 mm) was significantly smaller compared to one-canal roots (1.21 mm, P<0.001). The three healing groups did not have a significantly different mesio-distal REF (P>0.05).

Width of REF in the bucco-lingual direction (Table 1)

In the bucco-lingual direction, the mean width of REF measured 2.61±1.24 mm (range, 1.16–5.12 mm). Differences in the REF widths were significant across tooth groups (P<0.001). Incisors/canines presented a significantly smaller mean REF width (1.56 mm) compared to premolars (2.62 mm, P=0.005) or molars (3.36

mm, P<0.001). Furthermore, two-canal roots had a significantly larger mean REF width (4.08 mm) compared to one-canal roots (2.00 mm, P<0.001). With regard to healing, the bucco-lingual REF width was smaller in non-healed roots (2.00 mm) compared to healed (2.63 mm,) or scar-healed roots (2.74 mm), but the differences did not reach statistical significance.

Thickness of PRD (Tables 2 and 3)

The PRD had a mean thickness of 1.19±0.23 mm at the apical level and 1.44±0.27 mm at the coronal level. Irrespective of the tested sites and subgroups, mean coronal thicknesses were always greater than mean apical thicknesses (P<0.001), and mean buccal or lingual thicknesses were always significantly greater than mean mesial or distal (P<0.001) thicknesses. Neither mean apical nor coronal thicknesses of PRD showed significant differences across the three tooth groups. However, mean thicknesses of PRD in one-canal roots were significantly greater compared to two-canal roots (P<0.001 for apical thickness and P=0.001 for coronal thickness). Mean apical or coronal PRD thicknesses did not differ significantly across the three healing groups (P>0.05).

Alignment of REF

In the mesio-distal plane, 59 out of 61 REFs (96.7%) were aligned with the longitudinal axis of the root: one REF inclined distally and one mesially. In the bucco-lingual plane, 57 REFs (93.4%) were parallel to the longitudinal axis of the root: two REFs inclined buccally and two lingually. The alignment exhibited a borderline significance for the impact of different tooth groups (P=0.047). However, no significant difference

TABLE 3. Thickness (mm) of PRD* per subgroup (n=61)

Subgroups	N roots	"Apical" thickness Mean±SD (range)	"Coronal" thickness Mean±SD (range)
All roots	61	1.19±0.23 (0.73–1.70)	1.44±0.27 (0.74–2.08)
Incisors/canines	20	1.21±0.21 (0.93–1.70)	1.52±0.21 (1.03–1.91)
Premolars	13	1.26±0.25 (0.78–1.67)	1.5±0.25 (1.08–1.90)
Molars	28	1.14±0.23 (0.73–1.59)	1.36±0.29 (0.74–2.08)
1-canal roots	43	^A 1.26±0.2 (0.93–1.7)	^B 1.53±0.24 (1.03–2.08)
2-canal roots	18	^A 1.03±0.21 (0.73–1.48)	^B 1.25±0.21 (0.74–1.62)
Presence of post/screw	22	1.19±0.22 (0.78–1.67)	1.51±0.30 (1.03–2.08)
Absence of post/screw	39	1.19±0.24 (0.73–1.70)	1.41±0.24 (0.74–1.77)
Healed	37	1.19±0.26 (0.73–1.70)	1.43±0.30 (0.74–2.08)
Scar-healed	19	1.19±0.17 (0.92–1.59)	1.45±0.22 (1.03–1.76)
Not-healed	5	1.15±0.18 (0.98–1.43)	1.50±0.15 (1.28–1.70)

*PRD: Peripheral root dentine, SD: Standard deviation
Same superscript letters denote statistically significant differences (P<0.05) across subgroups

was noted when comparing roots with single or double canals ($P>0.05$). The alignment of the REF had no statistically significant effect on healing.

Healing outcome

After 1 year, 37 roots (60.7%) were classified as healed and 19 roots (31.1%) as healed with a scar. Only five roots (8.2%) were categorized as non-healed. None of the study parameters (REF, PRD) demonstrated statistically significant differences across the three healing groups, as shown in Tables 1 and 3. Therefore, the null hypothesis was accepted.

DISCUSSION

The present study analyzed the length and width of REF using CBCT that was taken 1 year after apical surgery. To the best of our knowledge, this is the first radiographic study evaluating REF and PRD dimensions using CBCT. This 3D clinical imaging technique has been shown to provide reliable data with regard to object dimensions and linear measurements in comparison to the gold standard (8).

One limitation of the present study was that postsurgical CBCTs were not taken immediately after surgery but only after 1 year, meaning that possible dimensional changes of the REF might have occurred. However, the used REF material, that is, MTA, has proven to be dimensionally stable (9). Another limitation of this radiographic study is the similarity in radio-opacity of MTA to the one of gutta-percha. This may impede the possibility to exactly select the cut-off point between the two materials.

The overall mean length of the REF was 2.02 ± 0.52 mm, which is shorter than the recommended length of 3 mm. The reasons for this shorter REF length may be technical (i.e., surgical access does not allow for full sink depth of the microtip, or the conical shape of the tip only removes dentine at its wider base) or radiographic (i.e., delineation between the REF and the existing root canal filling is not clear). The presence of a post or screw may also influence the REF length. However, an additional analysis demonstrated no significant difference in the mean length of the REF for roots with a post/screw (2.04 ± 0.78 mm, $n=22$) compared to roots without a post/screw (2.01 ± 0.29 mm, $n=39$). In roots with two canals, the mean REF length (1.82 mm) was significantly shorter than in roots with single canals

(2.11 mm). This could be attributed to the fact that, the length of the REF in the isthmus area of roots with two canals was usually shorter than in the canal areas (Fig. 5). Depth preparation in the isthmus area may be hampered since orthograde root-canal treatment rarely negotiates the isthmus area, and the hour-glass cross section of the root with narrowing in the isthmus area limits the retrograde preparation.

With regard to the width of REF, the obtained data reflect the different sizes of the cross sections of the treated roots. For in-

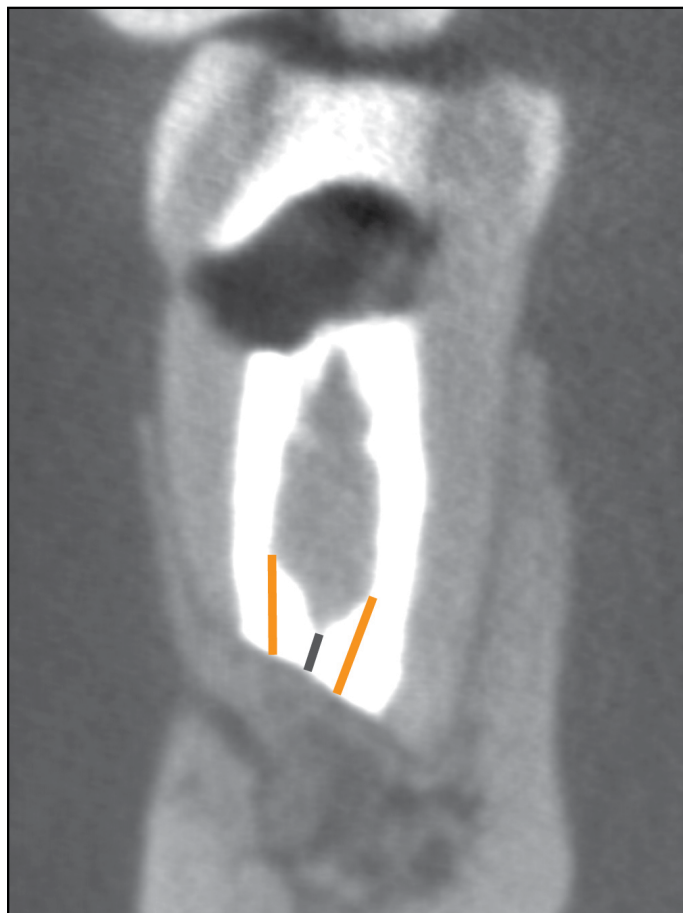

Figure 5. Measurements of the REF length in a right mandibular first molar (bucco-lingual direction, coronal CBCT).

Vertical orange lines=length of REF in the canal areas
Vertical black line=length of REF in the isthmus area

TABLE 4. Previously reported data with regard to the length of REF*

Authors and year	Technique of root-end cavity preparation	Radiographic assessment	n	Mean length of REF	Comments
von Arx et al. 1998 (10)	Sonic micro tips	Periapical radiographs, Rinn	50	3.08 mm \pm 1.03 (2-7 mm)	70% \geq 3 mm
Wang et al. 2004 (11)	Variety of ultrasonic micro tips	Periapical radiographs, Rinn	155	-	39% \leq 2 mm 61% $>$ 2 mm
Peñarrocha et al. 2007 (12)	Ultrasonic micro tips	Periapical radiographs	333	2.25 mm (0.3-4.5 mm)	Mean width of REF*: 1.1 mm (0.25-3 mm)
Barone et al. 2010 (13)	Variety of ultrasonic micro tips	Periapical radiographs, Rinn	106	-	21% \leq 2 mm 79% $>$ 2 mm
Villa-Machado et al. 2013 (14)	Rotary instruments or ultrasonic micro tips	Periapical radiographs, Rinn	171	-	52% \leq 2 mm 48% $>$ 2 mm

*REF: Root-end filling

stance, molars presented the largest mean REF width in the bucco-lingual direction, but the smallest mean REF width in the mesio-distal direction, thus reflecting the commonly oval cross section of molar roots. In particular, mesio-buccal roots of maxillary molars and mesial roots of mandibular molars, which are frequently treated with apical surgery, present such an oblong cross section.

Previous clinical studies using microsurgical instruments for root-end cavity preparation reported inconsistent lengths of the REF (10-14) (Table 4). These studies used periapical radiographs (parallel technique with the Rinn film holder) to measure the REF length. However, none of the studies provided details on how the length was actually determined (technique and instruments for measuring). Due to the distance from the object (root apex) to the radiographic film, there is some (longer) distortion of the actual REF length on the radiographic image. Furthermore, acute beveling of the cut root face also results in (longer) projection of the REF on the periapical radiograph than it actually is.

Two studies assessed the healing outcome with regard to the REF length. According to Barone et al. (13), the rate of healed cases comparing cases with the REF length ≤ 2 mm and > 2 mm did not differ significantly. Villa-Machado et al. (14) reported a rate of healed/healing cases of 87% in teeth with a REF length > 2 mm compared to 81% in teeth with a REF length ≤ 2 mm; this difference was statistically not significant. Similarly, the REF length did not statistically differ across the three healing groups in the present study.

In-vitro studies evaluated the influence of the REF length on apical leakage. Gilheany et al. (15) demonstrated that increasing the length of the REF significantly reduced the microleakage, whereas increasing the bevel of root-end resection resulted in significantly more leakage. They reported that the increased leakage was primarily due to leakage through permeable apical dentine since a resection angle of 30 or 45 degrees exposed more dentinal tubules than a flat, 0 degree cut. They recommended that the retrograde filling on a beveled resected apex should ideally be 3.5 mm deep to prevent apical leakage (15). Similarly, Valois and Costa (16) assessed the influence of the REF length on the sealing ability in an *in vitro* study using extracted single-rooted human teeth. They demonstrated that a 4 mm REF was significantly more effective in preventing leakage compared to a length ≤ 3 mm. In contrast, Rahimi et al. (17) reported no significant differences of microleakage among three different REF depths of 1 mm, 2 mm, or 3 mm in MTA-filled roots.

With regard to the PRD thickness following root-end resection and cavity preparation, only scarce data are available. In an experimental study on extracted maxillary human molars, roots containing two canals and an isthmus were subjected to a 3 mm root-end resection with subsequent root-end preparation using ultrasonic microtips (18). The authors reported a mean wall thickness of 0.43 ± 0.11 mm at the thinnest sites remaining between the retrocavity and the root surface measured at the resection level. Roy et al. (19) performed a similar analysis on human maxillary central incisors and canines to assess the minimum PRD after 3 mm root-end resection and ultrasonic

root-end cavity preparation. The mean thickness amounted to 1.2 ± 0.2 mm in central incisors and to 0.9 ± 0.19 mm in canines. In the present study, the mean PRD at the resection level of incisors and canines was 1.21 mm, thus corroborating the data from Roy and co-workers (19).

Narrow dentine walls may enhance the risk of dentine cracks, but results from *in vitro* studies are controversial. While earlier studies suggested a correlation of the incidence of crack formation and thin dentine walls (20, 21), more recent studies have refuted such an assumption (22–25). The likelihood of subclinical cracks already present before root-end management must be considered as a cause of subsequent failure (26, 27).

CONCLUSION

The mean length of the REF in the present study was 2.02 mm. On average, more than 1 mm thickness of PRD was maintained at the resection level around the REF. No correlation was observed between the study parameters (REF and PRD dimensions) and the healing outcome.

Disclosures

Conflict of interest: The authors declare that there are no conflicts of interest related to this study.

Ethics Committee Approval: Approval by ethical committee of the canton Bern/Switzerland; #KEK-BE 098/11.

Peer-review: Externally peer-reviewed.

Financial Disclosure: No external funding, apart from the support of the authors' institutions, was available for this study.

Authorship contributions: Concept – T.V.A., M.M.B.; Design – T.V.A., M.M.B.; Supervision – T.V.A., M.M.B.; Funding - None; Materials - T.V.A.; Data collection &/or processing – E.M., T.V.A., M.M.B.; Analysis and/or interpretation – E.M., T.V.A., M.M.B.; Literature search – T.V.A.; Writing – T.V.A., E.M., M.M.B.; Critical Review – T.V.A., E.M., M.M.B.

REFERENCES

- Kim S, Kratchman S. Modern endodontic surgery concepts and practice: a review. *J Endod* 2006; 32(7):601–23. [CrossRef]
- Nair PN. Pathogenesis of apical periodontitis and the causes of endodontic failures. *Crit Rev Oral Biol Med* 2004; 15(6):348–81. [CrossRef]
- Kruse C, Spin-Neto R, Christiansen R, Wenzel A, Kirkevang LL. Periapical Bone Healing after Apicectomy with and without Retrograde Root Filling with Mineral Trioxide Aggregate: A 6-year Follow-up of a Randomized Controlled Trial. *J Endod* 2016; 42(4):533–7. [CrossRef]
- Parirokh M, Shabahang S: Root-end filling materials. In: Torabinejad M, Rubinstein R, editors. *The art and science of contemporary surgical endodontics*. 1st ed. Hanover Park, IL, USA: Quintessence Publishing; 2017. p.179–202.
- Kim S. Principles of endodontic microsurgery. *Dent Clin North Am* 1997; 41(3):481–97.
- Bornstein MM, Bingisser AC, Reichart PA, Sendi P, Bosshardt DD, von Arx T. Comparison between Radiographic (2-dimensional and 3-dimensional) and Histologic Findings of Periapical Lesions Treated with Apical Surgery. *J Endod* 2015; 41(6):804–11. [CrossRef]
- von Arx T, Janner SF, Hänni S, Bornstein MM. Agreement between 2D and 3D radiographic outcome assessment one year after periapical surgery. *Int Endod J* 2016; 49(10):915–25. [CrossRef]
- Fokas G, Vaughn VM, Scarfe WC, Bornstein MM. Accuracy of linear measurements on CBCT images related to presurgical implant treatment planning: A systematic review. *Clin Oral Implants Res* 2018;29 Suppl 16:393–415. [CrossRef]
- Parirokh M, Torabinejad M. Mineral trioxide aggregate: a comprehensive literature review-Part I: chemical, physical, and antibacterial properties. *J Endod* 2010; 36(1):16–27. [CrossRef]

10. von Arx T, Kurt B, Ilgenstein B, Hardt N. Preliminary results and analysis of a new set of sonic instruments for root-end cavity preparation. *Int Endod J* 1998; 31(1):32–8. [\[CrossRef\]](#)
11. Wang N, Knight K, Dao T, Friedman S. Treatment outcome in endodontics-The Toronto Study. Phases I and II: apical surgery. *J Endod* 2004; 30(11):751–61. [\[CrossRef\]](#)
12. Peñarrocha M, Martí E, García B, Gay C. Relationship of periapical lesion radiologic size, apical resection, and retrograde filling with the prognosis of periapical surgery. *J Oral Maxillofac Surg* 2007; 65(8):1526–9. [\[CrossRef\]](#)
13. Barone C, Dao TT, Basrani BB, Wang N, Friedman S. Treatment outcome in endodontics: the Toronto study-phases 3, 4, and 5: apical surgery. *J Endod* 2010; 36(1):28–35. [\[CrossRef\]](#)
14. Villa-Machado PA, Botero-Ramírez X, Tobón-Arroyave SI. Retrospective follow-up assessment of prognostic variables associated with the outcome of periradicular surgery. *Int Endod J* 2013; 46(11):1063–76. [\[CrossRef\]](#)
15. Gilheany PA, Figdor D, Tyas MJ. Apical dentin permeability and microleakage associated with root end resection and retrograde filling. *J Endod* 1994; 20(1):22–6. [\[CrossRef\]](#)
16. Valois CR, Costa ED Jr. Influence of the thickness of mineral trioxide aggregate on sealing ability of root-end fillings in vitro. *Oral Surg Oral Med Oral Pathol Oral Radiol Endod* 2004; 97(1):108–11. [\[CrossRef\]](#)
17. Rahimi S, Shahi S, Lotfi M, Yavari HR, Charehjo ME. Comparison of microleakage with three different thicknesses of mineral trioxide aggregate as root-end filling material. *J Oral Sci* 2008; 50(3):273–7. [\[CrossRef\]](#)
18. Lin CP, Chou HG, Kuo JC, Lan WH. The quality of ultrasonic root-end preparation: a quantitative study. *J Endod* 1998; 24(10):666–70. [\[CrossRef\]](#)
19. Roy R, Chandler NP, Lin J. Peripheral dentin thickness after root-end cavity preparation. *Oral Surg Oral Med Oral Pathol Oral Radiol Endod* 2008; 105(2):263–6. [\[CrossRef\]](#)
20. Abedi HR, Van Mierlo BL, Wilder-Smith P, Torabinejad M. Effects of ultrasonic root-end cavity preparation on the root apex. *Oral Surg Oral Med Oral Pathol Oral Radiol Endod* 1995; 80(2):207–13. [\[CrossRef\]](#)
21. Frank RJ, Antrim DD, Bakland LK. Effect of retrograde cavity preparations on root apices. *Endod Dent Traumatol* 1996; 12(2):100–3. [\[CrossRef\]](#)
22. Gondim E Jr, Gomes BP, Ferraz CC, Teixeira FB, Souza-Filho FJ. Effect of sonic and ultrasonic retrograde cavity preparation on the integrity of root apices of freshly extracted human teeth: scanning electron microscopy analysis. *J Endod* 2002; 28(9):646–50. [\[CrossRef\]](#)
23. Khabbaz MG, Kerezoudis NP, Aroni E, Tsatsas V. Evaluation of different methods for the root-end cavity preparation. *Oral Surg Oral Med Oral Pathol Oral Radiol Endod* 2004; 98(2):237–42. [\[CrossRef\]](#)
24. de Bruyne MA, De Moor RJ. SEM analysis of the integrity of resected root apices of cadaver and extracted teeth after ultrasonic root-end preparation at different intensities. *Int Endod J* 2005; 38(5):310–9. [\[CrossRef\]](#)
25. Tobón-Arroyave SI, Restrepo-Pérez MM, Arismendi-Echavarría JA, Velásquez-Restrepo Z, Marín-Botero ML, García-Dorado EC. Ex vivo microscopic assessment of factors affecting the quality of apical seal created by root-end fillings. *Int Endod J* 2007; 40(8):590–602. [\[CrossRef\]](#)
26. Tawil PZ, Saraiya VM, Galicia JC, Duggan DJ. Periapical microsurgery: the effect of root dentinal defects on short- and long-term outcome. *J Endod* 2015; 41(1):22–7. [\[CrossRef\]](#)
27. Tawil PZ, Arnarsdottir EK, Phillips C, Saemundsson SR. Periapical Microsurgery: Do Root Canal-retreated Teeth Have More Dentinal Defects? *J Endod* 2018; 44(10):1487–91. [\[CrossRef\]](#)