

## Negotiating and Treating Lateral Canals: A Report of 7 Cases

 Luis Felipe JIMÉNEZ-ROJAS,<sup>1,2,3</sup>  Liliana Patricia ARTAZA,<sup>1,4</sup>  Vanessa Pandolfi PESSOTTI,<sup>1,5</sup>  
 Débora Parra SELLERA,<sup>1,6</sup>  Jorge Carlos ALBERDI,<sup>1,7</sup>  Alessandra Cristina BAASCH,<sup>2,8</sup>  
 Karen BRISSON-SUÁREZ,<sup>1,2</sup>  Flávio Rodrigues Ferreira ALVES,<sup>2</sup>  Isabela das Neves RÔÇAS,<sup>1,2</sup>  
 José Freitas SIQUEIRA Jr<sup>1,2</sup>

<sup>1</sup>Endo Chat Research Group, Rio de Janeiro, Brazil

<sup>2</sup>Postgraduate Program in Dentistry, University of Grande Rio (UNIGRANRIO), Rio de Janeiro, Brazil

<sup>3</sup>Department of Endodontics, Central University of Venezuela, Caracas, Venezuela

<sup>4</sup>Department of Endodontics, Maimonides University, Buenos Aires, Argentina

<sup>5</sup>Private Practice, Vila Velha, Brazil

<sup>6</sup>Private Practice, Santos, Brazil

<sup>7</sup>Department of Endodontics, Catholic University of Córdoba, Córdoba and National University of Northeast, Faculty of Health Sciences, Corrientes, Argentina

<sup>8</sup>Department of Endodontics, Santa María University, Caracas, Venezuela

### ABSTRACT

This is a series of 7 cases in which the operator penetrated lateral canals with instruments. Two teeth presented with irreversible pulpitis, 4 with necrotic pulps, and 1 with previous treatment. Except for the teeth with pulpitis, all the others were associated with apical periodontitis. The main root canal was always relatively straight, with the lateral canals at the middle third of the root. Suggestive images of lateral canal presence were seen on periapical radiographs in five cases. The clinician introduced intentionally small hand instruments in the lateral canal in 5 cases, while the penetration was fortuitous in the others. The lateral canals were filled in all cases. Follow-up examination was possible in five cases, all of them showed evidence of successful clinical and radiographic outcomes. Introducing files into lateral canals may permit some preparation and penetration of irrigant solution, favoring disinfection and, consequently, enhancing the treatment outcome.

**Keywords:** Apical periodontitis, lateral canal, root canal infection, root canal treatment

#### Please cite this article as:

Jiménez-Rojas LF, Artaza LP, Pessotti VP, Sellera DP, Alberdi JC, Baasch AC, Brisson-Suárez K, Alves FRF, Rôças IN, Siqueira Jr JF. Negotiating and Treating Lateral Canals: A Report of 7 Cases. *Eur Endod J* 2024; 9: 287-94

#### Address for correspondence:

Flávio Rodrigues Ferreira Alves  
 Postgraduate Program in  
 Dentistry, University of Grande Rio  
 (UNIGRANRIO), Rio de Janeiro, Brazil  
 E-mail: flavioferreiraalves@gmail.com

**Received :** May 24, 2023,

**Revised :** December 01, 2023,

**Accepted :** December 07, 2023

**Published online:** August 06, 2024  
 DOI 10.14744/ej.2023.43265

This work is licensed under  
 a Creative Commons  
 Attribution-NonCommercial  
 4.0 International License.



### HIGHLIGHTS

- This report presents seven cases in which clinicians succeeded in introducing files into lateral canals.
- All lateral canals were located at the middle portion of the root.
- The lateral canals were adequately filled in all cases.
- All cases showed evidence of successful clinical and radiographic outcomes.

### INTRODUCTION

The root canal system usually exhibits complex internal anatomy with high prevalence of lateral and accessory canals (1). Lateral canals are defined as accessory canals located in the coronal or middle third of the root, usually extending horizontally from the main canal space (2). Frequent-

ly, the content of the lateral canals remains unaltered by chemical and mechanical procedures, regardless of the technique or irrigant used (3).

The main cause of post-treatment apical periodontitis is the persistence of bacteria in the root canal system after chemo-mechanical pro-

cedures (4, 5). Once the bacterial infection spreads from the main canal to lateral ramifications, it can induce and maintain periradicular inflammation, while frank access to a sustainable source of nutrients is also achieved (3).

In addition, the time that the irrigant remains in the canal may be insufficient to diffuse, reach and kill bacteria located in lateral canals, compromising disinfection (6, 7). Different instruments and strategies have been proposed to promote or improve the cleaning and disinfection of these difficult-to-reach areas, but the results are unpredictable (8, 9). Because of physical limitations dictated by the usual small diameter and a tortuous path of lateral canals, it is tricky or even impossible for endodontic instruments to reach and promote an effective cleaning of these anatomic areas (10, 11). The reports on the use of instruments to clean lateral canals are limited (12).

This case series aimed to report seven clinical cases in which the operator intentionally or unintentionally negotiated lateral canals with the instruments, favoring cleaning and disinfection before filling these difficult-to-reach anatomic areas.

### CASE SERIES

This case series has been written according to Reporting Items for Root and Canal Anatomy in Case Reports (PROUD) 2020 guidelines (13). The reports comprised 7 patients undergoing root canal treatment by four endodontic specialists (two from Brazil and the other two from Argentina), and each one had one tooth with a lateral canal that could be negotiated by instruments. Pulpal and periapical diagnoses were based on signs and symptoms, pulp and periapical tests, periapical radiographs, and cone-beam computed tomography (CBCT) findings. Clinical and radiographic data are listed in Table 1. All teeth were treated under local anesthesia following aseptic measures, including rubber dam isolation and operative field decontamination. Consent for treatment was given by all patients included in this case series.

#### First Case

A 45-year-old male patient attended the dental consultation with irreversible pulpitis in tooth #35. A lateral canal was disclosed by chance during root canal exploration with a small stainless steel K-file (#10) (Dentsply-Maillefer, Ballaigues, Switzerland). The electronic apex locator (Propex Pixi, Dentsply-Maillefer, Ballaigues, Switzerland) indicated that the apical terminus was far shorter than the measures obtained in the diagnostic radiograph. A periapical radiograph was taken to evaluate the instrument length in the canal and revealed the presence of a lateral canal (Fig. 1). Without removing the instrument from this position, it was used to slightly debride the lateral canal with gentle manual oscillating and filing motions. The main root canal was then prepared, followed by passive ultrasonic irrigation (PUI) using the Irrisonic tip (Helse Ultrasonics, Ocoee, USA) to activate both sodium hypochlorite 2.5% (NaOCl) and ethylenediamine tetraacetic acid 17% (EDTA), each one for 1 min, in sequence. Next, the root canal was filled by the vertical compaction technique using Calamus Dual device (Dentsply, Tulsa, USA), with gutta-percha and AH Plus root canal sealer

(Dentsply Sirona, Charlotte, USA). The filling material penetrated into the lateral canal successfully (Fig. 1). The treatment was completed in a single appointment.

#### Second Case

A 57-year-old female patient attended the dental office because of irreversible pulpitis in the left mandibular canine (#33) that presented with two roots. Clinical tests and radiographic evaluation determined the diagnosis. The lateral canal was not evident on radiographs and was discovered by chance, after an unexpected reading by the electronic apex locator (Propex Pixi, Dentsply-Maillefer, Ballaigues, Switzerland) during the negotiation of the main canal of the buccal root with a hand K-type file #10 (Dentsply-Maillefer, Ballaigues, Switzerland). Without removing the instrument, a radiograph was taken and revealed that it was penetrating a lateral canal. Gentle instrumentation was conducted in the lateral canal using the #10 and a #15 file. The main root canals were then prepared with WaveOne primary (#25/.07) (Dentsply Maillefer) up to the WL, and supplementary activation of 2.5% NaOCl and 17% EDTA was performed using ultrasonics and the EndoActivator device (Dentsply-Tulsa, Oklahoma, USA). The definitive canal filling was placed using the vertical compaction technique with gutta-percha and the AH Plus sealer (Dentsply Sirona, Charlotte, USA), and the lateral canal was also filled (Fig. 2). The treatment was concluded in a single visit.

#### Third Case

A 75-year-old male patient attended the dental office with a chronic apical abscess associated with a root canal-treated maxillary right central incisor (#11). A lateral canal was suspected on the radiographs based on an apparent laterally overfilled radiopaque material and was intentionally searched for during retreatment. After removing the previous filling material, the lateral canal was successfully detected and confirmed by periapical radiography and under the operating microscope (Microscope Decius Advanced DFVasconcellos, Valença, Brazil). The main canal was enlarged around the lateral canal to facilitate access and visualization. The lateral canal was negotiated with a hand stainless steel K-type file #10 (Dentsply-Maillefer, Ballaigues, Switzerland) and then enlarged to instrument #20 (Dentsply-Maillefer, Ballaigues, Switzerland). The main canal was re-instrumented up to the WL, and supplementary approaches with PUI for 5.25% NaOCl (Fórmula&Ação, SP, Brazil); and 17% EDTA (Fórmula&Ação, São Paulo, Brazil), as well as photodynamic therapy (PDT) (Laser Duo, MMOptics, São Carlos, SP, Brazil and methyleneblue 0,05%, Chimiolux-DMC, São Carlos, Brazil) were conducted. An interappointment medication with calcium hydroxide was placed. Next, the apical canal was filled with Mineral Trioxide Aggregate (MTA Repair HP, Angelus, Londrina, PR, Brazil). Filling material successfully penetrated the lateral canal. In another session, the FibreKor fiberglass post (Pentron, Orange, USA) was installed with Relyx dual resin cement (3M, Sumaré, Brazil) (Fig. 3).

#### Forth Case

A 60-year-old female patient presented for root canal treatment of the maxillary right central incisor (#11), diagnosed with pulp

**TABLE 1.** Case description

	Case 1	Case 2	Case 3	Case 4	Case 5	Case 6	Case 7
Age	45	57	75	60	25	40	34
Gender	Male	Female	Male	Female	Female	Male	Male
Tooth and accessory canal classification*	'35(MH)	'33 B(MH) L	'11(MH)	'11(MH)	'21(MH)	'21(MH)	'31(MH)
Pulp diagnosis	Irreversible pulpitis	Irreversible pulpitis	Previously treated Chronic apical abscess	Pulp necrosis Asymptomatic apical periodontitis	Pulp necrosis Symptomatic apical periodontitis	Pulp necrosis Asymptomatic apical periodontitis	Pulp necrosis Asymptomatic apical periodontitis
Periapical diagnosis	Normal	Normal	Ca(OH) <sub>2</sub> +saline	Ca(OH) <sub>2</sub> +propylene glycol	Ca(OH) <sub>2</sub> +propylene glycol	CPMC	CPMC
Intracanal medication	No	No	Intentional	Intentional	Intentional	Intentional	Intentional
Penetration in the LC	Fortuitous	Fortuitous	Yes	Yes	Yes	No	Yes
Irrigation activation	Yes	Yes	NaOCl	NaOCl	NaOCl	NaOCl	NaOCl
Irrigant used	EDTA	EDTA	EDTA	EDTA	EDTA	EDTA	EDTA
Obturation technique	Vertical compaction	Vertical compaction	Apical Plug	Vertical compaction	Vertical compaction	Thermafil	Vertical compaction
Filling material	Gutta-percha	Gutta-percha	MTA	Gutta-percha	Gutta-percha	Gutta-percha	Gutta-percha
Sealer	AH Plus	AH Plus	No sealer, only FibreKor fiberglass	Pulp Canal Sealer	Pulp Canal Sealer	AH 26	AH 26
Use of magnification	No	No	Yes	Yes	Yes	No	No

\*: Classification according to Ahmed et al., (34). CPMC: Camphorated paramonochlorophenol, LC: Lateral canal, NaOCl: Sodium hypochlorite, EDTA: Ethylenediamine tetraacetic acid

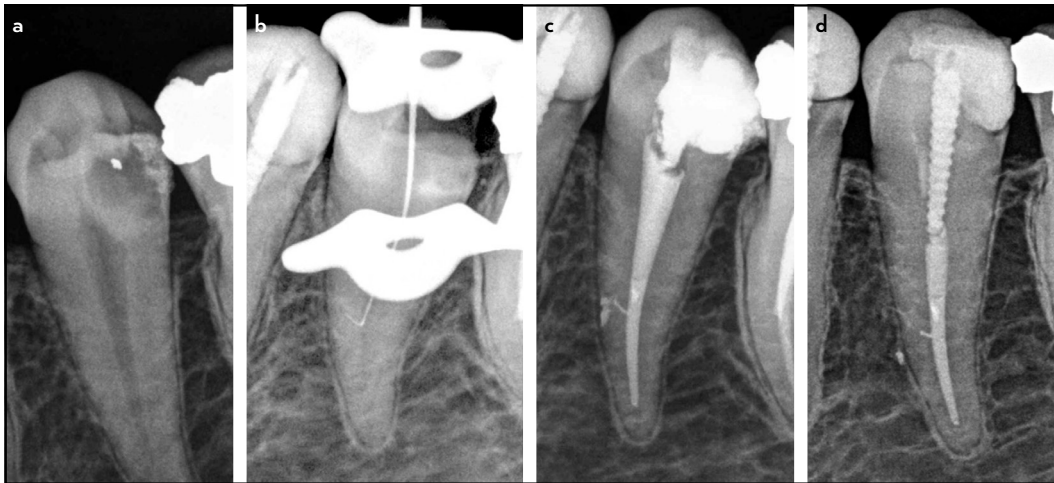
necrosis and apical periodontitis based on clinical and radiographic evaluations. A lateral canal was evident on the initial radiograph and was intentionally sought during the main canal negotiation. A small SS K-type file #10 (Target K Easy, Belo Horizonte, Brazil) was successfully used to find and explore the lateral canal, whose presence was confirmed by the electronic apex locator (NSK iPEX II electronic apex locator, Joinville, Brazil), periapical radiography, and magnification/illumination by the dental operating microscope (Microscope Decius Advanced DFVasconcellos, Valença, Brazil). The lateral canal was initially instrumented with hand K-type files #10 and #15. Next, the main canal was prepared to the WL and subjected to supplementary ultrasonic activation of 2.5% NaOCl (Farmaderm, Vitória, Brazil) and 17% EDTA (Farmaderm, Vitória, Brazil), followed by PDT (Laser Duo MM Optics, São Carlos, Brazil). An intracanal medication with calcium hydroxide in propyleneglycol was placed for one week. The canal was then filled by the vertical compaction technique using gutta-percha and Pulp Canal Sealer (Kerr, Orange, USA). The lateral canal was successfully filled. Clinical and radiographic follow-up at 3 years showed a favourable outcome (Fig. 4).

**Fifth Case**

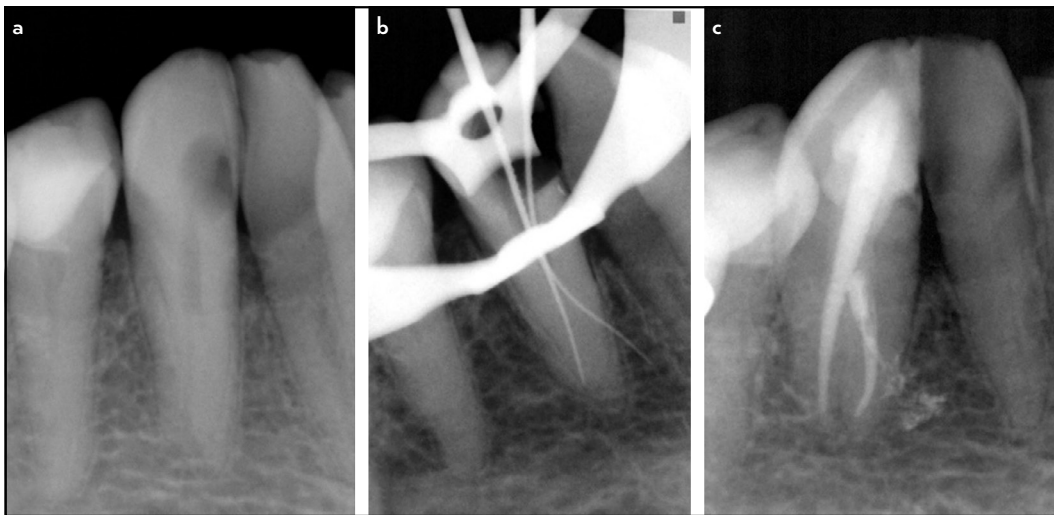
A 25-year-old female patient was referred for root canal treatment of the maxillary left central incisor (#21) with pulp necrosis and symptomatic apical periodontitis. A lateral canal was suspected on initial radiographs and looked for during the main canal negotiation. The lateral canal was located using a hand K-type file #10 (Target K Easy, Belo Horizonte, Brazil) and confirmed by the electronic apex locator (NSK iPEX II electronic apex locator, Joinville, Brazil), periapical radiograph, and visualization of its entrance under the operating microscope. The lateral canal was enlarged up to hand file #20. After the preparation of the main canal, 2.5% NaOCl (Farmaderm, Vitória, Brazil) and 17% EDTA (Farmaderm, Vitória, Brazil), were ultrasonically activated, and an intracanal medication with calcium hydroxide in propyleneglycol (Farmaderm, Vitória, Brazil) was placed for one week. Root canal filling was then placed using the vertical compaction technique and Pulp Canal Sealer (Kerr, Orange, USA). Penetration of the filling material into the lateral canal was observed on the post obturation radiographs. A follow-up examination at 15 months showed that periapical healing was in progress, and normal periodontal ligament space was associated with the lateral canal (Fig. 5).

**Sixth Case**

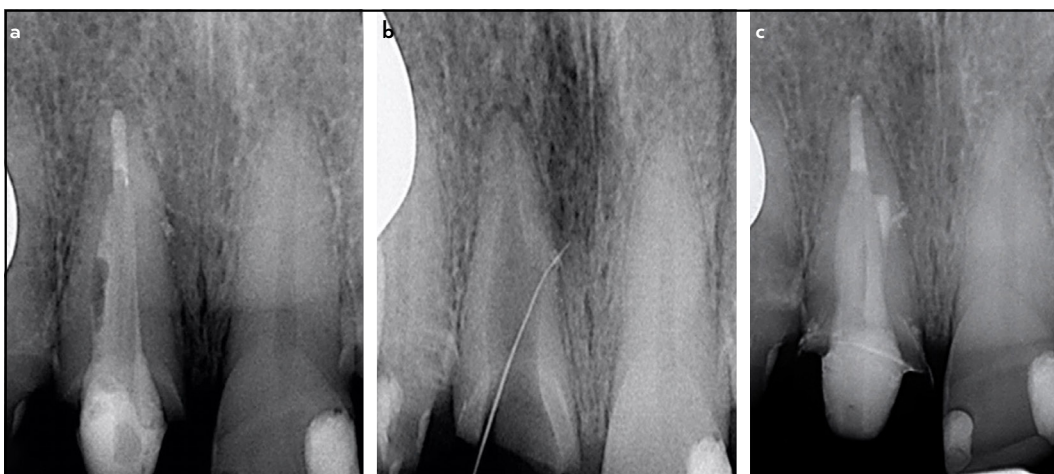
A 40-year-old male patient showed up at the dental office for root canal treatment of the maxillary left central incisor (#21). This tooth was diagnosed with pulp necrosis and asymptomatic apical periodontitis based on the clinical and radiographic examination. A lateral canal was highly suspected because of a lateral lesion on the initial radiographs, independent of the periapical lesion. Efforts were made to locate and negotiate the lateral canal with K-type files #10 and #15 (Dentsply-Maillefer, Ballaigues, Switzerland). The main canal was then prepared up to the WL using 2.5% NaOCl (Tedequim, Córdoba, Argentina) irrigation and a final rinse with 17% EDTA (Densell, Buenos Aires, Argentina) for smear layer removal. An intracanal medication with camphorated paramonochlorophenol (CPMC) (Farmadental, Buenos Aires, Argentina) was placed for



**Figure 1.** Case 1, tooth 35 with irreversible pulpitis. (a) initial; (b) instrument in the lateral canal; (c) after root canal filling; and (d) 1-year follow-up radiographs



**Figure 2.** Case 2, tooth 33 with irreversible pulpitis. (a) initial; (b) instrument in the lateral canal; and (c) after root canal filling

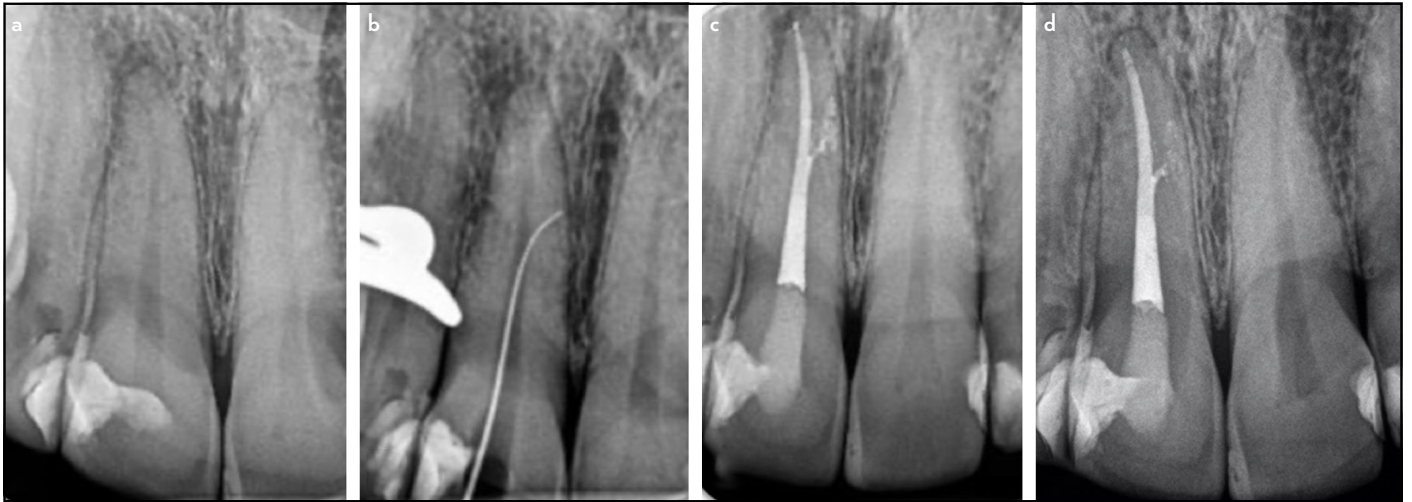

**Figure 3.** Case 3, tooth 11, retreatment of a tooth with chronic apical abscess. (a) initial; (b) instrument in the lateral canal; and (c) after root canal filling

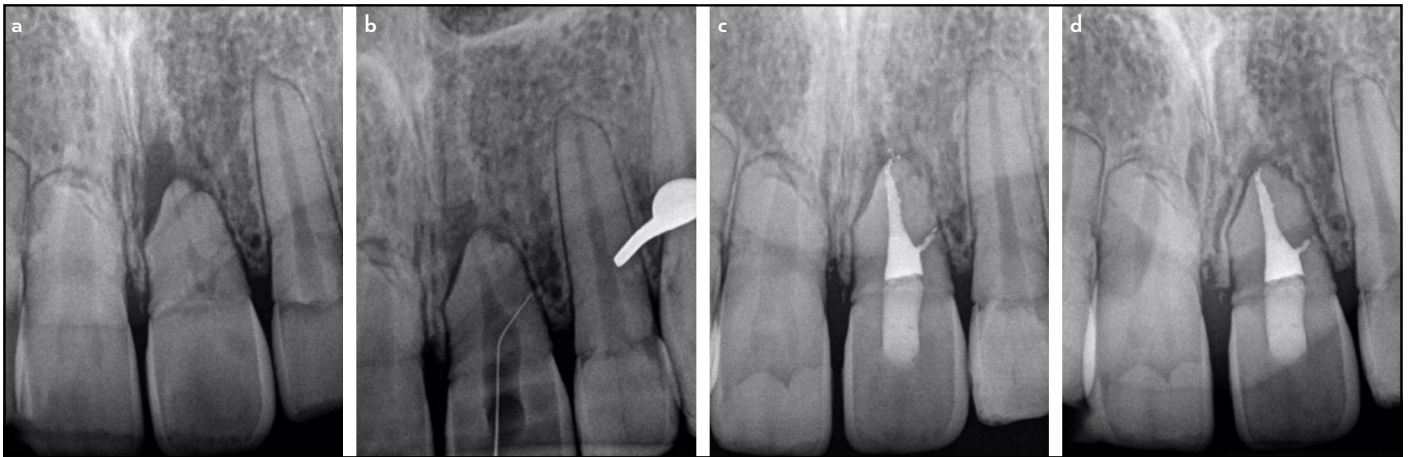
one week. In sequence, the canal was filled using the Thermafil technique (Dentsply-Maillefer, Ballaigues, Switzerland) and AH 26 root canal sealer (Dentsply-Maillefer, Tulsa, Oklahoma). Fill-

ing material was observed within the lateral canal. A follow-up examination at 3 years revealed that both the periapical and lateral lesions had been repaired (Fig. 6).

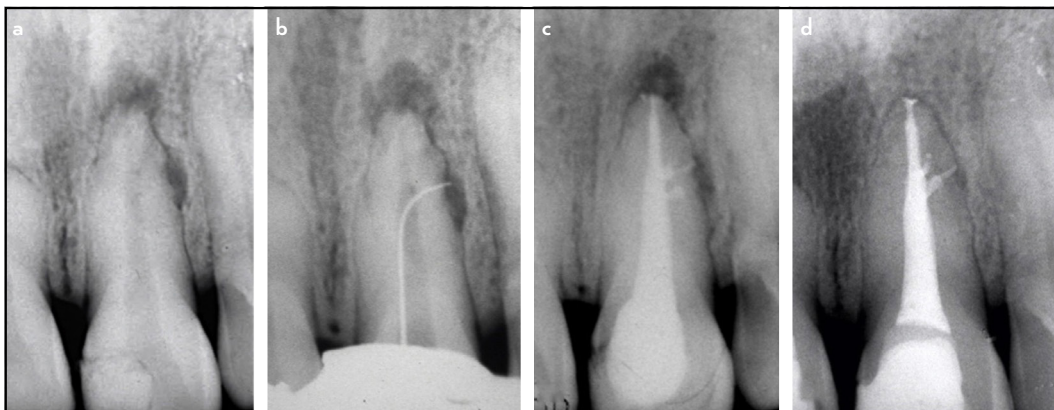




**Figure 4.** Case 4, tooth 11, necrotic pulp with apical periodontitis. (a) initial; (b) instrument in the lateral canal; (c) after root canal filling; and (d) 3-year follow-up radiographs



**Figure 5.** Case 5, tooth 21, necrotic pulp with apical periodontitis. (a) initial; (b) instrument in the lateral canal; (c) after root canal filling; and (d) 1-year follow-up radiographs

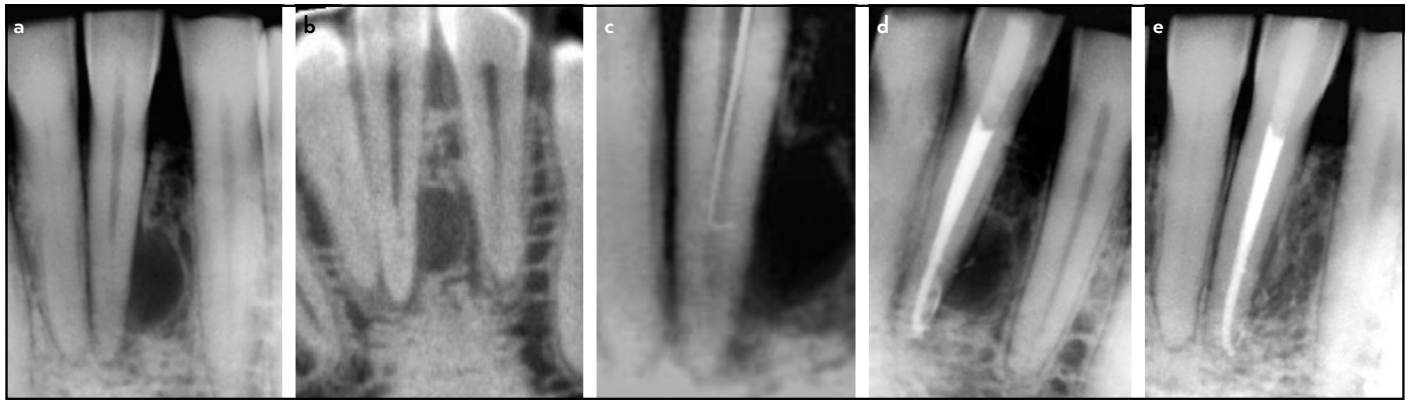

**Figure 6.** Case 6, tooth 21, necrotic pulp with apical and lateral periodontitis. (a) initial; (b) instrument in the lateral canal; (c) after root canal filling; and (d) 3-year follow-up radiographs

### Seventh Case

A 34-year-old male patient was referred to the endodontist for treatment of the mandibular left central incisor (#31) with pulp necrosis and asymptomatic apical periodontitis. Radiographs and a CBCT with voxel size 0.080×0.080, 90 kV, 8.0 mA, and 4×4 cm field of view (3D Accuitomo 170, J. Morita Cor-

poration, Kyoto, Japan) revealed a large lateral lesion, highly suggestive of being related to a lateral canal. There was also some involvement of the periapical bone. The lateral canal was successfully located and penetrated by a hand K-type file #10 (Dentsply-Maillefer, Ballaigues, Switzerland), but no further preparation was performed because of the abrupt instrument



**Figure 7.** Case 7, tooth 31, necrotic pulp with lateral periodontitis. (a) initial; (b) CBCT image; (c) instrument in the lateral canal; (d) after root canal filling; and (e) 1-year follow-up radiographs

CBCT: Cone-beam computed tomography

curvature and risk of fracture. The canal was instrumented to the WL using 2.5% NaOCl (Tedequim, Córdoba, Argentina) irrigation, followed by ultrasonic activation of NaOCl and 17% EDTA (Densell, Buenos Aires, Argentina) and intracanal medication with CPMC (Farmadental, Buenos Aires, Argentina) for one week. The canal was obturated using the vertical compaction technique (EQV, Metabiomed, Seoul, Korea) and AH 26 root canal sealer (Dentsply Maillefer, Tulsa, OK, USA). Filling material was successfully forced into the lateral canal. A twelve-month follow-up examination showed virtually complete healing of the periapical and lateral tissues (Fig. 7).

## DISCUSSION

Lateral canals are generally small in size (1, 14), and are not often sought after by the clinician, except when a lateral lesion is present or the lateral canal is sufficiently large to be visible on the radiograph or CBCT. Five of the reported cases showed suggestive images of a lateral canal on periapical radiographs. In these cases, the clinician intentionally tried and succeeded in introducing small hand files in these lateral canals. In the other two cases, penetration of files in the lateral canals was fortuitous, and only revealed by unexpectedly too-short readings from the electronic apex locators. The fact that instruments were introduced in the lateral canals, deliberately or not, indicates that they were large enough with potential to be detected by radiographs and negotiated.

As mentioned above, another highly suggestive indication of the presence of a lateral canal is the observation of a radiolucent bone lesion in the lateral root aspect, as evident in two of the reported cases. Lateral canals are associated with lateral inflammatory lesions when the pulp in the main root canal is necrotic and infected, and when the lateral canal is large enough to permit either the passage of a large number of bacterial virulence factors or colonization by a large number of bacterial cells (3). In these teeth with lateral lesions, the condition of the tissue within the lateral canal cannot be determined clinically. Histopathologically, the tissue within the lateral canal may be either vital with varying degrees of inflammation or necrotic/infected (3). Sometimes, the tissue in the lateral canal may show partial necrosis, with the segment close to the canal being necrotic and infected while its portion close to the lateral

periodontitis lesion is severely inflamed. If the lateral canal is infected, forcing filling materials within it may not suffice to control infection because the filling materials usually have low antibacterial activity and only for a short period before setting (15, 16). Ideally, the lateral canal should be disinfected before filling. As it is usually impossible to introduce instruments in the large majority of lateral canals, because of their sizes or location in the root, their disinfection should rely on irrigants and interappointment medications (17–19). The cases reported here are apparent exceptions in that instruments were successfully introduced in the lateral canal and paved the way to promote some extent of disinfection and drive the irrigant into it. The two cases showing lateral lesions healed completely, suggesting that the infection in the lateral canal was controlled.

CBCT has been widely used as a valuable diagnostic tool in endodontics. It can reveal the location of the lateral canal in the root more accurately, and may guide the clinician in his/her attempts to penetrate the lateral canal with instruments (20). However, of the cases reported here, the CBCT was used for only one case. This was either because the case was treated before CBCT was widely available or because the cases showed no great complexity that would require further CBCT evaluation. Although CBCT effectiveness is not optimal for evaluating lateral canals (21), high-resolution CBCT with a radiation dose increment might amplify their detection (20). However, the benefits of this diagnostic information should be weighed against the increased radiation dose exposure.

The penetration of instruments in lateral canals is challenging, not only because of their small diameter but also because of their location and morphology. All cases reported here were of teeth with relatively straight roots with the lateral canals exiting at the middle third of the root. In 3 cases, the operating microscope helped the clinician to see and locate the lateral canal entrance. Indeed, some authors (12) have recommended that those lateral canals observed in the middle third of the root can be mechanically prepared by precuring small diameter files and with the aid of the operating microscope.

Because the retention time of the irrigant in the canal is usually short, it may not diffuse sufficiently to eliminate bacteria

and tissue remnants in the lateral canal (22). Activation of the irrigant, especially NaOCl, has been recommended to drive it into canal irregularities, including lateral canals, and improve disinfection of the canal system (23–25). In the present study, different clinicians conducted ultrasonic activation of NaOCl and EDTA in all but one case. In 2 cases, PDT procedures were also conducted to improve disinfection. It is important to point out that the effectiveness of PDT to supplement disinfection in the canal has yet to be demonstrated (26, 27).

Except for two cases with irreversible pulpitis treated in one session, the other 5 cases were treated in two or more visits using calcium hydroxide pastes in different vehicles. Antimicrobial intracanal medication has been recommended to improve the disinfection of the root canals, especially in areas not affected by the chemomechanical procedures (19, 28). Because it remains in the canal for one week or more, the antimicrobial medication has more time to diffuse and reach bacteria located in areas distant from the main canal lumen (19, 29).

Thermoplasticized gutta-percha techniques were used for root canal filling in all cases reported herein. These approaches permit a better filling of root canal irregularities and have been assumed to be more associated with the penetration of filling material in lateral ramifications (30, 31). Indeed, filling material was evident within the lateral canal in all cases reported.

Lateral canals often escape routine radiographic detection and have gained increasing attention in endodontic practice due to the potential clinical implications. Previous case reports addressed the surgical and conservative management strategies to approach these intricate canal systems. In a case report by Kim et al. (32), a surgical approach was undertaken to manage a lateral canal in a maxillary premolar since conventional root canal retreatment led to incomplete healing. A fast-setting calcium silicate cement was used to fill the lateral canal under magnification, and the lesion disappeared after 9 months. Parirokh and Hatami (33) presented a case report demonstrating the conservative treatment of an infected lateral canal. The authors utilized a conservative retreatment approach to address the infected canal, achieving a favorable outcome. In the present case series, all canals were treated with conservative approaches. These reports collectively emphasize the intricate nature of lateral canals and their potential implications in endodontic practice.

## CONCLUSION

This article reports on 7 cases in which different clinicians succeeded in introducing files into lateral canals, deliberately or not. The cases showed no significant anatomical complexities as the roots were relatively straight, and the entrance of the lateral canals was located at the middle portion of the root. It was possible to follow-up the patients in five of these cases, two of them with lateral apical periodontitis, and all of these showed excellent clinical and radiographic outcomes. Although rare and challenging to perform in most cases, introducing files into lateral canals may permit some preparation and penetration of irrigant solution in this area, favoring disinfection and, consequently, the treatment outcome.

## Disclosures

**Informed consent:** Written informed consent was obtained from the patients for the publication of the case report and the accompanying images.

**Authorship Contributions:** Concept – J.F.S.J.; Design – J.F.S.J.; Supervision – J.F.S.J., I.N.R., F.R.F.A.; Materials – L.P.A., V.P.P., D.P.S., J.C.A., L.F.J.R., A.C.B., K.B.S.; Data collection and/or processing – L.P.A., V.P.P., D.P.S., J.C.A., L.F.J.R., A.C.B., K.B.S.; Data analysis and/or interpretation – J.F.S.J., I.N.R., F.R.F.A.; Literature search – L.F.J.R., A.C.B., K.B.S.; Writing – J.F.S.J., I.N.R., F.R.F.A.; Critical review – J.F.S.J., I.N.R., F.R.F.A.

**Conflict of Interest:** All authors declared no conflict of interest.

**Use of AI for Writing Assistance:** Not declared.

**Financial Disclosure:** This study was supported by grants from Fundação Carlos Chagas Filho de Amparo à Pesquisa do Estado do Rio de Janeiro (FAPERJ).

**Peer-review:** Externally peer-reviewed.

## REFERENCES

- Vertucci FJ. Root canal morphology and its relationship to endodontic procedures. *Endod Topics* 2005; 10:26. [CrossRef]
- American Association of Endodontists (AAE). Glossary of endodontic terms. Revised 2020. Available at: <https://www.aae.org/specialty/clinical-resources/glossary-endodontic-terms.pdf> Accessed on Jan 23, 2024.
- Ricucci D, Siqueira JF, Jr. Fate of the tissue in lateral canals and apical ramifications in response to pathologic conditions and treatment procedures. *J Endod* 2010; 36(1):1–15. [CrossRef]
- Waltimo T, Trope M, Haapasalo M, Orstavik D. Clinical efficacy of treatment procedures in endodontic infection control and one year follow-up of periapical healing. *J Endod* 2005; 31(12):863–6. [CrossRef]
- Zandi H, Petronijevic N, Mdala I, Kristoffersen AK, Enersen M, Rôças IN, et al. Outcome of endodontic retreatment using 2 root canal irrigants and influence of infection on healing as determined by a molecular method: a randomized clinical trial. *J Endod* 2019; 45(9):1089–98. [CrossRef]
- Kanter V, Weldon E, Nair U, Varella C, Kanter K, Anusavice K, et al. A quantitative and qualitative analysis of ultrasonic versus sonic endodontic systems on canal cleanliness and obturation. *Oral Surg Oral Med Oral Pathol Oral Radiol Endod* 2011; 112(6):809–13. [CrossRef]
- de Gregorio C, Paranjpe A, Garcia A, Navarrete N, Estevez R, Esplugues EO, et al. Efficacy of irrigation systems on penetration of sodium hypochlorite to working length and to simulated uninstrumented areas in oval shaped root canals. *Int Endod J* 2012; 45(5):475–81. [CrossRef]
- Siqueira JF, Jr., Rocas IN. Optimising single-visit disinfection with supplementary approaches: a quest for predictability. *Aust Endod J* 2011; 37(3):92–8. [CrossRef]
- Pacheco-Yanes J, Provenzano JC, Marceliano-Alves MF, Gazzaneo I, Pérez AR, Gonçalves LS, Siqueira JF, et al. Distribution of sodium hypochlorite throughout the mesial root canal system of mandibular molars after adjunctive irrigant activation procedures: a micro-computed tomographic study. *Clin Oral Investig* 2020; 24(2):907–14. [CrossRef]
- Mazzi-Chaves JF, Silva-Sousa YTC, Leoni GB, Silva-Sousa AC, Estrela L, Estrela C, et al. Micro-computed tomographic assessment of the variability and morphological features of root canal system and their ramifications. *J Appl Oral Sci* 2020; 28:e20190393. [CrossRef]
- Xu T, Tay FR, Gutmann JL, Fan B, Fan W, Huang Z, et al. Micro-computed tomography assessment of apical accessory canal morphologies. *J Endod* 2016; 42(5):798–802. [CrossRef]
- Chaniotis A, Filippatos CG. The Use of a Novel Approach for the Instrumentation of a Cone-beam Computed Tomography-discernible Lateral Canal in an Unusual Maxillary Incisor: Case Report. *J Endod* 2017; 43(6):1023–7. [CrossRef]
- Ahmed HMA, Rossi-Fedele G. Preferred reporting items for root and canal anatomy in the human dentition (PROUD 2020) - A systematic review and a proposal for a standardized protocol. *Eur Endod J* 2020; 5(3):159–76. [CrossRef]
- Dammaschke T, Witt M, Ott K, Schafer E. Scanning electron microscopic investigation of incidence, location, and size of accessory foramina in primary and permanent molars. *Quintessence Int* 2004; 35(9):699–705.
- Orstavik D. Antibacterial properties of root canal sealers, cements and pastes. *Int Endod J* 1981; 14(2):125–33. [CrossRef]



16. Kayaoglu G, Erten H, Alacam T, Orstavik D. Short-term antibacterial activity of root canal sealers towards *Enterococcus faecalis*. *Int Endod J* 2005; 38(7):483–8. [\[CrossRef\]](#)
17. Siqueira Junior JF, Rôças IDN, Marceliano-Alves MF, Pérez AR, Ricucci D. Unprepared root canal surface areas: causes, clinical implications, and therapeutic strategies. *Braz Oral Res* 2018; 32(Suppl 1):e65. [\[CrossRef\]](#)
18. Vieira AR, Siqueira JF, Jr., Ricucci D, Lopes WS. Dentinal tubule infection as the cause of recurrent disease and late endodontic treatment failure: a case report. *J Endod* 2012; 38(2):250–4. [\[CrossRef\]](#)
19. Ricucci D, Russo J, Rutberg M, Burleson JA, Spångberg LS. A prospective cohort study of endodontic treatments of 1,369 root canals: results after 5 years. *Oral Surg Oral Med Oral Pathol Oral Radiol Endod* 2011; 112(6):825–42. [\[CrossRef\]](#)
20. Ji Y, Wen S, Liu S, Zhu M, Yao M, Wang T, et al. Could cone-beam computed tomography demonstrate the lateral accessory canals? *BMC Oral Health* 2017; 17(1):142. [\[CrossRef\]](#)
21. Sousa TO, Hassan B, Mirmohammadi H, Shemesh H, Haiter-Neto F. Feasibility of Cone-beam Computed Tomography in Detecting Lateral Canals before and after Root Canal Treatment: An *Ex Vivo* Study. *J Endod* 2017; 43(6):1014–7. [\[CrossRef\]](#)
22. Alves FR, Almeida BM, Neves MA, Rôças IN, Siqueira JF Jr. Time-dependent antibacterial effects of the self-adjusting file used with two sodium hypochlorite concentrations. *J Endod* 2011; 37(10):1451–5. [\[CrossRef\]](#)
23. Vera J, Arias A, Romero M. Effect of maintaining apical patency on irrigant penetration into the apical third of root canals when using passive ultrasonic irrigation: an *in vivo* study. *J Endod* 2011; 37(9):1276–8. [\[CrossRef\]](#)
24. Pereira TC, Dijkstra RJB, Petridis X, Sharma PK, van de Meer WJ, van der Sluis LWM, et al. Chemical and mechanical influence of root canal irrigation on biofilm removal from lateral morphological features of simulated root canals, dentine discs and dentinal tubules. *Int Endod J* 2021; 54(1):112–29. [\[CrossRef\]](#)
25. de Gregorio C, Estevez R, Cisneros R, Heilborn C, Cohenca N. Effect of EDTA, sonic, and ultrasonic activation on the penetration of sodium hypochlorite into simulated lateral canals: an *in vitro* study. *J Endod* 2009; 35(6):891–5. [\[CrossRef\]](#)
26. Souza LC, Brito PR, de Oliveira JC, Alves FR, Moreira EJ, Sampaio-Filho HR, et al. Photodynamic therapy with two different photosensitizers as a supplement to instrumentation/irrigation procedures in promoting intracanal reduction of *Enterococcus faecalis*. *J Endod* 2010; 36(2):292–6.
27. Plotino G, Grande NM, Mercade M. Photodynamic therapy in endodontics. *Int Endod J* 2019; 52(6):760–74. [\[CrossRef\]](#)
28. Siqueira JF, Jr., Rôças IN, Riche FN, Provenzano JC. Clinical outcome of the endodontic treatment of teeth with apical periodontitis using an antimicrobial protocol. *Oral Surg Oral Med Oral Pathol Oral Radiol Endod* 2008; 106(5):757–62. [\[CrossRef\]](#)
29. Rôças IN, Provenzano JC, Neves MS, Alves FRF, Gonçalves LS, Siqueira JF Jr. Effects of Calcium Hydroxide Paste in Different Vehicles on Bacterial Reduction during Treatment of Teeth with Apical Periodontitis. *J Endod* 2023; 49(1):55–61. [\[CrossRef\]](#)
30. Jarrett IS, Marx D, Covey D, Karmazin M, Lavin M, Gound T. Percentage of canals filled in apical cross sections - an *in vitro* study of seven obturation techniques. *Int Endod J* 2004; 37(6):392–8. [\[CrossRef\]](#)
31. Sant'Anna-Junior A, Guerreiro-Tanomaru JM, Martelo RB, et al. Filling of simulated lateral canals with gutta-percha or thermoplastic polymer by warm vertical compaction. *Braz Oral Res* 2015; 29:56. [\[CrossRef\]](#)
32. Kim HJ, Yu MK, Lee KW, Min KS. Surgical management of an accessory canal in a maxillary premolar: a case report. *Restor Dent Endod* 2019; 44(3):e30. [\[CrossRef\]](#)
33. Parirokh M, Hatami N. Conservative Treatment of an Infected Lateral Canal: A Case Report with a 4-Year Follow-up. *Iran Endod J* 2022; 17(3):156–60.
34. Ahmed HMA, Neelakantan P, Dummer PMH. A new system for classifying accessory canal morphology. *Int Endod J* 2018; 51(2):164–76. [\[CrossRef\]](#)