

## Evaluation of Root and Root Canal Morphology of Mandibular First and Second Molars in a Greek Population: A CBCT Study

 Eleni KANTILIERAKI,  Antigoni DELANTONI,  Christos ANGELOPOULOS,  Panagiotis BELTES

### ABSTRACT

**Objective:** To study the number of roots, canal configurations, and frequency of morphological variations in mandibular first and second molars in a Greek population.

**Methods:** This study examined 478 mandibular first molars and 524 mandibular second molars using a high-resolution cone-beam computed tomography (CBCT). The number of roots was recorded and the root canal configuration was categorized based on the classification by Vertucci. The presence and configuration of C-shaped root canals were recorded and they were classified according to the Fan classification. The symmetry between the right and the left side was also evaluated.

**Results:** Among the mandibular first molars, 0.2% teeth were single-rooted, 96.4% were two-rooted, and 3.3% were three-rooted. In the mandibular second molars, 12.2%, 82.8%, and 4.9% were single-rooted, two-rooted, and three-rooted, respectively. In two-rooted mandibular first and second molars, the most frequent root canal pattern observed was Vertucci's type II in the mesial root (69.8% and 64.1%, respectively) and Vertucci's type I in the distal root (81.7% and 97.7%, respectively). Three-rooted molars showed one oval-shaped mesial root and two distal roots (56.2% in first molars, 65.4% in second molars), where each distal root contained a single root canal (type I), and the mesial root presented either type II (53.3%), IV (26.6%), I (13.3%), or V (6.6%) canal configurations. C-shaped canals were only detected in mandibular second molars (5.3% of teeth, 10.8% of individuals), and bilateral occurrence was observed in 24.5% patients. The most frequent root canal pattern was Fan's C1 type at the orifice, followed by C3a and C3b in the coronal and middle third, which joined into a single canal (C4) apically.

**Conclusion:** The characteristics of the root and root canal anatomy of the mandibular first and second molars of Greek individuals were similar to those observed in Caucasians. However, the higher incidence of third roots in mandibular molars in Greek individuals compared to Caucasians requires absolute clinical awareness.

**Keywords:** Cone-beam computed tomography, greek population, mandibular molars, root morphology, root canal morphology

### HIGHLIGHTS

- Mandibular second molars present significantly more anatomic irregularities than mandibular first molars.
- The incidence of a third root was 8.6% of individuals, which is the highest incidence reported among Caucasians.
- The most common root canal configuration in the mesial root of two-rooted molars was Vertucci's type II (67%), followed by types IV (20.3%), III (1.7%), and V (1%), and types I (89.5%) and II (1.5%) in distal roots.
- C-shaped root canals were encountered in 10.8% of the individuals and were unilateral in 75.5% of the cases.
- In C-shaped molars, the most common root canal configuration was a single C-shaped orifice, furcating into three canals in the coronal and middle third and ending in a single canal apically.

### INTRODUCTION

The success of non-surgical and surgical root canal treatment is highly dependent on adequate knowledge on root and root canal anatomy (1). Awareness of possible anatomical variations in the roots and canals is important for clinicians to prevent the occasion of missed canals in teeth scheduled for root canal treatment.

Among all tooth groups, mandibular molars present the highest diversity in terms of external and internal root anatomy. A number of studies have proved the existence of a strong link between tooth morphology and racial background. Mandibular molars in Caucasian populations typically

have two roots (mesial and distal) and three root canals (2). A single root is encountered in 8.7%–14.2% of mandibular second molars and 0.3%–3% of mandibular first molars, while a third root is

Please cite this article as:  
Kantilieraki E, Delantoni A,  
Angelopoulos C, Beltes P.  
Evaluation of Root and Root Canal  
Morphology of Mandibular First  
and Second Molars in a Greek  
Population: A CBCT Study. *Eur  
Endod J* 2019; 4: 62-8

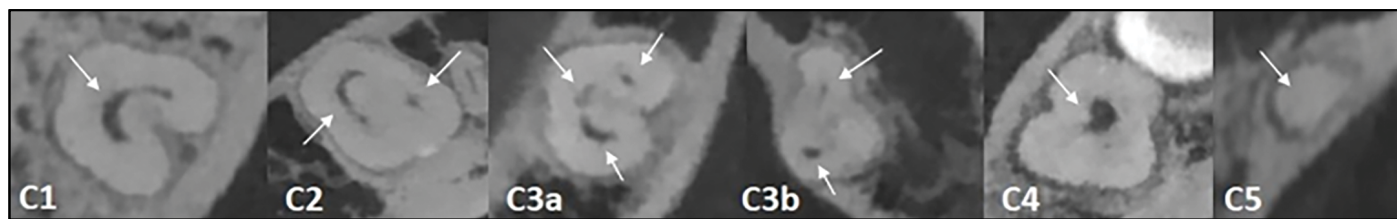
From the Department of  
Endodontology (E.K. ✉  
ekantilieraki@gmail.com, A.D.,  
C.A., P.B.) Aristotle University of  
Thessaloniki, Greece

Received 04 February 2019,  
Accepted 07 May 2019

Published online: 18 July 2019  
DOI 10.14744/ej.2019.19480

This work is licensed under  
a Creative Commons  
Attribution-NonCommercial  
4.0 International License.





**Figure 1.** Modified Melton's classification of C-shaped root canal configuration presented through axial slices in mandibular second molars

observed in 1.8%–2.7% and 0%–2.6% of mandibular second molars and mandibular first molars, respectively (3-7). The C-shaped morphology is relatively rare (4.6%–11%) (8). However, an increased prevalence of single-rooted mandibular molars (22%–41%), three-rooted mandibular molars (25.3%–51.4%), and C-shaped canal morphology (10%–44.5%) has been observed in Asian populations and has been termed as the Mongoloid trait (9-12). Therefore, it is speculated that the Caucasian dental pattern is characterized by morphological reduction and simplification of anatomic traits (13).

A review of the existing literature indicated that the root and root canal anatomy in Greeks has scarcely been studied till date. Moreover, no studies about the morphological features of mandibular molars were found. Therefore, the present study aimed to map the morphological features of the roots and root canals of permanent mandibular first and second molars using high-resolution cone-beam computed tomography (CBCT).

## MATERIALS AND METHODS

The study protocol was approved by the Institutional Research Committee of the Aristotle University of Thessaloniki, Greece. Written informed consent was obtained from all patients, and data anonymization using the open source ARX Data anonymization tool was performed to encrypt the personal identifiable information of the participants.

Between 01/01/2015 and 01/01/2017, 372 CBCT scans were acquired from the Department of Dentoalveolar Surgery, Implantology, and Oral Radiology of the Aristotle University of Thessaloniki, Greece as well as from a private radiology clinic. All the CBCTs had been performed either to guide the diagnostic process or as part of the patient's dental treatment plan.

The CBCT scanners used were the NewTom VGi Evo (NewTom, Verona, Italy) set at 110 kVp, 3.00 mA, and 4.3 s and the Scanora® 3D (Soredex Co., Tuusula, Finland) set at 90 kVp and 13 mA. The voxel dimensions for both scanners were  $0.1 \times 0.1 \times 0.1 \text{ mm}^3$ . The inclusion criteria for this study were; patient age was 18–65 years, bilateral presence of mandibular first or mandibular second molars, fully formed apices, non-endodontically-treated teeth, teeth without posts, cores, or prosthetic restorations, teeth without any signs of internal or external resorption, and absence of extensively calcified root canals.

The subjects were divided according to sex. A total of 1002 teeth were included in the analysis, of which 592 belonged to females and 410 belonged to males. The mean age of all patients was 37 years (range: 18–65 years). The sample comprised of 478 mandibular first molars and 524 mandibular second molars. The acquired volumetric data for the teeth were

analyzed in three planes (axial, coronal, and sagittal) using the proprietary software of each CBCT scanner, in order to evaluate the following morphological features: (i) number of roots, (ii) root canal configuration, and (iii) frequency of C-shaped root canals and their configuration. The root canal configurations of non-C-shaped roots were analyzed based on Vertucci's classification (2) and the additional configurations were described by Sert and Bayirli (14). In C-shaped molars, the root canal pattern was recorded at four levels along the length of the root: orifice, coronal third, middle third, and apical third. The root canal configuration was categorized according to the modified Melton's classification (Fig. 1) (15). Differences between the first and second mandibular molars in terms of the prevalence of morphological variations (additional roots and C-shaped canals), sex, and tooth position (left or right quadrant) were compared using the two-sample t-test. The statistical analyses, as well as the calculation of the results, were performed using MATLAB (Release r2016A; Mathworks Inc., Natick, MA, USA).

All CBCT scans were assessed separately by two examiners, and any disagreements were discussed until a consensus was reached. Inter-rater reliability was measured at 0.85 ( $\kappa=0.85$ ).

## RESULTS

The number of roots and the root symmetry between males and females are presented in Table 1.

Single-rooted molars were categorized based on the outline of the cross-section of the root as (i) O-shaped and (ii) C-shaped. The O-shaped molars presented a round or oval cross-section along the entire root length, while C-shaped molars displayed a C-shaped cross-section at least at one point along the root. In the latter, the convex part of the root faced buccally and lingually in 70% and 30% of the cases, respectively. Amongst the individuals with single-rooted mandibular molars, bilateral occurrence was observed in 17.4% of the O-shaped molars and 32.5% of the C-shaped molars.

A third root was encountered in 8.6% of the individuals (9.3% females, 7.6% males) and 4.2% of teeth. The representative images of radix entomolaris are shown in Figure 2. Bilateral occurrence was observed in 18.8% of the cases (20% females, 16.6% males). The number of mandibular first and second molars presenting radix entomolaris or radix paramolaris, as well as the root course of the third root classified as according to Carlsen and Alexandersen, is presented in Table 2 (16, 17).

No correlation was found between the number of roots and the sex of the patient ( $P=0.52$ ). However, the prevalence of additional roots was statistically higher in mandibular second molars than mandibular first molars ( $P<0.01$ ).

**TABLE 1.** Percentage distribution of the number of roots and root canals according to sex, and symmetry between females and males

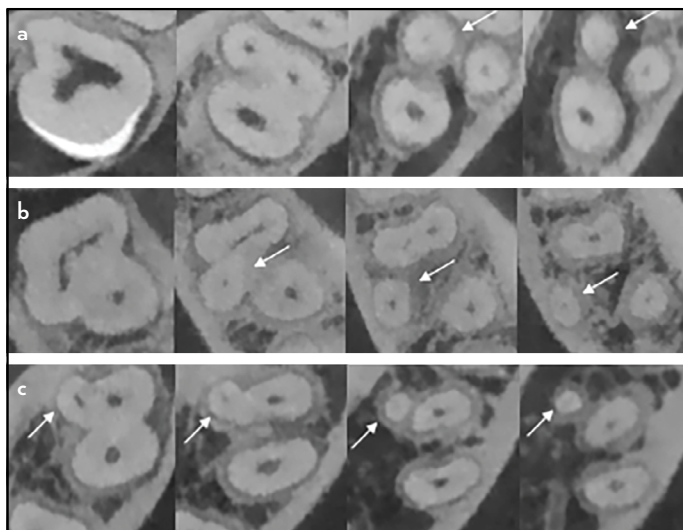
Molar type	No. of roots		Female (n/%)	Male (n/%)	Symmetry (n/%)
Mandibular first molars	Single rooted (n=1)	O-shaped	1 (100.0)	-	-
	Two rooted (n=461)	M	271 (58.8)	190 (41.2)	161 (97.0)
	Three rooted (n=16)	D	4 (25.0)	2 (12.5)	2 (16.6)
		MB, ML, D	5 (31.2)	5 (31.2)	2 (16.6)
Mandibular second molars	Single rooted (n=64)	O-shaped (n=11) (non C-shaped root canals)	7 (63.7)	3 (27.3)	2 (22.2)
		O-shaped (n=12) (C-shaped root canals)	6 (50.0)	5 (41.6)	2 (16.6)
		C-shaped (n=41)	30 (73.2)	12 (29.7)	10 (24.5)
	Two rooted (n=434)	M	256 (59.0)	178 (41.0)	125 (85.6)
	Three rooted (n=26)	D	3 (11.5)	3 (11.5)	
		MB, ML, D	14 (53.8)	6 (23.1)	2 (10.0)

D: Distal, DB: Distobuccal, DL: Distolingual, M: Mesial, MB: Mesiobuccal, ML: Mesiolingual

**TABLE 2.** Percentage distribution of root type (n) in mandibular molars that presented radix entomolaris

	Radix Entomolaris			Accessory mesial and buccal roots			Total
	A	B	C	AC	SMB	RP	
Mandibular first molars	4 (25.0)	-	3 (18.7)	5 (31.2)	4 (25.0)	-	16 (100.0)
Mandibular second molars	7 (26.9)	-	3 (11.5)	5 (19.2)	7 (26.9)	4 (15.4)	26 (100.0)

A: Separate distolingual root of lesser dimensions than main distal root, B: Two distal roots of equal dimensions, C: Separate mesiolingual root, AC: Separate root located centrally in the lingual aspect, and SMB: Separate mesiobuccal root, RP: Radix paramolaris, B: Separate root located centrally in the buccal aspect



**Figure 2.** Mandibular first and second molars displaying a third root: (a) Separate mesiobuccal root, (b) radix entomolaris type AC (separate root located centrally in the lingual aspect), (c) Separate mesiobuccal root

**Root canal configuration**

The root canal configurations according to the types described by Vertucci (2) and Sert & Bayirli (14) in single-rooted, two-rooted, and three-rooted mandibular first and second molars are shown in Table 3. In two-rooted molars, the mesial roots mainly displayed Vertucci’s type II anatomy (69.9% first molars, 64.1% second molars), followed by type IV (26.2% first molars, 14.1% second molars). A single root canal in the mesial root, wider buccolingually than mesiodistally, was observed

more frequently in mandibular second molars (17.7%) as compared to first molars (2.2%). An additional orifice between the mesiobuccal and mesiolingual orifices, indicating the presence of a third root canal (middle mesial), was detected in one mandibular first molar sample. It ran an independent course up to the apical third of the root, where it merged with the mesiolingual root canal (Fig. 3). All single-rooted molars with a C-shaped outline of the root, as well as 12 O-shaped molars, presented with C-shaped configurations of their root canal system.

**C-shaped root canals**

A total of 53 mandibular second molars presented C-shaped configurations of the root canal system (Table 4), which are shown in Figure 4. This variation was not observed in any mandibular first molars. The prevalence of C-shaped canals according to sex and root canal configuration based on the modified Melton’s classification is presented in Table 4. A C-shaped outline of the root co-existed with C-shaped canals in all cases, and bilateral occurrence was recorded in 24.5% of the cases (27.7% females, 17.6% males). The combined population analyses revealed no statistically significant difference between tooth position and occurrence of C-shaped morphology (P=0.18). However, when performed solely on samples obtained from females, the analyses showed a tendency toward more complex morphologies in the mandibular left quadrant as compared to the right (P<0.05). Overall, the C-shaped morphology was observed in 10.8% of the individuals (12.1% females, 8.9% males) and in 5.3% of teeth.

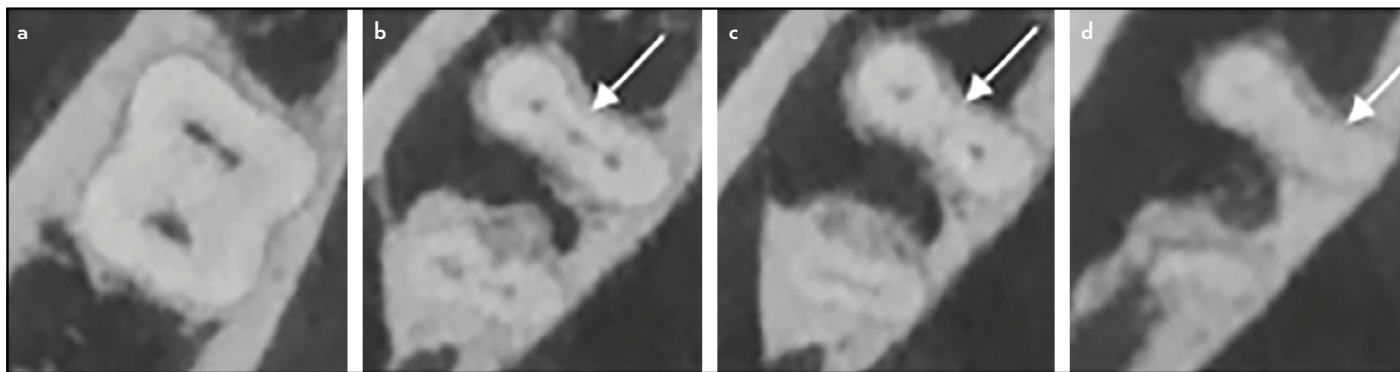
**TABLE 3.** Root canal configuration according to the types described by Vertucci and Sert & Bayirli in non-C-shaped mandibular first (n=478) and second molars (n=471)

Mandibular first molars	No. of roots	Root	Root canal configuration (n/%)							
			Type I	Type II	Type III	Type IV	Type V	Type XV	Type XVIII	Type XIX
	Single rooted (n=1)		-	1 (100.0)	-	-	-	-	-	-
	Two rooted (n=461)	M	7 (1.5)	322 (69.8)	3 (0.6)	121 (26.2)	3 (0.6)	1 (0.2)	-	1 (0.2)
		D	377 (81.7)	58 (12.6)	12 (2.6)	7 (1.5)	3 (0.6)	-	-	-
	Three rooted (n=6)	MB	6 (100.0)	-	-	-	-	-	-	-
		ML	6 (100.0)	-	-	-	-	-	-	-
		D	6 (100.0)	-	-	-	-	-	-	-
	Three rooted (n=10)	M	1 (10.0)	5 (50.0)	-	3 (30.0)	1 (10.0)	-	-	-
		DB	10 (100.0)	-	-	-	-	-	-	-
		DL	10 (100.0)	-	-	-	-	-	-	-
Mandibular second molars	Single rooted (n=11)		3 (27.3)	7 (63.6)	-	-	-	-	1 (9.1)	-
	Two rooted (n=434)	M	77 (17.7)	278 (64.1)	12 (2.8)	61 (14.1)	6 (1.4)	-	-	-
		D	424 (97.7)	6 (1.4)	-	2 (0.5)	2 (0.5)	-	-	-
	Three rooted (n=6)	MB	6 (100.0)	-	-	-	-	-	-	-
		ML	6 (100.0)	-	-	-	-	-	-	-
		D	6 (100.0)	-	-	-	-	-	-	-
	Three rooted (n=20)	M	3 (15.0)	11 (55.0)	-	5 (25.0)	1 (5.0)	-	-	-
		DB	20 (100.0)	-	-	-	-	-	-	-
		DL	20 (100.0)	-	-	-	-	-	-	-

D: Distal, DB: Distobuccal, DL: Distolingual, M: Mesial, MB: Mesibuccal, ML: Mesiolingual

**TABLE 4.** Prevalence of C-shaped root canals in mandibular second molars based on sex, bilateral occurrence, and root canal configuration according to the modified Melton's classification at four cross-sectional levels

C-shaped molars	Female		Male		Symmetry		Total
	Root canal configuration (n/%)						
No. of teeth (n/%)	36 (67.9)		17 (32.1)		13 (24.5)		53 (5.3)
Levels of the Root	C1	C2	C3a	C3b	C4	C5	Total
Orifice	41 (77.4)	-	4 (7.5)	8 (15.1)	-	-	53 (100.0)
Coronal root third	15 (28.3)	6 (11.3)	26 (49.1)	6 (11.3)	-	-	53 (100.0)
Middle root third	5 (10.4)	7 (13.2)	25 (47.1)	15 (29.2)	1 (2.1)	-	53 (100.0)
Apical root third	3 (6.3)	-	4 (8.3)	26 (49.1)	19 (35.8)	1 (2.1)	53 (100.0)

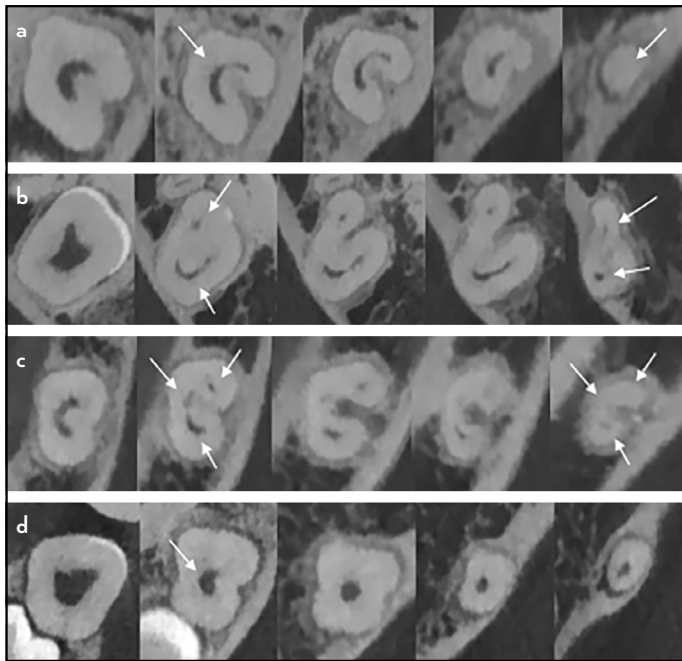


**Figure 3.** (a-d) Mandibular first molar with three root canals in the mesial root showing a separate middle mesial canal in the coronal third (b), joining with an isthmus into the mesiolingual (c). The course of the canal(s) cannot be identified in the apical third (d)

## DISCUSSION

The purpose of the present study was to provide detailed information on the root and root canal morphology of mandibular first and second molars in a Greek population using CBCT.

Morphological traits in teeth represent an index of affinity between populations and are of great importance from the perspectives of anthropology and endodontics. The Greek population by means of race is considered Mediterranean, a



**Figure 4.** Cases of mandibular second molars with C-shaped root canal configuration: (a) type C1 resulting in C5 apically, (b) type C2 leading to type C3b apically, (c) C-shaped orifice and type C3a configuration of the root canals, (d) type C4

sub-race of Caucasian, referring mainly to those inhabiting Southern Europe. The Mediterranean race profile is also prevalent in parts of Western Asia, Western Central Asia, and South Asia, which are regions that have been intersecting with the population of Greece for centuries.

CBCT is an efficient tool in the study of tooth morphology, as it provides valuable *in vivo* anatomic information regarding teeth in the coronal, sagittal, and axial views. Its additional advantages include low patient radiation, reduced image distortion, and superimposition of anatomical structures (18). Although micro-CT offers additional information regarding morphological structures of the minor dimensions, such as isthmi, apical delta, and lateral canals, it is not suitable for clinical application due to extensive radiation doses (18). Analyzing CBCT scans from radiology archives offers an extended pool of available information and contributes to a large sample size, which is a crucial part of population studies. In the present study, images from 1002 teeth were investigated, comprising the largest study conducted so far on the Greek population.

The acquired CBCT data was derived from two scanners (NewTom VGi Evo; Scanora 3D). Although pooling data with different characteristics can lead to ambiguous results, the CBCT scanners selected in the present study displayed overall similar settings. Moreover, the voxel size (0.100 mm<sup>3</sup>) was identical, meaning that each observed slice presented the exact same dimensions with both scanners.

Previous studies utilizing CBCT have often relied on imaging protocols of larger slice thickness (19). In the present study, a high-resolution protocol was employed, thus providing better image quality and enhanced visualization of all investigated parameters.

Results showed that the majority of mandibular first and second molars in Greeks had two roots. A single root was a trait more commonly found in mandibular second molars compared to mandibular first molars (12.2% and 0.2% respectively). The reported prevalence in mandibular second molars ranges between 22%–41% in Asians (9, 10) and 8.7%–14.2% in Caucasians (3-5). Regarding the mandibular first molar, the percentages of single root occurrence are 0.7% and 0.3%–3% respectively (3-5, 20). An additional effort was made to differentiate between an O-shaped and a C-shaped root outline. Out of 65 single-rooted molars, 36.9% had an O-shaped root and 63.1% had a C-shaped root. Kim et al. (9) reported a 0.10% incidence of O-shaped roots in mandibular second molars, but none in mandibular first molars. However, the present study showed a prevalence of 0.2% and 4.3% in mandibular first and second molars, respectively.

The presence of a third root is considered a Mongoloid trait, and its prevalence is highly dependent on race. Studies have shown that Eskimos, Chinese, North Americans, Indians, and Koreans display higher percentages (25.3%–51.4%) than their Caucasian counterparts, who present an incidence of 0%–2.6% in mandibular first molars and 1.8%–2.7% in mandibular second molars (4-7, 21). In the present study, a third root was observed in 8.6% of the patients and 4.2% of the teeth, with the distribution being slightly higher in second molars (4.9%) than in the first molars (3.3%). Although a low frequency was expected considering it is an Asiatic trait, the percentage was higher than other Caucasian population studies. The third root was most frequently encountered in second molars, which was concurrent with the studies by Plotino et al. (5) and Martins et al. (4), but differed from the observations by Zhang et al. (10), Karale et al. (22), Nur et al. (23), and Shemesh et al. (7), all of whom reported a higher incidence of a third root in mandibular first molars. This could be attributed to genetic differences in racial background, considering that the former studied white individuals, mainly of Italian and Portuguese origin, while the latter studied individuals of Asian, Indian, Eastern-Turkish, and Israeli origin. The symmetry between the right and left side of the patient was detected in 18.8% of the cases, which was significantly lesser than that in individuals of Taiwanese, Japanese, and Chinese origin (53.6%–68.6% cases) (12).

Regarding the internal morphology of the mesial root, the most frequent configuration was type II in both first (69.9%) and second molars (64.1%), followed by type IV (26.2% and 14.1%, respectively). A single-rooted canal was more common in mandibular second molars (17.7%) than in first molars (2.2%). Globally, the most prominent configuration in Caucasians was type IV in approximately 57% of the cases, followed by type II in 31.5% cases (24). In mandibular second molars, type II was the most prevalent anatomy in approximately 32.3% cases, followed by type IV (28%) and type I (6.5%) (25). Remarkably, two studies reported type V as the most prevalent in both mandibular first and second molars, followed by type III and I in individuals of Belgian, Chilean, and North American origin (3, 26).

A third root canal in the mesial root of mandibular molars can be observed between the orifices of the mesiobuccal and

mesiolingual root canal. In Caucasians, the reported prevalence ranges between 2.1%–36% (26). The clinical study by Azim et al. (27) is of particular interest, as it reported a third root canal in up to 46.2% of the cases by employing high-magnification and the troughing technique. In the present study, this morphology was observed only in one mandibular first molar (0.2%), with the additional canal merging with the mesiolingual canal in the apical third of the root. The low frequency could partly be attributed to the lack of efficiency of CBCT in detecting structures of minor dimensions, as well as the third root canal not being a true canal in all cases, rather just a slim communication between the main root canals (28). Therefore, clinical exploration of the region between the two main mesial orifices is of utmost importance, because failing to do so can result in inadequate debridement, incomplete obturation, and a jeopardized treatment outcome.

With respect to the internal anatomy of the distal roots in Caucasians, the most prevalent root canal configuration was type I, followed by type V. A second root canal with an independent course was present in 1.3%–4% of the cases, while two root canals that merged apically were present in 2.5%–9.3% (3, 25, 26). In individuals of Asian origin, the distal root mainly showed a type I configuration as well, although a separate distolingual root was also present in up to one-third of the cases (10). In the present study, an oval-shaped type I canal was observed in the majority of first and second molars (81.7% and 97.7% respectively). The most frequent configurations were type II (12.6% in mandibular first and 1.4% in mandibular second molars), followed by types III (2.6%), IV (1.5%), and V (0.6%) in mandibular first molars, and type IV (0.5%) and V (0.5%) in mandibular second molars.

The single-rooted non-C-shaped molars showed a variety of anatomic types. The most frequent anatomy observed was two root canals that joined apically (type II), followed by a single root canal (type I). A case of three distinct canals joining in the middle third of the root to form a single oval root canal was also observed (type XVIII). These findings corroborate with the study by Silva et al. (19) that involved a Brazilian population, but differed from the observations of Kim et al. (9) who studied a Korean population and Plotino et al. (5) who studied a white population, both of which reported type I as the most frequent anatomy.

In three-rooted molars, the number of root canals varied between three and four. When two distinct mesial roots were observed, each one had a single root canal. In the case of one mesial and two distal roots, the most prevalent configurations for the mesial root were types II and IV followed by types I and V, in both mandibular first and second molars. The distal roots had a single canal in all cases. These findings differ from the study by Kim et al. (9), who observed a type I root canal in each root in a Korean population; but were in agreement with studies by Zhang et al. (10) and Plotino et al. (5) in terms of having reported more complex morphology of the mesial roots.

The C-shaped morphology was observed in 10.8% of mandibular second molars. The trait was not present in any mandibular first molars, corroborating the rarity of this variation. C-shaped root canals are predominantly considered an Asiatic trait, with

frequencies ranging up to 45.5% in mandibular second molars. In Caucasians, the reported prevalence is merely 4.6%–11% (8). Bilateral occurrence is documented in 70%–81% of the cases (8), with no proven correlation between age, sex, and laterality (29, 30). The results of the present study indicate that 75.5% of the cases were unilateral, meaning that the patient had only one mandibular molar with C-shaped morphology.

A C-shaped outline of the root positively correlated with C-shaped anatomy of the root canals. Additionally, the majority of the O-shaped roots presented C-shaped configurations. Therefore, it is advisable to treat any single-rooted mandibular molar encountered clinically with caution, as the chances of hosting a rather complicated root canal system are high.

Regarding the anatomic configurations, a single C-shaped orifice constitutes the most prevalent type at the orifice level, thus facilitating identification by the clinician. Three distinct canals were the most prominent pattern in the coronal and middle thirds of the root, and one or two canals were present apically.

## CONCLUSION

The majority of mandibular first and second molars in Greeks presented two roots (mesial and distal) and three root canals. The most frequent root canal pattern was Vertucci's type II in the mesial root, and Vertucci's type I in the distal root. The higher incidence of third roots in mandibular molars in Greek individuals compared to Caucasians and the presence of several variants of C-shaped canals require absolute clinical awareness.

## Disclosures

**Conflict of interest:** The authors deny any conflicts of interest related to this study.

**Ethics Committee Approval:** The study protocol was approved by the Institutional Research Committee of the Aristotle University of Thessaloniki, Greece (Protocol No.33/03-05-2018).

**Peer-review:** Externally peer-reviewed.

**Financial Disclosure:** No financial support was provided for the execution of the study.

**Authorship contributions:** Concept – E.K., P.B.; Design – E.K., A.D., C.A.; Supervision – P.B., C.A., A.D.; Funding - None; Materials - None; Data collection &/or processing – E.K., P.B., C.A., A.D.; Analysis and/or interpretation – E.K., A.D., C.A., P.B.; Literature search – E.K., P.B.; Writing – E.K., P.B.; Critical Review – C.A., P.B.

## REFERENCES

1. Vertucci FJ. Root canal morphology and its relationship to endodontic procedures. *Endod Topics* 2005; 10(1):3–29. [[CrossRef](#)]
2. Vertucci FJ. Root canal anatomy of the human permanent teeth. *Oral Surg Oral Med Oral Pathol* 1984; 58(5):589–99. [[CrossRef](#)]
3. Torres A, Jacobs R, Lambrechts P, Brizuela C, Cabrera C, Concha G, et al. Characterization of mandibular molar root and canal morphology using cone beam computed tomography and its variability in Belgian and Chilean population samples. *Imaging Sci Dent* 2015; 45(2):95–101. [[CrossRef](#)]
4. Martins JNR, Marques D, Mata A, Caramês J. Root and root canal morphology of the permanent dentition in a Caucasian population: a cone-beam computed tomography study. *Int Endod J* 2017(11);50:1013–26.
5. Plotino G, Tocci L, Grande NM, Testarelli L, Messineo D, Ciotti M, et al. Symmetry of root and root canal morphology of maxillary and mandibular molars in a white population: a cone-beam computed tomography study in vivo. *J Endod* 2013;39 (12):1545–8. [[CrossRef](#)]

6. Schäfer E, Breuer D, Janzen S. The prevalence of three-rooted mandibular permanent first molars in a German population. *J Endod* 2009; 35(2):202–5. [\[CrossRef\]](#)
7. Shemesh A, Levin A, Katzenell V, Ben Itzhak J, Levinson O, Zini A, et al. Prevalence of 3- and 4-rooted first and second mandibular molars in the Israeli population. *J Endod* 2015;41:338–42. [\[CrossRef\]](#)
8. von Zuben M, Martins JNR, Berti L, Cassim I, Flynn D, Gonzalez JA, et al. Worldwide Prevalence of Mandibular Second Molar C-Shaped Morphologies Evaluated by Cone-Beam Computed Tomography. *J Endod* 2017;43:1442–7. [\[CrossRef\]](#)
9. Kim SY, Kim BS, Kim Y. Mandibular second molar root canal morphology and variants in a Korean subpopulation. *Int Endod J* 2016;49 (2):136–44.
10. Zhang R, Wang H, Tian YY, Yu X, Hu T, Dummer PM. Use of cone-beam computed tomography to evaluate root and canal morphology of mandibular molars in Chinese individuals. *Int Endod J* 2011; 44(11):990–9. [\[CrossRef\]](#)
11. Morita M. Morphological studies on the roots of lower first molars in Japanese. [Article in Japanese]. *Shikwa Gakuho* 1990; 90(6):837–54.
12. Tu MG, Huang HL, Hsue SS, Hsu JT, Chen SY, Jou MJ, et al. Detection of permanent three-rooted mandibular first molars by cone-beam computed tomography imaging in Taiwanese individuals. *J Endod* 2009; 35(4):503–7. [\[CrossRef\]](#)
13. Scott GR, Turner CG. *The Anthropology of Modern Human Teeth*. Cambridge: Cambridge University Press; 1997. [\[CrossRef\]](#)
14. Sert S, Bayirli GS. Evaluation of the root canal configurations of the mandibular and maxillary permanent teeth by gender in the Turkish population. *J Endod* 2004; 30(6):391–8. [\[CrossRef\]](#)
15. Fan B, Cheung GS, Fan M, Gutmann JL, Bian Z. C-shaped canal system in mandibular second molars: Part I—Anatomical features. *J Endod* 2004; 30(12):899–903. [\[CrossRef\]](#)
16. Carlsen O, Alexandersen V. Radix entomolaris: identification and morphology. *Scand J Dent Res* 1990; 98(5):363–73. [\[CrossRef\]](#)
17. Carlsen O, Alexandersen V. Radix paramolaris in permanent mandibular molars: identification and morphology. *Scand J Dent Res* 1991; 99(3):189–95. [\[CrossRef\]](#)
18. Ordinola-Zapata R, Bramante CM, Versiani MA, Moldauer BI, Topham G, Gutmann JL, et al. Comparative accuracy of the Clearing Technique, CBCT and Micro-CT methods in studying the mesial root canal configuration of mandibular first molars. *Int Endod J* 2017; 50(1):90–6. [\[CrossRef\]](#)
19. Silva EJ, Nejaim Y, Silva AV, Haiter-Neto F, Cohenca N. Evaluation of root canal configuration of mandibular molars in a Brazilian population by using cone-beam computed tomography: an in vivo study. *J Endod* 2013; 39(7):849–52. [\[CrossRef\]](#)
20. Wang Y, Zheng QH, Zhou XD, Tang L, Wang Q, Zheng GN, et al. Evaluation of the root and canal morphology of mandibular first permanent molars in a western Chinese population by cone-beam computed tomography. *J Endod* 2010; 36(11):1786–9. [\[CrossRef\]](#)
21. Ferraz JA, Pécora JD. Three-rooted mandibular molars in patients of Mongolian, Caucasian and Negro origin. *Braz Dent J* 1993; 3(2):113–7.
22. Karale R, Chikkamalliah C, Hegde J, Aswathanarayana S, Santhosh L, Bashetty K, et al. The prevalence of bilateral three-rooted mandibular first molar in Indian population. *Iran Endod J* 2013; 8(3):99–102.
23. Nur BG, Ok E, Altunsoy M, Aglarci OS, Colak M, Gungor E. Evaluation of the root and canal morphology of mandibular permanent molars in a south-eastern Turkish population using cone-beam computed tomography. *Eur J Dent* 2014; 8(2):154–9. [\[CrossRef\]](#)
24. Madani ZS, Mehraban N, Moudi E, Bijani A. Root and Canal Morphology of Mandibular Molars in a Selected Iranian Population Using Cone-Beam Computed Tomography. *Iran Endod J* 2017; 12(2):143–8.
25. Wolf TG, Paqué F, Betz P, Willershausen B, Briseño-Marroquín B. Micro-CT assessment of internal morphology and root canal configuration of non C-shaped mandibular second molars. *Swiss Dent J* 2017; 127(6):513–9.
26. Harris SP, Bowles WR, Fok A, McClanahan SB. An anatomic investigation of the mandibular first molar using micro-computed tomography. *J Endod* 2013; 39(11):1374–8. [\[CrossRef\]](#)
27. Azim AA, Deutsch AS, Solomon CS. Prevalence of middle mesial canals in mandibular molars after guided troughing under high magnification: an in vivo investigation. *J Endod* 2015; 41(2):164–8. [\[CrossRef\]](#)
28. Maung Maung Kyaw Moe, Ha JH, Jin MU, Kim YK, Kim SK. Anatomical profile of the mesial root of the Burmese mandibular first molar with Vertucci's type IV canal configuration. *J Oral Sci* 2017; 59(4):469–74. [\[CrossRef\]](#)
29. Sabala CL, Benenati FW, Neas BR. Bilateral root or root canal aberrations in a dental school patient population. *J Endod* 1994; 20(1):38–42. [\[CrossRef\]](#)
30. Zheng Q, Zhang L, Zhou X, Wang Q, Wang Y, Tang L, et al. C-shaped root canal system in mandibular second molars in a Chinese population evaluated by cone-beam computed tomography. *Int Endod J* 2011; 44(9):857–62. [\[CrossRef\]](#)