

Periapical Healing of Endodontically Treated Teeth Filled Only in the Apical Third: A Randomized Controlled Trial

Roberto Gustavo SÁNCHEZ-LARA Y TAJONAR, Karla Pamela SÁNCHEZ-MENDIETA, Rita Elizabeth MARTÍNEZ-MARTÍNEZ, Rubén Abraham DOMÍNGUEZ-PÉREZ

ABSTRACT

Objective: To provide evidence from a clinical viewpoint that the bacteria persisting within the root canal system do not have a significant impact on the treatment outcome as long as an adequate apical sealing is performed.

Methods: A total of 42 patients with pulp necrosis and a periapical index (PAI) score of 5. Root canal treatment was performed in which the root canal filling was limited to the apical third of the root. In the control group, the root canal filling was performed up to the canal orifice. Data were analyzed using the Mann-Whitney test and the χ^2 or the Fisher exact test (when appropriate).

Results: All cases presented clinical success, absence of pain, swelling, sinus tract, tenderness to palpation or percussion and presented normal tooth mobility. Fifteen months were enough for all cases of both groups to be classified with a PAI score of ≤ 2 . There was no statistical difference between the cases that ended the study with a PAI-1 or PAI-2 score.

Conclusion: Within the limitations of this study, no significant differences in healing rates after complete obturation or only apical third obturation were observed. An adequate apical sealing can improve periapical healing, thus intracanal remnant bacteria apparently have no significant impact, at least for the first 15 months of follow-up.

Keywords: Endodontics, periapical healing, root canal obturation

Sánchez-Lara y Tajonar RG, Sánchez-Mendieta KP, Martínez-Martínez RE, Domínguez-Pérez RA. Periapical Healing of Endodontically Treated Teeth Filled Only in the Apical Third: A Randomized Controlled Trial. *Eur Endod J* 2018; 3: 24-30

From the Program of Endodontic Specialization (R.G.S.L.T., K.P.S.M., R.A.D.P. ✉ dominguez.ra@uaq.com), Universidad Autónoma de Querétaro Facultad de Medicina, Mexico; Program of Advanced Education in General Dentistry (R.E.M.M.), San Luis Potosí University, Mexico; Program of Research Laboratory of the Undergraduate and Postgraduate Dentistry (R.A.D.P.), Universidad Autónoma de Querétaro Facultad de Medicina, Mexico.

Received 24 May 2017, revision requested 19 June 2017, last revision received 11 August 2017, accepted 21 September 2017.

Published online: 22 December 2017
DOI 10.5152/eej.2017.17037

HIGHLIGHTS

- This is the first clinical trial where only apical obturation was done.
- Remnant bacteria apparently have no significant impact on periapical healing.
- An adequate apical sealing can improve peri-apical healing.

INTRODUCTION

Apical periodontitis is a common bacterial disease; its prevalence varies from 27% to 70% worldwide and increases with age (1). It is an inflammatory reaction of the periapical tissues and an immunological response of the host defence system to microbes that have infected the root canal (2, 3).

Some researchers attest that shaping and cleaning are strategically more significant than obturation for eliminating root canal infections and promote apical healing (4, 5). Nevertheless, it has been demonstrated that even meticulous canal treatment, shaping and cleaning rarely lead to a total microbial eradication (6, 7). It is well-known that organisms colonizing the root canal space survive in well-protected biofilms (8, 9). This biofilm is extremely difficult to eliminate, and now, apical periodontitis is considered a biofilm-induced disease (10, 11).

The obturation of the canal space to the working length has been a critical component of root canal treatment for sealing and isolating the periapical tissues from the biofilm and irritants that remain after shaping and cleaning and for eliminating the possibility of subsequent leakage. Some have shown that the quality of the root filling has an important contribution to the success of

primary and secondary root canal treatment (12-16), but more prospective evidence is lacking to show the impact of the apical sealing as the most important key to improve the periapical healing. This study attempts to provide evidence from a clinical view-point that the bacteria persisting within the root canal system do not have a significant impact on the treatment outcome as long as an adequate apical sealing is performed.

METHODS

Study Design

A randomized, two-arms parallel-group, controlled trial.

Population and clinical evaluation

From the 42 patients, one mandibular tooth from each patient was consecutively enrolled in the present longitudinal prospective study. The patients were randomly assigned to two groups: 21 patients to the experimental group (only apical third obturation) and 21 to the control group (Figure 1). They were recruited at the University Dental Clinic of the endodontic specialization program at the Autónoma de Querétaro University School of Medicine.

An informed and voluntary written consent was obtained from patients according to the ethical principles of Helsinki declaration. Prior to oral and systemic health questionnaire and a clinical examination and before explaining the clinical procedures, risks involved and all questions raised by the patients were clarified. It was explained very clearly to each patient that each one would be continuously monitored and that in case of presenting spontaneous pain or swelling, he or she would be excluded immediately from the study and proceed to do whatever was necessary to solve their discomfort.

The study protocol was reviewed and approved by the Investigation Committee of the Dentistry area of the Autónoma de Querétaro University School of Medicine. The diagnosis was performed by an experienced endodontist; clinical examination was performed to evaluate the presence of pain, the presence of swelling, tenderness to percussion and palpations and abnormal tooth mobility. Patients must have a restorable tooth, pulp necrosis and a periapical index (PAI) score (17) of 5 with a no more than 4 mm periapical radiolucency determined in the preoperative radiograph on a light box by measuring the largest diameter with a ruler (Figure 2). Only single rooted (one canal) teeth and distal roots of molars were included. Exclusion criteria included sinus tract presence, medically compromised patients or patients with allergies to antibiotics.

Clinical procedures

All patients were treated in one visit; clinical procedures were performed by the same experienced endodontist according to a standardized regimen, including local anaesthesia and isolation of the tooth by rubber dam. Disinfection of the tooth and the rubber dam was done using 2.5% sodium hypochlorite (Na-OCl). Caries and weak tissues were removed, and the endodontic access was prepared with a sterile high-speed N°4 carbide bur. N°3 Gates Glidden drill was used for coronal flar-

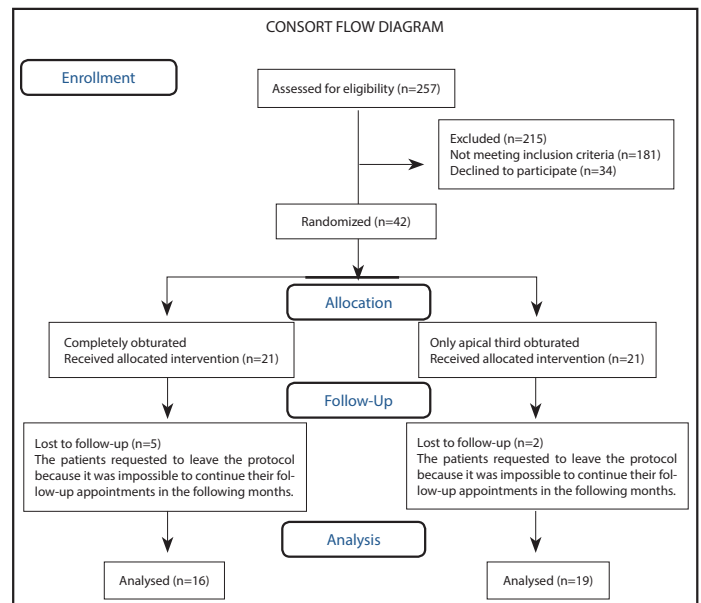


Figure 1. Consort flow diagram

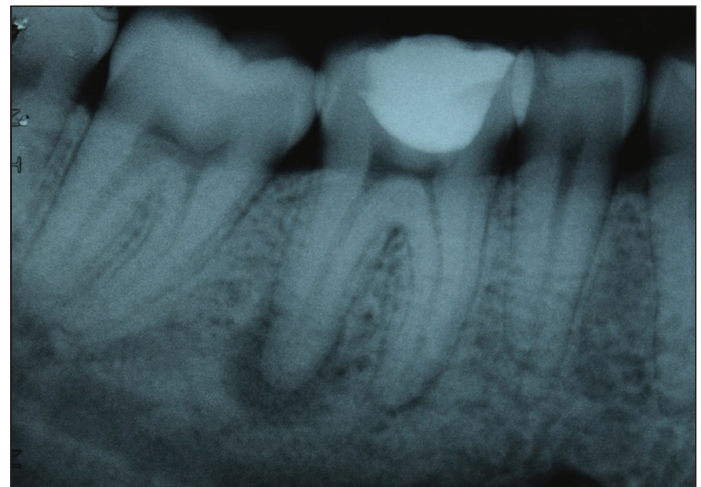


Figure 2. Preoperative periapical radiograph in which only the distal canal of the first right mandibular molar was included in the experimental group. Note the fourth right periapical radiolucency. APAI-5 score was assigned

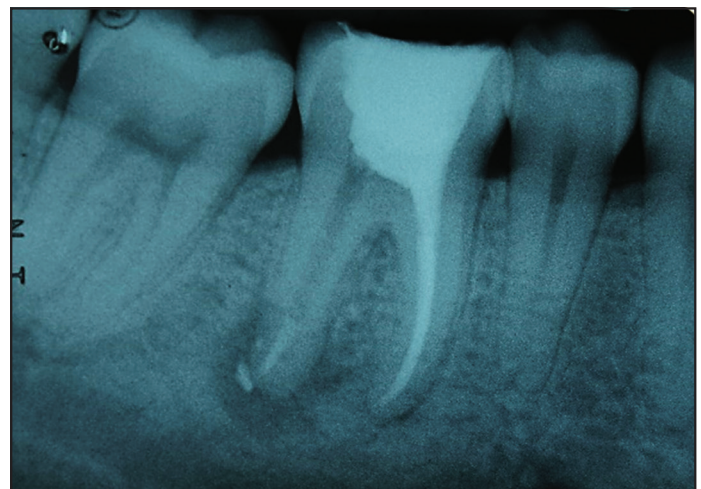

Figure 3. Immediate postoperative periapical radiograph. Note the desobturation at 4 mm less to the full length

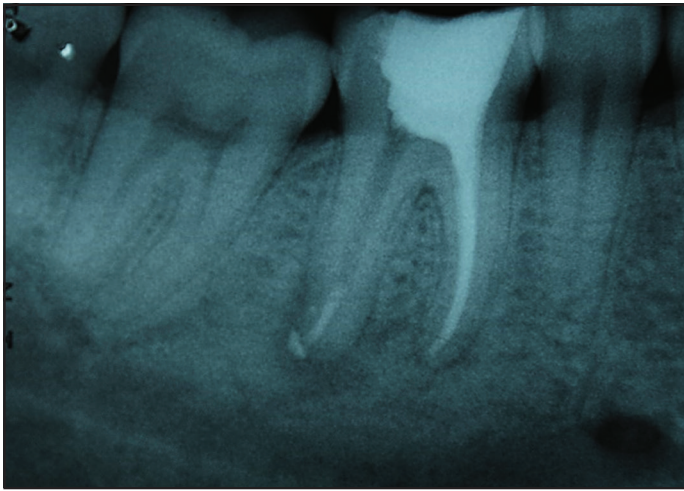


Figure 4. After 3 months of follow-up radiograph, the case was classified with a PAI-3 score

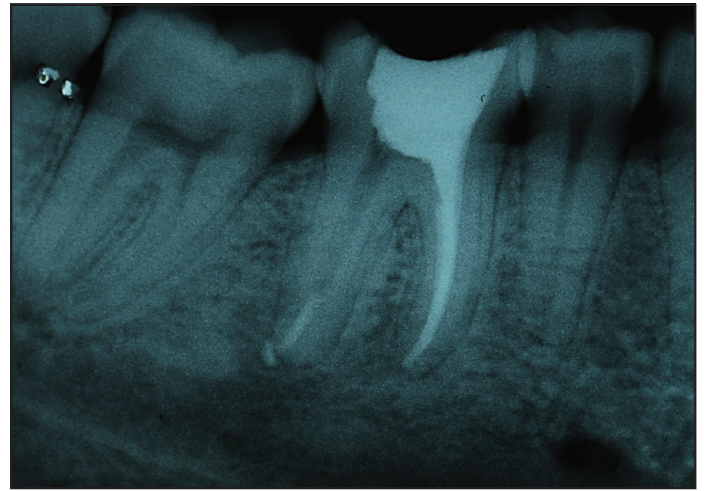


Figure 6. After 9 months of follow-up radiograph, it was classified with a PAI-2 score, so the trial finished to the patient

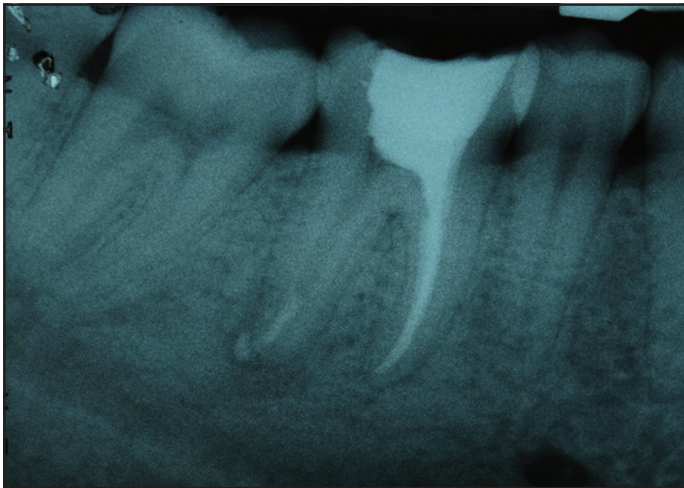


Figure 5. After 6 months of follow-up radiograph, the case was classified with a PAI-3 score

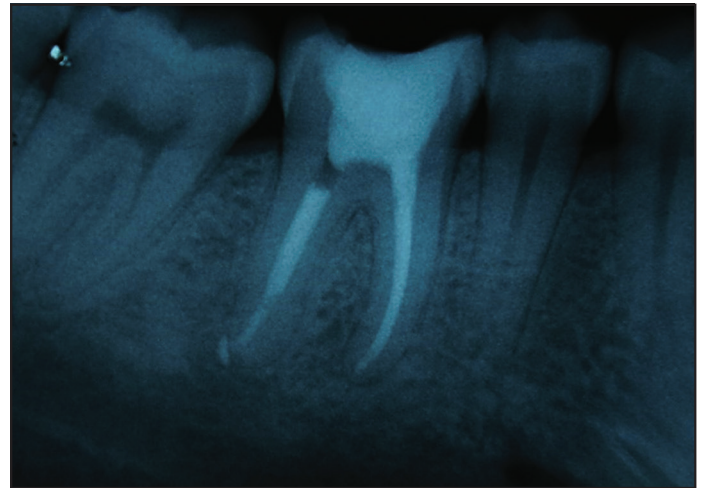


Figure 7. Final radiograph at 9 months after complete obturation was done. The patient was scheduled to definitely restoration

ing with copious irrigation of 2.5% NaOCl. The working lengths of the root canals were determined with size 15 stainless steel hand files and a Root ZXII electronic apex locator (J. Morita and Co, Tustin, CA, USA).

All root canals were instrumented using a standardized crown-down technique with ProTaper rotary system (Dentsply Maillefer, Ballaigues, Switzerland), initially S1, S2 and SX files were used in the coronal two-thirds, following the use of each shaping file, copious irrigation with 2.5% NaOCl was done and an apical patency with a size 10 file every time. S1 and S2 files were used in this manner until the depth of the size 15 hand file. Working length was reconfirmed.

The instrumentation was finished using one or more of the ProTaper (Dentsply Maillefer, Ballaigues, Switzerland), finishing files, F1, F2, F3 or F4. The canal was irrigated with saline solution and the patency was confirmed again. The root canals were dried with sterile paper points and irrigated with 17% ethylene diamine tetra-acetic acid during 5 minutes. A final irrigation was done with NaOCl and a confirmation of the

working length again. All canals were obturated using gut-tapercha and zinc oxide eugenol sealer by lateral compaction technique after the sealer was spun into the canals with the aid of a lentulo spiral and taking care of compacting as best as possible the apical third. In the experimental cases, another experienced endodontist removed the root canal filling with the F5 file at 4 mm less to the full length confirmed by a radiograph (Figure 3). This second intervention by another endodontist was performed at the same appointment with the objective of keeping the first endodontist blind to the objectives of the study. The excess cavities of all cases were filled with an in-intermediate restorative material (Dentsply/Caulk, Milford, DE, USA). All patients were advised to take 400 mg of ibuprofen every 8 hours for 3 days and to attend the university clinic at any time in case of pain, swelling or any discomfort. Everyone agreed to attend the follow-ups, first at one month and then every 3 months during 2 years.

At each appointment, clinical examination was performed to evaluate the presence of pain, the presence of swelling, tenderness to percussion and palpation and abnormal tooth mo-

bility. Also, after the first follow-up, a periapical radiograph was taken every time with a radiographic holder Rinn XCP (Dentsply, Elgin, IL, USA), in order to maximize the reproducibility of the radiographic paralleling technique (Figures 4-6).

Radiographic analysis

Pre- and postoperative radiographs were compared during each follow-up appointment. Each radiograph was digitized into joint photographic experts group format using a digital camera (Nikon, Tokyo, Japan) at a resolution of 1600 × 1200 pixels; contrast and brightness were automatically adjusted for all images using Adobe Photoshop 7.0 software (Adobe, San Jose, CA, USA), and the images were then evaluated in a dark room using a 15-inch screen and a 1280 × 800 pixel resolution. Images of the initial and consecutive periapical status were evaluated separately by three observers (experienced endo-dontist) using the PAI and a scoring sheet. For cases in doubt, a higher score was assigned. All observers were calibrated until an adequate interexaminer consistency was achieved and were blind to the aims of the study, as only the apical third of the radiographic images were shown to them and the rest of the image was covered with a black image box.

If during any follow-up, a PAI ≤ 2 and clinical success was found, the case was considered to be concluded. If the tooth belonged to the control group, it was definitely restored, whereas if belonged to the experimental group, the obturation of the complete canal was done before being restored (Figure 7).

Statistical Analysis

The interexaminer consistency was performed by the kappa coefficient. Descriptive analyses including mean and standard deviations were performed for all variables. Patient’s characteristics, including teeth, clinical parameters and PAI scores, are expressed as frequencies and percentages. Data were analysed using the Mann-Whitney test for quantitative and the χ^2 test or the Fisher exact test (when appropriate) for qualitative values. For all tests, P < 0.05 was considered statistically significant.

RESULTS

Seven patients were eliminated from the study because they fail to attend all the follow-ups. The interexaminer consistency was 0.80. Patients’ characteristics data are summarized in Table 1. There was no statistical difference in the distribution of the patients by age or gender. The mean age of the study population was around 45 years; and the gender was slightly predominant female (62.8%). No statistical difference was found in the distribution of tooth included in both groups (Table 2).

There were no significant differences between the groups in terms of preoperative conditions. Only in the one-month postoperative evaluation, there were reports of the presence of pain, swelling, tenderness to palpitations or to percussion and abnormal tooth mobility; however, no significant differences were observed between groups (Table 3). In none of the other follow-ups were there any signs or symptoms. With respect to the PAI, no patients were scored less than 5 in the first two fol-

TABLE 1. Clinical characteristics of the study patients

Group	Complete obturation n=16	Only apical obturation n=19	P
	$\bar{X} \pm SD$ (Range)		
Age (years)*	46.7 ± 12.1 (21-62)	43.3 ± 17.2 (21-80)	0.3710
	Frequency (%)		
**Male	8 (50)	5 (26.3)	0.1789
Female	8 (50)	14 (73.6)	

X: Mean; SD: Standard deviation; *Mann-Whitney test; ** Fisher exact test

TABLE 2. Distribution of the teeth included in both groups

	Complete n=16 obturation	Only apical obturation n=19
	Frequency (%)	
Molars	10 (62.5)	10 (52.6)
Premolars	3 (18.7)	3 (15.7)
Incisors	3 (18.7)	6 (31.5)

P=0.6879; Chi-square test

TABLE 3. Preoperative and one-month postoperative evaluations of both groups

	Complete obturation n=16	Only apical obturation n=19	P*
	Frequency (%)		
Preoperative evaluation			
Presence of Pain	11	9	0.3064
Presence of swelling	9	10	1.0000
Tenderness to palpitations	10	13	0.7362
Tenderness to percussion	11	15	0.7003
Presence of abnormal tooth mobility	6	9	0.7338
One Month Postoperative evaluation			
Presence of Pain	1	2	1.0000
Presence of swelling	0	0	N/A
Tenderness to palpitations	1	1	1.0000
Tenderness to percussion	1	2	1.0000
Presence of abnormal tooth mobility	1	1	1.0000

*Fisher exact test

low-ups (1 and 3 months), but from the third and subsequent (6, 9, 12 and 15 months), lower scores were assigned. Twelve months were enough for 68.1% of the experimental group and 74.9% of the control group to go through the initial PAI-5 score to a PAI ≤ 2 score. At 15 months of follow-up, all missing cases of both groups (100%) were classified with a PAI ≤ 2 score (Table 4) so the trial finished at this point. No statistical difference was observed between the number of cases that ended the study with a PAI-1 or -2 score (Table 5).

In general, all cases presented clinical success, absence of pain, swelling, sinus tract, tenderness to palpation or percussion and presented normal tooth mobility.

TABLE 4. Six to 15 months' distribution of PAI scores in both groups

	Complete obturation (n=16)		Only apical obturation (n=19)	
	PAI-1	PAI-2	PAI-1	PAI-2
	Frequency (%)			
6 months	0	0	1 (5.2)	0
9 months	6 (37.5)	2 (12.5)	4 (21.0)	1 (5.2)
12 months	3 (18.7)	1 (6.2)	4 (21.0)	3 (15.7)
15 months	3 (18.7)	1 (6.25)	4 (21.0)	2 (10.5)

TABLE 5. Comparison of both groups ended on a PAI-1 or -2 score

	Complete obturation (n=16)	Only apical obturation (n=19)
Frequency (%)		
PAI1	12 (75)	13 (68.4)
PAI	2 (25)	6 (31.5)

P=0.7233; Fisher exact test

DISCUSSION

Root canal treatment of teeth with apical periodontitis aims at the complete elimination of microbial invaders; however, endodontic treatment might still fail in some cases because of the incredible persistence and difficulty to eliminate of the microbial biofilm despite mechanical and chemical disinfection (18, 19).

Literature shows that microbial biofilms are difficult to remove from the root canal system, yet the favourable outcome for apical periodontitis is in a range of 75%-80% (13, 20, 21). It has been suggested that this rate of success is due to an appropriate reduction of the microbial bioburden to levels that are compatible with peri-radicular tissue healing (22). This may be true only to some extent, because it is well-known that if any bacteria survive to the mechanical and chemical disinfection and it is exposed to nutrients such as serum in the case of apical third, these organisms can alter their gene expression to accommodate to their new environment (10, 23-25) and will adversely affect the outcome of the root canal treatment (18, 26, 27). This has been shown in earlier clinical cross-sectional studies in humans (19, 28). The high rate of success can only be explained by the fact that microorganisms have been adequately isolated from the periapical tissues by obturation. In this study, the root canal treatment procedures were performed in root canals where a microbial bio-film is well-established and will be impossible to be completely eliminated, despite performing all mechanical and chemical routine procedures. By eliminating the obturation materials of most of the canal, the remaining bacteria would multiply or at least remain present for a while if they do not find a substrate. These bacteria without the apical sealing could maintain or even aggravate the periapical disease.

Results of this study are somehow consistent to the outcomes of performing endodontic treatment in one or two appointments using calcium hydroxide (29). We, as many others,

believe that it has been the same because in both cases the microbial bio-film is only being isolated from the periapical tissues, and neither one nor several appointments can actually eliminate it.

Complete elimination of microbial irritants is a fundamental objective of endodontic treatment. However, with all the knowledge that currently exists about the biofilm and the complexity of the root canal system, together with advances in root canal treatment procedures, the complete elimination of micro-organisms and their toxins cannot be achieved.

This study was a longitudinal prospective controlled investigation in similar patients by age and gender and a similar distribution of the treated teeth. All teeth had the same diagnosis, apical periodontitis and periapical radiolucency, so the included teeth would represent a long-standing pathologic process caused by a well-established intraradicular infection. All this makes the comparison between groups suitable. No clinical symptoms were registered after the first follow-up, thus the outcome was classified mainly on the radiographic evaluation.

The PAI scoring method was used to compare differences in periapical status from the beginning of the treatment to 15 months follow-up evaluation. This index has shown to have the potential for detection of healing with good reproducibility because it is based on a histological correlation (17, 30). A PAI-1 or -2 score is defined as healed or minimally inflamed and PAI-3 to-5 scores are defined as diseased. However, it is still a subjective outcome prone to observer variation. To overcome this disadvantage as much as possible, we undertook the task of calibrating observers until we could have a good consistency.

On the other hand, it is well-known that clinical outcome studies take a long time to monitor, demand substantial economic resources and are at risk of losing patients at follow-ups, so it is a common problem with these clinical studies to achieve enough sample size to a statistical significance. The number of patients available in our study as well as most other prospective studies is limited, within the limitations, no significant differences in the healing of periapical radiolucency were observed. Clinical success of teeth filled in the apical was comparable to those teeth filled to the canal orifices despite the small sample size included, these findings may still be clinically relevant. In this study, we had a high success rate in both groups that do not coincide with previous reports. This could be attributed to differences in study parameters and inclusion criteria for patients selection. Studies showed that systemic diseases such as diabetes or a compromised immune system have a significant influence on the success rate of root canal treatment on teeth with apical lesions (31, 32). We excluded cases with presence of sinus tracts or periapical radiolucency was larger than 4 mm. A better prognosis has been reported in teeth with periapical lesions with diameter less than 5 mm compared to larger lesions (33, 34). In addition, as we only included single rooted (one canal) teeth and distal roots of mo-

lars, some clear complexi-ties of the treatment of multi-rooted teeth were eliminated. Furthermore, by including only the distal roots, we eliminated the possibility of counting that teeth as a failure, as when some multi-rooted teeth are evaluated as whole units, the risk of observing persistent apical periodontitis after treatment is multiplied. Notably, this study has only included mandibular teeth. It has been reported that a better outcome is usually observed in mandibular than in maxillary teeth (34). We do not promote stopping cleaning and shaping of the root canals or filling routinely only the apical third. Rather, we firmly believe that if an adequate apical seal is performed in every case, the general success rate will not be affected, providing that there is an adequate coronal seal.

Investigations have shown that more than 2 mm short or beyond the apical foramen could result in poor treatment outcomes (12). Studies also showed that 1 mm loss in working length is enough to increase the incidence of treatment failures in teeth with apical periodontitis (12, 35). It has been concluded that a periapical tissue response will not develop unless microbial irritants can have a pathway to the periapical tissues.

Three-dimensional filling of the root canals will entomb the remaining micro-organisms inside the root canal walls; however, this procedure is unpredictable, especially in the apex. That is why it is very important to confirm the working length during entire procedure and to ensure the canal patency by passing a size 06, 08 or 10 hand file to the canal length before obturation, with an adequate working length control, the sealer and/or gutta-percha will flow into recesses of the canal (including accessory canals).

There is not enough evidence yet to support the ability to improve clinical performance of many of the recently introduced obturation materials and techniques. This emphasizes the need to translate anecdotal information into clinically relevant research data on new obturating materials and techniques.

CONCLUSION

Within the limitations of this study, no significant differences in healing rates after complete obturation or only apical third obturation were observed. An adequate apical sealing can improve periapical healing; thus, intracanal remnant bacteria apparently have no significant impact, at least for the first 15 months of follow-up.

Ethics Committee Approval: The study protocol was reviewed and approved by the Investigation Committee of the Dentistry area of the Autónoma de Querétaro University School of Medicine.

Peer-review: Externally peer-reviewed.

Author Contributions: Concept - R.G.S.L.T., R.A.D.P.; Design - R.G.S.L.T., R.A.D.P.; Supervision - K.P.S.M., R.G.S.L.T., R.A.D.P.; Resources - R.G.S.L.T., R.A.D.P.; Materials - R.G.S.L.T., K.P.S.M.; Data Collection and/or Processing - R.G.S.L.T., R.A.D.P. Analysis and/or Interpretation - R.A.D.P., R.E.M.M.; Literature Search - R.A.D.P., K.P.S.M.; Writing Manuscript - R.A.D.P., R.E.M.M.; Critical Review -

R.E.M.M., R.A.D.P.

Conflict of Interest: No conflict of interest was declared by the authors.

Financial Disclosure: The authors declared that this study has received no financial support.

REFERENCES

- Kabak Y, Abbott P V. Prevalence of apical periodontitis and the quality of endodontic treatment in an adult Belarusian population. *Int Endod J* 2005;38(4):238-45. [CrossRef]
- Stashenko P, Teles R, D'Souza R. Periapical inflammatory responses and their modulation. *Crit Rev Oral Biol Med* 1998;9(4):498-521. [CrossRef]
- Torabinejad M, Eby WC, Naidorf JI. Inflammatory and immunological aspects of the pathogenesis of human periapical lesions. *J Endod* 1985;11(11):479-88. [CrossRef]
- Haapasalo M, Endal U, Zandi H, Coil JM. Eradication of endodontic infection by instrumentation and irrigation solutions. *Endod Top* 2005;10(1):77-102. [CrossRef]
- Sabeti MA, Nekofar M, Motahhary P, Ghandi M, Simon JH. Healing of apical periodontitis after endodontic treatment with and without obturation in dogs. *J Endod* 2006;32(7):628-33. [CrossRef]
- Bystrom A, Sundqvist G. Bacteriologic evaluation of the efficacy of mechanical root canal instrumentation in endodontic therapy. *Eur J Oral Sci* 1981;89(4):321-8. [CrossRef]
- Dalton BC, Ørstavik D, Phillips C, Pettiette M, Trope M. Bacterial reduction with nickel-titanium rotary instrumentation. *J Endod* 1998;24(11):763-7.
- Nair PNR, Henry S, Cano V, Vera J. Microbial status of apical root canal system of human mandibular first molars with primary apical periodontitis after "one-visit" endodontic treatment. *Oral Surgery, Oral Med Oral Pathol Oral Radiol Endodontology* 2005;99(2):231-52. [CrossRef]
- Nair PNR, Sjögren U, Figdor D, Sundqvist G. Persistent periapical radiolucencies of root-filled human teeth, failed endodontic treatments, and periapical scars. *Oral Surgery, Oral Med Oral Pathol Oral Radiol Endodontology* 1999;87(5):617-27. [CrossRef]
- Costerton JW, Stewart PS, Greenberg EP. Bacterial biofilms: a common cause of persistent infections. *Science* (80-). 1999;284(5418):1318-22.
- Carr GB, Schwartz RS, Schaudinn C, Gorur A, Costerton JW. Ultrastructural examination of failed molar retreatment with secondary apical periodontitis: an examination of endodontic biofilms in an endodontic retreatment failure. *J Endod* 2009;35(9):1303-9. [CrossRef]
- Sjögren ULF, Hägglund B, Sundqvist G, Wing K. Factors affecting the long-term results of endodontic treatment. *J Endod* 1990;16(10):498-504.
- Ng Y, Mann V, Rahbaran S, Lewsey J, Gulabivala K. Outcome of primary root canal treatment: systematic review of the literature-Part 2. Influence of clinical factors. *Int Endod J* 2008;41(1):6-31.
- de Chevigny C, Dao TT, Basrani BR, Marquis V, Farzaneh M, Abitbol S, et al. Treatment outcome in endodontics: the Toronto study—phases 3 and 4: orthograde retreatment. *J Endod* 2008;34(2):131-7. [CrossRef]
- de Chevigny C, Dao TT, Basrani BR, Marquis V, Farzaneh M, Abitbol S, et al. Treatment outcome in endodontics: the Toronto study—phase 4: initial treatment. *J Endod* 2008;34(3):258-63. [CrossRef]
- Ng Y, Mann V, Gulabivala K. A prospective study of the factors affecting outcomes of nonsurgical root canal treatment: part 1: periapical health. *Int Endod J* 2011;44(7):583-609. [CrossRef]
- Ørstavik D, Kerekes K, Eriksen HM. The periapical index: a scoring system for radiographic assessment of apical periodontitis. *Dent Traumatol* 1986;2(1):20-34. [CrossRef]
- Sundqvist G, Figdor D, Persson S, Sjögren U. Microbiologic analysis of teeth with failed endodontic treatment and the outcome of conservative re-treatment. *Oral Surgery, Oral Med Oral Pathol Oral Radiol Endodontology* 1998;85(1):86-93. [CrossRef]
- Pinheiro ET, Gomes B, Ferraz CCR, Teixeira FB, Zaia AA, Souza Filho FJ. Evaluation of root canal microorganisms isolated from teeth with endodontic failure and their antimicrobial susceptibility. *Oral Microbiol Immunol* 2003;18(2):100-3. [CrossRef]
- Friedman S, Abitbol S, Lawrence HP. Treatment outcome in endodontics: the Toronto Study. Phase 1: initial treatment. *J Endod* 2003;29(12):787-93.
- Farzaneh M, Abitbol S, Lawrence HP, Friedman S. Treatment outcome in endodontics—the Toronto Study. Phase II: initial treatment. *J Endod* 2004;30(5):302-9. [CrossRef]

22. Siqueira JF, Rôças IN. Clinical Implications and Microbiology of Bacterial Persistence after Treatment Procedures. *J Endod* 2008;34(11). [\[CrossRef\]](#)
23. Hall-Stoodley L, Costerton JW, Stoodley P. Bacterial biofilms: from the natural environment to infectious diseases. *Nat Rev Microbiol* 2004;2(2):95-108. [\[CrossRef\]](#)
24. Donlan RM, Costerton JW. Biofilms: survival mechanisms of clinically relevant microorganisms. *Clin Microbiol Rev* 2002;15(2):167-93. [\[CrossRef\]](#)
25. Costerton W, Veeh R, Shirliff M, Pasmore M, Post C, Ehrlich G. The application of biofilm science to the study and control of chronic bacterial infections. *J Clin Invest* 2003;112(10):1466-77. [\[CrossRef\]](#)
26. Sjögren U, Figdor D, Persson S, Sundqvist G. Influence of infection at the time of root filling on the outcome of endodontic treatment of teeth with apical periodontitis. *Int Endod J* 1997;30(5):297-306. [\[CrossRef\]](#)
27. Waltimo T, Trope M, Haapasalo M, Ørstavik D. Clinical efficacy of treatment procedures in endodontic infection control and one year follow-up of periapical healing. *J Endod* 2005;31(12):863-6. [\[CrossRef\]](#)
28. Molander A, Reit C, Dahlén G, Kvist T. Microbiological status of root-filled teeth with apical periodontitis. *Int Endod J* 1998;31(1):1-7. [\[CrossRef\]](#)
29. Sathorn C, Parashos P, Messer HH. Effectiveness of single-versus multiple-visit endodontic treatment of teeth with apical periodontitis: a systematic review and meta-analysis. *Int Endod J* 2005;38(6):347-55. [\[CrossRef\]](#)
30. Kerosuo E, Ørstavik D. Application of computerised image analysis to monitoring endodontic therapy: reproducibility and comparison with visual assessment. *Dentomaxillofac Radiol* 1997;26(2):79-84. [\[CrossRef\]](#)
31. Marending M, Peters OA, Zehnder M. Factors affecting the outcome of orthograde root canal therapy in a general dentistry hospital practice. *Oral Surgery, Oral Med Oral Pathol Oral Radiol Endodontology* 2005;99(1):119-124. [\[CrossRef\]](#)
32. Fouad AF, Burleson J. The effect of diabetes mellitus on endodontic treatment outcome: data from an electronic patient record. *J Am Dent Assoc* 2003;134(1):43-51. [\[CrossRef\]](#)
33. Hoskinson SE, Ng YL, Hoskinson AE, Moles DR, Gulabivala K. A retrospective comparison of outcome of root canal treatment using two different protocols. *Oral Surgery, Oral Med Oral Pathol Oral Radiol Endodontology* 2002;93(6):705-715. [\[CrossRef\]](#)
34. Ørstavik D, Qvist V, Stoltze K. A multivariate analysis of the outcome of endodontic treatment. *Eur J Oral Sci* 2004;112(3):224-230. [\[CrossRef\]](#)
35. Chugal NM, Clive JM, Spångberg LSW. Endodontic infection: some biologic and treatment factors associated with outcome. *Oral Surgery, Oral Med Oral Pathol Oral Radiol Endodontology* 2003;96(1):81-90. [\[CrossRef\]](#)