

# Primary Lung Lymphoma

Mesiha Babalık, Abdullah Şimşek, İlhami Yapıcı

Clinic of Chest Diseases, Prof. Dr. Türkan Akyol Chest Diseases Hospital, Bursa, Turkey

## Abstract

Primary lung lymphoma (PLL) is a rare entity. It is difficult to diagnose, with a nonspecific clinical and radiological presentation. It may masquerade as pneumonia and lung tumors, and this disease should be kept in mind especially in the differential diagnosis of nonresolving pneumonias. This report describes a PLL case.

**Keywords:** Diagnosis, lung, primary lymphoma

## INTRODUCTION

Primary lung lymphoma (PLL) accounts less than 1% of lung cancers (1), 0.4% of all lymphomas, and 3.6% of non-Hodgkins lymphomas (2). Patients with PLL mostly have nonspecific symptoms, such as persistent cough, or maybe asymptomatic. PLL can mimic pneumonia, and its clinical course is slow (3). It is diagnosed if extra-pulmonary involvement is ruled out. Surgical procedures are needed for definitive diagnosis for most of the cases. According to the Ann Arbor pulmonary lymphoma staging system,

Stage

IE: Lung only, could be bilateral

II 1E: Lung and hilar lymph nodes

II 2E: Lung and mediastinal lymph nodes

II 2EW: Lung & chest wall or diaphragm

III: Lung and lymph nodes below the diaphragm

IV: Diffuse

This report describes a PLL case.

## CASE PRESENTATION

A 56-years-old male smoker admitted to clinic with a complaint of chest pain. Three years ago, he was diagnosed with pneumonia and flexible bronchoscopy had been performed. Bronchoscopic appearance and histopathologic and microbiological results of bronchial lavage had been found normal then.

Physical examination was normal. Chest X-ray showed bilateral consolidations in both lungs. Laboratory test results were all within the normal range except C-reactive protein, which was high at 9.9 mg/L (normal range 0–5). Computerized tomography (CT) of thorax showed bilateral consolidations with air bronchograms at the middle (lingula of the left lung) and lower lobes of both lungs and right pleural effusion (Figure 1). CT-guided transthoracic tru-cut lung biopsy yielded diffuse B cell lymphoma. Positron emission tomography (PET) CT revealed standard uptake value (SUV) of 5.6 for the anterobasal segment of the right lung, 5.5 for the inferior lingular segment of the left lung, and 3.8 for the right and left paratracheal lymph nodes (Figure 2). Based on these findings, PLL was diagnosed. He was referred to the oncology clinic.



Received Date: 06.11.2015

Accepted Date: 23.01.2016

Available Online Date: 14.03.2016

DOI: 10.5152/ejp.2016.39200

Corresponding Author

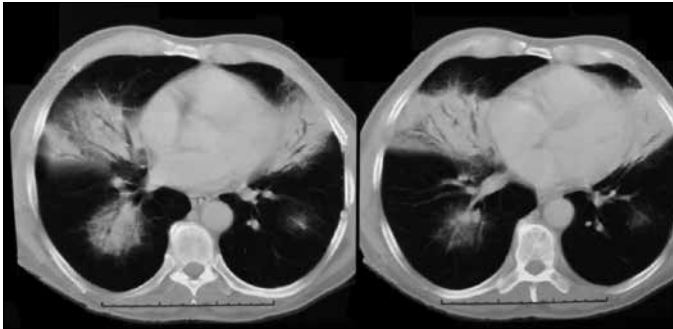
Abdullah Şimşek

E-mail: abdullahsimsek1@yahoo.com.tr

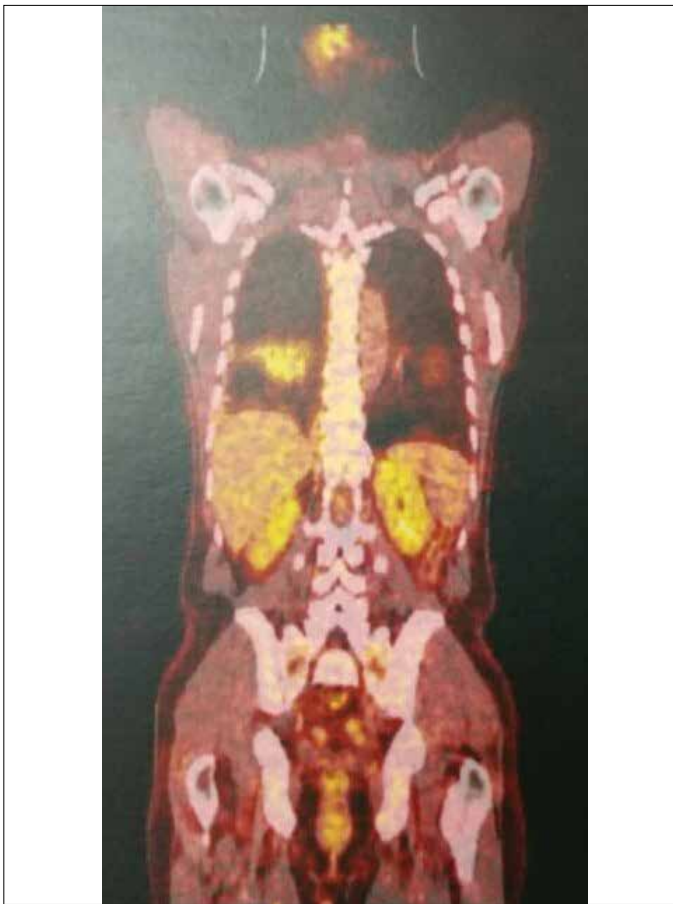• Available online at [www.eurasianj pulmonol.com](http://www.eurasianj pulmonol.com)



This work is licensed under a Creative Commons Attribution-NonCommercial 4.0 International License.



**Figure 1.** Thorax CT: Bilateral consolidations with air bronchograms  
CT: computed tomography



**Figure 2.** PET-CT Image  
PET-CT: positron emission tomography-computed tomography

## DISCUSSION

The most frequent type of PLL is mucosa-associated lymphoid tissue lymphoma accounting for 58-87% of cases, but diffuse large B-cell lymphoma accounts for 5-20% of cases (4, 5).

Characteristics of the PLL are as follows: 1) Difficult to diagnose, with a nonspecific clinical and radiological presentation; 2) Diagnostic yield is low; 3) Difficult to differentiate from pseudo-lymphomas; and 4) Outcome is good. PLL is commonly seen in the fifth decade followed by late sixth and seventh decades of life. There is no extra-pulmonary involvement in PLL, but hilar or mediastinal lymph node involvement or chest wall involvement can be seen (6). In our patient,

there was bilateral involvement of the lung with mediastinal lymph node involvement. PET-CT showed no extra-pulmonary involvement.

Primary lung lymphoma may masquerade as pneumonia and lung tumors. It generally follows an indolent and slow clinical course and is detected incidentally on radiograms. Similarly, our patient had been misdiagnosed as pneumonia 3 years ago.

Radiographic findings of PLL are not specific, but the typical presentations are single or multiple nodular infiltrations involving one or both lungs; these infiltrations frequently have air bronchograms (1, 7). Nodal involvement is seen in 30% of the cases. Pleural effusions have been found in 25% of the cases. Atelectasis is rare. In our patient, there were bilateral consolidations with air bronchograms and pleural effusion.

It has been shown that 66.7% of the patients required surgical procedures to establish the definitive diagnosis. Bronchoscopy in 83% revealed the disease, but transbronchial lung biopsy was useful only in 30% of the patients (8). In the present case, diagnosis of PLL was confirmed by CT-guided transthoracic tru-cut lung biopsy.

According to Ann Arbor staging system, the present case was stage II 2E.

The prognostic factors are not well defined. The prognostic value of the hilar or mediastinal node involvement is controversial (9, 10). Higher stage disease was associated with a significantly worse outcome according to Graham et al. (1). However, it was suggested that bilateral disease was the most important prognostic factor. In the majority of cases, surgery may be used followed by chemotherapy. PLL has a good prognosis and a recurrence rate of less than 50% (1).

## CONCLUSION

Primary lung lymphoma is a rare entity; when bilateral pulmonary lesions are seen with a nonspecific clinical presentation, physicians should consider PLL in the differential diagnosis.

**Informed Consent:** We could not reach or communicate with them because of incorrect telephone number patient gave us. So written/verbal informed consent could not be obtained from the patient or parents of patient.

**Peer-review:** Externally peer-reviewed.

**Author Contributions:** Concept - M.B.; Design - A.Ş., M.B.; Supervision - A.Ş., İ.Y.; Materials - İ.Y.; Data Collection and/or Processing - M.B., A.Ş.; Analysis and/or Interpretation - A.Ş., İ.Y.; Literature Search - İ.Y., A.Ş.; Writing Manuscript - A.Ş.; Critical Review - A.Ş., M.B.

**Conflict of Interest:** No conflict of interest was declared by the authors.

**Financial Disclosure:** The authors declared that this study has received no financial support.

## REFERENCES

- Graham BB, Mathisen DJ, Mark EJ, Takvorian RW. Primary pulmonary lymphoma. *Ann Thorac Surg* 2005; 80: 1248-53. [\[CrossRef\]](#)
- Rosenberg SA, Diamond HD, Jaslowitz B, Craver LF. Lymphosarcoma: a review of 1269 cases. *Medicine* 1961; 40: 31-84. [\[CrossRef\]](#)
- Ünsal İ, Anar C, Yılmaz U, Hailiçolar H, Kargı A, Pişkin Ö. Primary Pulmonary Lymphoma (BALT Lymphoma): A Case report. *Turk Thorac J* 2010; 11: 80-3. [\[CrossRef\]](#)

4. Cadranel J, Wislez M, Antoine M. Primary pulmonary lymphoma. *Eur Respir J* 2002; 20: 750-62. [\[CrossRef\]](#)
5. Matsumoto T, Otsuka K, Funayama Y, Imai Y, Tomii K. Primary pulmonary lymphoma mimicking a refractory lung abscess: A case report. *Oncol Lett* 2015; 9: 1575-8. [\[CrossRef\]](#)
6. Saltzstein SL. Pulmonary malignant lymphomas and pseudolymphomas: Classification, therapy and prognosis. *Cancer* 1963; 16: 928-55. [\[CrossRef\]](#)
7. Chua SC, Rozalli FI, O'Connor SR. Imaging features of primary extranodal lymphomas. *Clin Radiol* 2009; 64: 574-88. [\[CrossRef\]](#)
8. Zinzani PL, Tani M, Gabriele A, Poletti V, Stefoni V, Alinari L, et al. Extranodal marginal zone B-cell lymphoma of MALT-type of the lung: single-center experience with 12 patients. *Leuk Lymphoma*. 2003; 44: 821-4. [\[CrossRef\]](#)
9. Ferraro P, Trastek V, Adlakha H, Deschamps C, Allen MS, Pairolero P. Primary non Hodgkins lymphoma of the lung. *Ann Thorac Surg* 2000; 69: 993-7. [\[CrossRef\]](#)
10. Hu YH, Hsiao LT, Yang CF, Chiou TJ, Liu JH, Gau JP, et al. Prognostic factors of Chinese patients with primary pulmonary non-Hodgkins lymphoma: the single-institute experience in Taiwan. *Ann Hematol* 2009; 88: 839-46. [\[CrossRef\]](#)