

A Case of Solitary Pulmonary Mass with Air-Bubble Sign: What Is Your Diagnosis?

Murat Yalçınsoy, Esen Akkaya

Clinic of Chest Diseases, Süreyyapaşa Chest Diseases and Thoracic Surgery Training and Research Hospital, İstanbul

A 58-year-old male patient was admitted to our clinic with complaints of productive cough and weight loss (6 kg) having begun with flu-like symptoms 15 days ago. His medical history included the use of acetylsalicylic acid after a cerebrovascular event from 9 years ago. The patient, who worked as a car mechanic, had 40 packs-year of smoking history. In the physical examination, his vital findings and oxygen saturation were within normal reference intervals, and no abnormality was observed, except limping in his right foot. Pulmonary function tests revealed mild obstructive dysfunction. The laboratory test value of C-reactive protein was 7.3, and the values of complete blood count and biochemistry were within normal intervals. The PPD test result was 10 mm.

In the posteroanterior chest X-ray, an oval mass lesion, the long margin of which extended toward the hilus in the neighborhood of the aortic curve on the left, was observed. In the lateral radiography, it was detected that the mass was localized in the upper mediastinum (Figure 1). The parenchymal window of the thorax computerized tomography revealed a 7x4 cm mass lesion extending from the level of the aortic arch in the left upper lobe to the subcarinal level in the neighborhood of the aorta. In the mediastinal window, it was observed that the mass included necrosis and air bubbles (Figure 2).

In the flexible bronchoscopy of the patient, it was determined that the separation of the left upper lobe apicoposterior carina and internal bronchus appeared irregular all around, and there were white nodules on it. The result of the mucosal biopsy that was performed was reported as "extensive squamous metaplasia in the bronchial mucosa epithelium and severe dysplasia." On the other hand, in the autofluorescence bronchoscopy, the mucosa of the carina between the left upper lobe apicoposterior and anterior segment was swollen, hyperemic, and fluorescent (+). Samples from this region were taken with mucosal and brush biopsies. The result of the pathology was "focal squamous metaplasia in the bronchial mucosa epithelium and dysplasia," and the result of the brush biopsy was reported as "inflammatory cells."

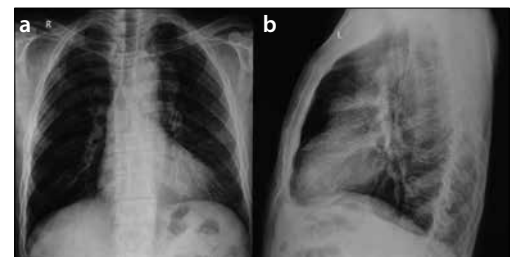


Figure 1. a, b. In the posteroanterior chest X-ray of the patient, an oval mass lesion, the long margin of which extends toward the hilus in the neighborhood of the aortic curve on the left, is seen (a). In the lateral radiography, the lesion is seen in the upper mediastinum (b)

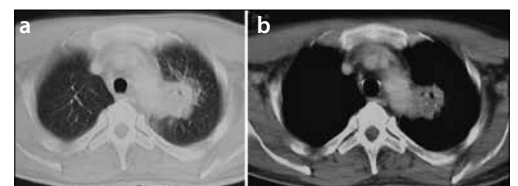


Figure 2. a, b. In the parenchymal window of the thorax computerized tomography, a mass lesion extending from the level of the aortic arch in the left upper lobe to the subcarinal level in the neighborhood of the aorta is seen (a). In the mediastinal window, a mass with necrosis and air bubbles is observed (b)



Received Date: 10.05.2014
Accepted Date: 25.05.2014
Available Online Date: 27.10.2014

Address for correspondence
Murat Yalçınsoy, Clinic of Chest Diseases,
Süreyyapaşa Chest Diseases and Thoracic Surgery
Training and Research Hospital, İstanbul, Turkey
E-mail: mrtyalcinsoy@yahoo.com

© Copyright 2014 Turkish Respiratory Society (TRS)
Eurasian J Pulmonol 2014
DOI: 10.5152/ejp.2014.32042

• Available online at www.eurasianj pulmonol.com

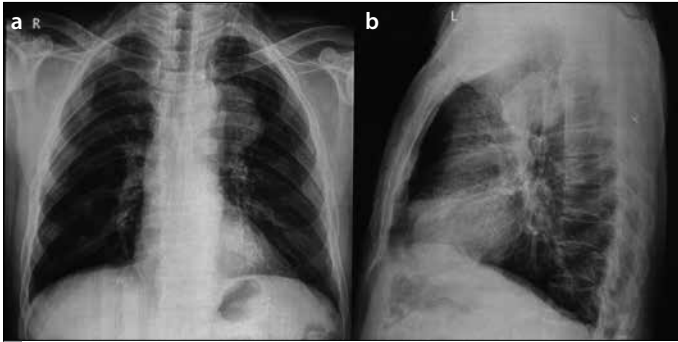


Figure 3. a, b. The progression of the lesion before posteroanterior chest radiography performed for control 8 months later (a). In the lateral radiography, a mass lesion localized in the upper mediastinum is seen (b)

Positron emission tomography (PET-CT) was performed on the patient, for whom a pre-diagnosis of malignancy could not be excluded. In the PET-CT, the SUVmax of the mass, with prevascular localization at the level of the aortic arch in the left upper lobe of the lung, was 3.2. Furthermore, a calcified soft tissue mass was detected in the left gluteal area.

Thoracotomy was considered to be appropriate for the diagnosis, but the patient had begun to be followed up, since he did not accept it. After 8 months, progression of the lesion was observed. However, the patient denied diagnostic intervention again. One year later, thoracotomy was decided to be performed when the patient accepted the procedure (Figure 3). Preoperative bronchoscopy revealed that the left upper lobe apicoposterior subsegment was occluded by a white lesion. When biopsy was performed in this area, purulent matter was exuded. The biopsy material was reported as "extensive squamous metaplasia in the bronchial mucosa epithelium and severe dysplasia." Frozen sectioning was performed for the mass that was settled on the main pulmonary artery

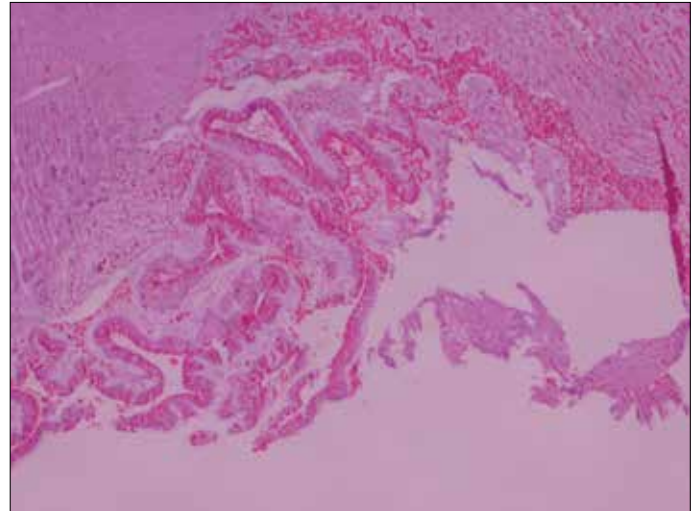


Figure 4. (HEX10) A cystic lesion surrounded by thin fibrous tissue that is lined by high columnar epithelium containing mucin and the margin adjacent to the lumen of which is single-row is seen. Its epithelial nuclei lining the lesion are localized to the basal and are small, uniform, and without mitosis, and the cystic mass consists substantially of large mucin lakes.

and that covered the upper lobe completely in the thoracotomy, and the mass was thought to be a bronchogenic cyst. Because wedge resection was not appropriate, the operation was ended with a left upper lobectomy. A cystic lesion that was surrounded by thin fibrous tissue that was lined by high columnar epithelium containing mucin and located in the pulmonary parenchyma and the margin adjacent to the lumen of which was single-row was detected in the postoperative pathological examination of the nodule. Epithelial nuclei that lined the lesion were localized to the basal part, and they were small and uniform. Also, no mitosis was observed. The cystic mass consisted substantially of large mucin lakes (Figure 4).

What is your diagnosis?

Mucinous cystadenoma

Mucinous cystadenoma, which is included in the adenoma group of benign epithelial tumors, is defined as a mucin-filled and well-differentiated cystic mass surrounded by a fibrous wall lined by columnar mucinous epithelium. If they occur as cystic structures invading adjacent tissue, displaying apparent atypia and pseudostratification and containing a great amount of mucin, they are called mucinous cystadenocarcinoma (1). A limited number of cases are reported in the literature (2, 3). They are benign tumors, and they are seen in the sixth and seventh decades of life in both genders (4). Moreover, bronchogenic cyst and congenital adenoid malformation (among non-neoplastic lesions) and bronchial mucous gland adenoma, mucoepidermoid carcinoma, mucinous bronchioloalveolar carcinoma, and metastatic carcinoma (among neoplastic lesions) should be considered.

Mucinous cystadenoma is generally asymptomatic, and it is diagnosed with the appearance of round, well-defined mass lesion in the chest radiography performed incidentally. Establishing a preoperative diagnosis is difficult in most cases. They can grow over time. The mass should be excised surgically for the final diagnosis.

Also, in our patient, the diagnosis was established and a cure was provided after the cyst was excised surgically. The patient is still followed up, and no finding of recurrence has been observed.

Informed Consent: Verbal informed consent was obtained from patient who participated in this study.

Peer-review: Externally peer-reviewed.

Author contributions: Concept - M.Y., E.A.; Design - M.Y., E.A.; Supervision - M.Y., E.A.; Resource - M.Y., E.A.; Materials - M.Y., E.A.; Data Collection and/or Processing - M.Y., E.A.; Analysis and/or Interpretation - M.Y., E.A.; Literature Review - M.Y., E.A.; Writing - M.Y., E.A.; Critical Review - M.Y., E.A.

Conflict of Interest: No conflict of interest was declared by the authors.

Financial Disclosure: The authors declared that this study has received no financial support.

REFERENCES

1. Travis WD, Brambilla E, Muller-Hermelink HK, Harris CC, editors. World Health Organization classification of tumors. pathology and genetics of tumors of the lung, pleura, thymus and heart. Lyon: IARC Press; 2004. p.
2. Gao ZH, Urbanski SJ. The spectrum of pulmonary mucinous cystic neoplasia: a clinicopathologic and immunohistochemical study of ten cases and review of literature. *Am J ClinPathol* 2005; 124: 62-70. [\[CrossRef\]](#)
3. Matsuo T, Yusuke Kimura N, Takamori S, Shirouzu K. Recurrent pulmonary mucinous cystadenoma. *Eur J Cardiothorac Surg* 2005; 28: 176-7. [\[CrossRef\]](#)
4. Ertan Aydın, NurettinKaraoğlanoğlu. Rare lung tumors. In: Yücel O, editor. Lung diseases and their treatment. 1st ed. Ankara: DermanYayıncılık; 2013.p.58-64.