

A Tracheal Diverticulum Case Diagnosed Through Three-Dimensional Images

Feyza Yılmaz¹, Selim Kervancıoğlu²

¹Department of Radiology, İnyet Topçuoğlu Medical Center, Gaziantep, Turkey

²Department of Radiology, Gaziantep University Faculty of Medicine, Gaziantep, Turkey

Tracheal diverticulum, which is defined as an air-filled lesion persisting in the trachea or main bronchus, comprises 1-2% of paratracheal lesions (1). Tracheal diverticulum is often asymptomatic and can cause chronic cough, dyspnea, stridor, and recurrent tracheobronchitis (2). Accurate diagnosis can be missed if the connection between the tracheal lumen and the diverticulum is not visualised on bronchoscopy. Tracheal diverticulum can easily be diagnosed non-invasively using volumetric multidetector computed tomography (MDCT).

A 62-year-old male patient presented to our department for MDCT scanning due to the complaint of chronic cough. Physical examination revealed no findings for the patient who smoked 60 pack.year. No abnormal finding was detected in the spirometric measurements or routine laboratory results of the patient. Thorax examination was performed with 64-channel CT (VCT XTeLightSpeed; General Electric, Milwaukee, USA). Section thickness was 3-5 mm, pitch was 1.5, and reconstruction interval was 2-3 mm. Of axial images, reconstruction images obtained via the methods of "multiplanar reformation (MPR), maximum intensity projection (MIP)" and three-dimensional "volume rendering (VR)" were evaluated. An oval irregular-surfaced air-filled lesion was detected at the right postero-lateral region of the tracheal lumen at the level of the thoracic inlet (Figure 1, 2). Since demonstration of a narrow connection to the tracheal lumen is critical for establishing the diagnosis of tracheal diverticulum, the connections were shown with oblique images (Figure 3). No wall thickening or calcifications were found. Bronchoscopy was recommended to the patient for further work-up, but he refused it.

Tracheal diverticula are lesions, usually with thin walls, which can include lobulations and reach diameters ranging from a millimeters to 3-4 cm. The connection between the tracheal wall and the air sac is quite narrow, and its longitudinal length can reach up to 5 mm in sessile form and 15 mm in peduncle form. Bronchogenic cysts, laryngocele, pharyngocele, Zenker's diverticulum, oesophageal diverticulum, apical paraseptal bullae, and apical herniation of the lungs should be taken into consideration for the differential diagnoses of diverticulum (3). There are two types of tracheal diverticulum: congenital and acquired. Congenital tracheal diverticulum is seen more commonly in males than in females. It is located 4-5 cm below the vocal cords or just above the carina, mostly on the right side of the trachea. Its diameter is smaller and its connection to the trachea is narrow. Congenital diverticulum involves all of the tracheal wall layers and it is often full of mucus. The presence of cartilaginous rings on the wall of the diverticulum should suggest high possibility of congenital type. If cartilaginous rings are not observed on the wall of diverticulum, it may be the acquired form of tracheal diverticulum. Other congenital anomalies such as tracheoesophageal fistula can rarely coexist (4). Acquired tracheal diverticulum can occur at any level, but is often located at the postero-lateral region, between the intra-thoracic and extra-thoracic trachea. It is larger than congenital tracheal diverticulum and its neck is wider. Intraluminal pressure that increases due to chronic cough accompanying bronchopulmonary disease causes mucous membrane herniation on the weakened points of the trachea wall and, as a result, diverticulum occurs. Diverticula can be individual or multiple. Unlike congenital diverticulum, the wall



Received Date: 30.01.2014
Accepted Date: 11.02.2014

Address for correspondence
Feyza Yılmaz, Department of Radiology, İnyet
Topçuoğlu Medical Center, Gaziantep, Turkey
E-mail: feyzagelebekyilmaz@hotmail.com

© Copyright 2014 Turkish Respiratory Society (TRS)
Eurasian J Pulmonol 2014
DOI: 10.5152/ejp.2014.29981

• Available online at www.eurasianj pulmonol.com

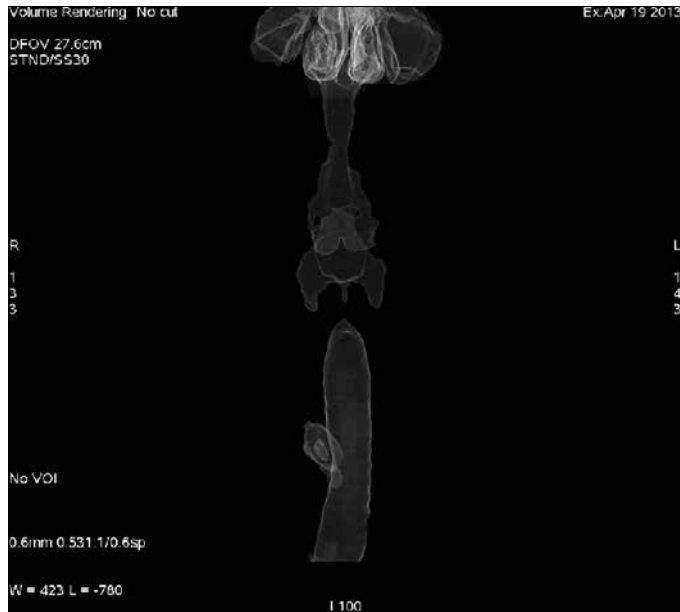


Figure 1. On 3D VR CT imaging, right paratracheal diverticulum from the antero-posterior aspect

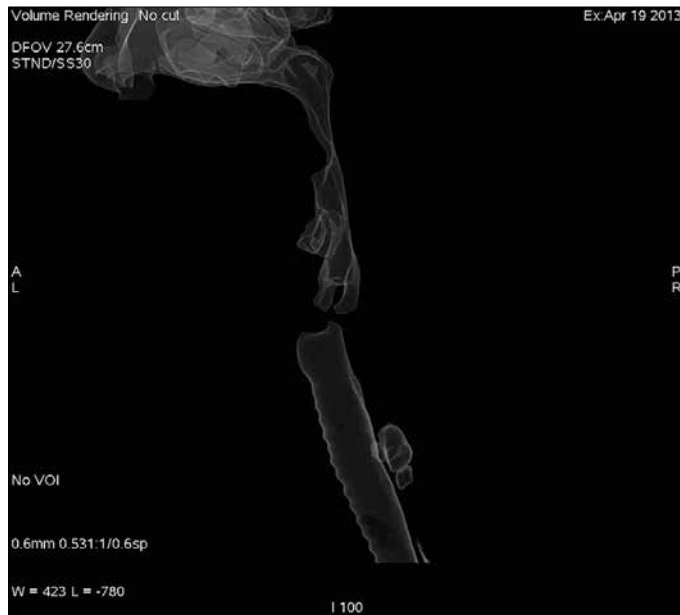

Figure 2. On 3D VR CT imaging, right paratracheal diverticulum from the left lateral aspect

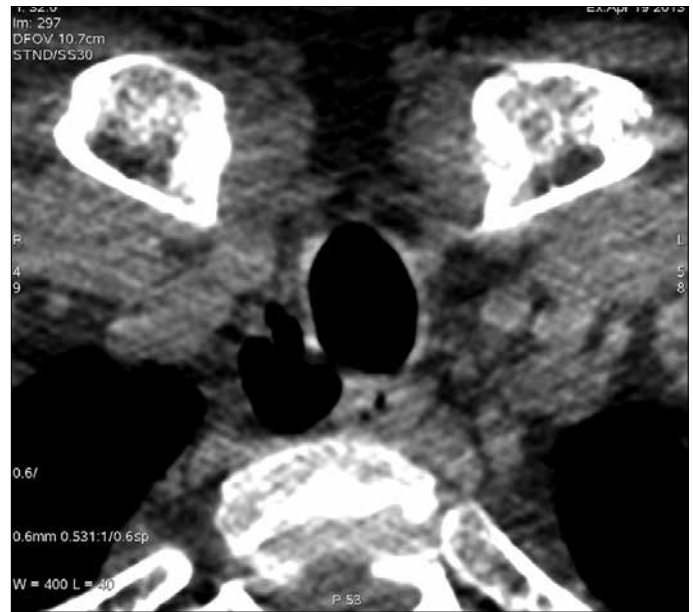

Figure 3. On CT axial section, right paratracheal diverticulum and its neck from oblique aspect

of the acquired form consists of only respiratory epithelium. Many acquired tracheal diverticula can exist with tracheobronchomegaly (5).

Radiological barium studies, endoscopic examination methods and CT can be used for the diagnosis of tracheal diverticulum (6). The neck of the diverticulum, thickened diverticulum wall secondary to recurrent infections, and inflammatory changes around the diverticulum can be visualised on computed tomography. Even if its neck is too small, diverticula can be detected with new generation MDCT.

Since tracheal diverticulum acts as a reservoir for bacteria, the differential diagnosis should be established with CT and symptomatic

cases should be treated definitely. As a treatment method for young patients, surgical resection can be performed. For geriatric patients, however, conservative medical treatments such as antibiotics, mucolytic and physiotherapy are recommended (5,6).

In conclusion, even if the neck is too small, tracheal diverticulum can be non-invasively diagnosed with new generation MDCT, without the need for fiberoptic bronchoscopy. Moreover, the borders and content of diverticulum and its connection to tracheal lumen can be visualised on reconstruction and volume rendering images. Therefore, MDCT scanning should be considered a priority for patients with suspected tracheal diverticulum.

Ethics Committee Approval: N/A.

Informed Consent: Written informed consent was obtained from patient who participated in this study.

Peer-review: Externally peer-reviewed.

Author Contributions: Concept - F.Y.; Design - F.Y., S.K.; Supervision - S.K.; Resources - F.Y.; Data Collection&/orProcessing - F.Y., S.K.; Analysis&/or Interpretation - F.Y., S.K.; Literature Search - F.Y., S.K.; Writing - F.Y.; Critical Reviews - S.K.

Conflict of Interest: No conflict of interest was declared by the authors.

Financial Disclosure: The authors declared that this study has received no financial support.

REFERENCES

1. Endo S, Saito N, Hasegawa T, Sato Y, Sohara Y. Tracheocele: surgical and thoracoscopic findings. *Ann Thorac Surg* 2005; 79: 686-97.
2. Waite S, Sharma A, Machnicki S. Right paratracheal air cyst (tracheal diverticulum). *Applied Radiology* 2003; 32.
3. Han S, Dikmen E, Aydin S, Yapakci O. Tracheal diverticulum: a rare cause of dysphagia. *Eur J Cardiothorac Surg* 2008; 34: 916-7.
4. Early EK, Bothwell MR. Congenital tracheal diverticulum. *Otolaryngol Head Neck Surg* 2002; 127: 119-21.
5. Soto-Hurtado EJ, Penuela-Ruiz L, Rivera-Sanchez I, Torres-Jimenez J. Tracheal diverticulum: a review of the literature. *Lung* 2006; 184: 303-7.
6. Caversaccio M, Becker M, Zbären P. Tracheal diverticulum presenting with recurrent laryngeal nerve paralysis. *Ann Otol Rhinol Laryngol* 1998; 107: 362-4.