

Transbronchial Biopsy: Our Experience in 5 Year

Tülin Sevim¹, Fatma Tokgöz Akyl¹, Meltem Ağca¹, Ayşe Alp Ersev²,
Emine Aksoy¹, Nilüfer Kongar¹, Oğuz Aktaş¹

¹Clinic of Chest Diseases, Süreyyapaşa Chest Diseases and Thoracic Surgery Training and Research Hospital, İstanbul, Turkey

²Clinic of Pathology, Süreyyapaşa Chest Diseases and Thoracic Surgery Training and Research Hospital, İstanbul, Turkey

Abstract

Objective: Transbronchial biopsy (TBB) is an old diagnostic method applied via fiberoptic bronchoscopy. The diagnostic value and complication rate of the procedure were found to vary in previous studies. In present study, the diagnostic value of TBB was analysed.

Methods: All medical files of 308 patients who underwent TBB between May 2010-May 2015 in our clinic were reviewed retrospectively. According to the final diagnoses, the diagnostic value and complication rates of TBB, the contribution of the additional samples of the same bronchoscopic session to the diagnoses, and the requirement of any additional invasive procedure were investigated.

Results: Of all the patients, 63% were female and the mean age was 51 (17-85). Bronchoalveolar lavage was taken in 257 patients. Ten percent of the procedures could not reach lung parenchyma. TBB was diagnostic in 105 (34%) patients. Fifty (16%) patients were diagnosed via other samples of the same session, 15 (5%) resolved spontaneously, 28 (9%) were diagnosed via other clinical findings, 41 (14%) did not accept further invasive method or were lost-to follow-up. Sixty-nine (22%) underwent an additional invasive procedure. The most frequent final diagnosis was sarcoidosis and the diagnostic value of TBB was 49%. Diagnostic rate of TBB was lower in fibrotic interstitial lung diseases (ILD) and malignancy whereas higher in non-fibrotic ILD. No mortality was seen related to TBB, pneumothorax was seen in 6%; non-massive bleeding in 3%, respiratory failure in 0.3%.

Conclusion: Transbronchial biopsy is a procedure having a higher diagnostic value in certain diseases and has an acceptable morbidity. When combined with other bronchoscopic samples, the need for further invasive methods decreases significantly.

Keywords: Fiberoptic bronchoscopy, sarcoidosis, transbronchial biopsy

INTRODUCTION

In pulmonary diseases, it is important to establish diagnosis through minimal invasive methods in terms of reducing cost and complications. Fiberoptic bronchoscopy (FOB)-guided transbronchial biopsy (TBB) is a diagnostic technique that has been used for many years (1). It provides the appropriate sampling particularly in the diagnosis of tuberculosis, organizing pneumonia (OP), and respiratory bronchiolitis in which the involvement of the disease is apparent in the center of or around the bronchioles and in the diagnosis of some diseases such as lymphangitis carcinomatosa and sarcoidosis which have involvement throughout the lymphatic distribution (2).

Transbronchial biopsy should be performed carefully considering its indications and clinical use because some complications associated with the procedure, such as bleeding, pneumothorax, cardiac arrhythmia, and respiratory failure, can develop (3). In recent years, TBB has been reported to be used less frequently due to some reasons including the development of alternative diagnostic methods (4). The diagnostic success and complications of this procedure has been reported at various rates in national and international studies, and there are no large studies conducted on this subject in our country.



Received Date: 21.06.2016

Accepted Date: 29.09.2016

DOI: 10.5152/ejp.2016.96729

Corresponding Author

Fatma Tokgöz Akyl

E-mail: fatmatokgoz286@gmail.com

• Available online at www.eurasianj pulmonol.com



This work is licensed under a Creative Commons Attribution-NonCommercial 4.0 International License.

In this study, the diagnostic success of TBB performed under the guidance of FOB without fluoroscopy in the last 5 years, the complications associated with the procedure, and the degree of the need for further invasive procedure for the final diagnosis when evaluated with the samples taken in the same FOB session were investigated.

METHODS

Patient Selection

The study was a single-centered, retrospective cohort study, and the patients were selected by scanning the electronic database of the hospital. The medical records of 326 patients who underwent FOB-guided TBB in our clinic between May 2010 and May 2015 were evaluated. Of them, 308 patients, who were confirmed to undergo TBB during this period, were included in the study.

Demographic and radiological features of the patients, pre-diagnoses, complications induced by the procedure, pathology results, and follow-up results were recorded. The ethical approval for the study was received from the scientific committee of Süreyyapaşa Chest Diseases and Chest Surgery Training and Research Hospital (Istanbul, Turkey). The study was conducted in accordance with the Declaration of Helsinki. Because it was a retrospective study in which patient files were reviewed, informed consent was not obtained from the patients.

The Procedure of Bronchoscopy

In the procedure of bronchoscopy that was applied in our clinic, patients were monitored, 2% lidocaine was administered as local anesthesia before the process, and sedation was induced using midazolam when needed. In the presence of localized disease, biopsy was taken from the segment including the disease. On the other hand, if there was diffuse involvement, biopsy was collected from the lower lobe anterior or lateral basal segments between 3 and 6 (5). During the procedure, at least, one chest disease specialist and bronchoscopy technician had to be ready.

Study Protocol

Transbronchial biopsy pathology results were classified as "diagnostic" or "non-diagnostic":

- 1) Diagnostic procedure: The procedures in which TBB pathological evaluation provided a specific diagnosis with clinical and radiological findings.
- 2) Non-diagnostic procedure: The procedures in which TBB pathological evaluation did not provide a specific diagnosis with clinical and radiological findings. That is, the procedures in which TBB pathological evaluation were reported as non-specific findings, normal pulmonary parenchyma, or non-existent lung parenchymal involvement.

The patients for whom TBB was non-diagnostic were evaluated in two groups in terms of the need for further invasive procedure (Figure 1):

- a) Patients not undergoing further invasive procedure:
 1. Patients diagnosed via other procedures that were applied in the same session (bronchoalveolar lavage (BAL), microbiological or cytological evaluation of bronchial lavage, brush biopsy, etc.).
 2. Patients diagnosed through other noninvasive diagnostic methods (serological tests, microbiological tests, collagen tissue markers, etc.).

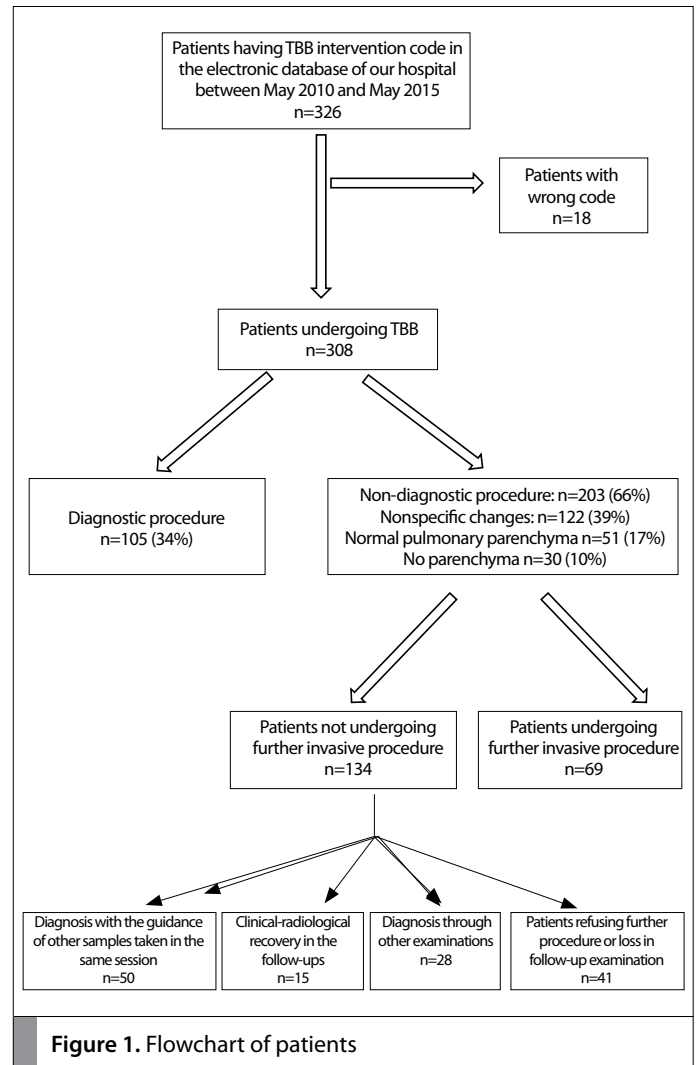


Figure 1. Flowchart of patients

3. Patients not undergoing further diagnostic procedure because of clinical–radiological improvement in the follow-up.
 4. Patients refusing to undergo further invasive procedure or patients not returning for follow-up examination.
- b) Patients undergoing further invasive procedure: Patients undergoing any additional invasive diagnostic procedure after bronchoscopy.

Statistical Analysis

The data obtained were recorded in SPSS for Windows 16.0 (Chicago, IL, USA) software and presented as mean±standard deviation.

RESULTS

Of the 308 patients included in the study, 63% (n=194) were female and the mean age was 51±14 (17–85) years. While radiological findings were localized in 26 (8%) patients, they were multilobar or diffuse in other patients. The indication for TBB was established with the pre-diagnosis of sarcoidosis (51%, n=158) and interstitial pulmonary disease (38%, n=118) in most of the patients and with the pre-diagnosis of tuberculosis and malignancy in other patients under the guidance of radiological and clinical findings. The procedure of bronchoscopy was mostly performed on patients with pre-diagnosis of sarcoidosis. In bronchoscopy, 257 (83%) patients underwent BAL in the same session.

Table 1. Transbronchial biopsy pathology results

	n	%
Diagnostic findings	105	34
Nonspecific changes	122	39
Normal pulmonary parenchyma	51	17
No parenchyma	30	10

Table 2. Further invasive procedures that were performed

	n=69	%
Mediastinoscopy	29	42
Surgical biopsy	26	38
Lymph node biopsy	7	10
TFNAB	3	4
Skin biopsy	2	3
EBUS	2	3

EBUS: Endobronchial ultrasonography; TFNAB: transthoracic fine needle aspiration biopsy

Diagnostic Value of TBB

Parenchyma could not be reached in 30 (10%) patients. In 105 (34%) patients, TBB pathological evaluation with clinical and radiological findings resulted as diagnostic. On the other hand, in 203 (66%) patients, TBB pathological evaluation with the guidance of clinical and radiological findings was non-diagnostic. Of these 203 patients, while parenchymal changes and normal parenchyma were reported in 122 and 51 patients, respectively, parenchyma was not obtained in 30 of them (Table 1).

In the investigation of 203 patients, for whom TBB was non-diagnostic, with regard to additional invasive procedure, it was observed that 134 of them did not undergo further invasive procedure. In 50 of these 134 patients, diagnosis was established through mucosa or brush biopsies, BAL fluids, and microbiological examinations, which were applied in the same session. While 12 patients (4%) refused further invasive procedure, 29 patients (9%) did not visit for follow-up examination.

In 69 (22%) patients, further invasive procedure was applied for diagnosis. The invasive methods that were used are shown in Table 2.

Final Diagnoses

In the detailed evaluation considering diagnoses, the most common final diagnosis was sarcoidosis (40%). In 59 (49%) patients with sarcoidosis, TBB provided a diagnosis with the guidance of clinical and radiological findings. While diagnosis was established through radiological and clinical findings, BAL analysis, bronchial mucosa biopsy, and extrapulmonary organ biopsies in 33 patients, further invasive procedures were required at the rate of 25%. In tuberculosis, which is another granulomatous disease, the rate of the contribution of TBB to diagnosis was 47% and the need for additional process after FOB was 21%.

Organizing pneumonia, which is among non-fibrotic interstitial lung diseases, was supported by TBB pathology in 13 of 16 patients (81%).

Two patients were diagnosed with the help of clinical findings and BAL fluid findings and their diagnosis was confirmed in follow-ups. Surgical biopsy was performed in one patient (5%). In the diagnosis of hypersensitivity pneumonia (HP) and eosinophilic lung disease (ELD), the success rate of TBB pathology for obtaining specific findings was 46% and 60%, respectively. On the other hand, non-diagnostic TBB was confirmed by diagnosing with BAL and clinical findings in the follow-ups.

While the rate of diagnostic findings of TBB was 50% for desquamative interstitial pneumonia and 67% for bronchiolitis, surgical biopsy was performed in other patients. The final diagnosis was usual interstitial pneumonia (UIP) in 21 patients and nonspecific interstitial pneumonia (NSIP) in six patients. The diagnosis of UIP was established with TBB findings in one patient, with surgical biopsy in 11 patients, and with clinical and radiological findings in nine patients. Diagnostic findings of TBB were reported in one of six patients with NSIP.

The diagnosis was established through TBB in all five siderosis patients. Secondary interstitial lung disease (ILD) was diagnosed in 20 patients with ILD, for whom TBB did not provide a specific diagnosis. Sixteen of these patients were followed up with the diagnosis of connective tissue disease and four patients with the diagnosis of drug-induced ILD, and no further procedure was applied for these patients. The success of TBB according to final diagnoses, the rates of diagnosis with other samples taken in the same session, and the need for further invasive procedures are presented in Table 3.

Seven patients were diagnosed with anthracosis and 15 patients who developed radiological improvement in the follow-up were diagnosed with pneumonia. The final diagnosis of 16 patients was malignancy. Of these patients, 10 had primary lung cancer, four had metastatic lung cancer, and two had lymphoma. The success rate of TBB in the diagnosis of malignancy was 6%.

Complications

Mortality associated with the procedure was not observed. Pneumothorax was found in 18 (6%) patients and respiratory failure in one patient. While two patients with pneumothorax recovered with high flow oxygen therapy in the follow-up period, chest tube was inserted in 16 patients. Of the patients developing pneumothorax, eight had sarcoidosis, three were those who did not visit for follow-up examinations or refused further examinations, one had OP, one had HP, one had tuberculosis, one had pneumonia, one had secondary ILD, and one had malignancy. The patient who developed respiratory failure was diagnosed with lung cancer. Non-massive bleeding during the procedure was noted in 11 patients (4%). While four of these patients did not return for follow-up examinations, three were diagnosed with sarcoidosis, two with secondary ILD, and one with bronchiolitis.

DISCUSSION

Our study is the largest series that evaluates TBB findings in our country. The diagnosis was established only through TBB at the rate of 34%, and no mortality was observed. It was found that diagnostic success of TBB varied depending on diseases, and TBB was found to be diagnostic in half of patients with sarcoidosis. While the success of TBB was high in some diseases including OP, ELD, bronchiolitis, tuberculosis, and HP, the need for further invasive procedure, particularly for BAL analysis and clinical assessment, decreased. The rate

Table 3. Diagnostic success of TBB and the need for further invasive procedures according to final diagnoses

	Rate of diagnosis via TBB	Diagnosis with other samples collected in the same session	Further invasive procedure
Sarcoidosis (n=122)	59 (49%)	33 (26%)	30 (25%)
Tuberculosis (n=15)	7 (47%)	5 (32%)	3 (21%)
OP (n=16)	13 (81%)	2 (14%)	1 (5%)
HP (n=13)	6 (46%)	7 (54%)	-
Eosinophilic lung disease ELD (n=5)	3 (60%)	2 (40%)	-
DIP (n=4)	2 (50%)	-	2 (50%)
Bronchiolitis (n=3)	2 (67%)	-	1 (33%)
UIP (n=21)	1 (5%)	-	11 (52%)
NSIP (n=6)	1 (17%)	-	5 (83%)
Siderosis/Pneumoconiosis (n=5)	5 (100%)	-	-
Secondary interstitial disease (n=20)	-	-	-
Anthracosis (n=7)	5 (100%)	-	2
Pneumonia (n=15)	-	-	-
Malignancy (n=16)	1 (6%)	1 (6%)	14 (88%)
Patients loss in follow-up (n=40)	-	-	-

DIP: desquamative interstitial pneumonia; ELD: Eosinophilic lung disease; HP: Hypersensitivity pneumonia; NSIP: nonspecific interstitial pneumonia; OP: organizing pneumonia; TBB: transbronchial biopsy; UIP: usual interstitial pneumonia

of diagnosis was found to be low in fibrotic interstitial diseases and malignancy.

In the study by Çetinkaya et al. (6) 53 cases were evaluated with TBB. In this series, while seven of the lesions were localized, parenchyma could not be reached in 28% of the procedures and diagnosis was established in 57%. Uçar et al. (7) evaluated 104 cases and they reported TBB to be diagnostic at the rate of 48%. In our series, parenchyma was reached in 90% of cases, and diagnostic rate was found to be lower than in other studies. These different rates might have resulted from different patient distribution in the study group. In our series, the diagnosis of secondary ILD was established on the basis of serological tests and clinical findings in 20 patients and TBB was not diagnostic in these patients. Moreover, radiological improvement was observed in the follow-up examination of 15 patients and these patients were evaluated to have pneumonia. When considered from this point of view, it can be suggested that more attention should be paid for TBB indication.

With regard to TBB success according to diagnoses, Çetinkaya et al. (6) obtained the highest diagnostic success rate in sarcoidosis (66%)

and in malignancy (60%). This rate was reported to be above 50% for malignancy, tuberculosis, and sarcoidosis and 100% for PCP and silicosis in the study by Uçar et al. (7). In this series, the success rate was 51% in diffuse lesions and 59% in localized lesions. Descombes et al. (8) succeeded at the rate of 92% in HP and 75% in sarcoidosis with parenchymal involvement. In other studies, the diagnostic rate of TBB for sarcoidosis was reported to be 54%–60% (9, 10). In our series, the diagnostic rate of TBB was 49% in sarcoidosis, the diagnosis of which was more common. Because we did not classify patients according to the presence of parenchymal involvement, this rate was for all sarcoidosis patients with and without parenchymal involvement.

It is known that due to patchy involvement, TBB has low sensitivity but high specificity in the pattern of UIP (11). In recent years, particularly with the description of radiological diagnostic criteria for UIP, the rate of TBB application has decreased in those patients. Also, in our series, diagnostic rates are low in fibrotic ILD, such as UIP and NSIP. In non-fibrotic interstitial diseases, diagnostic rate was about 50% for Desquamative Interstitial Pneumonia (DIP) and bronchiolitis. This rate was high in OP patients. A diagnosis was established in almost half of HP and ELD patients. These results emphasize the importance of radiological fibrosis signs in TBB indication.

When the results of BAL fluid taken under the guidance of bronchoscopy were evaluated with biopsy, the need for further invasive process reduces (12). Barut et al. (13) reported that the rate of accurate diagnosis increased when BAL and TBB materials were combined. In our series, cellular analysis of BAL fluid decreased the need for surgical biopsy in patients having sarcoidosis, OP, ELD, and HP and not undergoing further invasive process.

Recently, it has been reported that the frequency of TBB application has decreased because of complications associated with the procedure and because of the development of alternative diagnostic methods (4). Transbronchial cryobiopsy is a new method that comes into prominence particularly in the diagnosis of diffuse parenchymal lung disease. Compared to flexible bronchoscopy, its advantages are shown to be higher success rate in reaching parenchyma, the ability to collect larger samples, and the absence of crushing artifacts in the samples. The diagnostic success rate of cryobiopsy was reported to be 76-77%. The rate of complications was 7-28% for pneumothorax, 0.3-1.4% for bleeding, and 0.1% for death (14, 15). There is no definite standardization in some issues such as cooling agent of cryobiopsy, freezing time, and the distance of parenchyma from the pleura. The reported rates of diagnosis and complications vary, and new prospective studies are needed for determining the role of the procedure in the differential diagnosis (16, 17).

Another method, endobronchial ultrasonography (EBUS) helps increase the rate of bronchoscopic diagnosis, particularly in sarcoidosis. In a study comparing EBUS-guided transbronchial needle aspiration with TBB, the diagnostic value of EBUS was found to be higher (18). In our center, EBUS has been used more often for the last 2 years. In the clinical practice of patients with the pre-diagnosis of sarcoidosis, TBB and BAL with FOB are performed primarily, and EBUS is applied when a diagnosis cannot be established. We suggest that further studies with larger series should be conducted for the identification of diagnostic algorithm in patients with the pre-diagnosis of sarcoidosis.

Because of the complications of TBB, the rate of pneumothorax was reported to be 6% and the rate of bleeding to be 0-4% in the series conducted in our country (6, 7). In a series on 173 cases, the rate of complications, the most common ones of which were bleeding and pneumothorax, was found to be 6.8% (19). In a current review, the rate of pneumothorax related to the procedure was reported to be 0.2-5.5% and chest tube drainage was needed in about half of them (20). Of our patients, pneumothorax was observed in 6% and non-massive bleeding was observed in 3%. One patient (0.3%) had respiratory failure.

The primary limitation of the study is its being a retrospective and single-centered study. Because of its retrospective design, patients' detailed history and the existence of comorbid diseases were not recorded. Extensive classification of radiological findings was not performed. They were only grouped as localized and diffuse.

The strengths of the study involve high number of patients and the implementation of the procedures by an experienced team.

In conclusion, TBB is an easily applicable procedure having high diagnostic value in certain disease groups and low mortality and morbidity. Its diagnostic success is higher in non-localized lesions and non-fibrotic diseases. When combined with BAL and other bronchoscopic processes, the need for advanced invasive diagnostic methods is reduced.

Ethics Committee Approval: Due to the retrospective design of the study, ethic committee approval was not taken. Local Academic Committee Approval was taken from Süreyyapaşa Chest Diseases and Thoracic Surgery Training and Research Hospital.

Informed Consent: Due to the retrospective design of the study, informed consent was not taken.

Peer-review: Externally peer-reviewed.

Conflict of Interest: No conflict of interest was declared by the authors.

Financial Disclosure: The authors declared that this study has received no financial support.

REFERENCES

- Levin DC, Wicks AB, Ellis JH. Transbronchial biopsy via flexible fiberoptic bronchoscope. *Am Review Resp Dis* 1974; 110: 4-12.
- Casoni G, Gurioli C, Poletti V. Transbronchial pulmonary biopsies. *Monaldi Arch Chest Dis* 2011; 75: 39-41.
- A.C. Mehta and P. Jain (eds.), *Interventional Bronchoscopy: A Clinical Guide, Respiratory Medicine* 10, 15 DOI 10.1007/978-1-62703-395-4_2, © Springer Science+Business Media New York 2013. In: *Transbronchial lung biopsy* Jain P. Page:15-44.
- Tukey MH, O'Connor GTO, Wiener RS. Population based trends in bronchoscopy and transbronchial lung biopsy from 2000 to 2009. DOI: 10.1164/ajrccm-conference.2012.185.1_MeetingAbstracts.A449310.1164/ajrccm-conference.2012.185.1_MeetingAbstracts.A4493.
- de Fenoyl O, Capron F, Lebeau B, Rochemaure J. Transbronchial biopsy without fluoroscopy: A five-year experience in out-patients. *Thorax* 1989; 44: 956-9. [CrossRef]
- Çetinkaya E, Yıldız P, Kadakal F, Çıkrıkçıoğlu U, Tekin A, Soysal F, et al. The diagnostic value of transbronchial biopsy at lung disease. *Tub Toraks* 2001; 49: 221-4.
- Uçar E, Tozkoparan E, Deniz Ö, Gümüş S, Özcan A, Bilgiç H, et al. Diagnostic value of transbronchial biopsy: analysis of 104 cases. *Gülhane TD* 2005; 47: 187-9.
- Descombes E, Gardiol D, Leuenberger P. Transbronchial lung biopsy: An analysis of 530 cases with reference to the number of samples. *Monaldi Arch Chest Dis* 1997; 52: 324-9.
- Hernandez Borge J, Alfageme Michavila I, Munoz Mendez J, Villagomez Cerrato R, Campos Rodriguez F, Pena Grinan N. Factors related to diagnostic yield and complications of transbronchial biopsy. *Arch Bronconeumol* 1998; 34: 133-41.
- Aka Aktürk Ü, Salepçi B, Çağlayan B, Fidan A, Turan D, Torun E, et al. The role of bronchoscopy in diagnosis of sarcoidosis. *Eurasian J Pulmonol* 2011; 13: 140-5. [CrossRef]
- Tomassetti S, Cavazza A, Colby TV, Ryu JH, Nanni O, Scarpi E, et al. Transbronchial biopsy is useful in predicting UIP pattern. *Resp Research* 2012; 13: 96. [CrossRef]
- Goldstein RA, Rohatgi PK, Bergofsky EH, Block ER, Daniele RP, Dantzker DR, et al. Clinical role of bronchoalveolar lavage in adults with pulmonary disease. *Am Rev Respir Dis* 1990; 142: 481-6. [CrossRef]
- Barut F, Özdamar ŞO, Bahadır B, Doğan Gün B, Bektaş S, Çolak S, et al. Comparison of the diagnostic results of bronchoalveolar lavage with synchronous transbronchial biopsies. *Türkiye Klinikleri J Med Sci* 2007; 27: 179-83.
- Casoni GL, Tomassetti S, Cavazza A, Colby TV, Dubini A, Ryu JH, et al. Transbronchial lung cryobiopsy in the diagnosis of fibrotic interstitial lung diseases. *Plos One* 2014; 9: e86716. [CrossRef]
- Dhooria S, Sehgal IS, Aggarwal AN, Behera D, Agarwal R. Diagnostic yield and safety of cryoprobe transbronchial lung biopsy in diffuse parenchymal lung diseases: systematic review and meta-analysis. *Respir Care* 2016; 61: 700-12. [CrossRef]
- Torrego A, Shah PL. Transbronchial lung cryobiopsy: new options for a new reality. *Respiration* 2016; 91: 204-5. [CrossRef]
- Tanrıverdi E, Çetinkaya E. Invasive diagnostic methods in interstitial lung disease. *Guncelghs* 2014; 2: 320-6.
- Oki M, Saka H, Kitagawa C, Kogure Y, Murata Y, Ichihara S, et al. Prospective study of endobronchial ultrasound-guided transbronchial needle aspiration of lymph nodes versus transbronchial lung biopsy of lung tissue for diagnosis of sarcoidosis. *J Thorac Cardiovasc Surg* 2012; 143: 1342-9. [CrossRef]
- Pue CA, Pacht ER. Complications of fiberoptic bronchoscopy at a university hospital. *Chest* 1995; 107: 430-2. [CrossRef]
- Huang Y, Huang H, Li Q, Browning RF, Parrish S, Turner Jr JF, et al. Transbronchial lung biopsy and pneumothorax. *J Thorac Dis* 2014; 6: 443-7.