

Radyoterapi Sonrası Mandibuler Kondilde Yetmezlik Kırığı:

Vaka Raporu

Insufficiency Fracture of the Mandibular Condyle After Radiotherapy:

Case report

Banu Özveri Koyuncu¹, Servet Kandemir², Cemal Akay¹, Sevtap Günbay¹

¹Ege Üniversitesi Dişhekimliği Fakültesi, Ağız Diş Çene Cerrahisi Anabilim Dalı, İzmir

²Ege Üniversitesi Dişhekimliği Fakültesi Oral Diagnoz Ve Radyoloji Anabilim Dalı, İzmir

Özet

Radyasyona bağlı mikrovasküler zarar kemikte hipoksi ve bunun sonucunda da nekroz veya kırığa neden olabilmektedir. Yetmezlik (spontan) kırıklar nadirdir ve radyoterapi sonucunda meydana gelir. Bu kırık tipi, hem klinik hem de radyografik olarak metastazik hastalıklarla karışabilir. Bu kırık çeşidinin bilinmesi gereksiz araştırma ve tedavilerin yapılmasını önlemiş olur. Radyoterapiden sonra, bu tip komplikasyonları engellemek için rutin radyolojik ve klinik takip gereklidir. Bu konuda diş hekimi büyük role sahiptir. Vaka raporunda, erkek hastada radyoterapi sonrası mandibuler kondilde meydana gelen kırık sunulmaktadır.

Anahtar Kelimeler: Radyoterapi, kırık, kemik

Abstract

Radiation-induced microvascular damage results in bony hypoxia, which can result in necrosis or fracture. Insufficiency (spontaneous) fractures are uncommon and they are observed mostly in postradiotherapy period. These fractures can be confused both clinically and radiographically with metastatic diseases. Increased awareness of these fractures may help to avoid unnecessary investigations and treatments. After the radiotherapy treatment, the routine radiological and clinical follow-ups is mandatory to prevent such complications, and the dentist has a fundamental role in this context. In this article, we present a case of fracture of the condyle of the mandible following radiotherapy in a man.

Key words: Radiotherapy, fracture, bone

Introduction

Radiotherapy, alone or associated with surgery or chemotherapy, produces a significant increase in cure rates for many malignancies of the head and neck region. However, high doses of radiation in large areas may result in several undesired complications that manifest during or after the completion of therapy. Irradiation of bone kills the cells that are responsible for bone maintenance and remodeling that renders the irradiated bone brittle and prone to injury. Post-irradiation bony injuries include mandibular osteoradionecrosis (MORN), pelvic insufficiency (spontaneous) fracture, hip fracture, fracture of long bones, rib fracture, and pediatric growth abnormalities.¹ Osteoradionecrosis is defined as an area of exposed necrotic bone in one or more locations of the maxillary or mandibular alveolar

process, with failure to heal during at least three months. ORN can develop spontaneously in one-third of all cases, but usually manifests after tooth extraction, after oral surgery, or due to irritation caused by poorly fitting dentures. In most cases the condition is chronic, progresses gradually and becomes more extensive and painful.^{2,3} Marx³ defined ORN as resulting from the effects of RT, i.e., hypovascularization, hypoxia and hypocellularity. These circumstances in turn adversely affecting tissue repair capacity. Insufficiency fracture occurs as a result of normal stresses on weakened brittle bone.⁴ Risk factors for “insufficiency fracture” following irradiation are similar to the risk factors for osteoporotic fracture. A proposed mechanism for these atypical fractures is inadequate osteoclast activity which impairs bone remodeling and repair of

normally occurring microdamage.⁵

At present a fibro-atrophic mechanism has been suggested, characterized by alterations in bone metabolism and the formation of free radicals, inflammation and microvascular thrombosis that evolve towards necrosis of the affected tissues.⁶ In this report, a case of mandibular condyle fracture after radiotherapy of the nasopharyngeal area in a man is described. The necessity of awareness of this type of fracture and the importance of consultation with maxillofacial surgeon for the patients whom are treated with radiotherapy are discussed.

Case report

A 62-year-old male presented to the Ege University,

School of Dentistry for comprehensive dental care. During the clinical examination, trismus was determined. So, intraoral examination was difficult because of the limitation in the jaw opening. Clinically, attrition due to the bruxism at the teeth was observed. The examination identified several teeth to be nonrestorable due to caries. His lower right second premolar, first molar, and lower left second premolar, second molar, and third molar teeth had profound caries. There was also a radix of upper left third molar tooth. In radiological examination, the panoramic radiograph revealed right subcondylar non-union fracture (Figure 1).

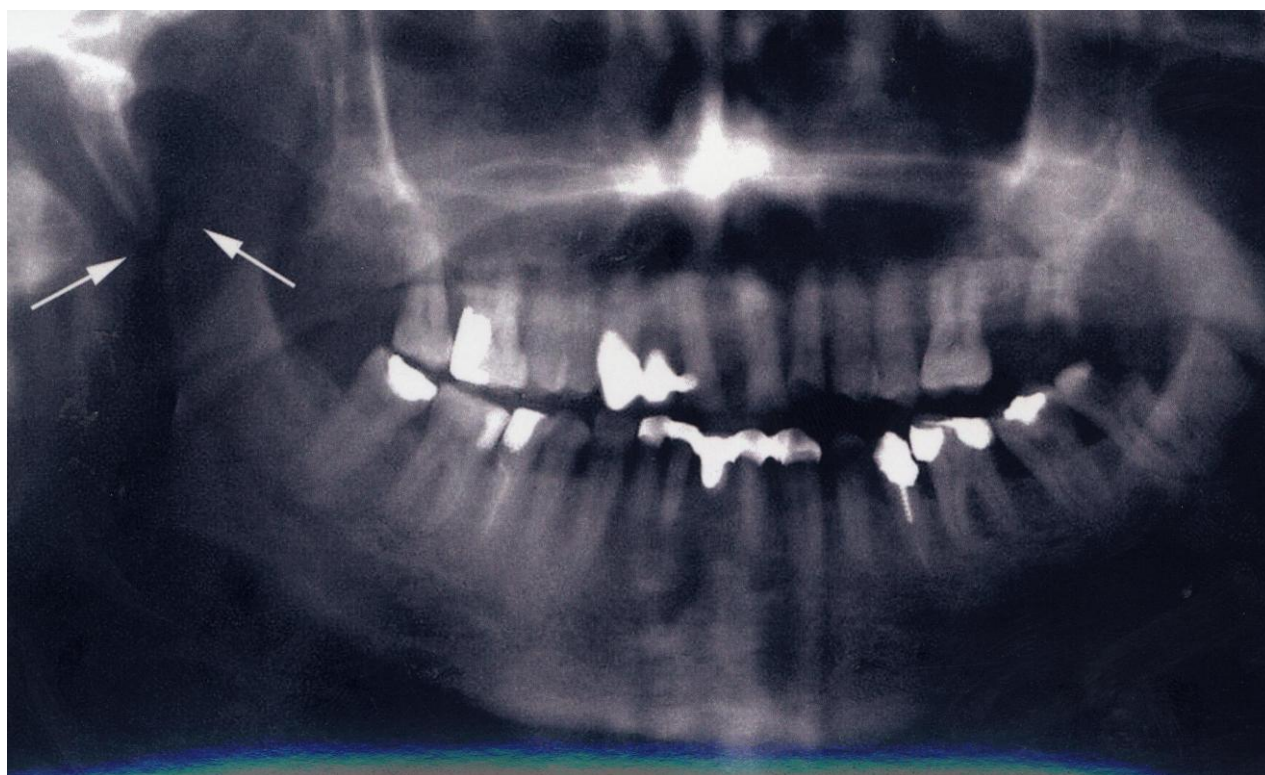


Figure 1. Panoramic radiograph showing fracture of right temporomandibular condyle. (arrows)

The patient displayed an 18 mm interincisal opening. Right lateral excursive movement measured 5 mm while the left lateral excursion was approximately 3 mm. Protrusive movement measured as 5 mm.

Past History

He was operated because of a nasopharyngeal carcinoma 11 years ago. Postoperative radiation therapy was given for the nasopharyngeal and was treated with 70 Gy. Three years after the first treatment, local recurrence occurred and nasopharyngeal area was treated again with 60 Gy. He was reviewed regularly by the

Oncology Department, and remained asymptomatic. He was surprised when we told him that he had a condyle fracture. We asked him about any significant trauma but the answer was negative. Based on the patient's medical history, both the clinical and radiographic examinations, the diagnosis of insufficiency fracture (spontaneous fracture) of mandibular condyle due to the radiotherapy was made. The patient was referred to his physician for consultation before teeth extractions. The physician was also informed about the non-union of the condylar fracture. Epinephrine-free local anesthetic was

recommended as well as pre- and postoperative prophylactic antibiotic coverage: lincomycin (Lincocin ® Eczacıbaşı Pharmaceuticals, Turkey 600 mg, 2 times) per a day, intramuscular for 10 days by the physician. The patient's treatment was planned to be done conservatively because his physician did not recommend any surgical therapy for the fracture. During the extraction of molar teeth, to minimize the trauma at the bone, they were sectioned into single-rooted teeth to facilitate removal of roots. The following instructions were given to the patient; he was advised go on a soft diet and muscle relaxant drugs has been given to the patient regarding a medication regimen. The patient presented for a recall visit after three months and we observed that the maximum interincisal opening was approximately 21 mm. The patient was invited for follow-ups. The mandibular condyle fracture exhibited no signs until his subsequent death due to metastasis of the tumour eighteen months after his first visit to our department.

Discussion

The insufficiency fractures (spontaneous fracture) have been observed after radiation exposure and also described in several situations with no history of prior trauma: the postmenopausal state, subsequent to treatment with high dose corticosteroids.⁷ Patients who develop mandibular osteoradionecrosis late (>36 months) after radiotherapy, and those with more extensive mandibular osteoradionecrosis (including fracture and/or fistula) are more likely to fail conservative therapy, thus it requires surgery. The time to develop a fracture from radiotherapy is between 1 and 190 months.⁸ The patient reported a characteristic cracking sound while eating 3 months ago. (128th month after the initial radiotherapy) Our patient was asymptomatic and had no prior history of significant trauma. Special types of injuries to temporomandibular joint include pathologic and stress. Pathologic fracture due to metastasis should be included in the differential diagnosis when a radiotherapy patient presents with a condyle fracture as in this case report. Characteristic feature of a metastatic fracture is osteolysis or osteosclerosis in the radiological evaluation.⁹ In our patient, neither osteolysis nor osteosclerosis was observed at the fracture area. Therefore, the diagnosis of insufficiency fracture of condyle due to the radiotherapy was made. After radiation treatment of nasopharyngeal tumours, tumours in the retromolar and the posterior palate areas, gradual development of trismus occurs. During treatment of lesions in these areas, the

temporomandibular joint and the muscles of mastication are within the field of radiation, and gradual fibrosing and sclerosing take place.¹⁰ In this case, radiotherapy which was given 11 years ago, induced fibrosing and sclerosing of the masticatory muscles. So, trismus has been observed as a complication of radiotherapy. Mandibular osteoradionecrosis continues to be a clinical problem especially when doses to the mandible significantly exceed 60 Gy. If there are predisposing risk factors, e.g., poor dentition and poor likelihood of post-radiotherapy dental care, or a large volume of irradiated mandible, the risk of mandibular osteoradionecrosis will be increased for a given dose.⁸ We think that in our case, the causative factor in occurring fracture was an external factor. This was the dosage of the radiotherapy which affected the temporomandibular joint area. Atrophy of bone is dose related and occurs when doses exceed 40Gy.⁸ In our patient, the total radiation dosage was 130 Gy. This was an important factor that the resistance of the patient's bone to fracture was further decreased by radiotherapy. The result of this causative factor was a weakened bony structure. According to us, the normal activity of musculus pterygiodeus lateralis stressed the mandibular condyle of the patient and a fracture has been occurred at the muscle sticking location. Factors that can influence fractures are the forces exerted by the masticatory muscles, the occlusal loading pattern and the osseous anatomy. So, it is surmised that nocturnal bruxist forces were responsible for the spontaneous fractures.¹¹ In our opinion, to prevent bruxism, a repositioning splint can be made for the patient. At the beginning, if a radiotherapy patient is consulted to a dental profession for examination of temporomandibular joint, perhaps the existing bruxism in the patient can be diagnosed. Fractures can be symptomatic or not.¹² According to us, temporomandibular joint dysfunction syndrome pain may also be confused with fracture of mandibular condyle, in symptomatic patients. When temporomandibular joint is within the field of radiotherapy, temporomandibular joint pain must be evaluated carefully and should be suspected of a fracture. Because the treatment of head and neck cancer patients with high dosage radiotherapy leads to osteoradionecrosis, any surgical therapy in this field may result with complication. Even without surgical procedure, complications such as spontaneous fractures may occur. So, the radiotherapy patients must be examined clinically and radiographically with routine follow-ups.

References

1. Engleman MA, Woloschak G, Small W. Radiation-Induced Skeletal Injury. *Cancer Treatment and Research* 2006; 128: 155-169.
2. McLeod NM, Bater MC, Brennan PA. Management of patients at risk of osteoradionecrosis: results of survey of dentists and oral & maxillofacial surgery units in the United Kingdom, and suggestions for best practice. *Br J Oral Maxillofac Surg* 2010; 48:301-4.
3. Marx RE. Osteoradionecrosis: a new concept of its pathophysiology. *J Oral Maxillofac Surg* 1983;41:283-8.
4. Bliss P, Parsons CA, Blake PR, et al. Incidence and possible etiological factors in the development of pelvic insufficiency fractures following radical radiotherapy. *Br J Radiol* 1996; 69:548-554.
5. Neviasser AS, Lane JM, Lenart BA, Edobor-Osula F, Lorich DG. Low-energy femoral shaft fractures associated with alendronate use. *J Orthop Trauma* 2008; 22:346-50.
6. Chrcanovic BR, Reher P, Sousa AA, Harris M. Osteoradionecrosis of the jaws-a current overview--part 1: Physiopathology and risk and predisposing factors. *Oral Maxillofac Surg* 2010;14:3-16.
7. Daffner RH, Pavlov H: Stress fractures:current concepts. *AJR* 1992 ;159:245-52.
8. Notani K, Yamazaki Y, Kitada H, et al. Management of mandibular osteoradionecrosis and the method of radiotherapy. *Head Neck* 2003; 25:181-186.
9. Resnick D, Goergen T. Section XV. *Traumatic Diseases*, Chapter 56 Physical Injury: Concepts and Terminology. In: Resnick D, Kransdorf MJ. Bone and joint imaging. Philadelphia, Elsevier Saunders, 2005.
10. 10- Carl W: *Cancer and the Oral Cavity*, Chicago, Quintessence, p.p.167, 1986.
11. 11- Libersa P, Roze D, Dumousseau T: Spontaneous mandibular fracture in a partially edentulous patient: case report. *J Can Dent Assoc* 2003; 69:428-30.
12. 12- Wyatt JP, Illingworth R, Graham C. *Major trauma*. Oxford Handbook of Emergency Medicine, Chapter 8, 2006.

Yazışma Adresi:

Doç. Dr. Banu Özveri Koyuncu
Ege Üniversitesi Dış Hekimliği Fakültesi Ağız, Diş ve Çene
Cerrahisi Anabilim Dalı Bornova İzmir Türkiye
Tel : +90 232 3881108; +90 555 2497777
E-posta: banuozverikoyuncu@yahoo.com