

Comparison of Maxillary Sinus Volumes in Individuals with Different Dentofacial Skeletal Patterns: A Cone-Beam Computed Tomography Study

Farklı Dentofasiyal İskelet Paternine Sahip Bireylerde Maksiller Sinüs Hacimlerinin Karşılaştırılması: Konik Işınlı Bilgisayarlı Tomografi Çalışması

Güldane MAGAT ¹	https://orcid.org/0000-0003-4418-174X
Melek TASSOKER ¹	https://orcid.org/0000-0003-2062-5713
Bekir LALE ²	https://orcid.org/0000-0002-3109-5300
Melike GÜLEÇ ³	https://orcid.org/0000-0002-5188-2360
Sevgi OZCAN ⁴	https://orcid.org/0000-0003-4601-5032
Kaan ORHAN ⁵	https://orcid.org/0000-0001-6768-0176

¹ Necmettin Erbakan Üniversitesi Diş Hekimliği Fakültesi

² Özel Muayenehane

³ Karamanoğlu Mehmetbey Üniversitesi Ahmet Keleşoğlu Diş Hekimliği Fakültesi

⁴ İzmir Katip Çelebi Üniversitesi Diş Hekimliği Fakültesi

⁵ Ankara Üniversitesi Diş Hekimliği Fakültesi

Atıf/Citation: Magat, G., Taşsöker, M., Lale, B., Güleç, M., Özcan, S., Orhan, K., (2023). Comparison of Maxillary Sinus Volumes in Individuals with Different Dentofacial Skeletal Patterns: A Cone-Beam Computed Tomography Study. Ege Üniversitesi Diş Hekimliği Fakültesi Dergisi, 2023; 44_1, 17-23.

Doi:10.5505/eudfd.2023.75046

ABSTRACT

Introduction: In dentistry, the maxillary sinus is a paramount anatomical formation due to its proximity to teeth. The aim of this study is to evaluate the change of the maxillary sinus volumes (MSV) in accordance with three different types of skeletal malocclusions, by using digital three-dimensional (3D) modeling.

Methods: Overall, 158 cone-beam computed tomography (CBCT) images of 79 patients were analyzed. The MSV was measured using the MIMICS 19.0 software (Materialise HQ Technologielaan, Leuven, Belgium). Cephalometric angular measurement (ANB) was used to evaluate the skeletal patterns (Angle class I-II-III). The angle between Sella-Nasion and point A (SNA) was also measured.

Results: The average volume of the right maxillary sinus was 12.450 cm³, while the left was 12.586 cm³. No significant relationships between MSV, age, gender, and SNA values or between the left and the right sinus were found ($p>0.05$). Also, MSV did not show any meaningful differences in accordance with the various skeletal types ($p>0.05$).

Discussion and Conclusion: Age, gender, malocclusion classes, and SNA values did not provide any substantial alteration on the volume of the maxillary sinus. The outcomes of this study may be beneficial in the assessment of the maxillary sinus when outlining operations such as orthodontic mini screw implantation and orthognathic surgery.

Keywords: CBCT, maxillary sinus volume, skeletal malocclusion types, age, gender

ÖZ

Giriş ve Amaç: Diş hekimliğinde maksiller sinüs, dişlere yakınlığı nedeniyle çok önemli bir anatomik oluşumdur. Bu çalışmanın amacı, dijital üç boyutlu (3D) modelleme kullanarak, maksiller sinüs hacimlerinin (MSH) üç farklı iskelet maloklüzyonuna göre değişimini değerlendirmektir.

Yöntem ve Gereçler: 79 hastanın 158 konik ışınli bilgisayarlı tomografi (KIBT) görüntüsü incelendi. MSH, MIMICS 19.0 yazılımı (Materialise HQ Technologielaan, Leuven, Belçika) kullanılarak ölçüldü. İskeletsel yapıyı (Açı sınıfı I-II-III) değerlendirmek için sefalometrik açısal ölçüm (ANB) kullanıldı. Sella-Nasion ile A noktası arasındaki açı (SNA) da ölçüldü.

Bulgular: Sağ maksiller sinüsün ortalama hacmi 12.450 cm³, sol ise 12.586 cm³ idi. MSH, yaş, cinsiyet ve SNA değerleri arasında veya sol ve sağ sinüs arasında anlamlı ilişki bulunamadı ($p>0.05$). Ayrıca MSH, çeşitli iskelet tiplerine göre anlamlı bir farklılık göstermedi ($p>0.05$).

Tartışma ve Sonuç: Yaş, cinsiyet, maloklüzyon sınıfları ve SNA değerleri maksiller sinüs hacminde önemli bir değişiklik sağlamadı. Bu çalışmanın sonuçları, ortodontik mini vida implantasyonu ve ortognatik cerrahi gibi operasyonları ana hatlarıyla belirtirken maksiller sinüsün değerlendirilmesinde faydalı olabilir.

Anahtar Kelimeler: KIBT, maksiller sinüs hacmi, iskeletsel maloklüzyon tipleri, yaş, cinsiyet

Sorumlu yazar/Corresponding author*: gul_dent@hotmail.com

Başvuru Tarihi/Received Date: 11.08.2021

Kabul Tarihi/Accepted Date: 08.12.2021

INTRODUCTION

Playing a critical aspect in the development of facial contours, the maxillary sinus is the biggest and the first to develop among the four paranasal sinuses.¹ The formation of the maxillary sinus begins in the third month of fetal development. Pneumatization of the sinus continues until the ages of 15-18.² The average MSV is 14-18 cm³ in adults, which decreases with age nonspecific to gender after the maximum growth period. MSV could be altered as a result of pathological conditions such as systemic and neoplastic diseases.³ Changes could also occur with rapid maxillary expansion following orthodontic treatment or the use of a facemask.⁴

Formed by the alveolar process of the maxilla, the maxillary sinuses have a tight anatomical relationship with the roots of the molar and premolar teeth, which could lead to the pneumatization of the sinus following the extraction of these teeth.⁵ Forcing the medialization of the second molar in the absence of the first is challenging because of the roots of the second molar being in close proximity with the cortical sinus wall.⁶ The region of the maxillary sinus is imperative in the placement of anchorage devices. For maxillary molar anchorage, mini-screws are implanted from the buccal side into the interalveolar septum between the maxillary first molar and second premolar.⁶ This makes the detailed evaluation of the size and morphological traits of the maxillary sinus critical when it comes to dealing with problems associated with different types of malocclusions.⁶

In academic literature, dry and cadaveric skulls, lateral cephalograms, pantomograms, CTs, CBCTs, and MRIs were used to evaluate MSV. First made known in 1998⁷, CBCT, has become favored in the therapeutic and diagnostic planning in dentistry. As a result of well-defined images and a more conservative dosage of radiation and processing time, CBCT is favored in comparison to CT; which is thought to be the principal method of paranasal sinus imaging. Also, CT images have 3-D cross-sectional imaging, which eliminates images containing distorted and super positional teeth.⁸

With respect to the maxillary sinuses being closely associated with the skeletal structure of the maxilla; we proposed that skeletal malocclusions can cause alterations to sinus formation⁹, which propagated our research objective of analyzing the correlation between 3 variant skeletal malocclusions and MSV by using 3-D modeling.

METHODS

This study has the approval of The Ethics Board Committee of XXXXX University, Faculty of Dentistry (decision no 2019/05).

Sample Selection

The selected were patients requesting orthodontic assessment that were admitted to Oral and Maxillofacial

Radiology Clinic, Faculty of Dentistry between the dates of September 2014 and April 2019, who had undergone both CBCT and lateral cephalometric imaging because of diagnostic and operative procedures. From the chosen, 79 patients (26 males, 53 females) with an average age of 17.29 ± 3.96 years (ranging from 8-36 years) were selected in accordance with the inclusion/exclusion criteria. Our study included CBCT images in which the boundaries of the maxillary sinus region were clearly observed in 3D within the field of view (FOV) area.

Our principles for exclusion were: CBCTs of patients who had received surgery or grafting of the maxillary sinus, pathologies like cysts or tumors, acute/chronic sinusitis, craniofacial deformities, ≥ 3 mm mucosal swelling, nasal or sinus polyposis, and those missing teeth (excluding maxillary third molars) or tooth germs (patients with partial permanent dentition).

The gender and age of those involved in this project were gathered from their medical records. Images that did not adhere to the aforementioned selection criteria were disregarded from the study. A posthoc power-analysis software computed the statistical power of the sample size (100%), based on a previous studies¹⁸ value for MSV which was 16.74 ± 5.28 cm³ with an alpha of 0.05.

Data acquisition of digital lateral cephalometric radiography and CBCT

Recorded in JPEG format, and under certain specifications; tube voltage of 65-90 kV, tube current of 5-10 mA, and exposure time of 4.9 seconds, the digital lateral cephalograms were obtained using a conventional method with J.MORITA machine (2D Veraviewepocs®, MFG Corp., Kyoto, Japan),

However, CBCT images were obtained in the standard sitting position using the same device (3D Accuitomo CBCT instrument (J Morita Manufacturing Corp, Kyoto, Japan 17.5-second exposure, 90 kV voltage, 5 mA current, and 140 x 100 mm FOV). Patients were asked to bite with maximum intercuspation and not move their heads or tongues during scanning. All images had a full field of view so that the maxillary sinus was fully observed. To compute MSV, images were changed into DICOM format obtained from 0.25 mm thick axial slices.

Measurements

All the measurements were executed by a sole observer (B.L). In order to assess witness reliability, the same person executed the measurements for another time following a 4-week gap.

Adobe Photoshop CS6 (Adobe, San Jose, CA) was used for the analysis of angles SNA (angle between the maxilla and cranial base (Figure 1)) and ANB. Angle ANB provides insight into the categorization of individuals according to their longitudinal dentofacial skeletal pattern; class I (ANB; 0-4°), class II (ANB;> 4°) and class III (ANB; <0°) (Figure 1).¹⁹

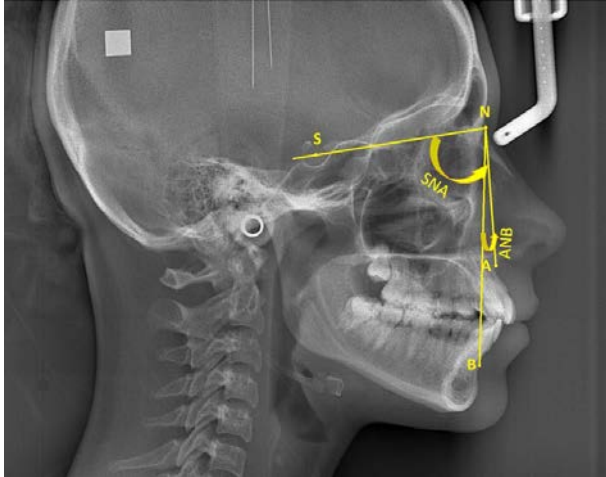


Figure 1. Skeletal cephalometric measurements and landmarks. SNA: angle between the maxilla and the cranial base. ANB: angle between the maxilla and the mandible. A, Subspinal: deepest anterior point at the concavity of the anterior maxilla; B, Supramental: deepest anterior point in the concavity of the anterior mandible. S, Sella: midpoint of the hypophyseal fossa. N, Nasion: anterior point at the frontonasal suture.

To compute the MSVs, CBCTs were relayed onto the MIMICS 19.0 software (Materialise HQ Technologielaan, Leuven, Belgium); for which the left and right MSVs were assessed independently for each person. Data from CBCT scans were converted to DICOM files and segmented by a single observer (B.L.) using manual thresholds. Thresholding was restricted to a min. of -1024 HU and a max. of 526 HU.¹⁰ By applying the software's "edit mask" tool¹¹, the maxillary sinus was isolated in accordance to the bone's framework and narrowest region of the ostium between the uncinate process and infundibulum. Then, by using the segmentation tools, the contact with the external space was blocked. By using the "region growing" tool, the removal of free pixels and segmental division generated by thresholding multiple objects were executed. Finally, by using the software's "calculate 3D" tool, the MSV values were immediately computed (Figure 2).

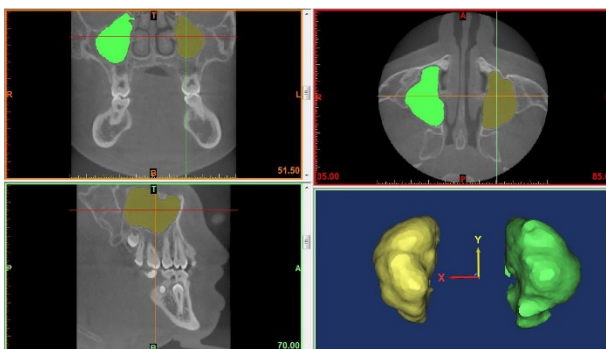


Figure 2. Three-dimensional reconstruction of the maxillary sinuses.

Statistical Analysis

For statistical analysis, the SPSS statistical software version 21.0 (SPSS, Chicago, IL, USA) was used. Intra-observer reliability was reinforced using Cronbach's alpha coefficients. Using the Kolmogorov Smirnov test, the suitability of the framework in comparison to regular distribution was assessed. With respect to the statistics not being normally distributed, Mann-Whitney-U tests were used to analyze if the measurements showed any variation with gender. The distinction between the left and right MSVs was made with the Wilcoxon sign test. With the Kruskal Wallis analysis, average MSVs were compared in accordance with the skeletal malocclusion variations. Correlation between measurements and age were examined by Spearman's Correlation Test. To discover whether there is a distinction between gender and malocclusion variations, the Chi-Square test was used. P values less than 0.05 were regarded to show statistical significance.

RESULTS

For intra-observer dependability, Cronbach's α values ranged between 0.90 and 0.96 for angle ANB, SNA, and the left and right MSVs, which results in very adequate reproducibility for each factor.

Sample distribution in regard to skeletal malocclusion variations in both genders can be seen in **Table 1**. No meaningful distinctions across genders in regard to skeletal malocclusion types can be found. For patients with Class I, the mean age was 17.29 ± 3.11 years, Class II was 17.20 ± 3.48 years, and finally Class III was 17.39 ± 5.37 years. There was no relationship between skeletal malocclusions and age ($p > 0.05$).

The average MSV was 12.450 cm^3 , and 12.586 cm^3 , for the right and left sinus respectively (Table 2). There was no significant difference between right and left MSV values ($p > 0.05$) (Table 2). Although the males' left and right MSV values were higher than females, no statistically meaningful were observed ($p > 0.05$) (Table 2). In Table 3, the average values of both MSVs in regard to the skeletal malocclusion variation were displayed. Skeletal malocclusions were showed no significant statistical differences to MSVs ($p > 0.05$).

The mean SNA value was $80.6^\circ \pm 3.95^\circ$ ($80.72^\circ \pm 3.75^\circ$ and $80.33^\circ \pm 4.38^\circ$ for females and males, respectively). There was no correlation between SNA value and age, and SNA value MSV ($p > 0.05$). While the mean SNA values for Class I, Class II and Class III were $81.09^\circ \pm 4.34^\circ$, $81.87^\circ \pm 3.72^\circ$, $78.41^\circ \pm 2.82^\circ$ respectively. It was determined that the SNA value did not differ significantly according to gender and skeletal classification ($p > 0.05$).

Table 1. Distribution of sample according to gender and skeletal malocclusion types

		Skeletal Malocclusion Types			Total	p value
		Class I	Class II	Class III		
Gender	Female	14	24	15	53	0.057
	Male	13	5	8	26	
	Total	27	29	23	79	

Table 2. The descriptive statistic of maxillary sinus volumes according to gender and presented as number (N) and cm³

	Gender	N	Minimum	Maximum	Mean	Std. Deviation	p value
Right Volume	Female	53	3.912	20.862	11.972	3.615	0.218
	Male	26	5.857	23.994	13.424	4.418	
Left Volume	Female	53	4.239	20.208	12.066	3.619	0.214
	Male	26	2.836	26.139	13.646	5.332	
Total	Right Volume	79	3.912	23.994	12.450	3.930	0.223
	Left volume	79	2.836	26.139	12.586	4.289	

Table 3. The descriptive statistic of maxillary sinus volumes according to skeletal malocclusion types and presented as number (N) and cm³

	Skeletal Malocclusion Types	N	Minimum	Maximum	Mean	Std. Deviation	P value
Right Volume	Class I	27	3.912	21.581	11.720	4.567	0.069
	Class II	29	5.845	17.116	11.872	3.216	
	Class III	23	7.911	23.994	14.034	3.636	
Left Volume	Class I	27	2.836	21.188	11.964	4.960	0.258
	Class II	29	7.394	18.545	12.183	2.979	
	Class III	23	4.626	26.139	13.826	4.750	

DISCUSSION

The characteristics of the maxillary sinus can be variant because of adjacent maxillary teeth; it can be impacted by differences in upper jaw anatomy and malocclusions.¹² There are existing researches that analyze MSV and how it can change with age, gender, racial background, nasal septum deviation, tooth position, orthodontic treatment, sinus disorders, rapid maxillary expansion, and the patient's state of dentition.¹¹ In addition to these studies, a study conducted in 2015¹³ found that individuals with unilateral or bilateral cleft palate and lip had smaller MSVs. Being aware of the sinus size and position is critical when the patient requires a significant amount of total maxillary impaction.²³ Therefore, in our study, we investigated that changes in the sagittal structure of the dentofacial skeleton may affect the maxillary sinuses.

Various methods have been evaluated in the literature to evaluate the pneumatization of the paranasal sinuses. Anatomical calculations attained from cadavers will

often lead to imprecise and misguided research results because of significant soft tissue loss. It has been stated that the most accurate and reliable method is the segmentation method when evaluating the volume of the sinuses.¹¹ Therefore, in our study, we evaluated the segmentation method with a 3D software tool (MIMICS).

The right and left maxillary sinuses showed an average volume of 12.450 cm³ and 12.586 cm³, respectively. There are studies in the literature reporting that the volume of MS varies between 8.6 cm³ and 32.9 cm³.³ MSVs close to our results have also been reported in previous studies.¹ On the other hand, some studies have reported MSVs higher than the volumes obtained with this study.^{14, 15} Although it has been reported that MS pneumatization is completed between the ages of 12-14¹⁴, Jun et al.¹ reported that the development of MS continued in the third decade in males and in the second decade in females. Genetics, environmental factors, and infections play a key role in the formation of paranasal sinuses. In a study involving the CT radiographs of

Japanese subjects, the volumes of the maxillary sinuses were assessed and determined to be an average of 23.6 cm³ on the right and 20.9 cm³ on the left side, exceeding the volumes of other races.¹⁶

The results of studies in the literature evaluating the difference between right and left MSVs vary.^{1, 11, 17} Aksoy¹⁸ and Demir et al.¹⁹ found no significant difference between right and left MSVs, but reported that MSV was higher in males. Prabhat et al.²⁰ reported that MSV was significantly higher in males than females, and the right MSV was also larger than the left MSV. On the other hand, Arijji et al.¹⁷ also stated that they did not find a significant difference between right and left MSVs or between genders. Recently, Shrestha et al.²¹ evaluated the MSVs of 50 women and 50 men aged 21 to 64 years and found that males' MSVs were statistically higher than females. Jun et al.¹ reported that MSV was significantly higher in males than females during the developmental period, while there was no significant difference between males and females in the same age groups after development was completed. In a study conducted by Okşayan et al.²², the right and left MSV values were found to be 11.47 ± 4.09 cm³ and 11.79 ± 4.50 cm³ in females, respectively, and 16.60 ± 3.58 cm³ and 16.58 ± 4.62 cm³ in males. Asantogrol et al.²³ reported that the right MSV was significantly higher in males than in females, and they found no difference on the left side. In our study, there were no difference between right and left MSVs according to gender. The differences in volume were suggested to be a consequence of varying height-weight proportions and unique methods in volume assessment.²⁴ Furthermore, the thesis did not indicate potentially missing teeth. Although research has generally suggested that the right and left MSVs of the same person exhibit no significant variations^{11, 17}, they can potentially be distinct. The possible differences in right and left side dentition have to be considered when carrying out this comparison. Our study did not include individuals who, excluding the 3rd molars, had absent teeth or tooth germs (this is the case for patients who exhibit inadequate permanent dentition). Kalabalık and Ertas⁸ analyzed the CBCT radiographs of 252 subjects, ranging from ages 12-85, with absent premolar and molar teeth; the results showed that MSV increased with absent teeth, particularly in subjects over the age of 61.

Emirzeoglu et al.¹⁴ conducted research on 77 subjects over the age of 18 and did not notice a significant relationship between age and volume. Arijji et al.¹⁷ researched paranasal sinus volume and its relation to age; following evaluation of 115 CT radiographs of many subjects, the MSV demonstrated an increase up to the age of 20 and steadily declined subsequently. Following the investigation of 200 CBCT radiographs, Belgin et al.¹¹ observed the greatest maxillary size in the 18-24-year-old group and the lowest in the older group. Although Emirzeoglu et al.¹⁴ did not indicate the absence of teeth in their research, Arijji et al.¹⁷ reported that individuals

lacking teeth had a greater MSV than those who did not. Thus, they suggested that the impact of age should be thoroughly investigated as the average age of individuals with and without teeth are statistically different. Furthermore, the development of facial bones was thought to be associated with this.¹¹

Our research findings demonstrated that MSV was not related to skeletal malocclusions, despite the fact that sinuses with the highest volume belonged to subjects with Class III malocclusion. In contrast, Dhiman et. al.⁹ observed a higher maxillary sinus volume in class II malocclusions in relation to Class I and III. In a study conducted in the same population as ours²², it was compared MSV in high-angle, low-angle, and normal-angle groups using CBCT of 60 adults aged 29.90 ± 10.91 years. Similar to our results, they found no differences in MSV in vertical skeleton groups except for maxillary sinus lengths. In another study conducted in the same population as ours²³, MSV was evaluated in the CBCT images of 48 patients with an average age of 20.16 years, and it was found that MSV did not differ according to the sagittal skeletal structure.

The SNA shows the relative anteroposterior position of the maxilla relative to the cranial base. It is stated that subjects with a larger skull base have a wider maxillary sinus. Studies investigating the correlation between SNA and MSVs are insufficient in the literature.^{6,9} Therefore, we wanted to investigate whether the SNA parameter has an effect on MSV. Endo et. al.⁶ and Dhiman et al.⁹ reported that SNA, SNB, and ANB angles were insignificant when evaluating the size of the maxillary sinuses. In a study conducted in 2019²⁵, SNA, ANB, and MSV parameters were evaluated in beta-thalassemia and control groups. While it was determined that there was no difference in SNA between the control and thalassemia groups, MSV was found to be smaller in the thalassemia group. Consistent with this study, SNA had no effect on MSV bilaterally in our study either.

CONCLUSION

Our study displayed the independence of MSV in correlation to various skeletal malocclusion types, age, gender, and SNA angle. The products of this study may be beneficial when it comes to the assessment of the maxillary sinus in various dentofacial skeletal patterns during the planning of orthognathic surgery and mini screw implantations. Newer studies including alternative orthodontic measurements are required to clarify our understanding of the volumetric alterations of the maxillary sinus.

Acknowledgements None.

Compliance with ethical standards

Conflict of interest The authors declare that they have no conflict of interest.

Ethical approval This study was approved by The Ethics Board Committee of xxxxx University, Faculty of Dentistry (decision no 2019/05).

Informed consent Not required.

REFERENCES

1. Jun BC, Song SW, Park CS, Lee DH, Cho KJ, Cho JH. The analysis of maxillary sinus aeration according to aging process; volume assessment by 3-dimensional reconstruction by high-resolutional CT scanning. *Otolaryngol Head Neck Surg* 2005; 132: 429-434.
2. Scuderi AJ, Harnsberger HR, Boyer RS. Pneumatization of the paranasal sinuses: normal features of importance to the accurate interpretation of CT scans and MR images. *AJR Am J Roentgenol* 1993; 160: 1101-1104.
3. Sánchez Fernández JM, Anta Escuredo JA, Sánchez Del Rey A, Santaolalla Montoya F. Morphometric study of the paranasal sinuses in normal and pathological conditions. *Acta Otolaryngol* 2000; 120: 273-278.
4. Pamporakis P, Nevzatoğlu Ş, Küçükkeleş N. Three-dimensional alterations in pharyngeal airway and maxillary sinus volumes in Class III maxillary deficiency subjects undergoing orthopedic facemask treatment. *Angle Orthod* 2014; 84: 701-707.
5. Oz AZ, Oz AA, El H, Palomo JM. Maxillary sinus volume in patients with impacted canines. *The Angle Orthod* 2017; 87: 25-32.
6. Endo T, Abe R, Kuroki H, Kojima K, Oka K, Shimooka S. Cephalometric evaluation of maxillary sinus sizes in different malocclusion classes. *Odontology* 2010; 98: 65-72.
7. Mozzo P, Procacci C, Tacconi A, Martini PT, Andreis IB. A new volumetric CT machine for dental imaging based on the cone-beam technique: preliminary results. *Eur Radiol* 1998; 8: 1558-1564.
8. Kalabalık F and Ertaş ET. Investigation of maxillary sinus volume relationships with nasal septal deviation, concha bullosa, and impacted or missing teeth using cone-beam computed tomography. *Oral Radiol* 2019; 35: 287-295.
9. Dhiman I, Singla A, Mahajan V, Jaj HS, Seth V, Negi P. Reliability of frontal sinus with that of maxillary sinus in assessment of different types of skeletal malocclusions. *J Indian Orthod Soc* 2015; 49: 96-103.
10. Panou E, Motro M, Ateş M, Acar A, Erverdi N. Dimensional changes of maxillary sinuses and pharyngeal airway in Class III patients undergoing bimaxillary orthognathic surgery. *Angle Orthod* 2013; 83: 824-831.
11. Belgin CA, Colak M, Adiguzel O, Akkus Z, Orhan K. Three-dimensional evaluation of maxillary sinus volume in different age and sex groups using CBCT. *Eur Arch Otorhinolaryngol* 2019; 276: 1493-1499.
12. Basdra EK, Stellzig A, Komposch G. The importance of the maxillary sinuses in facial development: a case report. *Eur J Orthod* 1998; 20: 1-4.
13. Erdur O, Ucar FI, Sekerci AE, Celikoglu M, Buyuk SK. Maxillary sinus volumes of patients with unilateral cleft lip and palate. *Int J Pediatr Otorhinolaryngol* 2015; 79: 1741-1744.
14. Emirzeoglu M, Sahin B, Bilgic S, Celebi M, Uzun A. Volumetric evaluation of the paranasal sinuses in normal subjects using computer tomography images: a stereological study. *Auris Nasus Larynx* 2007; 34: 191-195.
15. Cho SH, Kim TH, Kim KR, et al. Factors for maxillary sinus volume and craniofacial anatomical features in adults with chronic rhinosinusitis. *Arch Otolaryngol Head Neck Surg* 2010; 136: 610-615.
16. Fernandes C. Volumetric analysis of maxillary sinuses of Zulu and European crania by helical, multislice computed tomography. *J Laryngol Otol* 2004; 118: 877-881.
17. Ariji Y, Kuroki T, Moriguchi S, Ariji E, Kanda S. Age changes in the volume of the human maxillary sinus: a study using computed tomography. *Dentomaxillofacial Radiol* 1994; 23: 163-168.
18. Aksoy S. Konik ıÇınlı komputerize tomografi kullanılarak üç boyutlu olarak paranasal sinüs ve varyasyonlarının üst havayolu anatomisi ile birlikte incelenmesi: Doktora Tezi. KKTC Yakın Doğu Üniversitesi, Sağlık Bilimleri Enstitüsü; 2013.
19. Demir UL, Akca ME, Ozpar R, Albayrak C, Hakyemez B. Anatomical correlation between existence of concha bullosa and maxillary sinus volume. *Surg Radiol Anat* 2015; 37: 1093-1098.
20. Prabhat M, Rai S, Kaur M, Prabhat K, Bhatnagar P, Panjwani S. Computed tomography based forensic gender determination by measuring the size and volume of the maxillary sinuses. *J Forensic Dent Sci* 2016; 8:40-46.

21. Shrestha B, Shrestha R, Lin T, et al. Evaluation of maxillary sinus volume in different craniofacial patterns: a CBCT study. *Oral Radiol* 2021; 37: 647-652.
22. Okşayan R, Sökücü O, Yeşildal S. Evaluation of maxillary sinus volume and dimensions in different vertical face growth patterns: a study of cone-beam computed tomography. *Acta Odontol Scand* 2017; 75: 345-349.
23. Aşantoğrol F, Etöz M, Topsakal K, Can F. Evaluation of the maxillary sinus volume and dimensions in different skeletal classes using cone beam computed tomography. *Annals Med Res* 2021; 28: 709-715.
24. Kawarai Y, Fukushima K, Ogawa T, et al. Volume quantification of healthy paranasal cavity by three-dimensional CT imaging. *Acta Otolaryngol* 1999; 540: 45-49.
25. Koparal M, Yalcın ED, Aksoy O, Ozcan-Kucuk A. Evaluation of maxillary sinus volume and surface area in children with β -thalassaemia using cone beam computed tomography. *Int J Pediatr Otorhinolaryngol* 2019; 125: 59-65.