

Case Report

Primary Ewing Sarcoma of the Kidney in a 54-Year-Old Male: A Rare Case Report

 Yusuf Ilhan,¹  Ceren Suntur,²  Havva Serap Toru,³  Onur Ertunc,⁴  Ali Murat Tatli,¹  Hasan Senol Coskun,¹
 Sema Sezgin Goksu,¹

¹Department of Medical Oncology, Akdeniz University Faculty of Medicine, Antalya, Türkiye

²Department of Internal Medicine, Akdeniz University Faculty of Medicine, Antalya, Türkiye

³Department of Pathology, Akdeniz University Faculty of Medicine, Antalya, Türkiye

⁴Department of Pathology, Suleyman Demirel University Faculty of Medicine, Isparta, Türkiye

Abstract

Ewing sarcomas/Primitive neuroectodermal tumors are aggressive tumors, typically seen in children and young adults. These tumors are of neuroectodermal origin and, also known as Ewing sarcoma family tumors. They are most commonly seen in the bones and soft tissues. Primary Ewing sarcoma of the kidney is rarely seen. It has nonspecific symptoms and imaging findings. Therefore, it is mostly diagnosed postoperatively. Its diagnosis is based on histological morphology, immunohistochemistry and, molecular genetic tests. A multi-modality treatment approach is very important. Here, we presented a male patient with primary Ewing sarcoma of the kidney, relatively in older age. A 54-year-old male patient admitted to the hospital with right flank pain and hematuria. He was operated successfully and then received adjuvant vincristine, doxorubicin, cyclophosphamide, and ifosfamide, etoposide chemotherapy regimens. No treatment-related toxicity was observed and the patient is still in remission. Despite using surgery and adjuvant chemotherapy in treatment, because of its rarity there was no randomized trial about kidney Ewing sarcomas. These rare tumors still need robust therapeutic treatment regimens.

Keywords: Ewing sarcoma, kidney sarcomas, kidney tumor

Cite This Article: Suntur C, Ilhan Y, Tatli AM, Sezgin Goksu S, Coskun HS, Toru HS, et al. Primary Ewing Sarcoma of the Kidney in a 54-Year-Old Male: A Rare Case Report. EJMA 2023;3(1):40–43.

Ewing sarcoma (ES) and peripheral primitive neuroectodermal tumors (PNET) were initially defined as different clinicopathological entities. However, because of their similar histological and cytogenetic properties, these tumors are now considered part of the spectrum of neoplastic diseases known as Ewing sarcoma family tumors (ESFT).^[1,2] ESFT is a family of small round cell tumors originating from neural crest outside the central and sympathetic nervous system. ESFT is the most commonly seen in the bones and soft tissues of children and adolescents. Rarely, they can

also originate from visceral organs. Renal cell carcinoma is the most common kidney tumor and primary Ewing sarcoma of the kidney (ESK) is an extremely rare disease. Histologically, ESK is characterized by rosette formation, CD99, FLI-1 positivity, and cytogenetically by t (11; 22) (q24; q12). As far as we know, more than 100 cases diagnosed with ES originated from the kidney have been reported worldwide. Here, we presented a male patient with ESK, relatively in an older age patient.

Address for correspondence: Yusuf Ilhan, MD. Akdeniz Üniversitesi Tıp Fakültesi, Tıbbi Onkoloji Anabilim Dalı, Antalya, Türkiye

Phone: +90 505 608 62 51 **E-mail:** dryusufilhan@gmail.com

Submitted Date: September 04, 2022 **Accepted Date:** January 29, 2023 **Available Online Date:** June 23, 2023

©Copyright 2023 by Eurasian Journal of Medical Advances - Available online at www.ejmad.org

OPEN ACCESS This work is licensed under a Creative Commons Attribution-NonCommercial 4.0 International License.



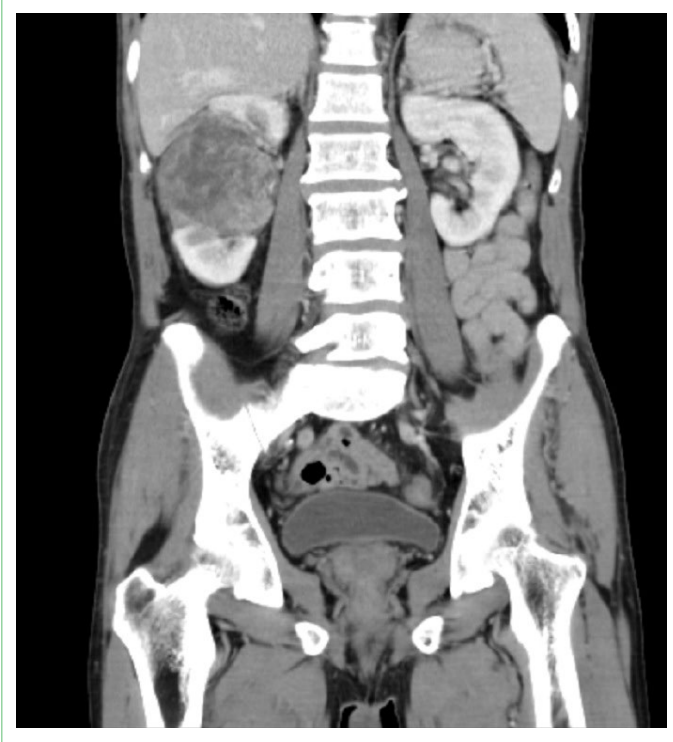

Figure 1. Coronal plane demonstrating the right upper pole renal mass.

Case Report

A 54-year-old male patient admitted to the hospital with right flank pain and hematuria. He had no other significant medical history. He had 30-pack-year smoking history and moderate alcohol consumption. Because of these symptoms, urinary ultrasonography was performed and nearly 7 cm solid mass was found in the right kidney. Computed tomography (CT) was performed upon the detection of a mass in the right kidney. A heterogeneously enhanced hyperdense cystic mass lesion, approximately 74*63 mm in size located in the upper pole of the right kidney was observed and renal cell carcinoma was considered in the differential diagnosis (Figs. 1, 2). The patient underwent a right radical nephrectomy. In the intra-operative observation, there was a mass about 7 cm extending from the middle pole of the right kidney towards the upper pole and anterior of the kidney. There was no invasion to the renal artery and vein. On pathological gross examination, there was a large tumour (6,9*6,1*6 cm) in the right kidney. The mass has infiltrated the renal parenchyma. Nuclear polymorphism, spindle cells, and rosette formation were observed in microscopic examination. Immunohistochemical examination revealed vimentin, cd99, fli-1 positive staining; synaptophysin, sma, myogenin, ck18 negative staining. Widespread CD99 and fli-1 positivity were observed in the case. In addition to morphologic and immunohistochemistry findings, for differential diagnosis of

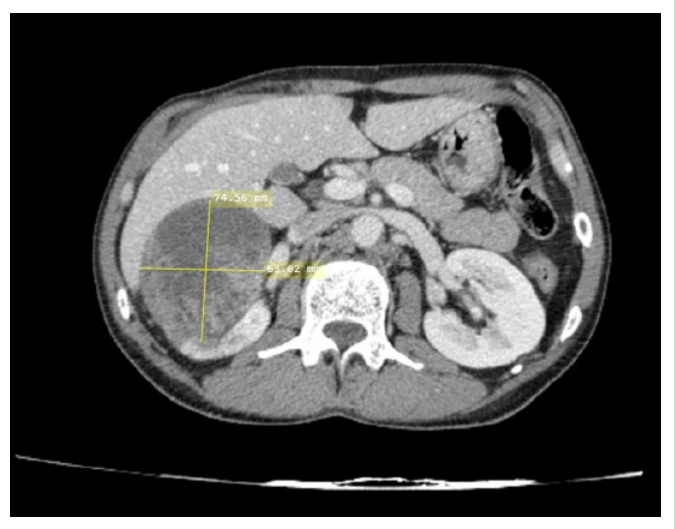


Figure 2. Computer tomography scan showing the 74*63 mm right upper pole renal mass.

these tumors, *EWSR1* gene rearrangement was performed using fluorescent in situ hybridization (FISH) technique. In FISH analyze, 30% of tumor cells were positive for *EWSR1* rearrangement. (Fig. 3). Because of widespread CD99 and FLI-1 positivity, and *EWSR1* gene rearrangement positivity, primary Ewing sarcoma of kidney was considered after the pathologic evaluation. Positron emission tomography/computed tomography was taken for postoperative staging and distant metastasis was not observed. The patient received adjuvant vincristine, doxorubicin, cyclophosphamide (VAC), and ifosfamide, etoposide (IE) chemotherapy regimens, alternately every 3 weeks. No treatment-related toxicity was observed and the patient is still in remission.

Discussion

Primary Ewing sarcoma of the kidney is a rare kidney tumor, accounting for less than 1% of all renal tumors. It mostly affects young adults, most commonly in the 2nd and 3rd decade. There is also a slight male dominance. Our case was 54 years old and, moderate older comparing with usual Ewing sarcomas.^[1-3] Clinical signs and symptoms are nonspecific such as flank pain, hematuria, and palpable mass. Furthermore, no specific finding for ES/PNET has been identified in ultrasonography and computed tomography or magnetic resonance imaging. The imaging features of most renal sarcomas are indistinguishable from renal carcinoma.^[1] In our case, similar to the cases in the literature, with CT imaging, renal cell carcinoma was considered, but after the operation, the pathology report was given as Ewing sarcoma. So, the diagnosis of ESK is mostly made post-operatively.

Histologically, ESK consists of small round cells. The differential diagnosis includes wilms tumor, neuroblastoma, synovial sarcoma, renal cell carcinoma, malignant lympho-

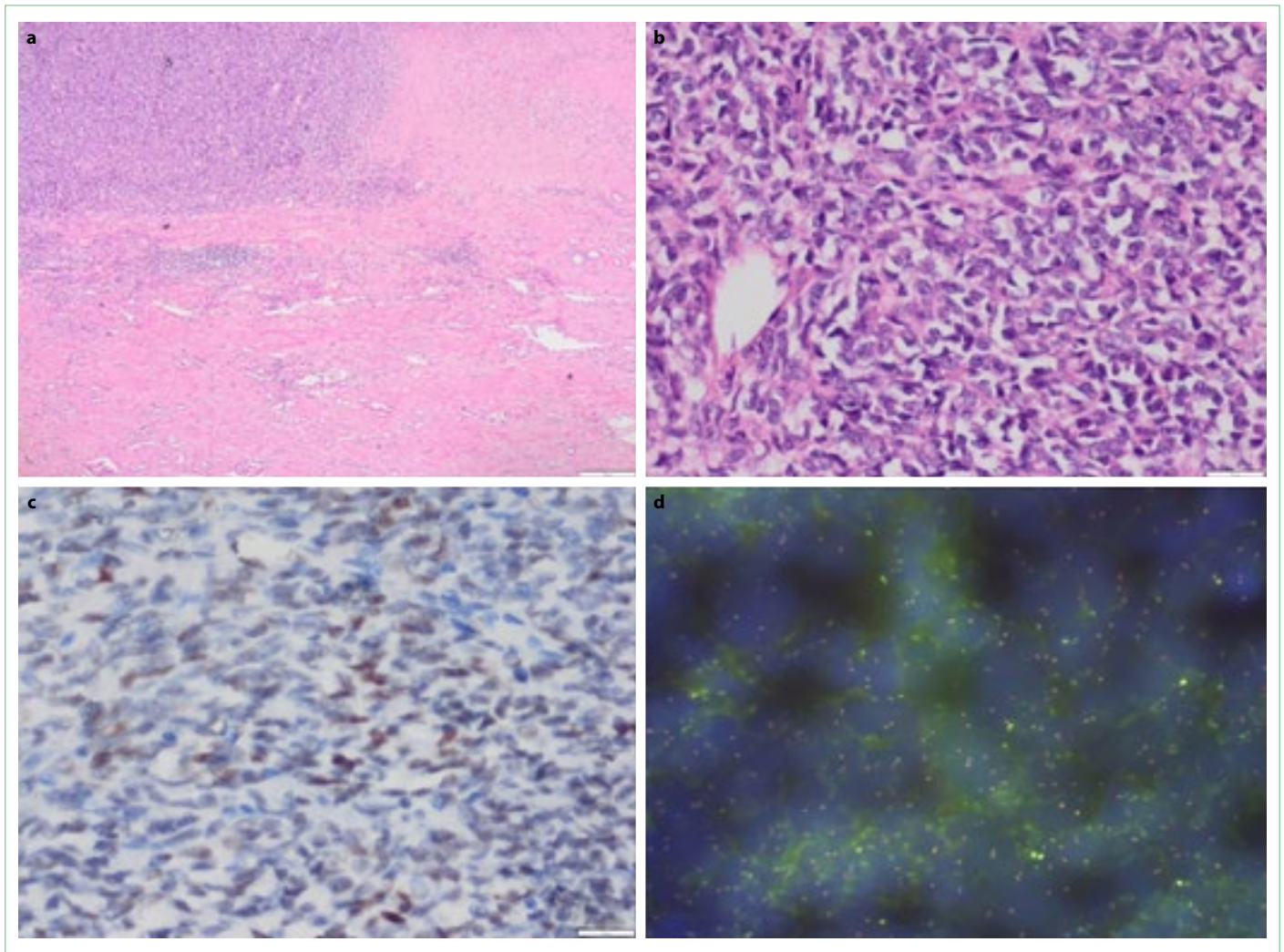


Figure 3. (a, b) Small round cell tumor in Kidney (Light microscopy H&E stain a: $\times 40$ b: $\times 400$). (c) The immunohistochemical FLI-1 nuclear expression in tumor cells (Light Microscopy IHC FLI 1 stain, $\times 400$). (d) The EWSR1 (22q12) dual-color, break-apart rearrangement (Immunofluorescent microscopy, FISH analysis, $\times 200$).

ma, solid variant of alveolar rhabdomyosarcoma, small cell neuroendocrine carcinoma, desmoplastic small round cell tumor, and small cell carcinoma.^[4] These small round cell tumors have similar morphological features but different prognoses. Therefore, the diagnosis should be supported by immunohistochemistry and molecular analysis in order to distinguish. CD99 and FLI-1 positivity are common in ES/PNET including ESK. In molecular analysis performed by FISH technique, ES / PNET is characterized by translocation between EWS (22q12) and FLI-1 (11q24) genes.

ES/PNET is an aggressive disease, grows rapidly and may metastasize early to the lung, liver, bone, and lymph nodes.^[4,5,9] An increase in survival was observed with aggressive adjuvant therapy in localized Ewing sarcomas.^[6,7] Currently, there is still no standard treatment for ESK. Mostly, they are treated with multi-agent chemotherapy knowing from classic bone Ewing sarcoma's trials regimens after radical

nephrectomy. Symptoms of our patient were developed in a short time, and when he was admitted to the hospital a gross mass, approximately 7 cm was detected. We also preferred to treat patient with VAC-IE altering adjuvant chemotherapy regimens after radical nephrectomy. However, patients with metastatic disease at the time of the first diagnosis had a poor prognosis. In chemotherapy, vincristine, ifosfamide, adriamycin, etoposide, cyclophosphamide, and actinomycin-D are widely used in both localize and metastatic diseases. If there is venous thrombosis associated with pulmonary metastasis, cavotomy may be added to the surgical intervention. If the surgical margin is positive or there is a localized lymph node involvement, radiotherapy should be added to the treatment as salvage therapy. However, there are conflicting opinions regarding the use of radiotherapy as first-line treatment.^[8] There are claims that anti-tumor agents such as apatinib, an angio-

genic drug, may be one of the treatment options for ESK, but more studies are needed to confirm their benefits on the disease.

Conclusion

Renal ES/PNET is a rare, aggressive malignancy. It is predominantly seen in young adults. Patients mostly present with nonspecific symptoms such as flank pain, hematuria, and palpable mass. There is no specific finding in imaging studies. However, imaging is required to evaluate the mass preoperatively and to detect metastases. The diagnosis of ES/PNET is based on histomorphology, immunohistochemical staining, and molecular genetic testing. Multimodal therapy including surgery, chemotherapy, and radiotherapy is indicated. Currently, the most common treatment is surgery and adjuvant chemotherapy for localized Ewing sarcoma of the kidney. However, this malignancy still needs stronger therapeutic regimens.

Disclosures

Informed Consent: Written informed consent was obtained from the patient for the publication of the case report and the accompanying images.

Peer-review: Externally peer-reviewed.

Conflict of Interest: None declared.

Authorship Contributions: Concept – Y.I., S.S.G.; Design – Y.I., C.S.; Supervision – A.M.T., S.S.G., H.S.C.; Materials – Y.I., C.S., O.E., H.S.T.; Data collection and/or processing – Y.I., C.S., H.S.T., O.E., A.M.T., H.S.C., S.S.G.; Analysis and/or interpretation – Y.I.; Literature search – Y.I.; Writing – Y.I., C.S.; Critical review – A.M.T., S.S.G., H.S.

References

1. Ekram T, Elsayes KM, Cohan RH, Francis IR. Computed tomography and magnetic resonance features of renal Ewing sarcoma. *Acta Radiol* 2008;49:1085–90.
2. Ellinger J, Bastian PJ, Hauser S, Biermann K, Müller SC. Primitive neuroectodermal tumor: rare, highly aggressive differential diagnosis in urologic malignancies. *Urology* 2006;68:257–62.
3. Angel JR, Alfred A, Sakhuja A, Sells RE, Zechlinski J. Ewing's sarcoma of the kidney. *Int J Clin Oncol* 2010;15:314–8.
4. Jimenez RE, Folpe AL, Lapham RL, Ro JY, O'Shea PA, Weiss SW, et al. Primary Ewing's sarcoma/primitive neuroectodermal tumor of the kidney: a clinicopathologic and immunohistochemical analysis of 11 cases. *Am J Surg Pathol* 2002;26:320–7.
5. Zhang S, Li Y, Wang R, Song B. Ewing's sarcoma/primitive neuroectodermal tumor of the kidney: a case report and literature review. *Transl Androl Urol* 2019;8:562–6.
6. Grier HE, Krailo MD, Tarbell NJ, Link MP, Fryer CJH, Pritchard DJ, et al. Addition of ifosfamide and etoposide to standard chemotherapy for Ewing's sarcoma and primitive neuroectodermal tumor of bone. *N Engl J Med* 2003;348:694–701.
7. Wedde TB, Lobmaier IV, Brennhovd B, Lohne F, Hall KS. Primary Ewing's Sarcoma of the Kidney in a 73-Year-Old Man. *Sarcoma*. 2011;2011:978319.
8. Riley DS, Barber MS, Kienle GS, Aronson JK, von Schoen-Angerer T, Tugwell P, et al. CARE guidelines for case reports: explanation and elaboration document. *J Clin Epidemiol* 2017;89:218–35.
9. Lalwani N, Prasad SR, Vikram R, Katabathina V, Shanbhogue A, Restrepo C. Pediatric and adult primary sarcomas of the kidney: a cross-sectional imaging review. *Acta Radiol* 2011;52:448–57.