

Neuroendocrine Tumours Detected After Appendectomy: 5-Year Single Center Experience with 4888 Acute Appendicitis Patients

Ahmet Başkent, Murat Alkan, Ecem Memişoğlu*, Okan Ok

Department of General Surgery, Kartal Dr Lütüfi Kırdar City Hospital, İstanbul, Turkey

ABSTRACT

This study is aimed to retrospectively examine the demographic characteristics, surgical procedure, histopathological results and survival of patients who underwent appendectomy with the diagnosis of acute appendicitis and were diagnosed histopathologically with neuroendocrine tumors of the appendix (ANET).

A retrospective study was performed in patients undergoing surgery for acute appendicitis between January 2015 and December 2020. Demographic characteristics of the patients, tumor diameter, tumor grade, invasion, surgical margin, TNM stage, postoperative follow-up and survival time were obtained from the hospital database. In addition, the expression of synaptophysin, chromogranin-A, Ki-67, CD56 tumor markers and mitotic index of the cases were assessed from the pathology reports.

In the histopathological examination of 4888 appendectomy specimens, ANET was detected incidentally in 31 cases (0.63%). The median age in these cases was 33 years and the women/men ratio was 1.6. Twenty seven (87.1) cases were found to be Grade 1, 3 (9.8%) Grade 2 and 1 (3.2%) Grade 3. Only appendectomy was performed in 26 (83.8%) of the patients, and complementary right hemicolectomy (RH) was performed in 5 (16.2%) patients with Grade 2. Residual tumor was seen in only 1 (Grade 3) of the cases who underwent RH. No recurrence was detected in any of the cases.

ANETs are very rare and are usually detected incidentally in pathological examinations after appendectomy. Therefore, routine appendectomy specimens should be carefully examined to determine the diagnosis. ANETs are a disease with a very good life expectancy and prognosis. Complementary right hemicolectomy should be recommended in advanced ANETs.

Keywords: Appendectomy, appendiceal neuroendocrine tumours, appendix

Introduction

Neuroendocrine tumors (NETs) are rare, slow-growing neuroendocrine tumors originating from enterochromaffin cells of the gastrointestinal and bronchopulmonary system (1). The system with the highest rate of neuroendocrine cells is the gastrointestinal tract (2). However, NETs are responsible for only 2% of all gastrointestinal system malignancies (3). NETs most commonly occur in the small intestine (44.7%), rectum (19.6%) and appendix (16.7%) (4).

Appendiceal neuroendocrine tumors (ANETs) are the most common (~60%) type of the appendix tumors. The majority of ANETs are well differentiated and have an excellent prognosis (5,6,7,8,9). In the current literature, it has been reported that ANETs have an annual incidence of 0.15-0.6 per 100,000 population and are seen more commonly in women than men, with the highest

incidence in the 5th decade of life (7,10,11,12). Most ANETs are incidental diagnosis, occur in 0.3%- 0.5% of patients undergoing appendectomy (5,9,11,13,14). A carcinoid syndrome associated with ANETs is rarely reported and is primarily associated with patients with metastatic disease. Metastatic disease is a rare condition in patients with ANETs.

The basic approach of ANET treatment is simple appendectomy, appendectomy with lymphadenectomy or right hemicolectomy (RH) according to oncological principles. Right hemicolectomy is performed in cases with positive resection margin, deep mesoappendix invasion, higher proliferation rate (Ki67 index >2%), patients with tumors of 1-2 cm in size with angio invasion, and all NETs whose tumor exceeds 2 cm (9,15).

In our study, demographic characteristics, surgical procedure, histopathological results and survival

*Corresponding Author: Ecem Memişoğlu, Kartal Dr. Lütüfi Kırdar City Hospital, Department of General Surgery, İstanbul, Turkey

E-mail: dreecem@gmail.com, Telephone: +90 (216) 458 30 00, Fax: +90 (216) 352 00 83

ORCID ID: Ahmet Başkent: 0000-0002-4420-879X, Murat Alkan: 0000-0003-0286-3072, Ecem Memişoğlu: 0000-0003-2360-4694, Okan Ok: 0000-0003-3550-7082

Received: 30.11.2022, Accepted: 22.12.2022

of patients who underwent appendectomy with the diagnosis of acute appendicitis and were diagnosed with histopathologically ANET were retrospectively analyzed.

Materials and Method

Between January 2015 and December 2020, 4888 cases who underwent appendectomy due to acute appendicitis in our hospital were evaluated retrospectively. Our study was approved by the ethics committee of our hospital. (Decision: 2020/514/184/10. Date: 26.08.2020) Patients with a definite diagnosis of ANET histopathologically were included in the study. Non-ANET malignancies, acute phlegmanous appendicitis, complicated (perforated and gangrenous) appendicitis and other malignancies that metastasized to the appendix were not included in our study.

Demographic characteristics of the patients, tumor diameter, tumor grade, invasion, surgical margin, tumor, lymph node and metastasis (TNM) stage of appendicular carcinoids, postoperative follow-up and survival times were obtained from the hospital database and patient files. In addition, synaptophysin, chromogranin-A, Ki-67, CD56 tumor markers and mitotic status data of the cases were analyzed from the pathology reports. Among the patients with ANET detected in the pathology results; patients with Stage 2 according to TNM staging were called for control, and after total colonoscopy was performed in terms of radiological examinations and possible synchronous colon tumors, complementary right hemicolectomy was performed. Patients who underwent right hemicolectomy were followed up with physical examination, colonoscopy, and radiological examination at 6-month and 1-year intervals postoperatively.

Statistical analysis: Statistical analysis of data was performed using SPSS™ software, version 20. Continuous variables were described as as median and normal range. Categorical variables were reported using numbers and proportions. Qualitative data were described using the number and percent.

Results

Appendix malignancy was detected in 38 of 4888 appendectomy specimens examined in 5 years in our hospital. Among these, 7 were excluded from the study because they had epithelial malignancies (3 mucinous adenocarcinoma, 2 adenocarcinomas,

2 stomach and breast appendix metastasis). The remaining 31 ANET cases were included in our study. All of these cases were found incidentally after appendectomy. The appendectomy specimens in our study were reported as well, moderately, and poorly differentiated neuroendocrine tumors. While the ratio of women to men was 1.6%, the median age was found to be 33 (13-66). The median follow-up was 35 (9-71) months. No recurrence was detected in any of the patients during the follow-up period.

According to WHO 2010 criteria, 27 of 31 (87.1%) patients were diagnosed as G1 (well-differentiated), 3 of them G2 and 1 of them as G3. Ki-67 and mitotic indices were also found to be high in patients with high grade. The tumor was located distally in 26 (83.9%) patients, in the middle in 4 (9.7%) patients, and at the root of the appendix in 1 (3.2%) patient. TNM staging was performed for the patients and no additional surgical intervention was planned for 26 patients with TNM T1a and T1b. There were 5 (16.1%) cases with T2 and T3 (one case well differentiated but larger than 2 cm), and three cases were moderately differentiated and one case was poorly differentiated. Right hemicolectomy (RH) was performed in these 5 cases. Residual tumor was detected in only one of the patients who underwent RH, and the surgical margins of this tumor were reported as clean. (Table 1).

NET biomarkers (Table 2) and the mitotic count under High Power Field (HPF) (Table 3) in the pathological specimens of 31 cases in our study are presented in tabular form. In addition, pathological microscopic images of ANET cases are shown in Figure 1A/B, 2A/B, 3A/B.

Discussion

ANETs originate from enterochromaffin cells, a type of neuroendocrine cell in the lamina propria and submucosa, mostly affect the young population, have a good prognosis and are responsible for 60% of rare appendiceal tumors (16). ANETs are detected in 0.2-0.7% of all appendectomies (17). In our study, the rate of ANET patients was observed at rates similar to the literature. Since most of the ANETs are localized in the distal region, they are less likely to cause obstruction (2). Most patients are asymptomatic, but only a few may develop symptoms due to large tumors or distant metastases. In many patients, ANET is incidentally diagnosed as a result of histopathological examination of the

Table 1. Demographic Characteristics

		n	%
Gender	Female	19	61.3
	Male	12	38.7
Age (year) (median)		13-69 (33.6)	
Follow-up duration (month) (mean)		9-71 (35)	
Right Hemicolectomy	No	26	83.9
	Yes	5	16.1
Survival	Yes	31	100
Tumor location	Distal	26	83.9
	Middle	4	12.9
	Radix	1	3.2
	Total	31	100
Differentiation	Well	27	87.1
	Moderately	3	9.7
	Poorly	1	3.2
	Total	31	100.0
Ki.67 Index	1-1.99	22	71
	2-20	8	25.8
	21-30	1	3.2
	Total	31	100.0
Staging (TNM)	T1a	4	12.9
	T1b	22	71
	T2	5	16.1
	Total	31	100.0
Tumor size (mm)	0-1	4	12.9
	2-20	22	71
	21-30	5	16.1
	Total	31	100.0
Median Tumor Diameter (mm)		5.06 (1-30)	

appendectomy specimen. The diagnosis of NET in our study was also determined incidentally, as a result of the histopathological examination of the appendectomy specimen for acute appendicitis. In cases with suspected ANET, the diagnosis can be made by chromogranin A level in the blood, 5-hydroxyindole acetic acid (5-HIAA) level in the urine (24 hours), abdominal tomography and octreotide scintigraphy (18).

Most of the ANETs in our study were localized in the distal appendix. Despite the presence of tumor at the distal end of the appendix in the vast majority of our cases (83.9%), it also raises suspicion about the pathogenesis of appendicitis through luminal obstruction in the patient group. In our study, acute inflammation of the appendix was observed in only one case due to luminal obstruction secondary to the tumor. Therefore,

these tumors are unlikely to initiate the process of appendicitis through luminal obstruction. In fact, in the studies of Roggo et al. and Amr B et al., it was emphasized that the localization of ANETs is the distal appendix (19,20). Ten percent of ANETs may be located in the radix of the appendix and cause obstruction (21). In our study, it was localized to the radix of the appendix in only 1 (3.2%) case. Poorly differentiated ANETs and goblet cell carcinoids progress more aggressively (22). ANETs rarely metastasize. If carcinoid syndrome or liver metastasis is suspected, it is recommended to measure 5-HIAA in 24-hour urine (22). In our study, liver metastases were not detected in any of the cases.

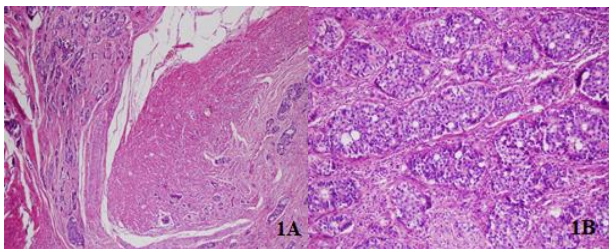
The most valuable aspect about the clinical course and prognosis of ANETs is the size of the tumor. The probability of metastasis is low in patients

Table 2. Tumor Markers

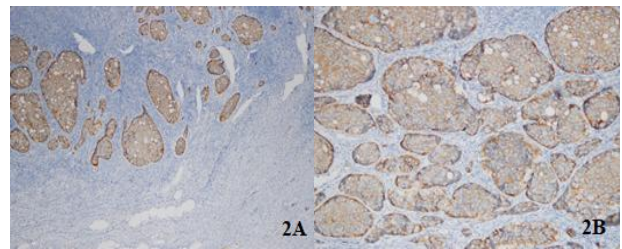
	Positive (+)	Negative (-)	No Data (%)	Valid (%)
Ki 67 (n)	31	0	-	31
(%)	100	0	-	100
Synaptophysin (n)	28	1	2	29
(%)	90.3	3.2	6.5	93.5
Chromogranin-A (n)	22	9	-	31
(%)	77	29	-	100
CD56 (n)	23	1	7	24
(%)	74.2	3.2	22.6	77.4

Table 3. Number of Mitosis in High Power Field (HPF)

	n	%	Valid (%)	Cumulative (%)
Non	5	16.1	16.1	16.1
0-1/10	15	48.4	48.4	64.5
1-2/10	7	22.6	22.6	87.1
4-5/10	4	12.9	12.9	100
Total	31	100	100	

**Fig.1A and 1B.** Hematoxylin and eosin-stained sections showing the tumor itself is composed of small uniform tumor nests of goblet cell arranged in a microglandular fashion

with a tumor size less than 2 cm, and the tumor size is less than 2 cm in 95% of the cases in our study. However, as the tumor size grows, 30% metastasis can be detected at the time of diagnosis, especially in major lesions (23). In addition to tumor size, tumor mitosis rate and Ki-67 index, histopathological grade and differentiation status are important about the behavior of the tumor (24). Consensus guidelines of the European Neuroendocrine Tumor Society (ENETS) published in 2012 also recommend simple appendectomy for tumors smaller than 1 cm. This seems to be curative regardless of the tumor site, and right hemicolectomy is performed within 3 months after the first appendectomy for patients with tumors larger than 2 cm (15). For tumors between 1 and 2 cm, if there is a positive or indistinct margin, higher proliferation rate, deep mesoappendix invasion, and/or vascular invasion, subsequent right hemicolectomy is

**Fig. 2A and 2B.** In the immunohistochemical studies, strong positivity for neuroendocrine cell component marker neuron-specific enolase (NSE) was detected in the tumor

recommended. Tumors less than 1 cm with R0 resection do not require follow-up.

In our study, 27 (87.1%) of 31 patients diagnosed with ANET were found to be Grade 1 (well differentiated) according to WHO 2010, 3 as Grade 2 and 1 as Grade 3. Ki-67 and mitotic indices were also found to be high in patients with high grade. Only appendectomy was performed in cases with grade 1 and 2 cm and clean surgical margins. Right hemicolectomy was additionally performed in patients with Grade 2 and Grade 3. Since it was larger than 2 cm in a Grade 1 case, right hemicolectomy was performed additionally in this case as in Grade 2 and Grade 3. In cases where reoperation is planned, a full colonoscopy should be performed to rule out synchronous colon cancer (25,26). We also performed preoperative total colonoscopy in our patients who underwent hemicolectomy and we did not detect any pathology in colonoscopy. Cases

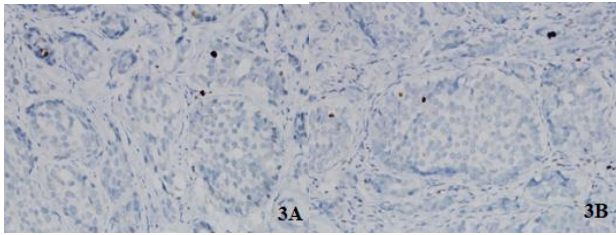


Fig. 3A and 3B. In the immunohistochemical studies strong positivity was detected in the tumor for neuroendocrine cell component marker chromogranin-A.

limited to the appendix and less than 2 cm, treated with simple appendectomy, do not require additional follow-up. In cases treated with right hemicolectomy, it is recommended to perform history, physical examination, chromogonin A and radiographic imaging examinations one year after resection (27).

The majority of ANETs have excellent prognosis and patients have more than 90% survival at 5 years. The risk of distant metastases in all ANETs is 4%, and the most frequent sites of metastasis are regional lymph nodes and liver (28). Initial treatment of liver metastases is metastasectomy. Since no carcinoid syndrome or metastasis was detected in our patient series, no additional treatment was applied to any patient. In addition, our median follow-up period was 35 (9-71) months. No recurrence was detected in any of the patients during the follow-up period. There are also publications stating that further treatment is unnecessary for tumors of 1 to 2 cm in ANETs. In the study of Egin S et al., 22 ANET cases were detected at T1 and T2 stages, and RH was not performed on any of the patients (29). In our study, RH was performed in cases with a diameter of 1 to 2 cm with mesoappendix or vascular invasion due to the presence of residual disease. Even though the number of patients was less in the study of Barut B et al., it is in line with our study in terms of incidence, staging, localization, follow-up, and approach of ANETs (30).

Data on relapse of ANET are scarce due to both the rarity and slow course of the disease. Therefore, studies showing the benefit of case-related survival with right hemicolectomy compared to simple appendectomy are lacking. For this reason, there are debates about the indications for further segmental colon resection, and there are debates as to whether the use of right hemicolectomy is oncologically sufficient or even overtreatment. This uncertainty is still controversial in the treatment with right hemicolectomy in patients with tumors larger than

1 cm and smaller than 2 cm and in patients with lymph node negativity larger than 2 cm.

As a conclusion, ANETs are extremely rare and are usually detected incidentally. Neuroendocrine neoplasms of the appendix are frequently diagnosed by pathological examination because of preoperative diagnostic methods of ANETs are inadequate. For this reason, routine appendectomy samples should be carefully examined for diagnosis. Besides, it is a disease with a good long-term prognosis. Treatment of ANETs is directly related to tumor size, localization, presence of lymphovascular and mesoappendix invasion, mitotic activation rate, and Ki67 level. If the tumor size is less than 2 cm and there is no negative prognostic factor, appendectomy is sufficient for treatment. Right hemicolectomy should be performed if the tumor is larger than 2 cm and has tumor invasion below the appendix serosa, has indistinct borders or deep mesoappendix invasion, has a higher proliferation rate (G2) and/or post-appendectomy angioinvasion. In the absence of perforation of the appendix, the prognosis of appendiceal carcinoid tumors is very good. Patients should be followed up periodically for recurrence and development of synchronous and/or metachronous colorectal cancer. However, more studies are needed to determine the optimal follow-up time.

References

1. Pinchot SN, Holen K, Sippel RS, Chen H. Carcinoid tumors. *Oncologist* 2008; 13: 1255-1269.
2. Bernick PE, Klimstra DS, Shia J, et al. Neuroendocrine carcinomas of the colon and rectum. *Dis Colon Rectum* 2004; 47: 163-169.
3. Estrozi B, Bacchi CE. Neuroendocrine tumors involving the gastroenteropancreatic tract: a clinicopathological evaluation of 773 cases. *Clinics (Sao Paulo)* 2011; 66: 1671-1675.
4. Maggard MA, O'Connell JB, Ko CY. Updated population-based review of carcinoid tumors. *Ann Surg* 2004; 240: 117-122.
5. Connor S.J, Hanna G.B, Frizelle F.A. Appendiceal tumors: Retrospective clinicopathologic analysis of appendiceal tumors from 7970 appendectomies. *Dis Colon Rectum* 1998; 41: 75-80.
6. Moertel C.G, Dockerty M.B, Judd E.S. Carcinoid tumors of the vermiform appendix. *Cancer* 1968; 21: 270-278.

7. Modlin I.M., Lye K.D, Kidd M. A 5-decade analysis of 13,715 carcinoidtumors. *Cancer* 2003; 97: 934-959.
8. Landry C.S,Woodall C, Scoggins C.R, et al. 2nd Analysis of 900 appendiceal carcinoid tumors for a proposed predictive staging system. *Arch. Surg* 2008; 143: 664-670.
9. Pape UF, Niederle B, Costa F, et al. Vienna Consensus Conference participants. ENETS Consensus Guidelines for Neuroendocrine Neoplasms of the Appendix (Excluding Goblet Cell Carcinomas). *Neuroendocrinology* 2016; 103: 144-152.
10. Yao JC, Hassan M, Phan A, et al. One hundred years after "carcinoid": epidemiology of and prognostic factors for neuroendocrine tumors in 35,825 cases in the United States. *J Clin Oncol* 2008; 26: 3063-3072.
11. Clift A. K,Frilling A. Neuroendocrine, goblet cell and mixed adeno-neuroendocrine tumours of the appendix: Updates, clinical applications and the future. *Expert Rev. Gastroenterol. Hepatol* 2017; 11: 237-247.
12. Dasari A, Shen C, Halperin D, et al. Trends in the Incidence, Prevalence, and Survival Outcomes in Patients With Neuroendocrine Tumors in the United States. *JAMA Oncol.* 2017; 3: 1335-1342.
13. Goede AC, Caplin ME, Winslet MC. Carcinoid tumour of the appendix. *Br. J. Surg* 2003; 90: 1317-1322.
14. Modlin IM, Kidd M, Latich I, Zikusoka MN, Shapiro MD. Current status of gastrointestinal carcinoids. *Gastroenterology* 2005; 128: 1717-1751.
15. Pape UF, Perren A, Niederle B, et al. Barcelona Consensus Conference participants. ENETS Consensus Guidelines for the management of patients with neuroendocrine neoplasms from the jejunum-ileum and the appendix including goblet cell carcinomas. *Neuroendocrinology* 2012; 95: 135-136.
16. Gosset A, Masson P. Tumeurs endocinnes de l'appendice. *La Presse Medicale* 1914; 22: 237-240 (in French).
17. Moris D, Tsilimigras DI, Vagios S, et al. Neuroendocrine Neoplasms of the Appendix: A Review of the Literature. *Anticancer Res* 2018; 38: 601-611.
18. Henderson L, Fehily C, Folaranmi S, et al. Management and outcome of neuroendocrine tumours of the appendix-a two centre UK experience. *J Pediatr Surg* 2014; 49: 1513-1517.
19. Roggo A, Wood WC, Ottinger LW. Carcinoid tumors of the appendix. *Ann Surg* 1993; 217: 385-390.
20. Amr B, Froghi F, Edmond M, Haq K, Thengungal Kochupapy R. Management and outcomes of appendicular neuroendocrine tumours: Retrospective review with 5-year follow-up. *Eur J Surg Oncol* 2015; 41: 1243-1246.
21. Abdelaal A, El Ansari W, Al-Bozom I, et al. Frequency, characteristics and outcomes of appendicular neuroendocrine tumors: A cross-sectional study from an academic tertiary care hospital. *Ann Med Surg (Lond)* 2017; 21: 20-24.
22. Emre A, Akbulut S, Bozdogan Z, et al. Routine histopathologic examination of appendectomy specimens: retrospective analysis of 1255 patients. *Int Surg* 2013; 98: 354-362.
23. Coursey CA, Nelson RC, Moreno RD, Dodd LG, Patel MB, Vaslef S. Carcinoid tumors of the appendix: are these tumors identifiable prospectively on preoperative CT? *Am Surg* 2010; 76: 273-275.
24. Davenport E, Courtney ED, Benson-Cooper S, Bissett IP. Appendiceal neuroendocrine neoplasms in the era of laparoscopic appendicectomy. *ANZ J Surg* 2014; 84: 337-340.
25. Pawa N, Clift AK, Osmani H, et al. Surgical Management of Patients with Neuroendocrine Neoplasms of the Appendix: Appendectomy or More. *Neuroendocrinology* 2018; 106: 242-251.
26. Rault-Petit B, Do Cao C, Guyétant S, et al. Management and Predictive Factors of Lymph Node Metastasis of Appendix Neuroendocrine Tumors: A National Study from the French Group of Endocrine Tumors (GTE). *Ann Surg* 2019; 270: 165-171.
27. National Comprehensive Cancer Network, "Neuroendocrine and adrenal tumors," 2019, https://www.nccn.org/professionals/physician_gls/pdf/neuroendocrine.pdf.
28. MacGillivray DC, Synder DA, Drucker W, ReMine SG. Carcinoid tumors: the relationship between clinical presentation and the extent of disease. *Surgery* 1991; 110: 68-72.
29. Eğin S, Kamalı G, Kamalı S, et al. Neuroendocrine tumor of the appendix: Twelve years of results from a single institution. *Ulus Travma Acil Cerrahi Derg* 2019; 25: 118-122.
30. Barut B, Gönültaş F. Carcinoid tumors of appendix presenting as acute appendicitis. Akut apandisit gibi bulgu veren apandiks karsinoid tümörleri. *Ulus Travma Acil Cerrahi Derg* 2019; 25: 510-513.