

Evaluation of Subclinical Papilledema In Patients With Obstructive Sleep Apnea Syndrome

Zeynep Gürsel Özkurt^{1*}, Melike Demir², Yusuf Yıldırım³, Selahattin Balsak³, Ümit Karaalp⁴

¹Dicle University Medical Faculty Ophthalmology Department, Diyarbakir, Turkey

²Dicle University Medical Faculty Thorax Diseases Department, Diyarbakir, Turkey

³Gazi Yasargil Education and Research Hospital Ophthalmology Department, Diyarbakir, Turkey

⁴Batman Area Hospital Ophthalmology Department, Batman, Turkey

ABSTRACT

The aim of this study is to analyze optic nerve head total retinal thickness (TRT) in Obstructive Sleep Apnea Syndrome (OSAS) and demonstrate a possible subclinical papilledema

Thirty-six patients with suspected OSAS underwent standard overnight polysomnography and were grouped into mild, moderate and severe. Seventy eyes of thirty six OSAS patients and seventy-two eyes of healthy controls were included. Retinal nerve fiber layer thicknesses (RNFL) and TRT s were measured by optic coherence tomography.

RNFL segment values showed no difference between OSAS and control groups. RNFL superior segment and inferonasal segments of the mild OSAS subgroup were found to be thinner than the moderate and severe OSAS subgroups ($p=0.034$, $p=0.025$, respectively). RNFL point values also showed no difference between the two groups. The RNFL inferior point of the mild OSAS subgroup was found to be thinner than the moderate and severe subgroups ($p=0.036$). OSAS TRTs were thinner than the controls at inferior and temporal points ($p=0.005$, $p=0.033$, respectively). The TRT inferior point of the mild OSAS subgroup was found to be thinner than the moderate and severe subgroups ($p=0.006$). At all points RNFL values were subtracted from the TRT values and compared. At the temporal point the OSAS group's TRT-RNFL was thinner than that of the control groups ($p=0.029$).

TRT measurements could not demonstrate a possible subclinical papilledema. Thinning of RNFL thickness and TRT in OSAS patients could be the result of hypoxemia related chronic atrophy.

Key Words: Obstructive sleep apnea syndrome, Papilledema, Total retinal thickness, Optical coherence tomography, Retinal nerve fiber layer

Introduction

Obstructive sleep apnea syndrome (OSAS) is the most common type of sleep disturbance affecting approximately 24% of middle aged men and 9% of middle aged women around the world.¹ It is characterized by repetitive episodes of complete or partial upper airway obstructions and pauses in breathing during sleep resulting in hypercapnia, hypoxemia, and hemodynamic, humoral, and neuroendocrine responses. It is reported that these responses can result in hypertension, cerebrovascular diseases and cardiovascular and ophthalmic morbidities.^{2,3} Ophthalmic morbidities are diverse, such as floppy eyelid syndrome, glaucoma and visual field defects, nonarteritic ischemic optic neuropathy and papilledema.^{4,5}

Optical coherence tomography (OCT) is a noninvasive and noncontact medical imaging technique that provides high-resolution cross-sectional images of the retina and optic nerve on

the micron scale. Retinal nerve fiber layer (RNFL) loss and thinning in OSAS patients has been shown by OCT imaging in previous studies.^{6,7} RNFL thinning is thought to be the result of ischemia of the optic nerve. One possible mechanism of ischemia is the increased intracranial pressure.^{8,9} Raised intracranial pressure causes increments of peripapillary RNFL thickness and total retinal thickness (TRT) and papilledema in acute phases.^{10,11} In previous studies, OSAS patients were screened by fundoscopic examinations, but no papilledema could be detected.^{12,13} The aim of the present study was to determine possible subclinical papilledema in OSAS patients by measuring both RNFL and TRT by OCT imaging.

Material and Methods

This study's protocol was approved by the institutional review board of the Dicle University

*Corresponding Author: Zeynep Gürsel Özkurt, Dicle University Medical Faculty Ophthalmology Department Diyarbakir
E-mail: drzeynepgursel@gmail.com, Phone: 0(505) 496 51 21

Received: 12.09.2018, Accepted: 25.11.2018

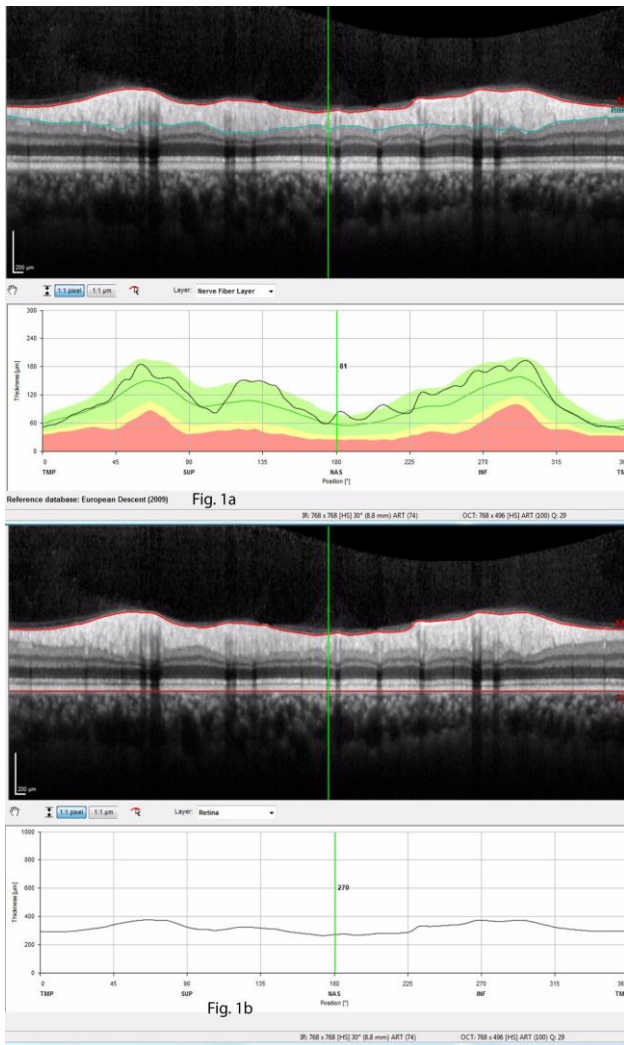


Fig. 1. OCT scan of a healthy subject. Green perpendicular lines show the location of the measured scan. **1a:** RNFL scan. RNFL is bordered anteriorly by the internal limiting membrane (red line) and posteriorly by the end of the reflective layer (blue line). Green perpendicular line showing nasal (180°) point location of RNFL thickness as 81 μ. **1b:** TRT scan. TRT is bordered anteriorly by the internal limiting membrane (red line) and posteriorly by the retina pigment epithelium basal membrane (red straight line). Green perpendicular line showing nasal (180°) point location of TRT as 270 μ.

Hospital and it was conducted in accordance with the principles of the Declaration of Helsinki. Informed consent was obtained from each patient and healthy subject.

The patient group comprised 36 subjects with 70 eyes who were diagnosed with OSAS after a sleep study but had not yet received treatment. The healthy control group again comprised 36 subjects but with 72 eyes. Exclusion criteria for both groups were: previous ocular surgery or trauma, any opacity at the ocular media, which can cause difficulty at OCT imaging, refractive spherical

errors more than 5D, cylindrical errors more than 3D, presence of optic disk changes such as glaucoma and optic atrophy, previous laser therapy, any other disease that can cause optic disk swelling, lung disease that results in hypoxemia such as chronic obstructive pulmonary disease, heavy smoking, and systemic metabolic diseases like diabetes and hypertension. Control subjects were also excluded if they had any snoring, daytime sleepiness or witnessed breath cessation at sleep.

All the participants underwent ophthalmologic examinations including refractive error measurement and best corrected visual acuity, slit-lamp biomicroscope examination, intraocular pressure measurement by Goldmann applanation tonometry and dilated fundus examination.

OCT Scanning: Spectral domain OCT (Spectralis; Heidelberg Engineering, Heidelberg, Germany) was performed on both eyes of all participants by the same experienced technical ophthalmologic assistant. After centering the subject’s papilla, the image was focused and scans were taken. A protocol ensured that the scans were obtained with an acceptable quality. At least three scans were obtained and the best quality version was chosen for the analysis.

RNFL was bordered anteriorly by the internal limiting membrane and posteriorly by the end of the reflective layer (Figure 1a). It was measured in a circle scan centered on the optic nerve head. The software divided the scan into one central and six peripheral segments and calculated the average values. The segments were central, temporal (316°–45°), temporal superior (46°–90°), nasal superior (91°–135°), nasal (136°–225°), nasal inferior (226°–270°), and temporal inferior (271°–315°).

TRT was bordered anteriorly by the internal limiting membrane and posteriorly by the retina pigment epithelium (Figure 1b). The software measured RNFL thickness with the TRT on the same scan. We documented the TRT and RNFL thickness of the participants at four points; superior, temporal, nasal and inferior (90°, 0°, 180° and 270°, respectively). We also subtracted RNFL thickness from TRT at four points in order to find the thickness of the layers that are prone to swelling.

Sleep Study: Patients who were suspected of having OSAS clinically by the chest diseases specialist underwent standard overnight polysomnography (PSG, E-Series, 44 channel polysomnograph; Compumedics™, Melbourne, Victoria, Australia). The Apne Hypopnea Index (AHI) defined by the American Academy of Sleep Medicine was calculated for each patient by

Table 1. RNFL segment values in OSAS and control groups

RNFL Segments	OSAS Group	Control Group	p values
Central	106.1±10.4μ	107.2±10.0μ	0.075
Temporal	139.0±24.2μ	142.3±15.8μ	0.335
Superonasal	118.5±25.4μ	123.0±28.0μ	0.314
Temporal	72.2±11.9μ	72.5±10.8μ	0.155
Nasal	81.9±15.2μ	83.4±14.7μ	0.555
Inferotemporal	149.9±23.0μ	152.6±19.9μ	0.312
Inferonasal	131.5±22.5μ	127.0±25.1μ	0.268

Table 2. RNFL point values in OSAS and control groups

RNFL Points	OSAS Group	Control Group	p values
Superior point (0°)	137.4±37.0μ	149.5±44.6μ	0.083
Inferior point (270°)	160.8±32.1μ	162.5±37.3μ	0.774
Temporal point (90°)	58.5±14.7μ	57.9±13.0μ	0.951
Nasal point (180°)	64.5±15.9μ	65.8±15.8μ	0.470

adding the average numbers of apnea episodes (pausing of oro-nasal flow for >10 seconds) and hypopnea episodes (decrement of oro-nasal flow of >30 % and 4 % oxygen desaturation) during an hour of sleep. In this study we included the patients with an AHI>5. An AHI of 5-15 was considered mild, 16-30 moderate, >30 severe, like the majority of studies.

Statistical Analysis: Statistical calculations were performed by the SPSS 15.0 statistical package (SPSS for Windows, Chicago, IL, USA). All parameters are presented as mean ± standard deviation (SD). Categorical variables were compared using the chi-square test. The distribution pattern of numerical dataset was analyzed by Kolmogorov-Smirnov test. Normally distributed data were compared by Student's t test while the data that were not normally distributed were compared with Mann Whitney U-test. Comparisons between mild, moderate and severe OSAS groups were analyzed by Kruskal-Wallis test. A p value of <0.05 was considered statistically significant.

Results

A total of 36 OSAS patients' 70 eyes (35 right, 35 left) and 36 control subjects' 72 eyes (36 right, 36 left) were included. The mean age was 48.1±11.5 years in OSAS group, 47.3±10.7 in control group. In OSAS group, the eyes' 77.1% were male, while the control groups eyes' 77.8% were male. Differences between two groups in terms of age

and gender were not statistically significant (p=0.642, p=0.928 respectively).

According to AHI values, the OSAS patients were grouped as mild (5-15), moderate (16-30) and severe (>30). Mild group comprised 3 patients' 6 eyes, moderate group 18 patients' 35 eyes and severe group 15 patients' 29 eyes. The mean AHI value was 10.3±3.4 in mild group, 21.7±3.8 in moderate group and 49.4±16.2 in severe group.

The OSAS groups' RNFL segment values were compared with the control group and within themselves. RNFL segment values showed no statistically significant difference between OSAS and control groups (Table 1). The mild OSAS subgroups RNFL central segment and inferonasal segments were found significantly thinner than the moderate and severe OSAS subgroups (p=0.034, p=0.025 respectively). The OSAS groups' RNFL values of 4 points (0°, 90°, 180° and 270°) were again compared with the control group and within themselves. Again there was no significant difference between OSAS and control groups (Table 2). The mild OSAS subgroups RNFL inferior point was found significantly thinner than the moderate and severe subgroups (p=0.036). At the same points TRT measurements were compared. At inferior (270°) and temporal (90°) points, OSAS groups TRTs were significantly thinner than the controls (p=0.005, p=0.033 respectively) (Table 3). The mild OSAS subgroups TRT inferior point was found significantly thinner than the moderate and severe subgroups (p=0.006). At all points RNFL values were subtracted from the TRT values and compared. At temporal (90°) point OSAS groups TRT-RNFL was

Table 3. TRT point values in OSAS and control groups

TRT Points	OSAS Group	Control Group	p values
Superior point (0°)	349.7±29.6μ	358.3±34.4μ	0.116
Inferior point (270°)	361.4±33.4μ	362.1±32.2μ	0.005
Temporal point (90°)	300.1±27.1μ	308.9±21.2μ	0.033
Nasal point (180°)	281.9±20.2μ	283.4±18.2μ	0.117

Table 4. TRT-RNFL point values in OSAS and control groups

TRT-RNFL Points	OSAS Group	Control Group	p values
Superior point (0°)	212.3±23.1μ	208.8±32.2μ	0.117
Inferior point (270°)	200.6±19.1μ	199.6±23.6μ	0.143
Temporal point (90°)	241.6±27.9μ	250.9±22.6μ	0.029
Nasal point (180°)	217.4±15.9μ	217.6±13.5μ	0.950

significantly thinner than the controls ($p=0.029$) (Table 4). There was no statistically significant difference between the OSAS subgroups.

Discussion

Optical atrophy and progressive thinning of RNFL in OSAS patients have been revealed in many previous studies (6,7). Initially, intraocular pressure instabilities were thought to be responsible for RNFL thinning and visual field defects (14,15). Later, RNFL thinning was also found in OSAS patients without any evident glaucoma.¹⁶ Peripapillary and macular choroidal thicknesses were evaluated and increments were detected in both (17,18). These data suggested a different pathophysiology than glaucoma for the neurodegeneration in OSAS.

Ischemia of the optic nerve in OSAS is thought to be the reason for the neurodegeneration. Basically, two possible mechanisms leading to ischemia are discussed: First is the autonomic instability causing nitric oxide/endothelin imbalance and abnormal vasodilation and vasoconstriction. The second is the increment of cerebrospinal fluid pressure because of raised systemic blood pressure and hypercapnia related cerebral vasodilation. Increased intracranial pressure results in papilledema and eventually optic neurodegeneration (8,16).

Papilledema has been sought in OSAS patients by fundoscopic examinations and fundus photography but no papilledema could be detected (12,13). In one study, forty-one OSAS patients were screened by fundoscopic examination and two disk swellings were found but the study was based on screening glaucoma and no comment was made about disk swellings (4). Previously in intracranial hypertension cases, optic nerves were examined by OCT, and TRT measurements were found superior to RNFL

measurements for monitoring subclinical papilledema (11,19,20). However, to the best of our knowledge, subclinical papilledema has not been screened by TRT measurements in OSAS patients before, so the current study is the first to report the TRT and RNFL values together in this condition.

We measured the RNFL thicknesses in seven segments. The values did not show any significant difference from the controls. RNFL thinning in OSAS patients is a result of optic neurodegeneration. Our study group comprised newly diagnosed patients so thinning of RNFL may not yet have occurred. Since RNFL thinning in OSAS patients occurs as a chronic process, moderate and severe subgroup values could be expected to be thinner than the mild groups. Despite this, the mild OSAS subgroup's RNFL superior segment, inferonasal segment and RNFL inferior point were found to be significantly thinner than the moderate and severe subgroups. Severe and moderate group OSAS patients may have worse hypoxemia and hypercapnia levels than the mild patients. Hypoxemia and hypercapnia can lead to more edematous thickening of RNFL which can falsely let us think there is less atrophy of RNFL in the severe group.

TRT's were measured at four points. In the OSAS group, inferior and temporal TRT's were found to be thinner than the control group. Again, as with RNFL measurements, the mild OSAS subgroup's TRT inferior point was found to be significantly thinner than the moderate and severe subgroups. TRT includes RNFL and the other layers of the retina, so thinner inferior point TRT of the mild group could be the consequence of the thinner RNFL, or it could also be related to edematous thickening of TRT in the moderate and severe subgroups. In order to prevent this bias, at four points we subtracted RNFL thickness from TRT and compared the layers that are

more prone to swelling. At the temporal point the OSAS group's TRT-RNFL was significantly thinner than the controls, but there was no statistically significant difference between the OSAS subgroups. This result contradicted the edematous thickening of TRT in the moderate and severe subgroups.

In this study, our TRT and TRT-RNFL measurements could not determine subclinical papilledema. In a previous study, OSAS patients' RNFLs were measured twice a day at 8:00 am and 7:30 pm and in the severe OSAS group diurnal changes of thickness were found (21). RNFL thicknesses were found to be significantly higher in the morning. This swelling in the morning was attributed to hypoxia and optic nerve ischemia during night sleep. In our study, the measurements were not taken at a particular time of day. This practice could have hindered the detection of possible subclinical papilledema.

Peripapillary choroidal thicknesses in OSAS patients were measured in a previous study and increments were reported at temporal and superotemporal segments (22). This increment was attributed to intracranial hypertension. In this study, we found temporal TRT and TRT-RNFL to be significantly thinner than the controls in the OSAS group. If temporal choroidal segments are affected and swell from rising intracranial hypertension, then atrophy of the overlying retinal segment can be expected. In our OSAS group, the time between the onset and the diagnosis could have resulted in thinning of the temporal retina.

In conclusion, the theory of increased intracranial pressure resulting in subclinical papilledema in OSAS was not demonstrated by TRT measurements. Diurnal changes of TRT can be studied to show possible morning subclinical edema. Further studies are needed to clarify the pathogenesis of optic neurodegeneration in OSAS.

Acknowledgements: None of the authors have conflict of interest. We did not have any financial support related to this submission.

References

1. Lee W, Nagubadi S, Kryger M, Mokhlesi B. Epidemiology of obstructive sleep apnea: a population-based perspective. *Expert Rev Respir Med* 2008; 1: 349-364.
2. Waller EA, Bendel RE, Kaplan J. Sleep disorders and the eye *Mayo Clin Proc* 2008; 83: 1251-1261.
3. Fraser CL. Obstructive sleep apnea and optic neuropathy: is there a link? *Curr Neurol Neurosci Rep* 2014; 14: 465.
4. Tsang C, Chong S, Ho C, Li MF. Moderate to severe obstructive sleep apnoea patients is associated with a higher incidence of visual field defect. *Eye* 2006; 20: 38-42.
5. Sharifipour F, Farrahi F, Moghaddasi A, Idani A, Yaseri M. Diurnal changes in retinal nerve fiber layer thickness with obstructive sleep apnea/hypopnea syndrome. *J Ophthalmic Vis Res* 2016; 11: 42-47.
6. Wang JS, Xie HT, Jia Y, Zhang MC. Retinal nerve fiber layer thickness changes in obstructive sleep apnea syndrome: a systematic review and Meta-analysis. *Int J Ophthalmol* 2016; 9: 1651-1656.
7. Wang W, He M, Huang W. Changes of Retinal Nerve Fiber Layer Thickness in Obstructive Sleep Apnea Syndrome: A Systematic Review and Meta-analysis. *Curr Eye Res* 2017; 42: 796-802.
8. Adam M, Okka M, Yosunkaya S, Bozkurt B, Kerimoğlu H, Turan M. The evaluation of retinal nerve fiber layer thickness in patients with obstructive sleep apnea syndrome. *J Ophthalmol* 2013; 2013: 292158.
9. Jennum P, Børgesen SE. Intracraial pressure and obstructive sleep apne. *Chest Journal* 1989; 95: 279-283.
10. Huang-Link YM, Al-Hawasi A, Oberwahrenbrock T, Jin YP. OCT measurements of optic nerve headchanges in idiopathic intracranial hypertension. *ClinNeurolNeurosurg* 2015; 130: 122-127.
11. Driessen C, Eveleens J, Bleyen I, van Veelen ML, Joosten K, Mathijssen I. Optical coherence tomography: a quantitative tool to screen for papilledema in craniosynostosis. *Childs Nerv Syst* 2014; 30: 1067-1073.
12. Fraser CL, Bliwise DL, Newman NJ, et al. A prospective photographic study of the ocular fundus in obstructive sleep apnea. *J Neuroophthalmol* 2013; 33: 241-246.
13. Peter L, Jacob M, Krolak-Salmon P, et al. Prevalence of papilloedema in patients with sleep apnoea syndrome: a prospective study. *J Sleep Res* 2007; 16: 313-318.
14. Mojon DS, Hess CW, Goldblum D, Bohnke M, Korner F, Mathis J. Primary open-angle glaucoma is associated with sleep apnea syndrome. *Ophthalmologica* 2000; 214: 115-118.
15. Moghimi S, Ahmadraji A, Sotoodeh H, et al. Retinal nerve fiber thickness is reduced in sleep apnea syndrome. *Sleep Med* 2013; 14: 53-57.
16. Kargi SH, Altin R, Koksall M, et al. Retinal nerve fibre layer measurements are reduced in patients with obstructive sleep apnoea syndrome. *Eye (Lond)* 2005; 19: 575-579.
17. Yuvacı İ, Pangal E, Bayram N, et al. Evaluation of posterior ocular changes using enhanced depth imaging-optical coherence tomography in patients with obstructive sleep apnea syndrome. *Arq Bras Oftalmol* 2016; 79: 247-252.
18. Bayhan HA, Aslan Bayhan S, İntepe YS, Muhafız E, Gürdal C. Evaluation of the macular choroidal thickness using spectral optical coherence tomography in patients with obstructive sleep

- apnoea syndrome. *ClinExpOphthalmol* 2015; 43: 139-144.
19. Vartin CV, Nguyen AM, Balmitgere, T Bernard M, Tilikete C, Vighetto A. Detection of mild papilloedema using spectral domain optical coherence tomography. *Br J Ophthalmol* 2012; 96: 375-379.
 20. Scott C, Kardon R, Lee A, Frisén L, Wall M. Diagnosis and grading of papilledema in patients with raised intracranial pressure using optical coherence tomography vs clinical expert assessment using a clinical staging scale. *Arch Ophthalmol* 2010; 128: 705-711.
 21. Chirapapaisan N, Likitgorn T, Pleumchitchom M, et al. Diurnal changes in retinal nerve fiber layer thickness with obstructive sleep apnea/hypopnea syndrome. *Int J Ophthalmol* 2016; 9: 979-983.
 22. Ozge G, Dogan D, Koylu MT, et al. Retina nerve fiber layer and choroidal thickness changes in obstructive sleep apnea syndrome. *Postgrad Med* 2016; 128: 317-322.