

Evaluating Edentulous Mandible Alveolar Crest Dimensions in Posterior Region By Cone Beam Computed Tomography

Alaettin Koç^{1*}, Ruşen Erdem²

¹Department of Oral and Maxillofacial Radiology, Faculty of Dentistry, Van Yüzüncü Yıl University, Van, Turkey

²Department of Orthodontics, Faculty of Dentistry, Atatürk University, Erzurum, Turkey

ABSTRACT

In this study, alveolar crest height (CH) and width (CW) in patients with edentulous mandible were measured, also the impact of gender and age factors on obtained values were evaluated.

Cone beam computed tomography (CBCT) images of 39 males and 38 females were analyzed retrospectively. CH and CW at 10 mm distal of right mental foramen of patients were measured on sectional images. Independent sample T-test and One-way ANOVA test were used for statistical analysis.

In CH measurements, there was no significant difference between males and females ($p=0.058$). However, males had significantly higher CW values compared to females ($p=0.039$). Considering age criteria, it was understood that age of patient have no significant effect on CW ($p=0.586$) and CH ($p=0.465$).

In this study, males just had significantly higher CW values. Besides, age factor had no significant effect on crest dimensions and it was concluded that each patient should be evaluated in itself during dental implant replacement regardless of age and gender.

Key Words: Dental implants, cone beam computed tomography, dental arch

Introduction

In recent years, dental implant has become a common treatment option with its high success rate. Nowadays, a certain number of dental implants are placed in patients every year with tolerable complications (1). For healthy maintenance of dental implants, patients should have a sufficient amount of and appropriate bone. However, as is known, a reduction occurs in residual bone dimension following remodeling after tooth extraction (2). Alveolar crest resorption after tooth extraction is usually observed in the horizontal plane and on the facial side. Meanwhile, a decrease in the height of alveolar crest is also observed. During this resorption process, the crests are repositioned to a more lingual position. The residual crest undergoes atrophy more rapidly in the first 6 months, which continues at a slower rate throughout life. Morphological changes in crest after tooth extraction were evaluated by cephalometric measurements, study models, radiographic analyses and direct measurements of the crest. Because of these reasons, the clinician should have experience with the healing process and the

repositioning changes observed in crest after tooth extraction (3-5).

The distance between the crest ridge and the mandibular canal is reduced to a few millimeters due to atrophy occurring in edentulous crests over time. In this case, nerve injury is inevitable in implant interventions carried out without taking precaution. Procedures, such as grafting and nerve repositioning, are used to prevent possible nerve injuries (6). In order to avoid such interventional procedures, some clinicians use shorter implants (7, 8).

The implant operator may use techniques such as crest expansion methods, sandwich osteotomy, and alveolar distraction osteogenesis to achieve a healthy bone thickness of minimum 1 mm around the implant. Although the abovementioned methods are effective, they may cause morbidity in the donor site (9, 10). In crestal bone augmentation technique, a healthy bone area is formed for implant application by creating a greenstick fracture on the buccal bone in the area to be used for implant surgery in both maxilla and mandible with inadequate bone dimensions (11, 12).

*Corresponding Author: Alaettin Koç, Van Yüzüncü Yıl University, 65080, Zeve Campus, Tuşba/Van, Turkey

E-mail: alttnkc@gmail.com, Phone: +90 (432) 225 17 44

ORCID ID: Alaettin Koç: 0000-0001-9984-6900, Ruşen Erdem: 0000-0002-5298-7949

Received: 16.08.2019, Accepted: 20.05.2020

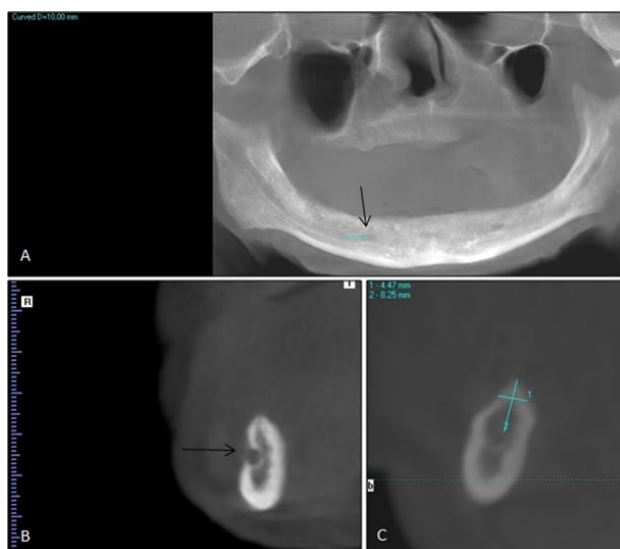


Fig. 1. 10 mm distal of right mental foramen on panoramic reconstruction view of cone beam computed tomography (A). Marked right mental foramen on coronal section image (B). Measurement of alveolar crest dimensions on coronal section image (C). (mental foramens were marked with black arrows)

Before dental implant surgery, alveolar CH may be pre-assessed by two-dimensional imaging techniques. However, magnification of panoramic radiography or measurement instability in bisecting angle technique of periapical radiography cannot provide accurate linear values. Therefore, applying to CBCT for three-dimensional evaluation is more sensible. CBCT provide image-guided dental implant surgery and clinician can perform implant surgery comfortably, so possible surgery complications can be avoided (13, 14).

The study was conducted to analyze the values of crest dimensions in patients with edentulous mandible and the correlation between the determined values and age and gender factors. By means of the study, the mean values, offering a prediction to clinicians before implant procedures in patients with edentulous mandible, can be provided.

Materials and Methods

G*power, version 3.1.9.2 (Franz Faul, Universität Kiel, Germany) software was used to perform a priori power analysis. 58 patients would be enough to obtain significant difference with 80% confidence, 20% type I error, 80.63% test power and 0.567 effect size. Therefore, total 77 patients were included in this study. The study was conducted retrospectively and the pre-taken CBCT images of 39 male and 38 female patients with edentulous mandible aged 48-85 years were used. CH at 10 mm distal of the right mental foramen and alveolar CW at 3 mm apical of

the crest ridge in the same area were measured on coronal section of CBCT images (Figure 1). Measurements of crest dimensions were performed on coronal section by an oral and maxillofacial radiologist who has been analyzing CBCT images for 3 years. In CBCT images included in the study, images with bone lesion in the relevant site and of poor quality were not included in this study. This study was started after the University ethics committee approval was obtained for this study (approval number: YYU-2017/11/29-06).

The CBCT images of the patients were scanned with KaVo 3D eXam (Biberach, Germany) tomography equipment and eXamVision (KaVo Dental GmbH, Biberach, Germany) software was used to analyze the images. In this study, scan area of 16×13 cm, voxel resolution of 0.4 mm, scan time of 8.9 seconds, scan parameters of 18.54 mAs and 120 kVp were used.

SPSS (IBM SPSS Statistics 20.0; IBM Co., USA) software was used for the statistical analysis. Student's t-test and one-way ANOVA test were applied to assess the values. In order to estimate the reliability of single referee, the CH and CW values of 15 patients were re-measured in a period of 2 months and intraclass correlation coefficient (ICC) was determined. Moreover, the correlation between patient's age and crest dimensions was analyzed using the Pearson's correlation coefficient test.

Results

The mean CW values were measured as 6.66 ± 2.29 mm in males and as 5.67 ± 1.81 mm in females. The mean CH values were measured as 8.21 ± 4.25 and as 6.54 ± 3.29 in males and females, respectively. When the mean values obtained were compared by gender, no significant difference were observed in CH ($p=0.058$), whereas the mean of CW were significantly higher in males ($p=0.039$) (Table 1). Given the mean CW and CH values among the age groups of 48 and 85 years, no significant difference was observed among the groups ($p=0.586$, $p=0.465$, respectively) (Table 2, 3).

When the re-measured data of the patients were evaluated, it was found that there was an excellent reliability ($ICC=0.972$) between the CH values and good reliability ($ICC=0.814$) between the CW values. Given the correlation between patient's age and CW ($r=-0.047$, $p=0.687$) and CH ($r=-0.109$, $p=0.346$), it was found that there was a very weak negative and insignificant correlation.

Table 1. Comparison of crest width and height values according to gender

	Gender	Mean±SD	T test (p value)
CW (mm)	Male	6.66±2.29★	0.039
	Female	5.67±1.81	
CH (mm)	Male	8.21±4.25	0.058
	Female	6.54±3.29	

★p< 0.05; SD, Standard deviation; CW, crest width; CH, crest height

Table 2. Comparison of crest width values according to age groups

Group (Age range)	N	Mean±SD	ANOVA test (p value)
48-59	25	6.16±2.04A	0.586
60-69	24	6.51±1.93A	
70-85	28	5.89±2.34A	

A: There is no difference among same letters; N, number; SD, standard deviation

Table 3. Comparison of crest height values according to age groups

Group (Age range)	N	Mean±SD	ANOVA test (p value)
48-59	25	7.35±4.20A	0.465
60-69	24	8.12±3.50A	
70-85	28	6.78±3.91A	

A: There is no difference among same letters; N, number; SD, standard deviation

Discussion

Alveolar crest height in patients may be affected by morphological abnormalities such as deep bite, lateral open bite, and cheek sucking (15, 16). Moreover, a study (17) reported that different skeletal types, for example, long face or short face syndrome may affect the CH in patients with edentulous mandible. However, the presence of such anomalies in the patients was not examined in the study and only the patients with an appropriate amount of alveolar crest were included in the study.

Today, mental foramen and mandibular canal measurements are also made with panoramic radiographs in dental implant planning. With this technique, the mandibular canal is not always noticed in patients, because the ossifying osseous structure surrounding the nerve may disappear as it gets closer to the mental foramen (18). As is known, CBCT, which is allowing measurement precision and detailed examination of the mandibular canal structure with cross-sectional images, is quite helpful for dentists in critical cases. Moreover, coronal and axial cross-sectional images that cannot be obtained by panoramic radiography can be used to have a chance to measure alveolar CW.

In a study by Bressan et al. (19) on patients with edentulous mandible, the CH values were measured significantly higher in males, while mean CW values did not differ significantly according to gender. In

addition, it was found that age factor did not affect crest dimensions. In the study, only the CW of males were significantly higher than the mean values of females with 0.99 mm, and that patient's age had no effect on crest dimensions. In a study (20) investigating crest measurements by CBCT it was found that males had significantly higher values than females in mandibular CW measurements of dentate patients aged 13-27 years, and that increased age caused an increase in the CW values. Interpreting the results of such studies, it is clear that the selected patient age group or whether patients' jaws in the study are dentate or edentulous affects the correlation between crest dimensions and age and gender factors. In the study by Soikkonen et al. (21), alveolar crest resorption was significantly greater in females, and it was suggested that this resorption arised due to loss of estrogen in the postmenopausal period and loss of calcium in bone developing in hyperparathyroidism. Considering the results of various studies, it was found that the mean values of CH did not differ significantly according to the age groups, in line with the study (19, 21, 22). Zhang et al. (23) measured alveolar crests of 59 male and female patients in dentate and edentulous patterns. They reported that males had significantly thicker CW than females, and that the age factor had no significant effect on CW, which is compatible with the present study. Pramstaller et al. (24) used CT images of 24 patients, it was found that the CW and CH values of

edentulous patients did not differ significantly between male and female patients. The limitations of the study are the absence of data on the patients' systemic diseases, no knowledge of the patients' duration of edentulousness, and the inclusion of only patients in a particular region. In addition to this study, it will be useful to analyze the correlation between systemic disease and crest dimensions by means of a study measuring the edentulous crest dimensions of patients with different systemic patients and determining which disease has a significant effect on crest dimensions.

Since the study was retrospective, the male/female patients' possible systemic diseases or habits, such as smoking, could not be included. Therefore, the effects of the mentioned factors on crest dimensions can be evaluated in a different study. In this study, it was found that advanced age did not affect crest dimensions, and the CW of males were significantly higher than the mean values of females. Also, the crest dimensions of each patient should be evaluated by three-dimensional imaging techniques before dental implant surgery.

References

- Sullivan RM. Implant dentistry and the concept of osseointegration: a historical perspective. *J Calif Dent Assoc* 2001; 29: 737-745.
- Çakır M, Karaca İR. İmplant Uygulamaları İçin Kret Koruma Teknikleri. *Atatürk Üniv Dış Hekim Fak Derg* 2015; 25: 107-118.
- Chen ST, Wilson Jr TG, Hammerle C. Immediate or early placement of implants following tooth extraction: review of biologic basis, clinical procedures, and outcomes. *Int J Oral Maxillofac Implants* 2004; 19: 12-25.
- Jahangiri L, Devlin H, Ting K, Nishimura I. Current perspectives in residual ridge remodeling and its clinical implications: a review. *J Prosthet Dent* 1998; 80: 224-237.
- Lekovic V, Kenney E, Weinlaender M, et al. A bone regenerative approach to alveolar ridge maintenance following tooth extraction. Report of 10 cases. *J Periodontol* 1997; 68: 563-570.
- Del Castillo PdVJ, Chamorro PM, Cebrián CJ. Repositioning of the inferior alveolar nerve in cases of severe mandibular atrophy. a clinical case. *Med Oral Patol Oral Cir Bucal* 2008; 13: 778-782.
- Adell R, Lekholm U, Rockler B, Brånemark P-I. A 15-year study of osseointegrated implants in the treatment of the edentulous jaw. *Int J Oral Surg* 1981; 10: 387-416.
- Stellingsma K, Raghoobar GM, Stegenga B. The extremely resorbed mandible: a comparative prospective study of 2-year results with 3 treatment strategies. *Int J Oral Maxillofac Implants* 2004; 19: 563-577.
- Enislidis G, Wittwer G, Ewers R. Preliminary report on a staged ridge splitting technique for implant placement in the mandible: a technical note. *Int J Oral Maxillofac Implants* 2006; 21: 445-449.
- Basa S, Varol A, Turker N. Alternative bone expansion technique for immediate placement of implants in the edentulous posterior mandibular ridge: a clinical report. *Int J Oral Maxillofac Implants* 2004; 19: 55-558.
- Scipioni A, Bruschi GB, Calesini G. The edentulous ridge expansion technique: a five-year study. *Int J Periodontics Restorative Dent* 1994; 14: 451-459.
- Sethi A, Kaus T. Maxillary ridge expansion with simultaneous implant placement: 5-year results of an ongoing clinical study. *Int J Oral Maxillofac Implants* 2000; 15: 491-499.
- Fokas G, Vaughn VM, Scarfe WC, Bornstein MM. Accuracy of linear measurements on CBCT images related to presurgical implant treatment planning: A systematic review. *Clin Oral Implants Res* 2018; 29: 393-415.
- Koç A, Kavut İ, Uğur M. Assessment of Buccal Bone Thickness in The Anterior Maxilla: A Cone Beam Computed Tomography Study. *Cumhuriyet Dent J* 2019; 22: 102-107.
- Beckmann S, Kuitert R, Prah-Andersen B, Segner D, The R, Tuinzing D. Alveolar and skeletal dimensions associated with overbite. *Am J Orthod Dentofacial Orthop* 1998; 113: 443-452.
- Kuitert R, Beckmann S, van Loenen M, Tuinzing B, Zentner A. Dentoalveolar compensation in subjects with vertical skeletal dysplasia. *Am J Orthod Dentofacial Orthop* 2006; 129: 649-657.
- Kuc J, Sierpińska T, Golebiewska M. The relationship between facial morphology and the structure of the alveolar part of the mandible in edentulous complete denture wearers. A preliminary study. *Acta Odontol Scand* 2015; 73: 57-66.
- Klinge B, Petersson A, Maly P. Location of the mandibular canal: comparison of macroscopic findings, conventional radiography, and computed tomography. *Int J Oral Maxillofac Implants* 1989; 4: 327-332.
- Bressan E, Ferrarese N, Pramstraller M, Lops D, Farina R, Tomasi C. Ridge Dimensions of the Edentulous Mandible in Posterior Sextants: An Observational Study on Cone Beam Computed Tomography Radiographs. *Implant Dent* 2017; 26: 66-72.
- Fayed MMS, Pazera P, Katsaros C. Optimal sites for orthodontic mini-implant placement assessed by cone beam computed tomography. *Angle Orthod* 2010; 80: 939-951.

21. Soikkonen K, Ainamo A, Xie Q. Height of the residual ridge and radiographic appearance of bony structure in the jaws of clinically edentulous elderly people. *J Oral Rehabil* 1996; 23: 470-475.
22. Yüzügüllü B, Gulsahi A, Imirzalioglu P. Radiomorphometric indices and their relation to alveolar bone loss in completely edentulous Turkish patients: a retrospective study. *J Prosthet Dent* 2009; 101: 160-165.
23. Zhang W, Tullis J, Weltman R. Cone Beam Computerized Tomography Measurement of Alveolar Ridge at Posterior Mandible for Implant Graft Estimation. *J Oral Implantol* 2015; 41: 231-237.
24. Pramstraller M, Schincaglia GP, Vecchiatini R, Farina R, Trombelli L. Alveolar ridge dimensions in mandibular posterior regions: a retrospective comparative study of dentate and edentulous sites using computerized tomography data. *Surg Radiol Anat* 2018; 40: 1419-1428.