

The Visceral Slide Test For The Prediction of Abdominal Wall Adhesions: A Prospective Cohort Study

Isil Safak Yildirim¹, Dogukan Yildirim^{2*}, Seyma Yesiralioglu¹, Sefik Eser Ozyurek¹

¹Department of Obstetrics and Gynecology, Bagcilar Training and Research Hospital, Istanbul, Turkey

²Department of Obstetrics and Gynecology, Kanuni Sultan Suleyman Training and Research Hospital, Istanbul, Turkey

ABSTRACT

An accurate prediction of abdominal wall adhesions would be extremely beneficial to help preventing injuries during the initial abdominal entry. Our aim was to evaluate the accuracy of the visceral slide test in predicting abdominal wall adhesions before surgery.

One hundred fifty-five patients who underwent benign gynecologic surgery were prospectively enrolled. Seventy patients (45%) had previous baseline risk factors including abdominal surgeries, episodes of pelvic inflammatory disease [PID] or peritonitis. Eighty-five patients (55%) had no risk for intraabdominal adhesions. On the day of surgery, patients underwent the visceral slide test in five zones of the abdomen using ultrasonography, and a prediction of adhesions was made for each zone. Ultrasound findings were then compared with intraoperative visualization.

A total of 112 laparotomies and 43 laparoscopies were performed. The use of the visceral slide test for the prediction of adhesions showed an overall accuracy of 86.5%, a sensitivity of 78.6%, a specificity of 88.2, a positive predictive value of 59.5%, and a negative predictive value of 94.9%.

Our study suggests that the visceral slide test is an easy, non-invasive, and reliable method for predicting abdominal wall adhesions in women undergoing benign gynecologic surgery.

Key Words: Visceral slide, ultrasonography, abdominal wall adhesions, laparoscopy

Introduction

Despite the advancements in surgical technology, intraabdominal adhesions following surgery is still a major concern for surgeons. Any inflammatory process in the abdomen, including pelvic inflammatory disease (PID), endometriosis or peritonitis, may also lead to intraabdominal adhesions. Adhesions are pathologic formations of fibrous scar tissue that adhere to abdominal wall or structures with the potential to cause serious morbidity and complicate subsequent operations (1).

An accurate prediction of intraabdominal adhesions would be extremely beneficial to help preventing injuries during the initial abdominal entry. For this purpose, transabdominal ultrasonography has been used to determine intraabdominal adhesions. In 1991, Sigel et al. proposed a technique by observing the sliding movement of the abdominal contents for the detection of the intraabdominal adhesions (2). Normally, the intraabdominal organs slide freely under the abdominal wall during normal respiration, a phenomenon named the "visceral

slide." A reduction or absence of visceral slide is suggestive of underlying abdominal wall adhesions. Thus, the visceral slide test could assist with preoperative surgical planning for laparoscopy or laparotomy.

In this prospective cohort study, we evaluated the use of the visceral slide test for the detection of intraabdominal adhesions and compared the results with intraoperative findings in women undergoing benign gynecologic surgery.

Materials and Methods

Local ethics board approval was granted for the study. The ethics standards of the 1975 Declaration of Helsinki as revised in 2000 were followed. We performed a prospective cohort study of patients who underwent laparoscopic or open gynecologic procedures for benign indications in Bagcilar Training and Research Hospital between March 2017 and May 2018.

One hundred fifty-five patients were scheduled to undergo a laparotomy (112 patients, 72.3%) or laparoscopy (43 patients, 27.7%). Seventy (45%)

*Corresponding Author: Dogukan Yildirim, Halkali Merkez mah. Avrupa Konutlari 3 Sitesi 10/58, Kucukcekmece, Istanbul, Turkey
E-mail: dogukanyildirim@yahoo.com, Phone: 0(506) 328 43 83

Received: 12.10.2018, Accepted: 28.11.2018

Table 1. Patient characteristics

Variable	Data
Number of patients, n	155
Age, mean (SD)	43.3 (8.9)
BMI, mean (SD)	28.9 (6.1)
Parity, median (range)	2 (0-12)
Comorbidity, n (%)	21 (13.5)
Any risk factor for adhesions, n (%)	70 (45.2)
Patients with reduced visceral slide, n (%)	37 (23.9)

BMI: body mass index, SD: standard deviation

patients had previous baseline risk factors including abdominal surgeries, episodes of PID or peritonitis. Eighty-five (55%) patients had no risk for intraabdominal adhesions. Patient characteristics (age, body mass index [BMI], obstetric history, surgical history, history of PID, indication for surgery, and comorbidities) are summarized in (Table 1). All patients were evaluated with an ultrasonographic examination of visceral sliding on the day of surgery. The ultrasound study was performed in the supine position using a Mindray DP-9900 Plus (Mindray, Shenzhen, China) 7.5 MHz abdominal transducer placed in a sagittal plane at the umbilicus and four abdominal quadrants; right upper quadrant (RUQ), right lower quadrant (RLQ), left upper quadrant (LUQ), left lower quadrant (LLQ). All ultrasound examinations were performed by the same investigators (ISY and SY) whose results were blinded to the surgeons. Thus, the findings of the ultrasound did not affect the decision of the type of surgery (laparotomy or laparoscopy), the types of incisions or the primary trocar sites. A conventional gel was used between the transducer and the skin to achieve acoustic coupling. Each patient was examined during normal breathing with an exaggerated inspiratory effort. Several cycles of respiration were observed, focusing on the deep layer of the abdominal wall to identify the vertical movement of the intraabdominal viscera. With uncooperative patients, visceral slide was induced by manual ballottement of the abdominal wall. Visceral slide was measured using an electronic scale. Abnormal visceral slide (negative test) was defined as no movement of the viscera or movement less than 1 cm. The comparison of the ultrasound findings

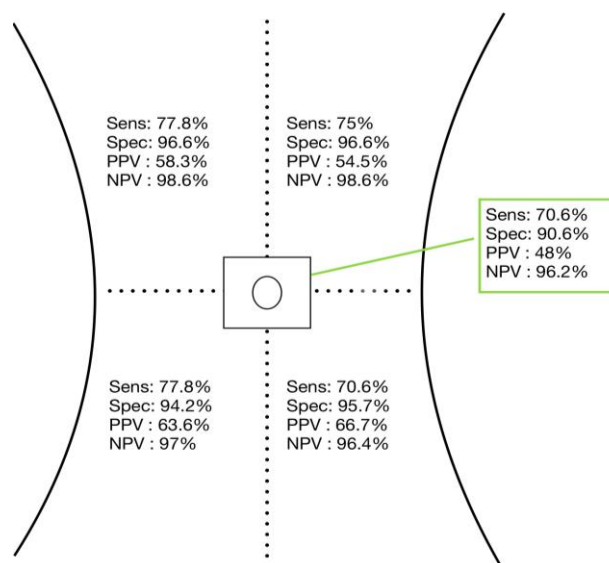


Fig. 1. Sensitivity (Sens), specificity (Spec), positive predictive value (PPV) and negative predictive value (NPV) of the visceral slide test in five zones

and surgery results was performed by a third independent investigator who was not involved in the ultrasound examination or the surgery.

The sample size calculation was based on a previous study with an incidence of 27% to 67% for adhesions after laparotomy (3). Based on the lower incidence (27%), the sample size required for an alpha of 0.05 and a power of 80% was 70 participants with a high risk of intraabdominal adhesions.

Results

All 155 enrolled patients underwent surgery, of which 112 patients (72.3%) underwent laparotomy, and 43 patients (27.7%) had a laparoscopy. The mean age of the women was 43.3 ± 8.9 years. The mean BMI was 28.9 ± 6.1 kg/m². In 35.5% of the patients (n=55), the BMI was ≥30 kg/m². Indications for surgery in all groups included symptomatic uterine leiomyoma (n=61), persistent adnexal mass (n=35), abnormal uterine bleeding resistant to medical treatment (n=29), adenomyosis-endometriosis (n=16), and desire for tubal ligation (n=14). Seventy (45%) patients had risk factors for intraabdominal adhesions (previous abdominal surgery, episodes of PID or peritonitis). Eighty-five (55%) patients had no risk factors for intraabdominal adhesions.

When all five predefined zones were grouped, reduced visceral slide (<1cm) with ultrasound was seen in 37 of 155 (23.8%) women. The resulting sensitivity of the visceral slide test to detect any adhesion was 78.6% with a specificity of 88.2%,

Table 2. Ultrasound and operative findings for the five defined zones

Ultrasound Findings	Intraoperative Findings					
	Omental Adhesion (n=22)		Bowel Adhesion (n=6)		Absence of Adhesions (n=127)	
Reduced Visceral Slide <1cm (n=37)	16 (72.7%)	TP	6 (100%)	TP	15 (11.8%)	FP
Free Movement (n=118)	6 (27.3%)	FN	0	FN	112 (88.2%)	TN

TN: true negative, TP: true positive, FN: false negative, FP: false positive

with positive (PPV) and negative predictive values (NPV) of 59.5% and 94.9%, respectively. For only the umbilical zone, visceral slide demonstrated a sensitivity of 70.6%, specificity of 90.6%, PPV 48%, and NPV 96.2%. The results of the other four abdominal quadrants are presented in (Figure 1). The performance of the visceral slide test is summarized in (Table 2).

During surgery, surgeons found 28 adhesions in five defined zones, most of which consisted of omental adhesions (22 of 28, 78.6%). In 10 of 28 patients (35.7%), adhesions were isolated in one zone, and the remainder (n=18, 64.3%) had multiple zone adhesions. There were adhesions within the umbilical zone in 17 patients: 6 with bowel adhesions and 11 with omental adhesions. All of these six patients with bowel adhesions had undergone previous midline laparotomy incisions. The visceral slide test was able to detect all six bowel adhesions with a sensitivity of 100%, specificity of 79.2%, PPV 16.2%, and NPV 100%.

For subgroup analyses, all patients were divided into two groups as follows: group 1, 85 patients (55%) with no risk factors, and group 2, 70 patients (45%) with a risk factor for intraabdominal adhesions. Four of 28 adhesions were found in the no-risk group (group 1), consisting of only mild omental adhesions, with a prevalence of 4.7% (4 in 85 cases). Eighteen omental and six bowel adhesions were found in the high-risk group (group 2), with a prevalence of 34.3% (24 in 70 cases). The visceral slide test showed a sensitivity of 75% in group 1 vs. 79.2% in group 2, specificity 90.1% in group 1 vs 84.2% in group 2, PPV 27.3% in group 1 vs. 73.1% in group 2, and NPV 98.6% in group 1 vs. 88.6% in group 2.

A further subgroup that included only women with BMI >30 kg/m² (n=55, 35.4%) was also analyzed to assess the use of the visceral slide test in obese patients. The sensitivity of the visceral slide test was 80% with a specificity of 84.4%,

PPV 53.3% and NPV 95%. In the non-obese group (n=100, 64.5%), the results were comparable; sensitivity 77.8%, specificity 90.2%, PPV 63.6%, and NPV 94.9%.

There were two bladder injuries and one serosal bowel injury, all of which were repaired intraoperatively. None of them was related to the initial abdominal entry.

Discussion

Our study showed that preoperative ultrasound imaging of the visceral slide is highly reliable in predicting anterior abdominal wall adhesions, with a sensitivity of 78.6%, NPV of 94.9% and overall diagnostic accuracy of 86.5%.

Intraabdominal adhesions are mostly diagnosed intraoperatively. A suspicion of intraabdominal adhesions in the preoperative phase would improve planning of the entry site for laparoscopy or laparotomy. This concept is extremely important in laparoscopy because the initial entry is usually performed blindly. Blind trocar entry may lead to complications, and 75% to 82% of laparoscopy-related complications result from the insertion of the first trocar (4,5). Complications are seen mainly in patients who have a risk factor for intraabdominal adhesions. In 68.9% of cases of bowel injuries in laparoscopy, adhesions or previous abdominal surgeries were documented in a literature review (6). The ability to predict the presence of such adhesions would help the surgeon to minimize the risk of entry complications in laparoscopy.

Ultrasonography is a simple and non-invasive imaging modality available for all surgical specialties. The visceral slide test using ultrasonography was first described by general surgeons for detecting intraabdominal adhesions in 1991 (2). Kolecki et al. found that the sensitivity and specificity of the visceral slide test to predict abdominal wall adhesions were 90 and

92%, respectively (7). Steitz et al. reported similar results, however, both studies were conducted in a non-blinded fashion (8). Kothari et al. were the first to report blinded data on the visceral slide test. They found a sensitivity of 43%, specificity of 90%, and overall accuracy of 78% (9).

Tu et al. used the visceral slide test in gynecologic surgeries and found a sensitivity of 86% and specificity of 91% below the umbilicus (10). In a recent study, Nezhat et al. found that a preoperative visceral slide test had a sensitivity of 83.3%, specificity of 96.8%, PPV of 71.4%, and NPV of 98.54% (11). In contrast to these studies, we found a seemingly lower sensitivity (70.6%) and PPV (48%), but similar specificity (90.6%) and NPV (96.2%) for the umbilical zone. However, the visceral slide test was able to detect all six bowel adhesions in the periumbilical area with a sensitivity of 100%, specificity of 79.2%, PPV of 16.2%, and NPV of 100%.

In a multicenter study, Aubé et al. showed that the visceral slide test had a sensitivity and specificity of 79% and 75%, respectively (12). They speculated that the low sensitivity and specificity of their results were because the majority of their patients were overweight. However, in our subgroup analysis, we found similar results between obese (BMI >30 kg/m²) and non-obese patients.

We had 15 cases of false-positive results; a restricted visceral slide test on ultrasonography but no adhesions in surgery. Seven (46.7%) of the 15 patients were obese, and 7 (46.7%) had a risk factor for intraabdominal adhesions. Two (67%) of three patients with very large myomas exceeding the pelvis also had a false-positive tests. We think that the use of the visceral slide test is not helpful in patients with very large myomas. We had 6 cases of false-negative results; free movement of the visceral organs but adhesions in surgery. Four (67%) of the 6 patients had risk factors for intraabdominal adhesions, and 3 (50%) were obese.

In laparoscopic surgery, the umbilicus is the most common insertion site for the first trocar. If adhesions are predicted in the periumbilical area, surgeons will generally choose Palmer's point (upper left quadrant) as the site of initial trocar entry, because this point is thought to be free of adhesions or go for a laparotomy. We found that the visceral slide test with ultrasonography was highly specific and had a high NPV for both areas, with a specificity of 90.6% and NPV of 96.2% for the umbilical zone, and a specificity of 96.6% and NPV of 98.6% for Palmer's point. This indicates

that a positive test (free visceral movement) corresponds to a high probability that the patient has no abdominal wall adhesions. However, it should be pointed out that 47% of our patients (8 of 17) with surgically confirmed umbilical adhesions also harbored LUQ adhesions. Therefore, both the umbilicus and Palmer's point should be evaluated separately to provide a safe entry site for laparoscopic operations.

The strength of this study was its prospective and blinded design. The first blinding was between the investigators and surgeons so that the visceral slide test did not affect the surgeons' choice on the type of surgery. The second blinding was achieved in the validation period by allowing a third independent investigator to make the comparison of the ultrasound and surgery results. There were also limitations to the study. We had difficulties in differentiating bowel and omental adhesions with the visceral slide test, we were only able to document whether the test was positive or negative.

The visceral slide test is an easy, non-invasive and reliable method for predicting abdominal wall adhesions. This useful test could help gynecologic surgeons choose a safe entry site to the abdomen and may reduce entry-related complications in laparoscopy or laparotomy.

Conflict of interest: The authors report no conflict of interest related with this study.

Acknowledgements: The authors have received no funding for this article.

References

1. Randall D, Fenner J, Gillott R, et al. A Novel Diagnostic Aid for Detection of Intra-Abdominal Adhesions to the Anterior Abdominal Wall Using Dynamic Magnetic Resonance Imaging. *Gastroenterol Res Pract* 2016; 2016: 2523768.
2. Sigel B, Golub RM, Loiacono LA, et al. Technique of ultrasonic detection and mapping of abdominal wall adhesions. *Surg Endosc* 1991; 5: 161-165.
3. Brill AI, Nezhat F, Nezhat CH, Nezhat C. The incidence of adhesions after prior laparotomy: a laparoscopic appraisal. *Obstet Gynecol* 1995; 85: 269-272.
4. Molloy D, Kaloo PD, Cooper M, Nguyen TV. Laparoscopic entry: a literature review and analysis of techniques and complications of primary port entry. *Aust N Z J Obstet Gynaecol* 2002; 42: 246-254.

5. Champault G, Cazacu F, Taffinder N. Serious trocar accidents in laparoscopic surgery: a French survey of 103,852 operations. *Surg Laparosc Endosc* 1996; 6: 367-370.
6. van der Voort M, Heijnsdijk EA, Gouma DJ. Bowel injury as a complication of laparoscopy. *Br J Surg* 2004; 91: 1253-1258.
7. Kolecki RV, Golub RM, Sigel B, et al. Accuracy of viscera slide detection of abdominal wall adhesions by ultrasound. *Surg Endosc* 1994; 8: 871-874.
8. Steitz HO, Meyer G, Schildberg FW. Ultrasonography of adhesions prior to laparoscopic procedures after previous abdominal operations. In: Farthmann EH, Meyer C, Richter HA (eds.). *Current aspects of laparoscopic colorectal surgery*. Springer, New York 1997; 210-216.
9. Kothari SN, Fundell LJ, Lambert PJ, Mathiason MA. Use of transabdominal ultrasound to identify intraabdominal adhesions prior to laparoscopy: a prospective blinded study. *Am J Surg* 2006; 192: 843-847.
10. Tu FF, Lamvu GM, Hartmann KE, Steege JF. Preoperative ultrasound to predict infraumbilical adhesions: a study of diagnostic accuracy. *Am J Obstet Gynecol* 2005; 192: 74-79.
11. Nezhat CH, Dun EC, Katz A, Wieser FA. Office visceral slide test compared with two perioperative tests for predicting periumbilical adhesions. *Obstet Gynecol* 2014; 123: 1049-1056.
12. Aubé C, Pessaux P, Tuech JJ, et al. Detection of peritoneal adhesions using ultrasound examination for the evaluation of an innovative intraperitoneal mesh. *Surg Endosc* 2004; 18: 131-135.