

Cough-induced rib fracture: A case report

Aysel Sünnetçioğlu^{a,*}, Abdussamet Batur^b

^aDepartment of Chest Diseases, Yuzuncu Yil University Faculty of Medicine, Van, Turkey

^bDepartment of Radiology, Yuzuncu Yil University Faculty of Medicine, Van, Turkey

Abstract. Coughing is a crucial defense mechanism that prevents the entry of foreign material into the tracheobronchial tree. It is generally self-limited and uncomplicated, but complications may develop especially when the cough is violent and paroxysmal. Rib fractures are one of these complications. In this case report, we describe a cough-induced rib fracture

Key words: Cough, rib fracture, chest pain

1. Introduction

Coughing is an important defense mechanism that prevents the entry of foreign material into the tracheobronchial tree and clears excessive secretions from the lung. It is a complex reflex response to the stimulation of the cough receptors of the lung (1). Paroxysmal and violent coughing is associated with many complications such as syncope, bradycardia, pneumomediastinum, pneumothorax, incontinence, muscle rupture, lung herniation through intercostal spaces, and rib fractures (2-4). In this report, we describe a patient who sustained a rib fracture as a result of violent coughing.

2. Case report

A 48-year old male patient applied to the chest diseases polyclinic with a cough and severe chest pain. The patient had been coughing for 20 days, but a sudden stabbing pain developed 3 days ago after a violent cough. The patient had no history of chest trauma. No chronic diseases or osteoporosis was present in the patient. The patients' vitals were as follows: pulse: 82/min, arterial blood pressure: 130/70 mmHg, finger saturation at room temperature: 97% and body temperature: 36.9 C. The right side of the chest was tender with palpation. No rales or rhonchi were heard. The other systemic examinations were normal. A fracture on the anterior of the

eighth rib was identified in the posterior-anterior lung radiograph (Figure 1). The posterior-anterior lung radiograph of 7 days ago was normal. The patient was prescribed anti-inflammatories, antitussives and antibiotics.

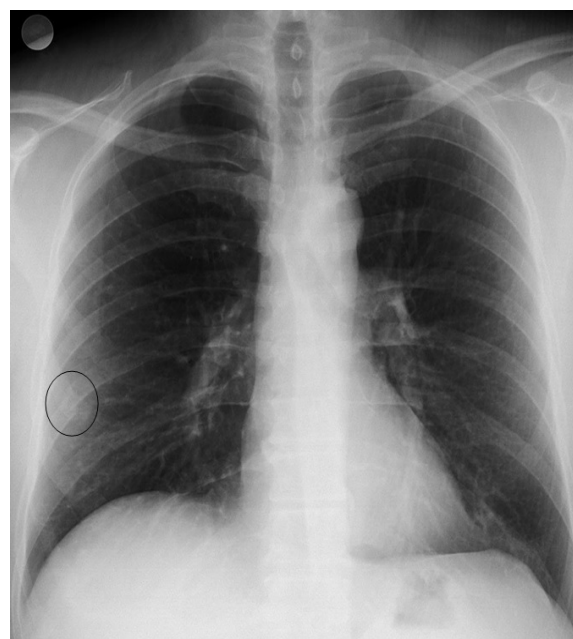


Fig. 1. A fracture on the anterior of the eighth rib was identified in the posterior-anterior lung radiograph.

3. Discussion

Cough is a defense mechanism of the lower respiratory tract. Cough is generally self-limited and uncomplicated but can be associated with complications, particularly when it is paroxysmal and violent. The most frequent complication is rib fracture (5). These fractures are likely to be related to recurrent mechanical stress to the ribs caused by coughing (6). When the force of the cough is greater than the elastic limit of the ribs,

*Corresponding Author: Aysel Sünnetçioğlu MD.

Department of Chest Diseases, Yuzuncu Yil University, Faculty of Medicine, Van, Turkey

Phone: + 90 (507) 113 05 81

Fax: + 90 (432) 216 75 19

E-mail: izciaysel@myynet.com

Received: 23.06.2015

Accepted: 11.11.2015

the cough can cause a fracture over the most vulnerable location, the costochondral junction. A second mechanism invokes an opposing force from the muscle attached to the same rib. This happens during violent coughing when the serratus anterior moves the ribs superiorly and laterally and the external oblique contracts to pull the ribs into medial alignment. According to previous studies, cough induced rib fractures occur most frequent on the lateral aspect of the fifth through ninth ribs (5-7). Hanak et al. (6) investigated cases of cough induced rib fractures for 9 years and in 85% of the patients, chronic cough for 3 weeks was detected.

The typical manifestations of rib fracture include localized pain in the chest wall, worsening discomfort during chest wall movement, and tenderness over the chest wall with palpation. Chest roentgenograms are sufficient for the diagnosis of cough-induced rib fractures in most cases (5,6). In addition, bone scintigraphy may reveal abnormal radionuclide concentrations on hidden fractures (8). Chest roentgenogram was able to reveal rib fracture in our cases.

The treatment of spontaneous rib fractures consists of pharmacological treatment and close clinical observation. If complications such as pneumothorax, pleural effusion, subcutaneous emphysema, hemothorax, hematoma, diaphragmatic rupture, lung hernia are observed tube thoracostomy and surgical intervention may be indicated (2,9).

As a result, rib fractures are rare complications induced by coughs. In patients that present with

persistent coughing and sudden chest pain, cough-induced rib fractures should be considered in the differential diagnosis of chest pain.

References

1. Irwin RS, Rosen MJ, Braman SS. Cough a comprehensive review. *Arch Intern Med* 1977; 137: 1186-1191.
2. George L, Rehman SU, Khan FA. Diaphragmatic rupture: A complication of violent cough. *Chest* 2000; 117: 1200-1201.
3. Ayers DE, LeFeuwer A, Barker P. Surgical repair of intercostal pulmonary hernia secondary to cough induced rib fracture. *J R Nav Med Serv* 2002; 88: 55-56.
4. Chiba Y, Kakuta H. Massive subcutaneous emphysema, pneumomediastinum and spinal epidural emphysema as complications of violent coughing: a case report. *Auris Nasus Larynx* 1995; 22: 205-208.
5. Roberge RJ, Morgenstern MJ, Osborn H. Cough fracture of the ribs. *Am J Emerg Med* 1984; 2: 513-517.
6. Hanak V, Hartman TE, Ryu JH. Cough-induced rib fractures. *Mayo Clinic Proceedings* 2005; 80: 879-882.
7. Daniel R, Naidu B, Khalil-Marzouk J. Cough-induced rib fracture and diaphragmatic rupture resulting in simultaneous abdominal visceral herniation into the left hemithorax and subcutaneously. *Eur J Cardiothorac Surg* 2008; 34: 914-915.
8. Suga K, Nishigauchi K, Fujita T, et al. Bone scintigraphy in two cases with cough related stress fractures of rib. *Kaku Igaku* 1992; 29: 495-499.
9. De Maeseneer M, De Mey J, Debaere C, Meysman M, Osteaux M. Rib fractures induced by coughing: An unusual cause of acute chest pain. *Am J Emerg Med* 2000; 18: 194-197.