

# Effects of Technological Innovations on Reconstructive Microsurgery; Flap Monitoring Systems After Free Tissue Transfer, Yesterday and Today

Özlem Çolak<sup>1</sup> , Özay Özkaya Mutlu<sup>2</sup> , Kadri Özer<sup>3</sup> 

<sup>1</sup>Department of Plastic Surgery, University of Health Sciences, Okmeydanı Training and Research Hospital, İstanbul, Turkey

<sup>2</sup>Private Practice, İstanbul, Turkey

<sup>3</sup>Department of Plastic Surgery, Aydın State Hospital, Aydın, Turkey

## Abstract

Microvascular anastomoses for the transfer of viable tissue are the basis of reconstructive surgery, and they are used to treat a broad spectrum of clinical problems. Recent advances in technology are promising in the improvement of microsurgery outcomes. The primary threat in reconstructive surgery is anastomotic vascular thrombosis, which can lead to tissue loss with potentially destructive consequences. Postoperative monitoring of tissue perfusion is critical because early recognition of vascular compromise and a rapid surgical intervention are associated with tissue recovery. Conventional flap monitoring methods used to be the primary means of monitoring during postoperative follow-up, but they were highly subjective and observer dependent. Medical devices introduced in flap monitoring have eliminated many of these shortcomings and have greatly improved this critical stage of reconstructive surgery. Although the features of the ideal monitoring device have been defined, there is no existing device that could meet all the currently expected requirements. In the near future, we are more likely to see further enhancement and clinical applications of existing technologies.

**Keywords:** Reconstructive surgery, microsurgery, flap monitoring, technology

## ORCID IDs of the authors:

Ö.Ç. 0000-0002-0201-1649;  
Ö.Ö.M. 0000-0001-6316-2347;  
K.Ö. 0000-0003-2966-6618

## Cite this article as:

Çolak Ö, Özkaya Mutlu Ö, Özer K. Effects of Technological Innovations on Reconstructive Microsurgery; Flap Monitoring Systems After Free Tissue Transfer, Yesterday and Today. Eur Arch Med Res 2018; 34 (Suppl. 1): S61-S65.

## Corresponding Author:

Özlem Çolak

## E-mail:

drozlemcolak@hotmail.com

**Received:** 05.11.2018

**Accepted:** 13.11.2018

**DOI:** 10.5152/eamr.2018.59244

Content of this journal is licensed under a Creative Commons Attribution-NonCommercial 4.0 International License.



## INTRODUCTION

Free flap was first introduced in the late 1950s, and it became a widely used tool in the reconstruction of large defects, with a success rate of up to 95% after the development of microsurgical techniques (1-4). Many etiologies, including cancer, trauma, infection, and congenital defects, may lead to microvascular reconstruction (5). For example, an amputated finger can be rescued only when the blood supply is restored by performing microvascular anastomoses in trauma patients who are admitted to our clinic and operated on after their informed consent forms are received (Figure 1). When the mastectomy is performed in women with breast cancer after obtaining their consent, the abdominal tissue is usually transferred to regenerate the breast (Figure 2). This technique has recently been used for tissue transfers such as facial and hand allotransplantation between different individuals (6, 7).

Along with the development of auxiliary flap monitoring techniques, the success rates, including a lower number of complications, increased efficiency, a shorter hospital stay, and improved overall results, have increased (8). This article summarizes current literature that supports the devices and protocols that are routinely used for postoperative free flap monitoring techniques and are planned to be used in the future.

## Flap Monitoring

The primary threat to reconstructive surgery is vascular thrombosis, which may occur in the anastomosis line due to some characteristics of the recipient. If surgery is not performed, tissue loss

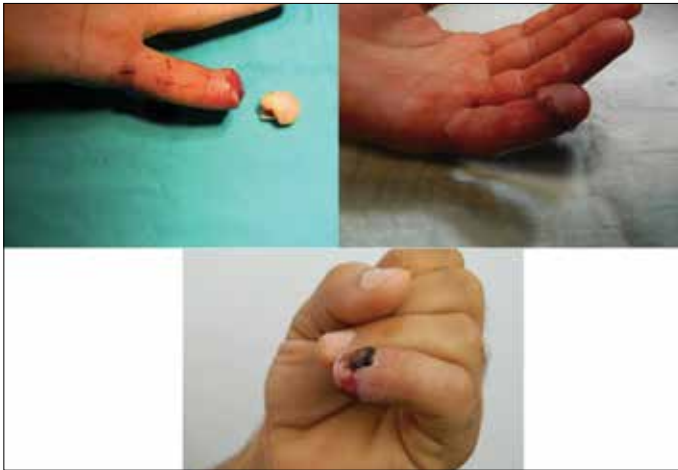

Figure 1. Restoration of blood flow after fingertip amputation and replantation in a trauma patient

accompanied by devastating consequences may occur. Since an early diagnosis of the vascular problem and the surgical intervention are closely related to the tissue recovery, postoperative monitoring of the perfusion of the transplanted tissue is extremely important.

Conventional flap monitoring methods include the clinical evaluation of the skin color, capillary filling, turgor, and flap temperature; however, these values are highly subjective and are observant dependent. The use of assistive technologies for flap perfusion and monitoring can provide early detection of possible complications. In 1975, Creech and Miller described the features of an ideal monitoring device as safe, fast, sensitive, reliable, and applicable to all flap types (9). In addition, the features that are expected from an ideal device are cost efficiency, ease of use, and continuous monitoring. While all these criteria appear to be reasonable, there are no existing devices that currently meet all these requirements.

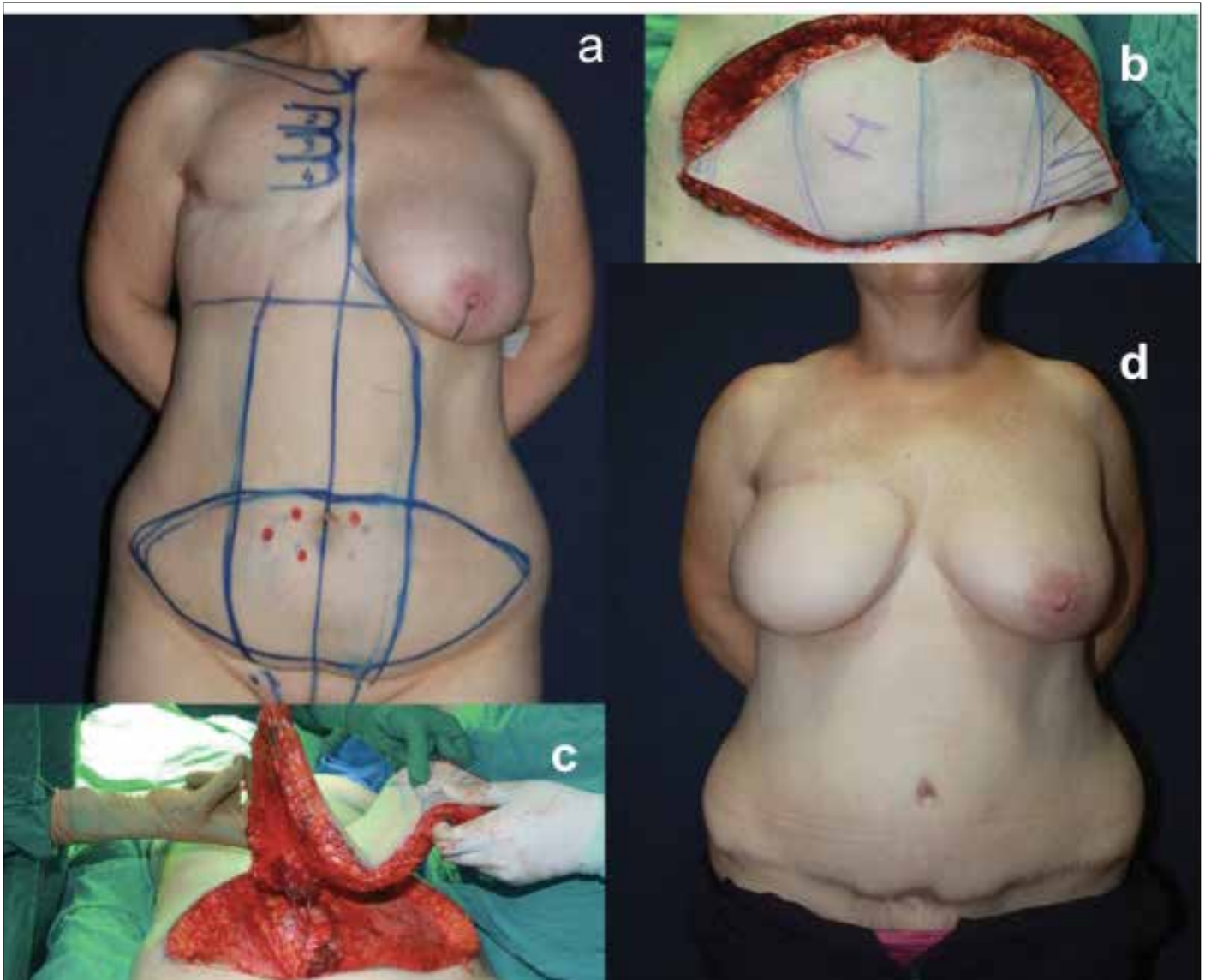
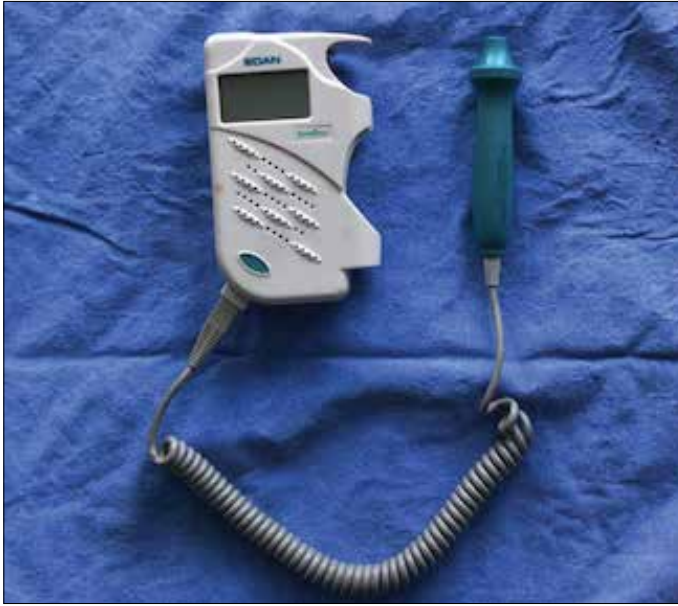

Figure 2. a-d. Microvascular breast reconstruction; (a) Planning of microvascular free tissue transfer from the abdomen in a patient undergoing mastectomy for left-side breast cancer; (b) Preparation of the abdominal tissue for transfer; (c) Vessels in which microvascular anastomosis will be performed for the transplantation of the abdominal tissue; (d) Postoperative image



**Figure 3. Hand Doppler**

Flap monitoring techniques can be classified according to the monitoring mechanism (vascular flow measurement according to tissue ischemia); time of use (intraoperative and postoperative); and invasiveness (invasive and noninvasive). The techniques monitoring the vascular flow include hand Doppler, implantable Doppler, color duplex ultrasonography, fluorescence angiography, and laser Doppler flowmeter (LDF). The techniques monitoring the tissue metabolism and ischemia are near-infrared spectroscopy and microdialysis. There are additional developing techniques such as thermal imaging, pH monitoring, transit-time volume flow measurement, and spatial frequency domain imaging (SFDI).

#### Hand Doppler

Acoustic Doppler sonography is the most commonly used method for free flap monitoring. Typically, it is used in accordance with physical examination. The most common type of this device is the one that is handheld, and it is connected with a probe to a central component containing the power and sound source (Figure 3). Handheld Doppler with a low-frequency continuous 8 mHz wavelength probe, which was first described by Karkowski and Buncke as a postoperative monitoring technique, is used to qualitatively determine the vascular flow (10). Since the distribution of arteries and vessels within the flap is not uniform, the probe is often applied to the flap surface before the surgery is completed, and the signal locations are then marked for postoperative monitoring. It is important to know that these surface signals generally represent the blood flow through smaller and more peripheral blood vessels close to the surface of the flap, but not the blood flow through the vessels involved in the microvascular anastomosis, which are generally embedded in the flap and cannot be accurately evaluated. It is also important that they cannot be evaluated with these handheld probes.

The advantages of hand Doppler include ease of use, noninvasiveness, and reusability. Its disadvantages are the difficulty in determining whether the signal source is from the vascular ped-

icle or from the recipient vessels, and the lack of quantitative measurement.

#### Color Duplex Ultrasonography

Color duplex ultrasound is a noninvasive flap monitoring technique that uses ultrasound to visualize microanastomosis vessels. The device consists of an ultrasound probe and a monitor that can be used in the radiology chamber or can be transported to the patient room. The person using the device first uses grayscale ultrasound to identify the static structures in the environment, such as postoperative fluid, and the vessels that have newly been anastomosed. Since the shift of ultrasound waves in the Doppler is in the audible range, and since different tones are assigned to different rates on the color scale, the flow through the anastomosis is visually noticeable (11). Often, the red color tints are used to indicate the current flowing toward the probe, and the blue color tints are used to indicate the current moving away from the probe. The use of this device requires a trained radiology technician, and a microsurgeon to assist with anatomical orientation, in addition to clinical radiologist.

The advantages of the device are that it is noninvasive, it can directly visualize the precise and quantitative characterization of in and outflow from the anastomotic openings of both vessels, and it can also be used in embedded flaps. Its disadvantage is that an experienced ultrasound technician or radiologist is needed to use the device.

#### Implantable Doppler

This device allows continuous monitoring of free flaps by applying the Doppler principle to an area adjacent to the microvascular anastomosis. It was first described by Swartz et al. in 1988, and little change has been made in its design so far (12). Implantable Doppler uses a 1 mm<sup>2</sup> piezoelectric crystal that acts as a 20 MHz ultrasonic Doppler probe. The probe is mounted on a 0.5-cm-wide silicone cuff, which is applied circumferentially around a blood vessel immediately distal to an anastomosis. The cuff is then secured to the two ends of the blood vessel using any of the variety of methods, including surgical clips, sutures, or fibrin glue (13). The probe and the cuff are connected to an audio and power source producing an audible signal through a wire coming out from the surgical incision and transmitting the Doppler signal. Once the postoperative monitoring is complete, the crystal and wire are easily separated from the cuff. The implantable Doppler can be applied to the artery, vein, or both if two devices are to be used. Many surgeons prefer to keep the device in venous anastomosis where both arterial and venous problems are more evident, rather than in arterial anastomosis where venous problems cannot be detected. The ability to make continuous measurements, ease of use, and the availability of embedded flaps are among the advantages of the device. The fact that it lacks quantitative measurement and that it is an invasive technique despite relatively simple mounting and removal are among the disadvantages.

#### Fluorescence Angiography

Infrared fluorescence angiography has recently been developed for the clinical use in microsurgery. The indocyanine green, a non-toxic dye, is injected into the vessel and circulated through the vascular system. It is then illuminated with laser that can be captured by a near-infrared camcorder, causing the stimulation

of the dye in the vascular system of the related tissue and then an infrared energy emission. A real time video visualization of the vascular flow is displayed on a monitor. Fluorescence angiography samples include the fluorescence-assisted resection and exploration (FLARE) imaging system (Curadel, Marlborough, MA) and the SPY fluorescence imaging system (Stryker, Kalamazoo, MI) (Figure 4) (14,15). Smaller systems such as PDE Neo (Mitaka, Denver, CO) have been developed. The advantages of fluorescent angiography include direct visualization of vascular flow and tissue perfusion. An instant data capture, a high cost of the device, and a relative contraindication in patients with iodine allergy and renal failure are among the disadvantages. In addition, although frequent use is possible, the large size and cost of the device limit the bedside use of the monitor postoperatively.

### Laser Doppler Flowmeter

The reflection of coherent laser light in Doppler is used to measure the blood flow velocity in LDF. The laser light is emitted from a source, and the back-scattered light, through which the frequency shift is determined, is collected. This frequency shift is proportional to the number and speed of the red blood cells in the measured area. The measurements are expressed as relative velocities, usually in the form of mL/min/100 g, which are the abbreviated LDF units (16,17). It is a noninvasive and continuous imaging device that evaluates perfusion and shows the flow within the tissue capillaries rather than pedicles. Periflux System 5000



Figure 4. SPY fluorescence imaging system

(Perimed, Kings Park, NY) and O2C (Oxygen to See, LEA Medizintechnik, Giessen, Germany) are the examples of this technology. It was first described in 1977 by Stern et al. to assess skin perfusion (18). Early device configurations included LDFs that were physically connected to a separate personal computer to automatically and continuously record data. Existing device models for flap monitoring have concentrated the data-processing component into a much smaller portable unit. The probes are applied to the flap surface and radiate the laser light to a depth of 8 mm (19). The reflected light is collected by the same probe, and the frequency shift between the transmitted and the reflected light is calculated to display a numerical flow value (20). The advantages of the device are that it provides a continuous monitoring, it is noninvasive, and it allows the recognition of possible flap failures prior to clinical findings. In contrast to other devices, it has various probes that can be applied to various types of tissues, including skin, muscle, and internal organ flaps. A high cost, the inability to discriminate arterial and venous pathology, sensitivity to small movements, relative value reporting, and the lack of a critical threshold to demonstrate the flap failure are among the disadvantages.

### Near-Infrared Spectroscopy

In this technique, a source emits the light of a given wavelength toward an object, and a detector measures the decrease in light intensity and scattering. Based on the characteristic absorption spectrum, the concentration of a particular chromophore can be determined. The spectroscopic devices used for free flap monitoring generally use near-infrared light (650-900 nm) that can penetrate to a depth of 20 mm with a light source and a detector located within a single probe. The probe is easily applied and fixed using an adhesive wrap or suture (21). The chromophores of light spectrum in human tissues for this region are deoxygenated (Hb) and oxygenated hemoglobin (HbO<sub>2</sub>) (22). The sum and rate of these two measurements can be used to calculate the relative changes in the total hemoglobin concentration and oxygen saturation (StO<sub>2</sub>), the two most commonly reported values by tissue spectrometry devices. ViOptix T.Ox (ViOptix, Newark, CA) is among the commercial examples of near-infrared spectroscopy. The advantages of the device are that it provides a continuous monitoring, it is noninvasive, it is less sensitive to motion (different from a LDF), and it allows the detection of the possible flap failures before the clinical findings. Its disadvantages are that it has a high cost, it cannot distinguish between an arterial and venous pathology, and it reports the relative values rather than the absolute ones.

### Microdialysis

Microdialysis, used for the first time in 1998 by Rödmark et al. in flap monitoring, is an invasive technique that allows intermittent flap monitoring (23). A regional blood flow disorder causes a decrease in tissue oxygen, which requires transition to anaerobic metabolism. Thus, an increase in the concentration of anaerobic metabolic products indicates local hypoperfusion and ischemia. Microdialysis evaluates the concentration of these products in the regional tissue with the dialysis membrane placed in the subcutaneous, adipose, or intramuscular tissue of the flap by inserting a sterile double-lumen microdialysis catheter. The physiological fluid delivered through the catheter along the dialysis membrane is balanced by the interstitial fluid surrounding the catheter on either side of the membrane. Thus, the collected liquid sample

reflects the composition of the interstitial fluid and the tissue concentration of metabolites, such as glucose, lactate, and pyruvate, which are shown numerically and graphically via a monitor, can be analyzed at the bedside. Ischemia is characterized by low glucose, high lactate, an increased lactate/pyruvate ratio, and high glycerol. The fact that it can be used in embedded flaps can be considered among the advantages.

To improve free flap reliability and flap monitoring, the interest in innovations and technology is increasing every day. Although high-resolution thermal imaging cameras are often quite expensive, the newly developed FLIR ONE (FLIR Systems, Inc., Wilsonville, OR) is a lower-resolution, smartphone-compatible miniature thermal camera with less than \$200. Similar to microdialysis, pH monitoring also permits an increase in hydrogen ion concentration, indications of regional anaerobic metabolism developing secondary to flap ischemia, and thus a mediator for vascular compromise. Transit-time volume flow measurement is a non-Doppler-based ultrasound technology that does not provide a continuous display, that detects physiological parameters of blood vessels and particularly vascular flow and resistance, and that improves cardiac surgery results when previously used to assess the coronary artery bypass quality. Finally, the SFDI is a new, infrared, and wide-field imaging technology with a mechanism similar to FLARE, but it is noninvasive and does not require dye injection. Although these devices equipped with new technological developments have a limited clinical use, they are commercially under development.

## CONCLUSION

Traditional monitoring methods are cheap, accurate, and easy to follow. However, the implantable Doppler system, LDF, and near-infrared spectroscopy are continuous methods that have been reported to detect the flap failure earlier than traditional methods and that appear to be the best monitoring techniques for most types of flaps currently. In addition, implantable Doppler and microdialysis techniques have been shown to be used successfully in embedded flaps. In the near future, there is a high likelihood of further development of existing technologies and their clinical applications. For example, new products that combine two existing technologies (such as spectroscopy and LDF) and that transmit devices with additional data sources (such as heat, acoustic Doppler) to mobile devices in real time will be developed.

**Peer-review:** Externally peer-reviewed.

**Author Contributions:** Concept - Ö.Ö., Ö.Ç.; Design - Ö.Ç., K.Ö.; Supervision - Ö.Ö., K.Ö.; Resources - K.Ö., Ö.Ç.; Data Collection and/or Processing - Ö.Ç., K.Ö., Ö.Ö.; Literature Search - K.Ö., Ö.Ç.; Writing Manuscript - Ö.Ç., K.Ö., Ö.Ö.; Critical Review - Ö.Ö., K.Ö.

**Conflict of Interest:** The authors have no conflicts of interest to declare.

**Financial Disclosure:** The authors declared that this study has received no financial support.

## REFERENCES

- Chen Y, Shen Z, Shao Z, Yu P, Wu J. Free Flap Monitoring Using Near-Infrared Spectroscopy: A Systemic Review. *Ann Plast Surg* 2016; 76: 590-7. [\[CrossRef\]](#)
- Nakatsuka T, Harii K, Asato H, Takushima A, Ebihara S, Kimata Y, et al. Analytic review of 2372 free flap transfers for head and neck reconstruction following cancer resection. *J Reconstr Microsurg* 2003; 19: 363-8. [\[CrossRef\]](#)
- Smit JM, Acosta R, Zeebregts CJ, Liss AG, Anniko M, Hartman EH. Early reintervention of compromised free flaps improves success rate. *Microsurgery* 2007; 27: 612-6. [\[CrossRef\]](#)
- Jones NF, Jarrahy R, Song JI, Kaufman MR, Markowitz B. Postoperative medical complications-not micro-surgical complications-negatively influence the morbidity, mortality, and true costs after microsurgical reconstruction for head and neck cancer. *Plast Reconstr Surg* 2007; 119: 2053-60. [\[CrossRef\]](#)
- Chao AH, Meyerson J, Podovski SP, Kocak E. A review of devices used in the monitoring of microvascular free tissue transfer. *Expert Rev Med Devices* 2013; 10: 649-60. [\[CrossRef\]](#)
- Siemionow M, Ozturk C. An update on facial transplantation cases performed between 2005 and 2010. *Plast Reconstr Surg* 2011; 128: 707-20. [\[CrossRef\]](#)
- Shores JT, Imbriglia JE, Lee WP. The current state of hand transplantation. *J Hand Surg Am* 2011; 36: 1862-7. [\[CrossRef\]](#)
- Karinja SJ, Lee BT. Advances in flap monitoring and impact of enhanced recovery protocols. *J Surg Oncol* 2018; 1-10. [\[CrossRef\]](#)
- Ferguson RE Jr, Yu P. Techniques of monitoring buried fasciocutaneous free flaps. *Plast Reconstr Surg* 2009; 123: 525-32. [\[CrossRef\]](#)
- Karkowski J, Buncke HJ. A simplified technique for free transfer of groin flaps, by use of a Doppler probe. *Plast Reconstr Surg* 1975; 55: 682-6. [\[CrossRef\]](#)
- Stone CA, Dubbins PA, Morris RJ. Use of colour duplex Doppler imaging in the postoperative assessment of buried free flaps. *Microsurgery* 2001; 21: 223-7. [\[CrossRef\]](#)
- Swartz WM, Jones NF, Cherup L, Klein A. Direct monitoring of microvascular anastomoses with the 20-MHz ultrasonic Doppler probe: an experimental and clinical study. *Plast Reconstr Surg* 1988; 81: 149-61. [\[CrossRef\]](#)
- Smit JM, Werker PM, Liss AG, Enajat M, de Bock GH, Audolfsson T, et al. Introduction of the implantable Doppler system did not lead to an increased salvage rate of compromised flaps: a multivariate analysis. *Plast Reconstr Surg* 2010; 125: 1710-7. [\[CrossRef\]](#)
- Lee BT, Matsui A, Hutteman M, Lin SJ, Winer JH, Laurence RG, et al. Intraoperative near-infrared fluorescence imaging in perforator flap reconstruction: current research and early clinical experience. *J Reconstr Microsurg* 2010; 26: 59-65. [\[CrossRef\]](#)
- Lee BT, Hutteman M, Gioux S, Stockdale A, Lin SJ, Ngo LH, et al. The FLARE intraoperative near-infrared fluorescence imaging system: a first-in-human clinical trial in perforator flap breast reconstruction. *Plast Reconstr Surg* 2010; 126: 1472-81. [\[CrossRef\]](#)
- Clinton MS, Sepka RS, Bristol D, Pederson WC, Barwick WJ, Serafin D, et al. Establishment of normal ranges of laser Doppler blood flow in autologous tissue transplants. *Plast Reconstr Surg* 1991; 87: 299-309. [\[CrossRef\]](#)
- Heller L, Levin LS, Klitzman B. Laser Doppler flowmeter monitoring of free-tissue transfers: blood flow in normal and complicated cases. *Plast Reconstr Surg* 2001; 107: 1739-45. [\[CrossRef\]](#)
- Stern MD, Lappe DL, Bowen PD, Chimosky JE, Holloway GA Jr, Keiser HR, et al. Continuous measurement of tissue blood flow by laser-Doppler spectroscopy. *Am J Physiol* 1977; 232: 441-8. [\[CrossRef\]](#)
- Hallock GG. Acoustic Doppler sonography, color duplex ultrasound, and laser Doppler flowmetry as tools for successful autologous breast reconstruction. *Clin Plast Surg* 2011; 38: 203-11. [\[CrossRef\]](#)
- Bonner R, Nossal R. Model for laser Doppler measurements of blood flow in tissue. *Appl Opt* 1981; 20: 2097-107. [\[CrossRef\]](#)
- Colwell AS, Craft RO. Near-infrared spectroscopy in autologous breast reconstruction. *Clin Plast Surg* 2011; 38: 301-7. [\[CrossRef\]](#)
- Xu RX, Young DC, Mao JJ, Povoski SP. A prospective pilot clinical trial evaluating the utility of a dynamic near-infrared imaging device for characterizing suspicious breast lesions. *Breast Cancer Res* 2007; 9: 88. [\[CrossRef\]](#)