



# Active Pulmonary Tuberculosis During Interferon Beta-1a Therapy in a Child with Multiple Sclerosis: A Case Report

© Pakize Cennetoğlu<sup>1</sup>, © Zeynep Öz<sup>1</sup>, © Canan Caymaz<sup>2</sup>, © Peren Perk Yücel<sup>1</sup>, © Pınar Arıcan<sup>1</sup>, © İhsan Kafadar<sup>1</sup>

<sup>1</sup>University of Health Sciences Turkey, Başakşehir Çam and Sakura City Hospital, Clinic of Pediatrics, Division of Pediatric Neurology, İstanbul, Turkey

<sup>2</sup>University of Health Sciences Turkey, Başakşehir Çam and Sakura City Hospital, Clinic of Pediatrics, Division of Pediatric Infectious Diseases, İstanbul, Turkey

## What is known on this subject?

Beta interferons are the first class of disease-modifying therapies, and their immunomodulatory effects are achieved by inhibiting T-cell activation and proliferation. However, modulation and interference with the patient's immune system may lead to adverse effects, such as increased susceptibility to infections.

## What this case report adds?

This is the first case of pulmonary tuberculosis in a pediatric patient with multiple sclerosis treated with interferon beta-1a, and effective treatment of serious infectious side effects was described.

## ABSTRACT

Interferon (IFN) beta ( $\beta$ ) is a potent anti-inflammatory and immunomodulatory agent that is used for treating patients with multiple sclerosis (MS). In this study, we present the case of a 15-year-old female patient diagnosed with MS and treated with IFN  $\beta$ -1a for six months who was referred to the emergency department with complaints of fatigue, fever, and coughing. She was diagnosed with pulmonary tuberculosis (TB). IFN  $\beta$ -1a therapy was stopped and anti-TB treatment was initiated. After nine months of therapy, she recovered from TB. This case presented with a rare side effect during the treatment of pediatric-onset MS with immunomodulatory drugs, demonstrating the importance of screening and close follow-up of patients with TB.

**Keywords:** Case report, interferon beta, multiple sclerosis, pediatric neurology, tuberculosis

## Introduction

Multiple sclerosis (MS) is a chronic autoimmune, inflammatory, and neurodegenerative disease of the central nervous system (CNS) (1). Pediatric-onset MS is used to describe patients who develop symptoms before 16 years of age (2). Immunomodulatory drugs are widely used for treating patients with MS to alleviate and

prevent the accumulation of neurological deficits, and their safety and tolerability are well established in adults; however, the available literature for pediatric-onset MS is limited (3). Beta-interferons ( $\beta$ -IFNs) are the first class of disease-modifying immunomodulatory agents used for treating pediatric-onset MS; however, modulation and interference with the patient's immune system may cause adverse effects, such as increased susceptibility



**Address for Correspondence:** Pakize Cennetoğlu MD, University of Health Sciences Turkey, Başakşehir Çam and Sakura City Hospital, Clinic of Pediatrics, Division of Pediatric Neurology, İstanbul, Turkey

**E-mail:** pakize.c@gmail.com **ORCID ID:** orcid.org/0000-0001-8963-68-70

**Received:** 23.05.2023 **Accepted:** 27.07.2023

to infections (4,5). In immunosuppressed patients, one of the most significant infections is tuberculosis (TB), but currently, there is limited information about the probability of latent TB in patients with MS (6,7). TB reactivation can occur because of the impact of immunosuppressive treatments on cellular immunity and depends on host susceptibility during exposure (8,9). Only 4 MS cases treated with IFN  $\beta$ -1b (10) and diagnosed with TB have been reported, and we did not find any reported active TB in pediatric MS patients treated with IFN  $\beta$ -1a. In this study, we present a case of active pulmonary TB in a pediatric MS patient treated with IFN  $\beta$ -1a. Informed consent was obtained from the patient's relatives.

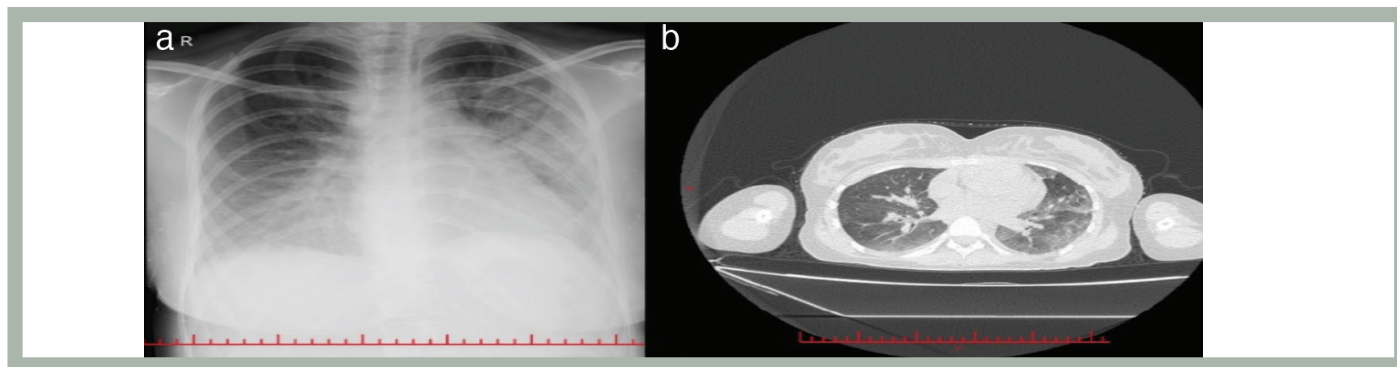
### Case Report

A 15-year-old female patient had been referred to our hospital two years ago with fatigue, headache, and difficulty walking complaints. She did not have any degenerative or neurological disorder in her medical and family history. In her physical examination, muscle strength in the lower extremities was 2/5, reflexes were normoactive, and there was no loss of sensation. Laboratory findings and CNS evaluation were normal. The immunoglobulin G index and oligoclonal band were negative. Magnetic resonance imaging (MRI) revealed bilateral diffuse nodular lesions in the left cerebellar peduncle, right cerebellar vermis, cerebral peduncle, and anterior pons. Based on clinical findings and MRI imaging, the patient was diagnosed with MS and treated with 1000 mg prednisone for 5 days, and the dose was tapered over 20 days. She was followed up without medication during remission. After eight months, she was referred to the emergency department because of recurring complaints of fatigue, weakness, and inability to walk. She was treated with prednisone at the same dose again because of her second attack. Her symptoms were alleviated, but her walking disability continued. After pulse steroid therapy, weekly intramuscular IFN  $\beta$ -1a therapy was

initiated because of progressive relapsing attacks. After ruling out acute infection, the tuberculin skin test (TST) was negative and the pulmonary X-ray was reported as normal. While she was treated with IFN  $\beta$ -1a therapy, she experienced symptoms including fatigue, fever, coughing, and vomiting during the sixth month of IFN- $\beta$  therapy after she had received two pulse steroid therapies eight months before. Physical examination revealed crepitant rales at 1/3 basal levels of the lungs. Pulmonary X-ray showed diffuse bronchopneumonic infiltration, and thoracic computed tomography showed diffuse centroacinar densities at the superior lobe of the left lung and minimal effusion in bilateral fissures (see Figure 1a, b). Sputum culture could not be obtained because of a lack of patient cooperation. *Mycobacterium tuberculosis* polymerase chain reaction was positive in two consecutive gastric aspirates. The TST was anergic. Complications related to susceptibility to infection developed in the patient who had a history of pulse steroid therapy and was currently undergoing IFN- $\beta$  therapy. The patient was diagnosed with TB. Her IFN- $\beta$  therapy was stopped, and anti-TB treatment was initiated with ethambutol 1.5 g/day, pyrazinamide 2 g/day, isoniazide 300 mg/day, and rifampicin 600 mg/day. Antibiogram confirmed *M. tuberculosis* susceptibility to all first-line drugs. After nine months of anti-TB therapy, she was free of TB, and during the anti-TB treatment period, the patient did not experience a relapse of MS.

### Discussion

In this article, we present the case of a pediatric-onset MS patient who was diagnosed with TB while receiving IFN therapy. We found that no similar pediatric case has been reported in the literature. The treatment of the patient was organized on the basis of the recommendations of the International Pediatric MS Study Group suggesting early disease-modifying treatment for pediatric patients with



**Figure 1.** (a) Pulmonary X-ray showing diffuse bronchopneumonic infiltration. (b) Thorax computed tomography showing diffuse centroacinar densities at the superior lobe of the left lung representing bronchopneumonic infiltration and minimal effusion in bilateral fissures

relapsing-remitting MS due to the benefits seen in adults. We were aware of the importance of long-term follow-up in this treatment, particularly in terms of side effects, such as activation or reactivation of latent infection, which are potentially most probably associated with drugs affecting cell-mediated immunity (8,11,12).

We diagnosed our patient with pulmonary TB, and when we reviewed the literature, we found that TB cases have been reported while treated with immunomodulatory drugs, including teriflunomide, cladribine, and alemtuzumab (13,14,15). Cohen et al. (16) reported two TB cases in >900 individuals treated with alemtuzumab in clinical trials. At the same time, they reported that none of the nearly 400 control patients treated with IFN developed TB (16).

The effects of IFN- $\beta$  were evaluated, and the reported side effects were flu-like syndrome and mild transient leucopenia (17). Gärtner et al. (18) reported a severe adverse effect rate of 11.9% (12 events), including benign intracranial hypertension, depression, and nephrotic syndrome, and all patients recovered.

TB cases under IFN  $\beta$ -1a among other therapies had not been reported in the literature until Sirbu et al. (10) described 4 cases of active pulmonary TB triggered by IFN  $\beta$ -1b therapy of MS. The onset of active TB was 28, 49, 35, and 46 years old, and the time between IFN-1b treatment initiation and TB was 12, 48, 36, and 84 months, respectively. IFN  $\beta$ -1b treatment was discontinued when active TB was confirmed and was resumed immediately after the cessation of TB treatment. One patient was diagnosed with TB again after 14 years (10). We diagnosed TB six months after the initiation of IFN therapy and discontinued it while she was receiving anti-TB therapy. After nine months of treatment, she was TB-free. Our limitations were that our case was a single case and our observation time was limited. When pediatric MS patients

treated with IFN- $\beta$  were evaluated, we did not encounter any reported TB cases, and there were many publications reporting that relapse rates were reduced in pediatric MS cases with the use of IFN- $\beta$ . Taking into consideration these benefits, we planned to reinstate therapy.

There is no definitive cure for pediatric-onset MS, but appropriate treatment should be initiated as soon as possible to slow disability and disease progression. Patients should also be monitored for drug-related side effects. This case report presents the effective treatment of TB diagnosed after the use of IFN- $\beta$  in a pediatric MS patient. Considering the favorable outcome of the use of IFN- $\beta$  therapy for treating patients diagnosed with pediatric MS, it is appropriate to control the patients for respiratory complaints, screening for latent TB, and follow-up for infectious pathologies.

### Acknowledgement

We used the CARE checklist when writing our report (19).

### Ethics

**Informed Consent:** Obtained.

**Peer-review:** Externally and internally peer-reviewed.

### Authorship Contributions

Surgical and Medical Practices: P.C., Z.Ö., P.P.Y., C.C., P.A., İ.K., Concept: P.C., Z.Ö., P.P.Y., C.C., P.A., İ.K., Design: P.C., Z.Ö., P.P.Y., C.C., P.A., İ.K., Data Collection or Processing: P.C., İ.K., Analysis or Interpretation: P.C., İ.K., Literature Search: P.C., İ.K., Writing: P.C., İ.K.

**Conflict of Interest:** No conflict of interest was declared by the authors.

**Financial Disclosure:** The authors declared that this study received no financial support.

## REFERENCES

1. Rodríguez Murúa S, Farez MF, Quintana FJ. The immune response in multiple sclerosis. *Annu Rev Pathol* 2022;17:121-139.
2. de Chalus A, Taveira M, Deiva K. Pediatric onset multiple sclerosis: future challenge for early diagnosis and treatment. *Presse Med* 2021;50:104069.
3. Waubant E, Banwell B, Wassmer E, et al. Clinical trials of disease-modifying agents in pediatric MS: opportunities, challenges, and recommendations from the IPMSSG. *Neurology* 2019;92:e2538-e2549.
4. Dhib-Jalbut S, Marks S. Interferon-beta mechanisms of action in multiple sclerosis. *Neurology* 2010;74(Suppl 1):S17-S24.
5. Luna G, Alping P, Burman J, et al. Infection risks among patients with multiple sclerosis treated with fingolimod, natalizumab, rituximab, and injectable therapies. *JAMA Neurol* 2020;77:184-191. Erratum in: *JAMA Neurol* 2021.
6. Pai M, Behr MA, Dowdy D, et al. Tuberculosis. *Nat Rev Dis Primers* 2016;2:16076.
7. Machuca I, Vidal E, de la Torre-Cisneros J, Rivero-Román A. Tuberculosis en pacientes inmunodeprimidos Tuberculosis in immunosuppressed patients *Enfermedades Infecciosas y Microbiología Clínica* 2018;36:366-374.
8. Epstein DJ, Dunn J, Deresinski S. Infectious complications of multiple sclerosis therapies: implications for screening, prophylaxis, and management. *Open Forum Infect Dis* 2018;5:ofy174.
9. Fragoso YD, Adoni T, Anacleto A, et al. How do we manage and treat a patient with multiple sclerosis at risk of tuberculosis? *Expert Rev Neurother* 2014;14:1251-1260.
10. Sirbu CA, Dantes E, Plesa CF, Docu Axelerad A, Ghinescu MC. Active pulmonary tuberculosis triggered by interferon beta-1b therapy of multiple sclerosis: four case reports and a literature review. *Medicina (Kaunas)* 2020;56:202.
11. Miller AE. Oral teriflunomide in the treatment of relapsing forms of multiple sclerosis: clinical evidence and long-term experience. *Ther Adv Neurol Disord* 2017;10:381-396.
12. Rommer PS, Milo R, Han MH, et al. Immunological aspects of approved MS therapeutics. *Front Immunol* 2019;10:1564.
13. O'Connor P, Wolinsky JS, Confavreux C, et al. Randomized trial of oral teriflunomide for relapsing multiple sclerosis. *N Engl J Med* 2011;365:1293-1303.
14. Gözübatık-Çelik RG, Öztürk M. A case of multiple sclerosis diagnosed with tuberculosis during teriflunomide therapy. *J Surg Med* 2022;6:535-536.
15. Rammohan K, Coyle PK, Sylvester E, et al. The development of cladribine tablets for the treatment of multiple sclerosis: a comprehensive review. *Drugs* 2020;80:1901-1928.
16. Cohen JA, Coles AJ, Arnold DL, et al. Alemtuzumab versus interferon beta 1a as first-line treatment for patients with relapsing-remitting multiple sclerosis: a randomised controlled phase 3 trial. *Lancet* 2012;380:1819-1828.
17. Basiri K, Etemadifar M, Derakhshan F, et al. Interferon-beta in pediatric multiple sclerosis patients: safety in short-term prescription. *Acta Med Iran* 2012;50:97-100.
18. Gärtner J, Brück W, Weddige A, et al. Interferon beta-1b in treatment-naïve paediatric patients with relapsing-remitting multiple sclerosis: two-year results from the BETAPAEDIC study. *Mult Scler J Exp Transl Clin* 2017;3:2055217317747623.
19. Gagnier JJ, Kienle G, Altman DG, et al. The CARE Guidelines: consensus-based clinical case reporting guideline development. *Glob Adv Health Med* 2013;2:38-43.