



Aortopulmonary Window: Classification, Associated Cardiac Anomalies, Treatment Options, and Clinical Outcome

● Fatma Sevinç Şengül¹, ● Perver Arslan¹, ● Pelin Ayyıldız¹, ● Erkut Öztürk²,
● İbrahim Cansaran Tanıdır², ● Okan Yıldız³, ● Sertaç Haydin³, ● Alper Güzeltaş¹

¹University of Health Sciences Turkey, İstanbul Mehmet Akif Ersoy Thoracic and Cardiovascular Surgery Training and Research Hospital, Clinic of Pediatric Cardiology, İstanbul, Turkey

²University of Health Sciences Turkey, Başakşehir Çam and Sakura City Hospital, Clinic of Pediatric Cardiology, İstanbul, Turkey

³University of Health Sciences Turkey, İstanbul Mehmet Akif Ersoy Thoracic and Cardiovascular Surgery Training and Research Hospital, Clinic of Pediatric Cardiovascular Surgery, İstanbul, Turkey

What is known on this subject?

Aortopulmonary window (APW) is a rare congenital heart defect. Symptoms depend on the size of the defect and associated anomalies. Treatment primarily involves surgical repair, with transcatheter closure reserved for select cases.

What this study adds?

The study highlights the importance of careful and systematic investigation for the detection of APW.

ABSTRACT

Objective: Aortopulmonary window (APW) is an uncommon congenital cardiac abnormality marked by a septation defect between the ascending aorta and pulmonary artery. This study aimed to define the clinical characteristics, diagnostic features, treatment strategies, and follow-up outcomes of pediatric patients diagnosed with APW.

Material and Methods: We retrospectively reviewed children diagnosed with APW from 2010 to 2023. Morphological APW typing of our patients was based on the classification that is settled by the Society of Thoracic Surgeons (STS) Congenital Heart Surgery Database Committee. The patients' demographic data, symptoms at admission, transthoracic echocardiography, cardiac computed tomography, management modalities, and follow-up data were evaluated.

Results: Twenty-five children were diagnosed with APW over the study period. Thirteen patients were male (52%), and the median age at presentation of the patients was three months (8 days-7.5 years). Two patients were diagnosed with coronary fistula by echocardiography at the first admission and were diagnosed with APW after catheterization. APW was detected in one patient while being operated on for large ventricular septal defect. According to the STS classification, 32% (n=8) of the patients were type III, 32% (n=8) were type I, 16% (n=4) were intermediate type, 12% (n=3) were type II, and 4% (n=1) were APW with aortic interruption. Associated cardiovascular malformations were in 76% (n=19) of the patients. Fifteen patients (60%) underwent surgery. Transcatheter closure of APW was performed in four patients (16%).

Conclusion: Detection of the APW requires careful and systematic investigation. Transcatheter closure can be performed in selected cases where the defect is suitable. Although rare, this defect, which can cause severe left-right shunting, should be kept in mind as a cause of pulmonary hypertension and unexplained cardiac dilation and should be investigated in patients whose cause cannot be determined.

Keywords: Aortopulmonary window, echocardiography, pulmonary hypertension, surgical treatment, transcatheter treatment



Address for Correspondence: Fatma Sevinç Şengül MD, University of Health Sciences Turkey, İstanbul Mehmet Akif Ersoy Thoracic and Cardiovascular Surgery Training and Research Hospital, Clinic of Pediatric Cardiology, İstanbul, Turkey

Phone: +90 212 692 20 00 **E-mail:** doganfatmasevinc@gmail.com **ORCID ID:** orcid.org/0000-0001-6791-3777

Received: 06.05.2023 **Accepted:** 09.06.2023

Introduction

Aortopulmonary window (APW) is an infrequent congenital cardiac defect characterized by incomplete partitioning of the aortic and pulmonary artery walls, leading to communication between these two structures. The presence of two separate semilunar valves helps distinguish APW from truncus arteriosus (1). This cardiac anomaly is a rare occurrence, accounting for approximately 0.2-0.6% of all congenital heart defects (2). Previous studies have reported a higher incidence of this cardiac anomaly among males (1,2,3). However, findings have been observed, with some reports indicating a female predominance (4,5), while others suggest a comparable occurrence rate between males and females (6). APW is frequently accompanied by other congenital heart defects. These associated anomalies may include ventricular septal defect (VSD), tetralogy of Fallot, transposition of the great arteries, double-outlet right ventricle, aortic interruption, aortic atresia, and in rare instances, coronary abnormalities (4,6,7).

In APW, intercommunication between the aorta and pulmonary artery causes a left-to-right (systemic-to-pulmonary) shunt, with the degree of shunting dictating the clinical course of the disease.

Shunting from the aorta to the pulmonary artery considerably increases during the neonatal period when pulmonary vascular resistance decreases. This causes congestive heart failure, which manifests as tachypnea, tachycardia, irritability, exhaustion, sweating, poor feeding or failure to thrive. If left untreated, pulmonary vascular obstructive disease may ensue at an early age, which is irreversible. Hence, early closure of large APWs is imperative to avert heart failure or pulmonary vascular disease. While surgery remains the standard treatment of choice (6,8), transcatheter APW closure can be a suitable alternative for patients with adequate rims (9,10).

The main aim of this study was to delineate the clinical attributes, diagnostic features, therapeutic approaches, and follow-up of pediatric patients diagnosed with APW.

Material and Methods

This retrospective analysis examined 25 patients who received an APW diagnosis at our clinic between 2010 and 2023, ranging from 8 days to 7.5 years. Before conducting the investigation, all ethical standards were met in accordance with the Declaration of Helsinki, with approval obtained from the University of Health Sciences Turkey, İstanbul Mehmet Akif Ersoy Thoracic and Cardiovascular Surgery Training and

Research Hospital Ethics Committee (March 2022/2022.03.19). Patient data, including demographic information, admission symptoms, transthoracic echocardiography, cardiac computed tomography (CT), management approaches, and follow-up information, were retrospectively evaluated.

Our patient cohort's morphological APW typing was determined based on the Society of Thoracic Surgeons (STS) Congenital Heart Surgery Database Committee classification (11) modified version of Mori et al.'s (3) classification. This classification system includes five subtypes:

1. APW with interrupted aortic arch,
2. Type I (proximal) APW, located above the sinus of Valsalva with a small inferior rim,
3. Type II (distal) APW, located at the highest part of the ascending aorta with a well-formed inferior rim and a small superior rim,
4. Type III (complete defect of the aortopulmonary septum) APW involves most of the ascending aorta with minimal superior and inferior rims,
5. Intermediate-type APW exhibits adequate superior and inferior rims and is more amenable to transcatheter closure.

According to the occurrence of concomitant cardiovascular anomalies, the study population was divided into two groups: the isolated APW group (n=6) and the complex APW group (n=19). Management strategies for the patients included surgical or transcatheter closure of the defect or medical treatment for pulmonary hypertension (PH) in patients with negative vasoreactivity. The regular outpatient follow-up was conducted at 3-6 months intervals. Follow-up was defined as the period from presentation to the last admission or death. Of the total patient cohort, three patients were lost to follow-up, one died after the operation, and the remaining 21 completed the follow-up period.

Statistical Analysis

The statistical analyzes were carried out using the SPSS 25 program (SPSS Inc., Chicago, IL, USA). For categorical data, frequencies and percentages are shown. The median value and interquartile range for variables with non-normal distributions were used, whereas the mean and standard deviation were used for variables with normal distributions.

Results

Demographic and Clinical Characteristics

From 2010 to 2023, 25 patients were diagnosed with APW in our clinic. The median age at presentation was three

months (8 days-7.5 years) and the median weight was 4.25 kg (2.1-21 kg). Of the patients, 13 were male (52%) and 12 were female (48%), resulting in a male-to-female ratio of 1.08 to 1. Congestive heart failure was the most common presenting symptom observed in 12 patients (50%), while 11 patients (44%) had heart murmurs. Two patients with significant PH and a negative vasoreactivity test were asymptomatic at admission. Diagnostic evaluations included echocardiography, cardiac catheterization (54.2%), and cardiac CT (48%) (Figure 1). Table 1 provides further details of the patients with APW.

We could visualize the AP window by 2D echocardiography in 22 (88%) patients. Two patients were initially diagnosed with a coronary fistula but were later diagnosed with APW after catheterization. In one patient, APW was detected during surgery for large VSD. In 21 patients with APW, there was significant left-to-right shunting that led to left atrial and ventricular dilatation. In most cases (83.3%), except for four, severe PH was observed, with pulmonary pressure almost equivalent to systemic pressures. Pulsed-wave and color flow Doppler demonstrated negative diastolic flow in the descending aorta due to diastolic left-to-right shunting through the APW.

One patient (4%) had APW with aortic interruption, while type III APW was noted in 32% (n=8) of the patients, type I in 32% (n=8), intermediate type in 16% (n=4), and type II in

12% (n=3), as per the STS classification. In addition, a patient had a 15 mm wide APW between the descending aorta and the main pulmonary artery at the level of the left subclavian artery.

In the cohort under investigation, a substantial proportion (76%, n=19) of the patients presented with associated cardiovascular malformations. Within the subset of patients with complex APW, the most frequent co-occurring cardiovascular malformations included topsy-turvy heart in 4 cases (16%), atrial septal defect in 4 cases (16%), and VSD in 4 cases (16%). An interrupted aortic arch type A and patent ductus arteriosus was in one patient (4%) with complex APW. Notably, one male patient (4%) with complex APW type I presented with abnormal coronary anatomy, specifically an anomalous origin of right coronary artery originating from the pulmonary artery (ARCAPA). Three patients (12%) displayed a right aortic arch; of these, two had an aberrant left subclavian artery (ALSA). Finally, a 7.5-year-old male patient within the complex APW cohort had tetralogy of Fallot as an associated cardiac defect.

Patients who were diagnosed with a topsy-turvy heart had a recognizable rotational abnormality affecting their heart and major arteries. Atrioventricular and ventriculoarterial connections on the left-sided heart showed concordance, and atrial configurations showed the typical superior-inferior

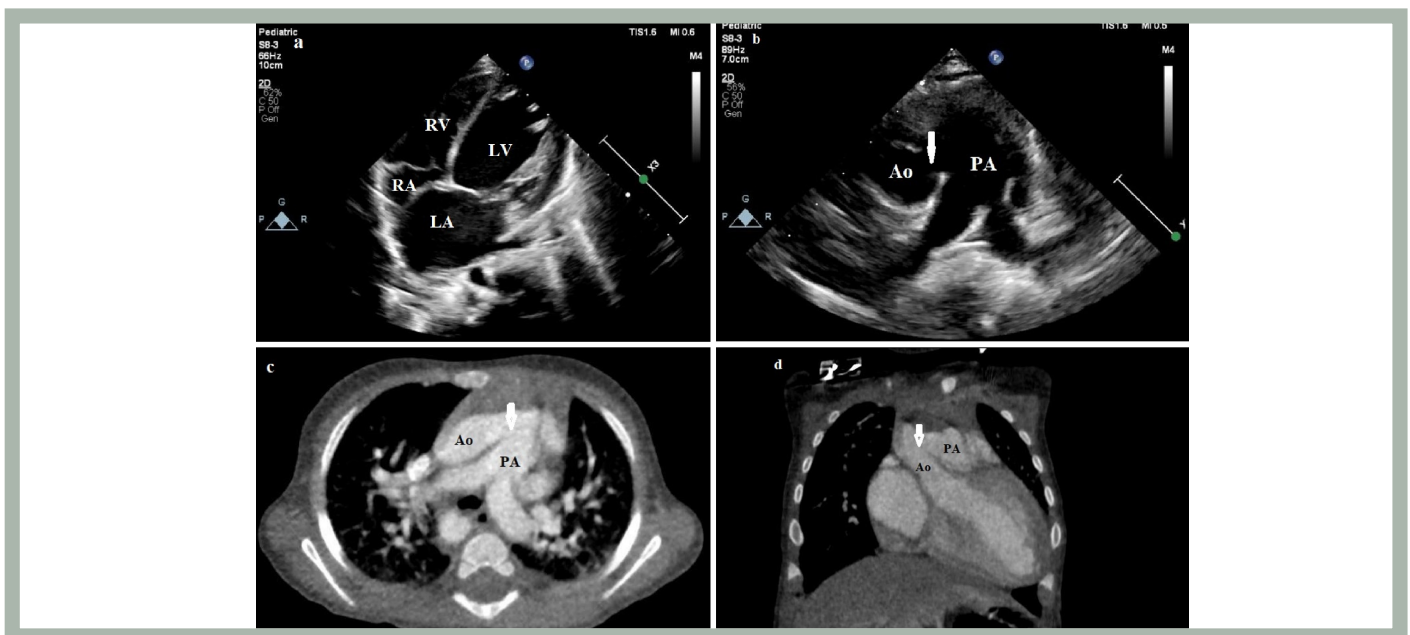


Figure 1. Echocardiography and computed tomography images of the patients with aortopulmonary window.

(a) Transthoracic echocardiography from apical four-chamber view shows enlarged left atrium (LA), and left ventricle (LV). (b) Transthoracic echocardiography from a parasternal short-axis view shows a wide defect between the ascending aorta (Ao) and the main pulmonary artery (PA) (white arrow). Computerized tomography shows a large aortopulmonary window (white arrow) in axial (c) and coronal (d) views.

RA: Right atrium, RV: Right ventricle

Table 1. Details of patients with aortopulmonary window

Patient	Age (month)	Weight (kg)	Symptom	Gender	Aortopulmonary window type	Concomitant cardiovascular anomalies	Management
1	3.5	4.5	Heart failure symptoms	M	III	Topsy-turvy heart	Surgery
2	4	3.8	Murmur	M	Intermediate type	Bicuspid aorta, right aortic arch, aberrant left subclavian artery	Transcatheter occlusion (ADO-I)
3	12	11	Murmur	F	I	Bicuspid aorta, aortic stenosis	Negative vasoreactivity
4	4	5	Heart failure symptoms	M	I	Left pulmonary artery stenosis	Surgery
5	3.5	21	None	F	Between the descending aorta and main pulmonary artery	Topsy-turvy heart	Negative vasoreactivity
6	15	6.5	Murmur	F	I	-	The decision of surgery was made. The patient lost to follow-up
7	6	5.3	Murmur	F	Intermediate type	Ventricular septal defect	Transcatheter occlusion (ADO-I)
8	72	18	Murmur	M	I	ARCAPA	Surgery
9	4	6.7	Heart failure symptoms	M	I	Ventricular septal defect	The decision of surgery was made. The patient lost to follow-up
10	5	5.5	Murmur	F	I	Right-sided aortic arch, aberrant left subclavian artery	Surgery
11	10 days	2.1	Murmur	F	Intermediate type	Atrial septal defect	Transcatheter occlusion (ADO-II)
12	8 days	2.3	Murmur	M	III	Atrial septal defect, a right-sided aortic arch, left persistent superior vena cava	Surgery
13	5	4	Heart failure symptoms	M	I	-	Surgery
14	2.5	3.7	Heart failure symptoms	M	II	-	Surgery
15	19 days	3	Heart failure symptoms	M	III	Topsy-turvy heart	Surgery
16	2.5	2.7	Murmur	M	I	Ventricular septal defect	Surgery
17	2	2.8	Heart failure symptoms	F	III	Atrial septal defect	Surgery
18	2	2.7	Heart failure symptoms	F	III	-	Surgery
19	20 days	3	Heart failure symptoms	F	III	Topsy-turvy heart	Surgery
20	8	8.3	Murmur	F	Intermediate type	-	Transcatheter occlusion (ADO-I)
21	90	20	None	M	II	Tetralogy of Fallot, absent left pulmonary artery	Negative vasoreactivity

Table 1. Continued

Patient	Age (month)	Weight (kg)	Symptom	Gender	Aortopulmonary window type	Concomitant cardiovascular anomalies	Management
22	20 days	3.5	Heart failure symptoms	M	III	Partial anomalous pulmonary venous return	The decision of surgery was made. The patient lost to follow-up
23	1	5	Heart failure symptoms	M	III	Ventricular septal defect	Surgery
24	1	3.4	Heart failure symptoms	F	APW with aortic interruption type A	Aortic interruption	Surgery
25	14 days	3	Murmur	F	I	-	Surgery

ADO: Amplatzer duct occluder, APW: Aortopulmonary window, ARCAPA: Anomalous origin of right coronary artery originating from the pulmonary artery, F: Female, M: Male

relationship of cardiac chambers. In addition, a significant connection was observed between the aorta and pulmonary artery (APW), which was associated with systemic pulmonary artery hypertension. Consistent with previous literature, all topsy-turvy heart cases were born to consanguineous parents, with two cases presenting as siblings. Among the patients analyzed, 23 out of 25 cases (92%) displayed no extracardial anomalies, while 8% of patients (two cases) demonstrated associated non-cardiac abnormalities, including Cornelia de Lange syndrome and tracheoesophageal fistula.

Management and Follow-up

Fifteen patients (60%) underwent surgery (patch repair of APW) at a median of 2.2 months (22 day-6 years) when they had a median weight of 3.6 kg (range, 2.7-18 kg). Among them, one male patient with abnormal coronary anatomy underwent reimplantation of ARCAPA during APW repair, and one patient with an interrupted aortic arch underwent patch augmentation of the aortic arch. A patient with esophageal compression resulting from an ALSA was successfully treated with ALSA transaction. Following surgical intervention, a patient diagnosed with a topsy-turvy heart manifested acute respiratory distress and left lung hyperinflation, leading to a rapid clinical deterioration. On the tenth postoperative day, venoarterial extracorporeal membrane oxygenation (ECMO) was initiated due to persistent respiratory failure. The patient of multiorgan failure and died on the 16th postoperative day, despite receiving six-day ECMO treatment (12). Transcatheter closure of APW was performed in four patients (16%) with aortopulmonary septal defects with adequate septal rims located at a safe distance from the aortic and pulmonary valves, coronary arteries, and pulmonary artery bifurcation at a median of 7.5 months (range: 4 months to 1.4 years) (Figure 2). No patient died during the intervention. Following a mean follow-up period of 33.6±28.3 months (4 months

to 79 months), all patients remained asymptomatic without requiring medication. In three patients with large defects, cardiac catheterization indicated high pulmonary vascular resistance, and the pulmonary vasoreactivity test with nitric oxide and 100% oxygen inhalation was non-reactive. Consequently, medical PH treatment was initiated. However, three patients required surgical intervention but were not followed up.

Discussion

This study provides an analysis of the clinical and diagnostic features, treatment approaches, and consequences of 25 pediatric patients with APW from a tertiary cardiac center. The APW is characterized by a deficient septum between the pulmonary artery and ascending aorta. Previous research has linked this anomaly with a diverse range of other cardiac malformations, including interrupted aortic arch, VSDs, topsy-turvy heart, tetralogy of Fallot, transposition of the great arteries, and coronary anomalies (4,7,13,14). More than half of our patients demonstrated associated cardiovascular abnormalities in our study. Among patients with complex APW, topsy-turvy heart, atrial septal defect, and VSD were the most frequently observed associated conditions (50%). In the case reports we reviewed, rare cardiovascular abnormalities were identified in association with APW, including a right aortic arch with an aberrant origin of the left subclavian artery (15), an isolated origin of the left subclavian artery from the left pulmonary artery (16), total abnormal pulmonary venous return (17), a right pulmonary artery originating from the ascending aorta (8), and crisscross pulmonary arteries (18). We have not encountered such rare abnormalities in our patients. Aortic stenosis, bicuspid aortic valve, bilateral superior vena cava, partially aberrant pulmonary venous return, and ARCAPA are a few unique coexisting cardiovascular problems that we did notice.

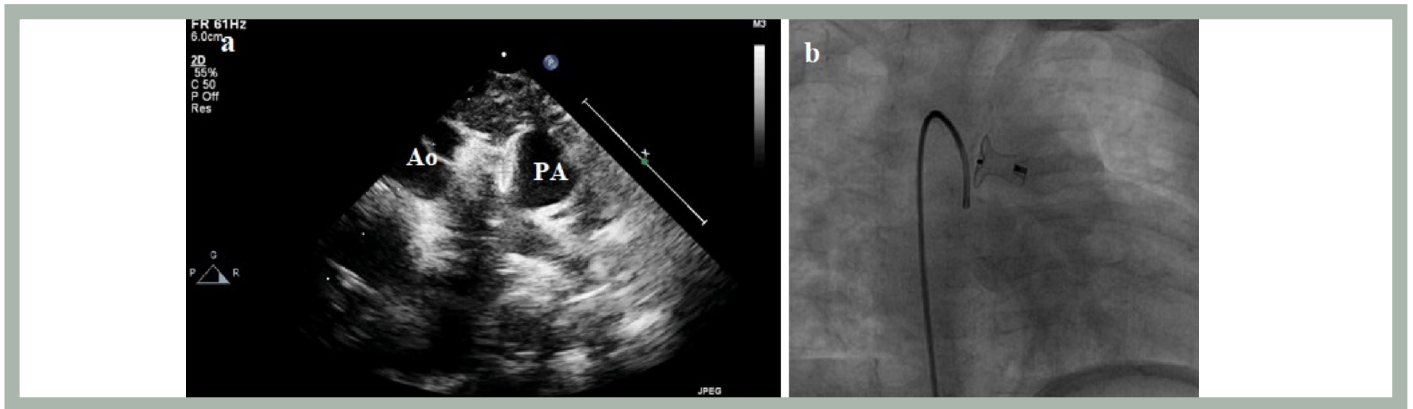


Figure 2. The transthoracic echocardiography (a) and catheter angiography (b) showed a good deployment of the device

Ao: Aorta, PA: Pulmonary artery

The clinical diagnosis of APW can be challenging in some cases and may require repeat echocardiography, diagnostic cardiac catheterization, or intraoperative assessment. Our study found that some patients were initially misdiagnosed but were later accurately diagnosed through further evaluation. One plausible explanation for the initial misdiagnosis of APW in a patient diagnosed during VSD surgery could be equalizing aortic and pulmonary pressure due to PH. Similarly, in two patients with a coronary fistula diagnosed during echocardiography, the small defect was mistaken for a fistula, and APW was only diagnosed during cardiac catheterization. In Kiran et al.'s (2) study, four patients were initially misdiagnosed with APW, and the factors contributing to this were analyzed. When there is unexplained heart failure, left heart dilatation due to a significant left-to-right shunt, and PH, an APW should be suspected. However, when the patient's clinical status and echocardiographic findings appear compatible, complex variants may be challenging to diagnose and easily overlooked. In addition to transthoracic echocardiography, this pathology can be demonstrated with the help of catheter or CT angiography and magnetic resonance imaging. Failure to diagnose APW patients can lead to irreversible obstructive changes in the pulmonary vascular bed, making the patient inoperable (19). In our cases, the late presentation of three patients with large defects (1 year, 3.5 years, and 7.5 years) highlights the importance of early detection and prompt intervention to avoid irreversible pulmonary obstructive changes, as all three had significant PH and negative vasoreactivity tests.

Important clinical factors in managing patients with APW include the size of the defect, the degree of left-to-right shunting into the pulmonary trunk, the presence of concurrent cardiovascular malformations, and the emergence

of PH. Early closure is imperative given the potential for rapid onset of congestive heart failure owing to high pulmonary blood flow. The conventional approach to treating APW is surgical intervention, and several studies (4,5,6,8,13,20) have examined surgical outcomes in this context. However, transcatheter closure may serve as a viable alternative in cases with no associated cardiovascular lesions and adequate rims. In fact, several studies (9,10,21) have documented successful experiences with transcatheter occlusion of APW. It is of utmost importance to carefully assess the location and size of the defect as well as the amount of superior and inferior rims present to minimize the risk of device-related complications such as embolization, coronary artery blockage, and damage to great vessels and valves. Additionally, the type of defect plays a critical role in determining the feasibility of transcatheter closure, with intermediate-type defects being more amenable to this approach.

Study Limitations

We acknowledge that our study has several limitations. Retrospective reviews of patients with APW were performed at a single center, which limits the generalizability of our findings. Additionally, our study was limited by the middle follow-up period.

Conclusion

In patients with AP windows, the current preferred method of diagnosis is echocardiography. Accurate diagnosis necessitates a meticulous and systematic evaluation. Small defects associated cardiac anomalies, or PH may present a diagnostic challenge, and the misdiagnosis is possible. Transcatheter closure can be considered in appropriate cases with sufficient septal rims. Although rare, this defect can

cause severe left-right shunt, leading to PH and unexplained cardiac dilation. Therefore, it should be considered a possible cause and investigated in patients whose underlying causes cannot be determined.

Ethics

Ethics Committee Approval: All ethical standards were met in accordance with the Declaration of Helsinki, with approval obtained from the University of Health Sciences Turkey, İstanbul Mehmet Akif Ersoy Thoracic and Cardiovascular Surgery Training and Research Hospital Ethics Committee (March 2022/2022.03.19).

Informed Consent: Retrospective study.

Peer-review: Externally and internally peer-reviewed.

Authorship Contributions

Surgical and Medical Practices: O.Y., S.H., Concept: F.S.Ş., Design: F.S.Ş., Data Collection or Processing: F.S.Ş., P.A., Analysis or Interpretation: E.Ö., İ.C.T., A.G., Literature Search: P.A., P.Ay., Writing: F.S.Ş.

Conflict of Interest: No conflict of interest was declared by the authors.

Financial Disclosure: The authors declared that this study received no financial support.

REFERENCES

- Allen HD, Shaddy RE, Penny DJ, Feltes TF, Cetta F. Moss and Adams' heart disease in infants, children, and adolescents: including the fetus and young adult. 9th ed. Philadelphia: Wolters Kluwer Health; 2016. p. 1-1900.
- Kiran VS, Singh MK, Shah S, John C, Maheshwari S. Lessons learned from a series of patients with missed aortopulmonary windows. *Cardiol Young* 2008;18:480-484.
- Mori K, Ando M, Takao A, Ishikawa S, Imai Y. Distal type of aortopulmonary window. Report of 4 cases. *Br Heart J* 1978;40:681-689.
- Bin-Moallim M, Hamadah HK, Alhabshan F, Alghamdi AA, Kabbani MS. Aortopulmonary window: types, associated cardiovascular anomalies, and surgical outcome. Retrospective analysis of a single center experience. *J Saudi Heart Assoc* 2020;32:127-133.
- Tiraboschi R, Salomone G, Crupi G, et al. Aortopulmonary window in the first year of life: report on 11 surgical cases. *Ann Thorac Surg* 1988;46:438-441.
- Moruno Tirado A, Santos De Soto J, Grueso Montero J, et al. Ventana aortopulmonar: valoración clínica y resultados quirúrgicos [Aortopulmonary window: clinical assessment and surgical results]. *Rev Esp Cardiol* 2002;55:266-270.
- Moore RA, Wallen WJ, Riggs KW, Morales DL. Three-dimensional printing in surgical planning: a case of aortopulmonary window with interrupted aortic arch. *Ann Pediatr Cardiol* 2018;11:201-203.
- He J, Yan D, Li B, Li H. Surgical repair of complex aortopulmonary window: a case study. *Braz J Cardiovasc Surg* 2018;33:424-427.
- Yıldırım A, Erdem A, Türkmen Karaağaç A. Transcatheter closure of the aortopulmonary window in a three-month-old infant with a symmetric membranous ventricular septal defect occluder device. *Türk Gogus Kalp Damar Cerrahisi Derg* 2021;29:101-104.
- Guzeltas A, Ugan Atik S, Tanidir IC. Transcatheter closure of aortopulmonary window in infants with amplatzer duct occluder-I. *Acta Cardiol Sin* 2021;37:305-308.
- Jacobs JP, Quintessenza JA, Gaynor JW, Burke RP, Mavroudis C. Congenital heart surgery nomenclature and database project: aortopulmonary window. *Ann Thorac Surg* 2000;69:S44-S49.
- Erek E, Guzeltas A, Ozturk NY, et al. Topsy-turvy heart: a very rare congenital rotational heart disease with tracheobronchial anomalies. *World J Pediatr Congenit Heart Surg* 2013;4:308-311.
- Dönmez YN, Aykan HH, Peker RO, Karagöz T, Doğan R. Association of interrupted aortic arch, aortopulmonary window with anomalous origin of the right pulmonary artery from the aorta, one-stage repair and postoperative outcomes: a case report. *Anatol J Cardiol* 2021;25:447-450.
- Hejazi Y, Mann G, Boudjemline Y, Udassi JP, Van Leeuwen G, Diab KA. Topsy-turvy heart with aortopulmonary window and severe airway Malacia: prenatal diagnosis and review of the literature. *Pediatr Cardiol* 2022;43:225-232.
- Zhu C, Wang T, Zhu Z, Liu K. Aberrant origin of left subclavian artery from the pulmonary artery and right aortic arch in an aortopulmonary window. *Interact Cardiovasc Thorac Surg* 2016;23:991-992.
- Agrawal V, Majid A, Jain I, Sheth M, Mishra A. Type II aortopulmonary window with isolated left subclavian artery from left pulmonary artery. *Braz J Cardiovasc Surg* 2020;35:402-405.
- Samaddar S, Bhatt D, Guleria M, Yadav DK, Gupta A. Total anomalous pulmonary venous connection masking an aortopulmonary window: a rare combination of defects. *Ann Pediatr Cardiol* 2018;11:322-324.
- Awasthy N, Jawid SA. Aortopulmonary window with crisscross pulmonary arteries: anatomically type 1, physiologically type 2. *J Cardiovasc Echogr* 2017;27:143-144.
- El Dick J, El-Rassi I, Tayeh C, Bitar F, Arabi M. Aortopulmonary window in adults: a rare entity leading to Eisenmenger syndrome. *Echocardiography* 2019;36:1173-1178.
- Talwar S, Siddharth B, Gupta SK, et al. Aortopulmonary window: results of repair beyond infancy. *Interact Cardiovasc Thorac Surg* 2017;25:740-744.
- Giordano M, Butera G. Percutaneous closure of an aortopulmonary window in a young adult patient: a case report of transcatheter closure with an occluder device. *Eur Heart J Case Rep* 2020;4:1-4.