



Magnetic Resonance Imaging Observations of Nearby Segment Deterioration in Isthmic and Degenerative Spondylolisthesis

Özlem Elibol¹, Utku Adilay²

¹University of Health Sciences Turkey, Kartal Dr. Lütfi Kırdar City Hospital, Clinic of Radiology, İstanbul, Turkey

²Balikesir University Faculty of Medicine, Department of Neurosurgery, Balikesir, Turkey

What is known on this subject?

Adjacent segments of degenerative spondylolisthesis exhibited more severe conditions in terms of disc space height, transverse area of the spinal dural sac, disc degeneration, and disc contour compared with isthmic spondylolisthesis.

What this study adds?

The study evaluated the level of degeneration in the neighboring upper and lower segments in lumbar isthmic and degenerative spondylolisthesis using magnetic resonance imaging.

ABSTRACT

Objective: The objective of the study was to evaluate the extent of deterioration in nearby upper and lower segments in lumbar isthmic and degenerative spondylolisthesis using magnetic resonance imaging (MRI).

Material and Methods: A retrospective evaluation was conducted on lumbar spine MRI scans of 51 individuals diagnosed with isthmic spondylolisthesis and 55 individuals diagnosed with degenerative spondylolisthesis. Adjacent intervertebral segments were evaluated for disc space height, thickness of ligamentum flavum, spinal dural sac transverse area, disc degeneration, facet hypertrophy, and disc contour.

Results: In all patients, both the upper segment ($p=0.003$) and lower segment ($p=0.024$) showed statistically significant differences between the two types of spondylolisthesis. Additionally, at the L4-L5 level (between the fourth and fifth lumbar vertebrae), there was a significant difference for the upper segment ($p=0.005$). There were statistically significant differences between the two types in the spinal dural sac transverse area in all patients for the upper segment ($p=0.004$), disc degeneration in all patients for the upper segment ($p=0.003$), disc contour in all patients for the upper segment ($p=0.014$), and L4-L5 level spondylolisthesis for the upper segment ($p=0.021$).

Conclusion: Disc space height measurements, spinal dual sac transverse area, disc degeneration, and disc contour were all worse in adjacent segments of degenerative spondylolisthesis compared with isthmic spondylolisthesis.

Keywords: Adjacent segment, degenerative spondylolisthesis, isthmic spondylolisthesis, lumbar vertebrae, magnetic resonance imaging



Address for Correspondence: Utku Adilay MD, Balikesir University Faculty of Medicine, Department of Neurosurgery, Balikesir, Turkey

Phone: +90 266 612 14 00 **E-mail:** utkuadilay@hotmail.com **ORCID ID:** orcid.org/0000-0003-4867-244X

Received: 22.05.2023 **Accepted:** 23.06.2023

Introduction

Spondylolisthesis was first described by Herbiniaux (1) in 1782. Spondylolisthesis is characterized by a shift in the uppermost part of the vertebral body as opposed to the lower part. Wiltse et al. (2) categorized spondylolisthesis into five classifications: congenital, isthmic, degenerative, traumatic, and pathological. Wiltse and Rothman (3) further distinguished the postsurgical type from the pathological type, resulting in a total of six distinct types of spondylolisthesis.

The degenerative and isthmic types are the most common forms of spondylolisthesis. The pathophysiology of spondylolisthesis is distinct in the degenerative and isthmic types. The effect of spondylolisthesis on adjacent segments is also distinguished between degenerative and isthmic types. The difference in degeneration in adjacent segments of degenerative and isthmic spondylolisthesis may also necessitate different surgical approaches for these pathologies. This study aimed to assess the level of degeneration in the neighboring upper and lower segments in cases of degenerative and isthmic spondylolisthesis using magnetic resonance imaging (MRI).

Material and Methods

Subjects

A retrospective evaluation was conducted on MRI scans of the lumbar spine in 51 individuals diagnosed with isthmic spondylolisthesis, and 55 individuals diagnosed with degenerative spondylolisthesis. These images were obtained from the Neurosurgery Department, Balıkesir University Faculty of Medicine, Balıkesir, Turkey. The inclusion criteria for the study were patients experiencing symptoms such as claudication, radiating pain, or low back pain leading them to undergo lumbar spine MRI. Individuals who had previously undergone lumbar surgery, had a vertebral fracture, or displayed spondylolisthesis in multiple segments or both types of spondylolisthesis were excluded from the study. This retrospective study was approved by the Clinical Research Ethics Committee, Balıkesir University Faculty of Medicine, Balıkesir, Turkey (decision no. 2023/64 and date: 10/05/2023).

Magnetic Resonance Imaging

We acquired sagittal T1-weighted images (repetition time/echo time msec: 758/12) and sagittal T2-weighted images (repetition time/echo time msec: 4,667/112) as part of the imaging process using Siemens Avanto 1.5T MRI (Siemens, Munich, Germany) and Philips Achieva 1.5T MRI (Philips, The Netherlands). The acquired images had a thickness of 4 mm,

with matrix dimensions of 168×512 for T1-weighted images and 180×512 for T2-weighted images.

Measurements

(a) Degree of Spondylolisthesis at the Index Level

The severity of spondylolisthesis was determined using the Meyerding System, which classifies degrees of translational displacement into grades 1 to 5 (4). These degrees of translational displacement were obtained from T2-weighted sagittal MRIs. Computed tomography of the lumbar spine was also used to verify the type of spondylolisthesis. Only patients with grade 1 Meyerding classification were included in this study, excluding Meyerding grades 2-5.

(b) Disc Space Height at the Superior and Inferior Adjacent Levels

The Farfan index was used to measure disc heights. To reduce errors, disc heights were determined from both the posterior and anterior regions of the disc space in sagittal T2-weighted images. The sum of these measurements was then divided by the anteroposterior diameters of the discs (5).

(c) Thickness of Ligamentum Flavum at the Superior and Inferior Adjacent Levels

The thickness of the ligamentum flavum was assessed using axial T1-weighted images at the midpoint of its length (6). This determined whether the interlaminar space had narrowed as the spinal motion segment lost height secondary to degeneration. In addition, we observed whether the ligamentum had folded into the spinal canal and thickened.

(d) Spinal Dual Sac Transverse Area at the Superior and Inferior Adjacent Levels

Lumbar spinal stenosis is characterized by the narrowing or constriction of the spinal canal, nerve root canal, or intervertebral foramina. The transverse area of the spinal dual sac was employed as an indicator for predicting canal stenosis. The cross-sectional area of the vertebral canal was measured at both the upper and lower adjacent levels.

(e) Degeneration of the Discs in the Neighboring Upper and Lower Levels

The severity of degeneration in the neighboring upper and lower intervertebral discs was assessed using the Pfirrmann et al. (7) grading system. In this classification method, the degree of degeneration was assessed using sagittal T2-weighted images. The grades were defined as follows: grade 1 indicated a normal shape with a distinct intact annulus and nucleus pulposus; grade 2 denoted an irregular shape of the nucleus pulposus with a horizontal band and reduced differentiation

between the nucleus pulposus and the annulus; grade 3 indicated an indistinct separation between the annulus and the diverse nucleus pulposus, which remained recognizable; grade 4 indicated a heterogeneous nucleus pulposus with annulus rupture, low signal intensity, and a decrease in disc height; and grade 5 represented similar characteristics as grade 4 but with the collapsed intervertebral space.

(f) Facet Hypertrophy at the Superior and Inferior Adjacent Levels

Facet hypertrophy was described as degeneration and enlargement of the facet joints. A normal facet joint was classified as F0. When the inferior articular process was hypertrophied, this was classified as F1. The hypertrophied superior articular process was classified as F2. When both the inferior and superior articular processes were hypertrophied, they were classified as F3 (8,9,10).

(g) Changes in the Disc Contour at the Superior and Inferior Adjacent Levels

The description of disc contour changes was categorized on a nominal scale as follows: 0 indicated a normal contour, 1 represented a bulge, 2 denoted a focal protrusion, 3 indicated a broad-based protrusion, and 4 indicated an extrusion.

Statistical Analysis

The data are reported as the mean \pm standard error of the mean. Statistical analysis was conducted using the Number Cruncher Statistical System (NCSS 2007) software (NCSS LLC, Kaysville, Utah, USA). One-Way ANOVA was employed to assess significant differences between the means of two or more independent groups. The Mann-Whitney U test was used when comparing differences between two independent groups with either ordinal or non-normally distributed continuous variables. Tukey's honest significant difference test was conducted to identify significantly different means. Student's t-test was used to evaluate significant differences between two sets of data. Wilcoxon signed-rank test was employed for comparing two related or matched samples. A p value below 0.05 was considered statistically significant.

Results

The study included 51 instances of isthmus spondylolisthesis and 55 cases of degenerative spondylolisthesis. The patients were 22.6% (n=24) male and 77.4% (n=82) female, with the average age for the isthmus type being 54.82 years of age \pm 12.29 years (range, 19 to 77 years of age) and the average age for the degenerative type being 59.60 years of age \pm 14.08 years (range, 42 to 82 years of age). For the isthmus type, 12

were (23.5%) men and 39 were (76.5%) women; there were three (5.9%) cases at the L3-L4 level, 18 (35.3%) cases at the L4-L5 level, and 30 (58.8%) cases at the L5-S1 (fifth lumbar and first sacral vertebrae) level. For the degenerative type, 12 were (21.8%) men and 43 were (78.2%) women; there were 1 (1.8%) cases at the L1-L2 level, 7 (12.7%) cases at the L2-L3 level, 8 (14.5%) cases at the L3-L4 level, 22 (40.0%) cases at the L4-L5 level, and 17 (31.0%) cases at the L5-S1 level. In the case of isthmus spondylolisthesis, 72 adjacent superior and inferior segments were observed, with 51 adjacent superior segments and 21 adjacent inferior segments. In contrast, in degenerative spondylolisthesis, there were 92 adjacent superior and inferior segments, consisting of 54 adjacent superior segments and 38 adjacent inferior segments. Specifically, at the L4-L5 level, isthmus spondylolisthesis exhibited 18 adjacent superior and 18 adjacent inferior segments, while degenerative spondylolisthesis showed 22 adjacent superior and 22 adjacent inferior segments. Complete details can be found in Tables 1, 2, 3, 4.

Degrees of Translation

The Meyerding system for determining the severity of spondylolisthesis was used to measure the translational displacement. Only patients with grade 1 Meyerding classification were included in this study, excluding Meyerding grades 2-5 from the statistical analysis.

Disc Space Height at the Superior and Inferior Adjacent Levels (Figure 1)

In midsagittal-T2-weighted MRI, the Farfan index was employed to measure disc heights. The obtained values for patients with isthmus and degenerative spondylolistheses were 0.46 ± 0.12 and 0.39 ± 0.12 , respectively, for the upper segment. For the lower segment, the values were 0.52 ± 0.15 for isthmus spondylolisthesis and 0.42 ± 0.16 for degenerative spondylolisthesis. The values obtained for L4-L5 level spondylolisthesis for the degenerative and isthmus types were 0.48 ± 0.10 and 0.37 ± 0.12 for the upper segment and 0.54 ± 0.15 and 0.47 ± 0.18 for the lower segment, respectively. Significant statistical differences were noted between the two types of spondylolisthesis, both for the lower segment ($p=0.024$) and the upper segment ($p=0.003$). In individuals experiencing spondylolisthesis specifically at the L4-L5 level, statistical significance was found for the upper segments ($p=0.005$). There were no statistically significant differences between the two types of spondylolisthesis for the lower segment in patients with L4-L5 levels spondylolisthesis ($p=0.172$).

Table 1. Superior adjacent intervertebral levels in all patients for disc space height, thickness of ligamentum flavum, spinal dural sac area, disc degeneration, facet hypertrophy, and disc contour

Superior adjacent level of all patients (n=105)	Isthmic (n=51) Mean ± SD	Degenerative (n=54) Mean ± SD	p
Disc space height	0.46±0.12	0.39±0.12	^a 0.003**
Right lig flavum thickness (mm)	3.54±1.16	3.84±1.47	^a 0.250
Left ligamentum flavum thickness (mm)	4.10±1.22	3.82±1.16	^a 0.240
Spinal dural sac transverse area (mm ²)	144.74±48.11	117.26±47.93	^a 0.004**
Disc degeneration	2.69±0.73	3.09±0.73	^d 0.003**
Facet hypertrophy	1.02±1.12	1.41±1.14	^d 0.059
Disc contour	1.25±0.84	1.80±1.16	^d 0.014*

^aStudent's t-test, ^dMann-Whitney U test, *p<0.05, **p<0.01, SD: Standard deviation

Table 2. Inferior adjacent intervertebral levels in all patients for disc space height, thickness of ligamentum flavum, spinal dural sac area, disc degeneration, facet hypertrophy, and disc contour

Lower adjacent level of all patients (lower n=59)	Defect (+) (n=21) Mean ± SD	Defect (-) (n=38) Mean ± SD	p
Disc space height	0.52±0.15	0.42±0.16	^a 0.024*
Right ligamentum flavum thickness (mm)	3.19±1.08	3.65±1.11	^a 0.136
Left ligamentum flavum thickness (mm)	3.81±1.43	3.94±1.49	^a 0.757
Spinal dural sac transverse area (mm ²)	122.8±34.25	131.16±47.34	^a 0.480
Disc degeneration	2.95±0.74	3.13±0.96	^d 0.430
Facet hypertrophy	1.19±1.17	1.47±1.27	^d 0.405
Disc contour	1.57±0.93	1.66±1.12	^d 0.899

^aStudent's t-test, ^dMann-Whitney U test, *p<0.05, SD: Standard deviation

Table 3. Superior adjacent intervertebral levels in all patients with L4-L5 level spondylolisthesis for disc space height, thickness of ligamentum flavum, spinal dural sac area, disc degeneration, facet hypertrophy, and disc contour

Upper (L3-L4) intervertebral level of isthmic and degenerative L4-L5 spondylolisthesis (n=40)	Defect (+) (n=18) Mean ± SD	Defect (-) (n=22) Mean ± SD	p
Disc space height	0.48±0.10	0.37±0.12	^a 0.005**
Right ligamentum flavum thickness (mm)	3.57±1.30	4.26±1.41	^a 0.121
Left ligamentum flavum thickness (mm)	4.10±1.28	4.29±1.04	^a 0.661
Spinal dural sac transverse area (mm ²)	128.47±45.33	101.68±39.99	^a 0.054
Disc degeneration	2.72±0.89	3.18±0.59	^d 0.059
Facet hypertrophy	1.11±1.32	1.55±1.22	^d 0.288
Disc contour	1.00±0.69	1.68±1.09	^d 0.021*

^aStudent's t-test, ^dMann-Whitney U test, *p<0.05, **p<0.01, SD: Standard deviation

The Thickness of the Ligamentum Flavum at the Neighboring Upper and Lower Levels (Figure 2)

No statistically significant differences were found between the two types of spondylolisthesis for the right ligamentum flavum values, both in the lower segment (p=0.136) and the upper segment (p=0.250). Likewise, in individuals with spondylolisthesis specifically at the L4-L5 level, no statistically

significant difference was found for the right ligamentum flavum values in both the lower segment (p=0.093) and the upper segment (p=0.121).

In terms of the left ligamentum flavum values, there were no statistically significant differences between the two types of spondylolisthesis in all patients, both in the upper segment (p=0.240) and lower segment (p=0.757). Likewise, among

Table 4. Inferior adjacent intervertebral levels in all patients with L4-L5 level spondylolisthesis for disc space height, thickness of ligamentum flavum, spinal dural sac area, disc degeneration, facet hypertrophy, and disc contour

Lower (L5-S1) intervertebral level of isthmic and degenerative L4-L5 spondylolisthesis (n=40)	Defect (+) (n=18) Mean \pm SD	Defect (-) (n=22) Mean \pm SD	p
Disc space height	0.54 \pm 0.15	0.47 \pm 0.18	^a 0.172
Right ligamentum flavum thickness (mm)	3.12 \pm 1.14	3.75 \pm 1.15	^a 0.093
Left ligamentum flavum thickness (mm)	3.64 \pm 1.00	4.23 \pm 1.64	^a 0.177
Spinal dural sac transverse area (mm ²)	116.71 \pm 32.70	140.36 \pm 43.20	^a 0.063
Disc degeneration	2.89 \pm 0.76	2.09 \pm 1.06	^d 0.503
Facet hypertrophy	1.11 \pm 1.18	1.18 \pm 1.14	^d 0.849
Disc contour	1.61 \pm 0.98	1.64 \pm 1.22	^d 0.944

^aStudent's t-test, ^dMann-Whitney U test, SD: Standard deviation

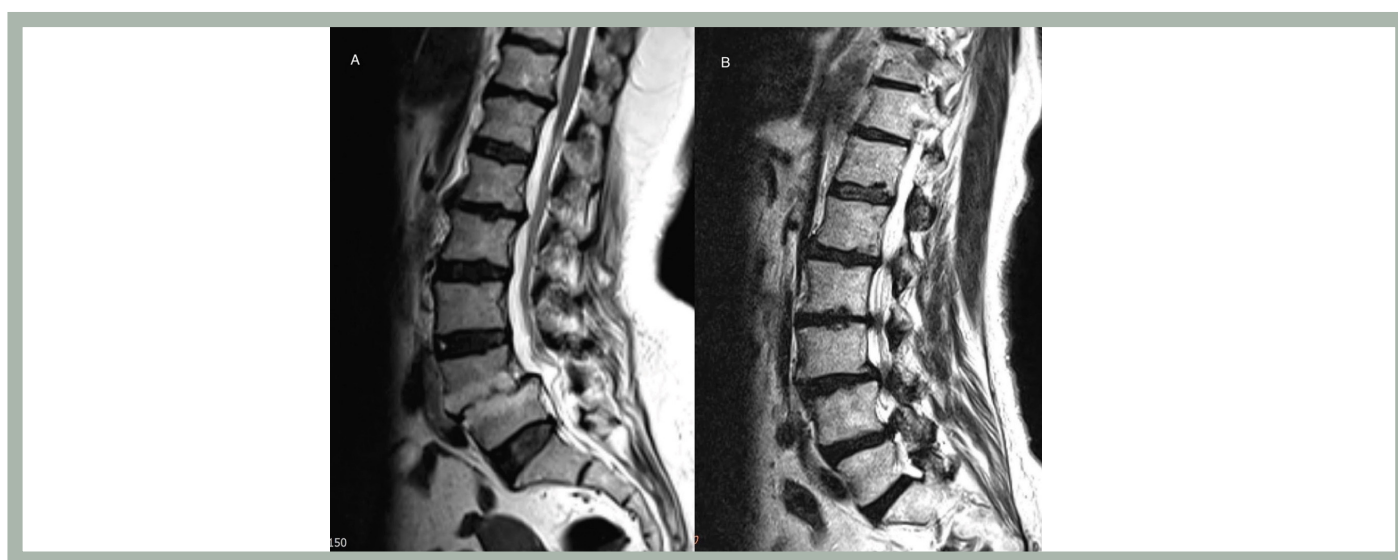

Figure 1. Left (A): midsagittal T2-weighted MRI in a patient with isthmic spondylolisthesis showing that disc space height is not decreased in adjacent segments and showing also grade 3 disc degeneration in the upper adjacent segment and grade 2 disc degeneration in the lower adjacent segment. Right (B): midsagittal T2-weighted MRI in a patient with degenerative spondylolisthesis showing that disc space height is decreased significantly in adjacent segments and showing also grade 4 disc degeneration in the upper adjacent segment and grade 3 disc degeneration in the lower adjacent segment

MRI: Magnetic resonance imaging

patients with L4-L5 level spondylolisthesis, no statistically significant difference was observed for the left ligamentum flavum values in both the upper segment ($p=0.661$) and lower segment ($p=0.177$).

The Cross-sectional Area of the Dural Sac at the Neighboring Upper and Lower Levels (Figure 3)

For measurements obtained regarding the cross-sectional area of the dural sac, the measurements obtained for patients with isthmic spondylolisthesis were 144.74 ± 48.11 mm², while for those with degenerative spondylolisthesis, the measurements were 117.26 ± 47.93 mm² for the upper

segment. For the lower segment, the values were 122.8 ± 34.25 mm² for isthmic spondylolisthesis and 131.16 ± 47.34 mm² for degenerative spondylolisthesis.

Among individuals diagnosed with spondylolisthesis specifically at the L4-L5 level, the measurements for the isthmic type were 128.47 ± 45.33 mm² for the upper segment and 116.71 ± 32.70 mm² for the lower segment. The values were 101.68 ± 39.99 mm² for the upper segment and 140.36 ± 43.20 mm² for the lower segment in patients with the degenerative type.

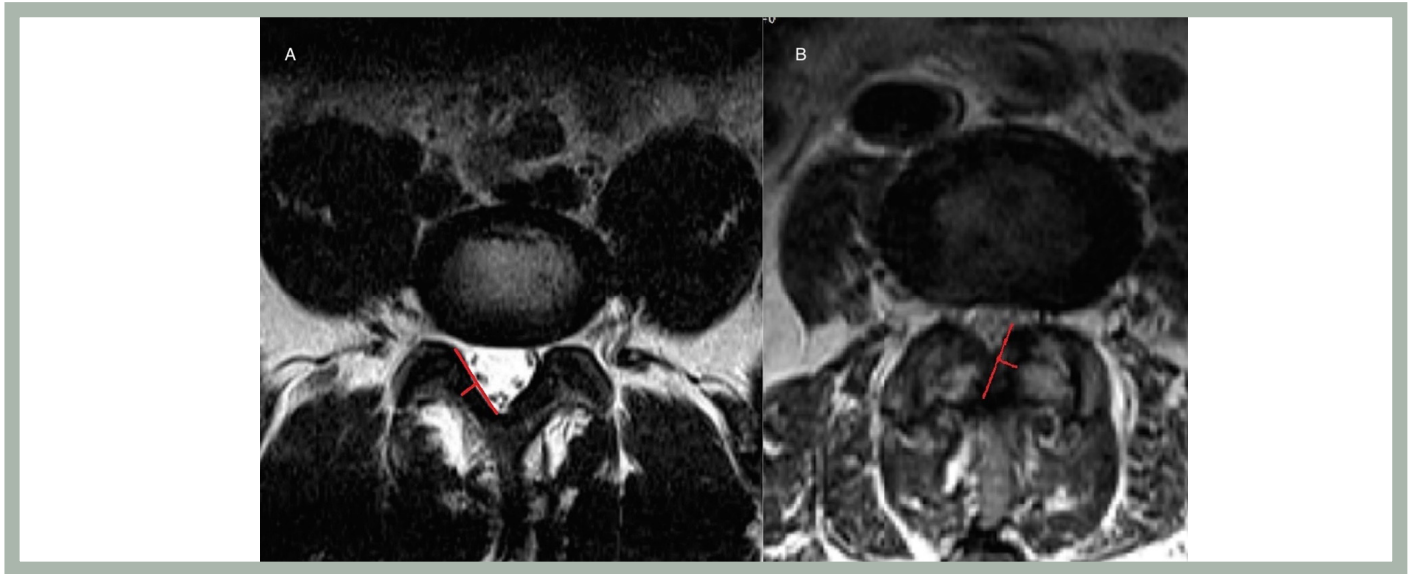


Figure 2. Left (A): axial T2-weighted MRI in a patient with isthmic spondylolisthesis showing that ligamentum flavum thickness is not increased and there is no facet degeneration in the adjacent segment. Right (B): axial T2-weighted MRI in a patient with degenerative spondylolisthesis showing that ligamentum flavum thickness is increased and there is facet degeneration in the adjacent segment

MRI: Magnetic resonance imaging

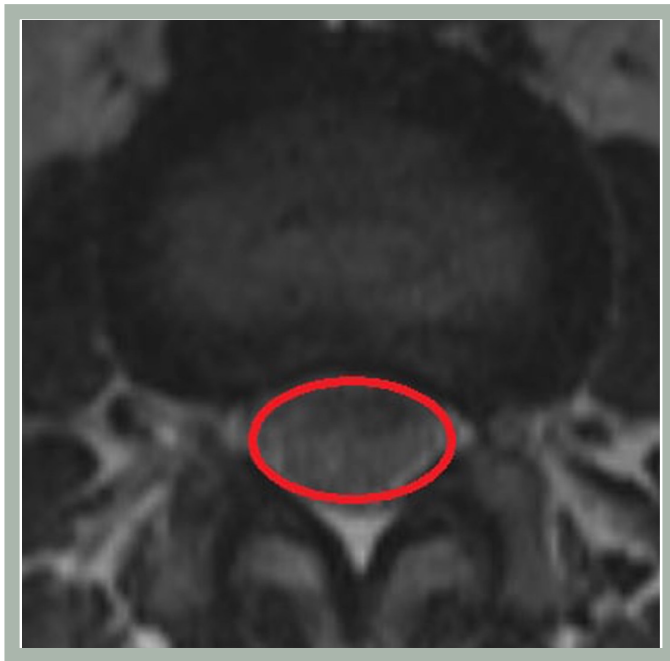


Figure 3. Axial T2-weighted MRI in a patient showing spinal dural sac area at the level of the disc

MRI: Magnetic resonance imaging

Statistical significance was found between the two types of spondylolisthesis in all patients for the upper segments ($p=0.004$). However, no statistical significance was observed between the two types of spondylolisthesis in all patients for the lower segment ($p=0.480$), in patients with L4-L5 level

spondylolisthesis for the upper segment ($p=0.054$), and in patients with L4-L5 level spondylolisthesis for the lower segment ($p=0.063$).

Degenerative Changes in the Discs at the Neighboring Upper and Lower Levels

The disc degeneration values obtained in all patients for the degenerative and isthmic types were 3.09 ± 0.73 and 2.69 ± 0.73 for the upper segment and 3.13 ± 0.96 and 2.95 ± 0.74 for the lower segment, respectively. The values obtained for L4-L5 spondylolisthesis for the degenerative and isthmic types of spondylolisthesis were 3.18 ± 0.59 and 2.72 ± 0.89 for the upper segment and 2.09 ± 1.06 and 2.89 ± 0.76 for the lower segment, respectively. Statistically significant differences were determined between the two types of spondylolisthesis in all patients for the upper segment ($p=0.003$). There were no statistically significant differences identified between the two types of spondylolisthesis in all patients for the lower segment ($p=0.430$), in patients with spondylolisthesis at the L4-L5 level for the upper segment ($p=0.059$), and in patients with spondylolisthesis at the L4-L5 level for the lower segment ($p=0.503$).

Facet Hypertrophy at the Superior and Inferior Adjacent Levels (Figure 4)

The values obtained for facet hypertrophy in all patients with the degenerative and isthmic types of spondylolisthesis were 1.41 ± 1.14 and 1.02 ± 1.12 for the upper segment and 1.47 ± 1.27 and 1.19 ± 1.17 for the lower segment, respectively.

In individuals diagnosed with spondylolisthesis specifically at the L4-L5 level, the values for the degenerative and isthmic types were 1.18 ± 1.14 and 1.11 ± 1.18 for the lower segment and 1.55 ± 1.22 and 1.11 ± 1.32 for the upper segment, respectively. However, there were no statistically significant differences observed between the two types of spondylolisthesis in all patients for the upper segment ($p=0.059$), in all patients for the lower segment ($p=0.405$), in patients with L4-L5 level spondylolisthesis for the upper segment ($p=0.288$), and in patients with L4-L5 level spondylolisthesis for the lower segment ($p=0.849$).

Changes in the Disc Contour at the Superior and Inferior Adjacent Levels (Figure 5)

The disc contour values obtained in all patients for the degenerative and isthmic types of spondylolisthesis were 1.66 ± 1.12 and 1.57 ± 0.93 for the lower segment and 1.80 ± 1.16 and 1.25 ± 0.84 for the upper segment, respectively. The values obtained for L4-L5 level spondylolisthesis for the degenerative and isthmic types were 1.64 ± 1.22 and 1.61 ± 0.98 for the lower segment and 1.68 ± 1.09 and 1.00 ± 0.69 for the upper segment, respectively. Statistical significance was observed between the two types of spondylolisthesis in all patients for the upper segment ($p=0.014$) and in patients with L4-L5 level spondylolisthesis for the upper segment ($p=0.021$). No statistically significant differences were found between the two types of spondylolisthesis in all patients for the lower segment ($p=0.899$) and in patients with L4-L5 level spondylolisthesis for the lower segment ($p=0.944$).

Discussion

The degenerative and isthmic types of spondylolisthesis are the prevailing forms. These types differ in their causes, mechanisms of development, natural progression, and treatment approaches. The isthmic type is characterized by a fibrous loss in the isthmic region of the posterior arch, leading to forward protrusion of the upper vertebral body and separation from the neural arch on the anterior surface. This type is primarily caused by repetitive anterior and posterior bending, often associated with stress fractures resulting from extension. It is frequently observed between the fifth lumbar (L5) and the first sacral (S1) vertebrae, and it tends to occur more frequently in men. In adults, the lesion can lead to instability and degenerative changes that can cause nerve compression, neurological symptoms, and severe pain and often require surgical intervention. Conversely, the degenerative type of spondylolisthesis arises from degenerative alterations and instability in the lumbar area, leading to the enlargement of bones and soft tissues (11). This type presents with back pain and neurological symptoms (12). The degenerative type frequently occurs between the fourth and fifth lumbar vertebrae and has a higher incidence rate in men.

Both isthmic and degenerative spondylolisthesis exhibit a progressive degenerative process as individuals age. However, they can be distinguished by their underlying causes, pathogenesis, and natural progression. The factors causing the degenerative and isthmic types of spondylolisthesis, and the spondylolisthesis itself, produce some changes in

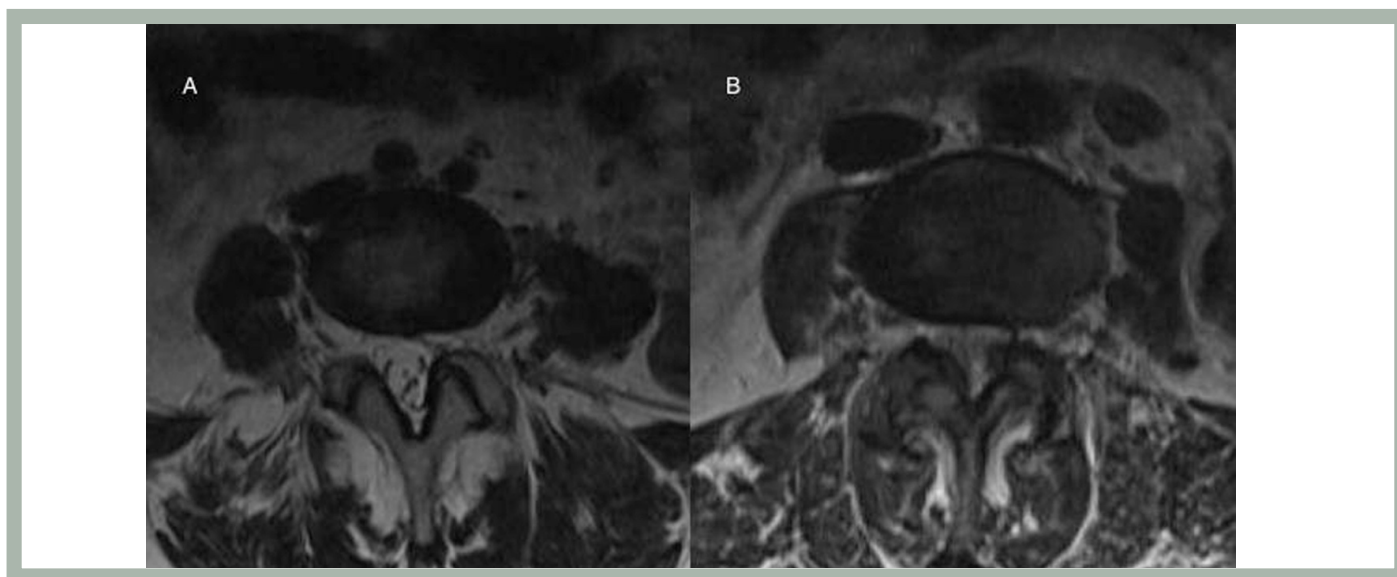


Figure 4. Left (A): axial T2-weighted MRI in a patient with isthmic spondylolisthesis showing mild facet hypertrophy. Right (B): axial T2-weighted MRI in a patient with degenerative spondylolisthesis showing severe facet hypertrophy

MRI: Magnetic resonance imaging

adjacent segments. The adjacent segments of degenerative and isthmic spondylolisthesis exhibit distinct characteristics in terms of degeneration and pathogenesis. However, there is limited research on the degenerative features of these adjacent segments in both types of spondylolisthesis. Jeong et al. (13) conducted a study using plain radiographs and MRI to evaluate the extent of degenerative changes and related factors in the lesion segments and their adjacent superior and inferior segments. They discovered that high-intensity zone lesions were more common in the superior segment above the lesion in isthmic spondylolisthesis than in the degenerative type. Another study by Saleem et al. (14) investigated the relationship between various aspects of lumbar degenerative disc disease, MRI findings, and symptomatology. They found that the most commonly affected lumbar discs associated with degeneration leading to herniation and stenosis were L4-L5 and L5-S1, which could be attributed to long-standing degeneration and changes in disc resilience. Wan examined

the biomechanical effects of interspinous spacer (X-stop) implantation on the area of the implant area and adjacent segments through computed tomography scanning (15). The study showed that X-stop implantation effectively expanded the dimensions of stenotic spinal segments but had minimal immediate biomechanical impact on the adjacent superior and inferior levels. In our present study, we examined MRI images of the affected segment as well as the neighboring upper and lower segments in both isthmic and degenerative spondylolisthesis cases to evaluate the level of degeneration in the adjacent segments.

Limited research has been conducted on the measurement of disc height in the adjacent upper and lower segments in cases of degenerative and isthmic spondylolisthesis using MRI. In our study disc space height was higher in the adjacent upper and lower segments of isthmic spondylolisthesis compared with the adjacent upper and lower segments of degenerative spondylolisthesis. This difference was statistically significant

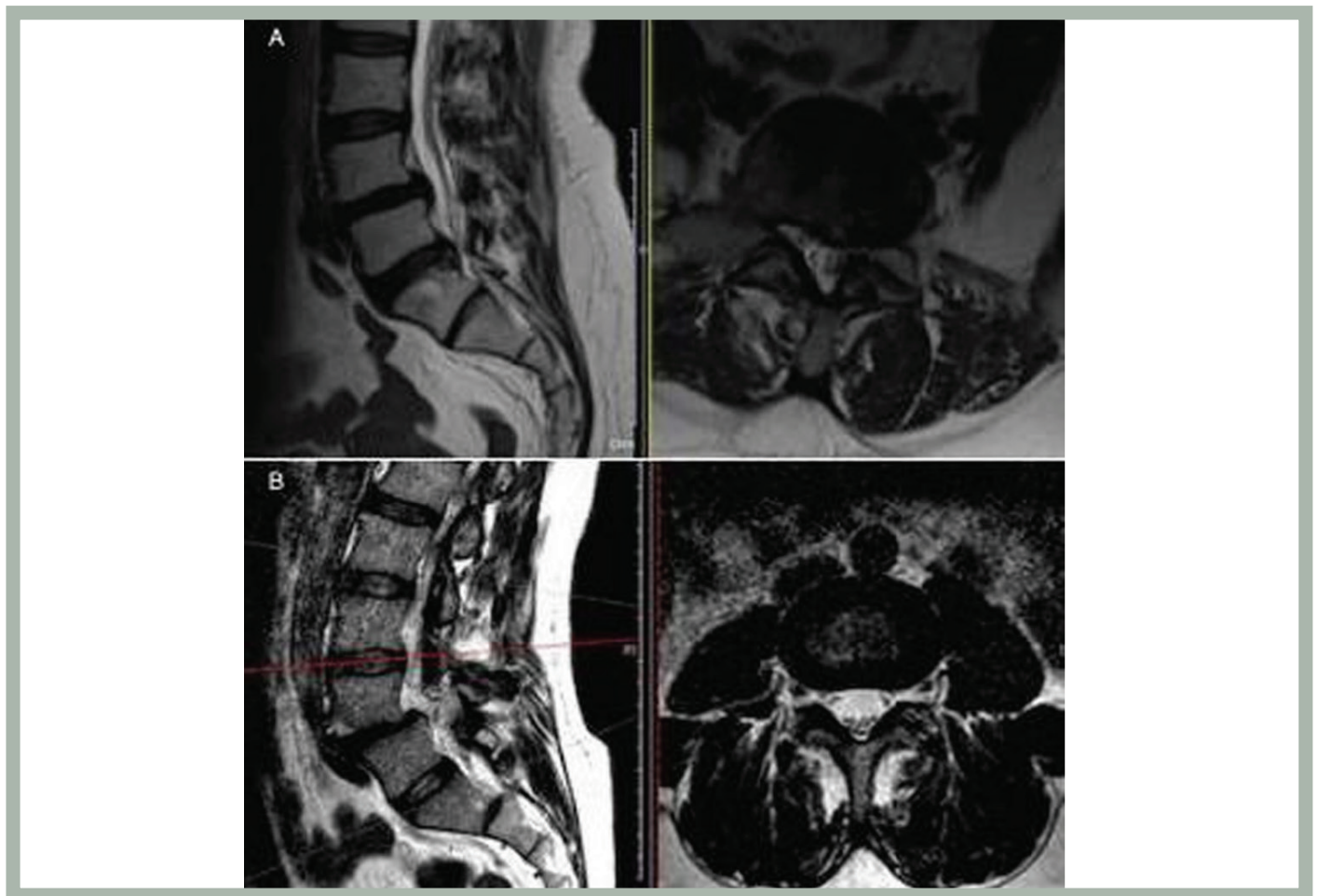


Figure 5. Upper figures (A): T2-weighted MRI in a patient with degenerative spondylolisthesis showing grade 4 disc herniation in the adjacent segment. Lower figures (B): T2-weighted MRI in a patient with isthmic spondylolisthesis showing no disc herniation in the adjacent segment

MRI: Magnetic resonance imaging

between the two types of spondylolisthesis in all patients for the upper segment ($p=0.003$), in all patients for the lower segment ($p=0.024$), and in patients with L4-L5 level spondylolisthesis for the upper segment ($p=0.005$). Loss of disc space height means more degeneration; however, our data show that there is less degeneration in the adjacent upper and lower segments with isthmic spondylolisthesis compared with the adjacent upper and lower segments with degenerative spondylolisthesis.

The enlargement of the ligamentum flavum can reduce the posterior diameter of the spinal canal. However, in our study, we did not find any statistically significant differences in ligamentum flavum hypertrophy between the two types of spondylolisthesis in all patients, specifically in the adjacent upper and lower segments.

The narrowing of the cross-sectional area of the dural sac is an important sign of degeneration in the lumbar spine. In our study, statistical significance was observed between the two categories of spondylolisthesis in all patients for the upper segments ($p=0.004$). These data show that there is less degeneration in the adjacent upper segment with isthmic spondylolisthesis compared with the adjacent upper segment with degenerative spondylolisthesis.

Limited studies have investigated intervertebral disc degeneration in the neighboring upper and lower segments of isthmic and degenerative spondylolisthesis using MRI. Our study revealed significant differences between the two types of spondylolisthesis in all patients regarding the upper segments ($p=0.003$). We observed that the adjacent upper and lower segments of isthmic spondylolisthesis exhibited lesser disc degeneration compared with the adjacent upper and lower segments of degenerative spondylolisthesis.

Facet hypertrophy refers to the enlargement of one or more facet joints, which play a crucial role in connecting the spinal vertebrae and enabling movement and flexibility. This enlargement typically occurs as a natural response of the body's healing mechanisms. To compensate, the body promotes the growth of bone tissue in the joints. However, this reaction leads to increased joint size and puts additional pressure on the surrounding areas. In some cases, facet hypertrophy can even result in the joints exerting pressure on the spinal nerves. In our study, we discovered that there was no statistically significant distinction in facet hypertrophy between the two types of spondylolisthesis in all patients, particularly in the neighboring upper and lower segments.

Changes in the disc contour are also important signs of degeneration. Our study shows that there are statistically significant changes in the disc contour between the two types

of spondylolisthesis in all patients for the upper segment ($p=0.014$) and in patients with L4-L5 level spondylolisthesis for the upper segment ($p=0.021$). These data show less degeneration in the adjacent upper segment with isthmic spondylolisthesis compared with the adjacent upper segment with degenerative spondylolisthesis.

Disc space height measurements, the cross-sectional area of the dural sac, disc degeneration, and alterations in disc contour exhibit less favorable results in the neighboring segments of degenerative spondylolisthesis in contrast to the adjacent segments of isthmic spondylolisthesis. This difference can be attributed to the prolonged duration of degenerative changes affecting all segments of the lumbar spine in degenerative spondylolisthesis. Such effects may contribute to the occurrence of spondylolisthesis in one segment and subsequent degeneration in the surrounding segments. The increased degeneration observed in adjacent segments of degenerative spondylolisthesis may necessitate the need for decompression and instrumentation across a larger number of spinal levels. Using the analyzed parameters as a predictor of further degeneration may be a subject for future investigation. Also, a new MRI classification of the adjacent levels and available treatment options are topics for further investigation.

Study Limitations

The relationship between demographic factors and the degenerative process was not studied, and this is a limitation of this study.

Conclusion

Due to different etiopathogenesis, degeneration appears quite different in the two types of spondylolisthesis. Degenerative spondylolisthesis progresses throughout all segments of the spine. The greater instability in isthmic spondylolisthesis plays a role in the degeneration of the other segments. disc space height measurements, spinal dual sac transverse area, disc degeneration, disc contour, modic change, and Schmorl's node appear worse in adjacent segments of degenerative spondylolisthesis compared with isthmic spondylolisthesis.

Ethics

Ethics Committee Approval: This retrospective study was approved by the Clinical Research Ethics Committee, Balıkesir University Faculty of Medicine, Balıkesir, Turkey (decision no. 2023/64 and date: 10/05/2023).

Informed Consent: Retrospective study.

Peer-review: Externally peer-reviewed.

Authorship Contributions

Surgical and Medical Practices: Ö.E., Concept: U.A., Design: U.A., Data Collection or Processing: Ö.E., Analysis or Interpretation: Ö.E., Literature Search: U.A., Writing: Ö.E., U.A.

Conflict of Interest: No conflict of interest was declared by the authors.

Financial Disclosure: The authors declared that this study received no financial support.

REFERENCES

1. Herbiniaux G. Traité sur divers accouchemens laborieux et sur les polypes de la matrice; ouvrage dans lequel on trouve la description d'un nouveau Levier, ... chez JL de Boubers. 1782.
2. Wiltse LL, Newman PH, Macnab I. Classification of spondylolysis and spondylolisthesis. *Clin Orthop Relat Res* 1976;23-29.
3. Wiltse LL, Rothman SL. Spondylolisthesis: classification, diagnosis and natural history. *Semin Spine Surg* 1989;1:78-94.
4. Meyerding HW. Spondylolisthesis. *J Bone Joint Surg Am* 1931;13:39-48.
5. Knutsson F. The instability associated with disk degeneration in the lumbar spine. *Acta Radiologica* 1944;25:593-609.
6. Chokshi FH, Quencer RM, Smoker WR. The "thickened" ligamentum flavum: is it buckling or enlargement? *AJNR Am J Neuroradiol* 2010;31:1813-1816.
7. Pfirrmann CW, Metzdorf A, Zanetti M, Hodler J, Boos N. Magnetic resonance classification of lumbar intervertebral disc degeneration. *Spine (Phila Pa 1976)* 2001;26:1873-1878.
8. Osman SG, Narayanan M, Winters C. Anatomic treatment-based classification of diseased lumbar spinal motion-segment. *IJNSS* 2013;1:1-10.
9. Modic MT, Steinberg PM, Ross JS, Masaryk TJ, Carter JR. Degenerative disk disease: assessment of changes in vertebral body marrow with MR imaging. *Radiology* 1988;166:193-199.
10. Fredrickson BE, Baker D, McHolick WJ, Yuan HA, Lubicky JP. The natural history of spondylolysis and spondylolisthesis. *J Bone Joint Surg Am* 1984;66:699-707.
11. Newman PH, Stone KH. The etiology of spondylolisthesis. *J Bone Joint Surg Br* 1963;45:39-59.
12. Garfin SR. Spinal-Fusion-The use of bone screws in the vertebral pedicles. *Spine* 1994;19:2254-2255.
13. Jeong HY, You JW, Sohn HM, Park SH. Radiologic evaluation of degeneration in isthmic and degenerative spondylolisthesis. *Asian Spine J* 2013;7:25-33.
14. Saleem S, Aslam HM, Rehmani MA, Raees A, Alvi AA, Ashraf J. Lumbar disc degenerative disease: disc degeneration symptoms and magnetic resonance image findings. *Asian Spine J* 2013;7:322-334.
15. Wan Z, Wang S, Kozánek M, Passias PG, Mansfield FL, Wood KB, Li G. Biomechanical evaluation of the X-Stop device for surgical treatment of lumbar spinal stenosis. *J Spinal Disord Tech* 2012;25:374-378.