


# Giant Adrenal Myelolipoma Occurring in the Post-Pregnancy Period<sup>§</sup>

Emine Sümeyye Atalay   
Hakan Erpek   
Mustafa Gök   
Nuket Özkavruk Eliyatkin 

## Gebelik Sonrası Dönemde Ortaya Çıkan Dev Adrenal Miyelolipom

### ABSTRACT

Adrenal myelolipoma is a rare benign tumor, and contrary to most of the adrenal tumors it is an endocrinologically inactive tumor. Mature adipose tissue, and active bone marrow components identified during histopathological examination are diagnostic clues. They are generally small in size, and detected incidentally. Its definitive etiology has not been determined yet. However multiple number of etiopathogenetic factors have been defined. Hematopoietic stem cell embolization in the adrenal gland is one of the most probable theories.

In this case report we present a 31-year-old patient whose pregnancy was terminated 10 months previously who developed rapidly progressive giant adrenal myelolipoma during the course of her pregnancy. According to literature findings, our case presented in the study is the first case who presented with abdominal pain during post-partum period. We think that this progressively increasing mass during nearly 10 months might be related to pregnancy.

**Keywords:** giant adrenal myelolipoma, pregnancy, adrenal mass

### Öz

Adrenal miyelolipom nadir görülen benign bir tümördür ve adrenal tümörlerin çoğunun aksine endokrinolojik olarak inaktif bir tümördür. Matür yağ doku ve histopatolojik inceleme sırasında saptanan aktif kemik iliği bileşenleri tanısız ipuçlarıdır. Genellikle küçük boyuttadır, tesadüfen tespit edilirler. Kesin etiyolojisi henüz saptanmamıştır. Bununla birlikte çok sayıda etiopatogenetik faktör tanımlanmıştır. Adrenal bezde hematopoetik kök hücre embolizasyonu en olası teorilerden biridir.

Bu olgu sunumunda, 10 ay önce gebeliği tamamlanan ve gebeliği süresince hızla ilerleyen dev adrenal miyelolipom gelişen 31 yaşında bir hastayı sunuyoruz. Literatür bulgularına göre, çalışmada sunulan olgumuz, doğum sonrası dönemde karın ağrısı ile başvuran ilk vakadır. Neredeyse 10 ay boyunca bu giderek artan bu kitlenin hamilelikle ilişkili olabileceğini düşünüyoruz.

**Anahtar kelimeler:** dev adrenal miyelolipom, gebelik, adrenal kitle

### INTRODUCTION

Adrenal myelolipoma was firstly described by Gierke in the year 1905. This rarely seen tumor is benign, and contrary to most of the adrenal tumors it is an endocrinologically inactive tumor. Mature adipose tissue, and active bone marrow components detected during histopathological examination are diagnostic clues. They are generally small in size, and detected incidentally. Its exact etiology has not been determined yet. However

multiple number of etiopathogenetic factors have been defined. Hematopoietic stem cell embolization in the adrenal gland is one of the most probable theories.

In this case report we presented a 31-year-old patient whose pregnancy was terminated 10 months previously and developed rapidly progressive giant adrenal myeloma during the course of her pregnancy and discussed the probable causes of this disease in light of literature data.

Received: 12 April 2019  
Accepted: 20 January 2020  
Publication date: 31 January 2020

**Cite as:** Atalay ES, Erpek H, Gök M, Özkavruk Eliyatkin N. Giant adrenal myelolipoma occurring in the post-pregnancy period. İKSSTD 2020;12(1):87-90.

**Nuket Özkavruk Eliyatkin**  
İzmir Katip Çelebi Üniversitesi  
Tıp Fakültesi Tıbbi Patoloji Anabilim Dalı  
İzmir - Türkiye  
✉ drnuket2003@yahoo.com  
ORCID: 0000-0002-7784-5699

**E. S. Atalay** 0000-0002-4806-4703  
Kırıkkale Üniversitesi Tıp Fakültesi  
Tıbbi Patoloji Anabilim Dalı  
Kırıkkale - Türkiye

**H. Erpek** 0000-0002-7662-8035  
Girne Üniversitesi Tıp Fakültesi  
Suat Günsel Hastanesi  
Genel Cerrahi Anabilim Dalı  
Kıbrıs

**M. Gök** 0000-0001-7021-0984  
Adnan Menderes Üniversitesi Tıp Fak.  
Radyoloji Anabilim Dalı  
Aydın - Türkiye

<sup>§</sup> Bu makale, 27. Ulusal Patoloji Kongresi'nde "Large Adrenal Myelolipoma Occurring in The Post-Pregnancy Period" başlığıyla poster bildirisi olarak sunulmuştur.

## CASE PRESENTATION

Our case was a 31-year-old female patient. For ten months she was describing a stabbing pain on her right upper abdominal quadrant. Her clinical history was unremarkable other than a terminated pregnancy 10 months previously. Any mass lesion was not detected at routine controls performed during her pregnancy. In abdominal USG image performed with the aid of an abdominal convex probe, there was a big solid mass in right adrenal region, mostly hyperechoic with interspersed hypoechoic regions (Figure 1a). Abdominal CT revealed a mostly homogenous, partly heterogenous mass lesion measuring 19x18x12 cm which priorly thought to stem from the right adrenal. The mass was equidense with skin,

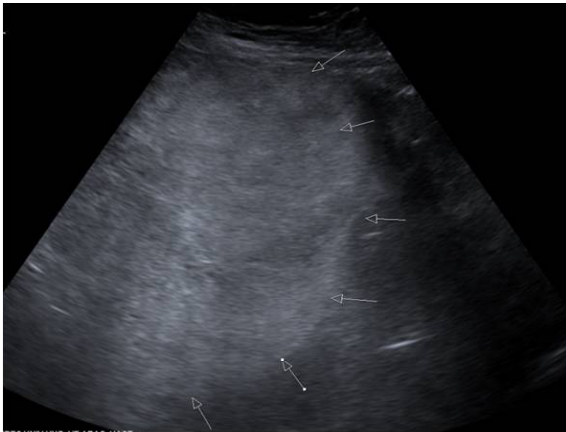

Figure 1a). In abdominal USG image (with abdominal convex probe); there is a big solid mass in right adrenal region, mostly hyperechoic with interspersed hypoechoic regions.

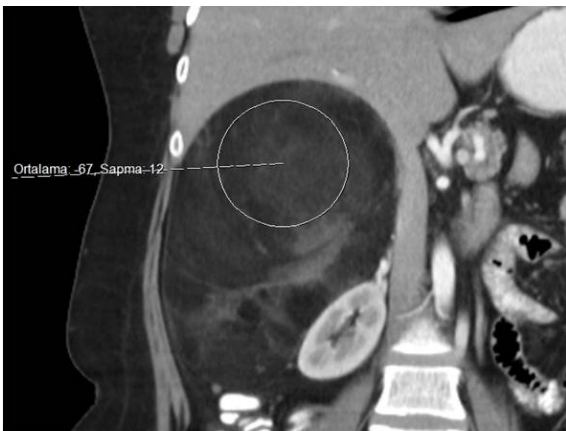

Figure 1b). In coronal contrast-enhanced CT image; there is heterogeneous well-defined, mass covering upper right retroperitoneal space with average attenuation value of -67 HU which is consistent with fat. Fat tissue is interspersed with higher attenuation areas which are consistent with hematopoietic tissue or hemorrhage.

and subcutaneous tissue and displaced the right kidney inferomedially. In coronal contrast-enhanced CT image; there was a well-defined mass covering upper right retroperitoneal space with an average attenuation value of -67 HU which was consistent with adipose tissue. Adipose tissue was interspersed with higher attenuation areas which were consistent with hematopoietic tissue or hemorrhage (Figure 1b). In axial T1-weighted in-phase gradient echo abdominal MR image revealed a right adrenal soft tissue mass with high signal intensity, suggesting the presence of fat component in the lesion. There were also areas of low signal intensity suggesting hematopoietic tissue or hemorrhage. In axial fat-saturated gadolinium-enhanced T1-weighted gradient-echo abdominal MR image; low signal intensity

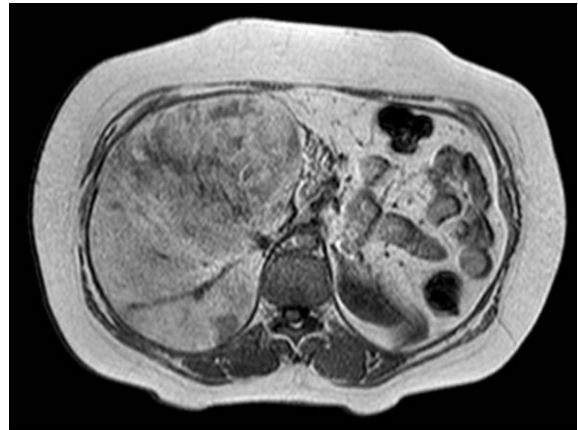


Figure 1c). In axial T1 weighted in-phase gradient echo abdominal MR image reveals a left adrenal tissue mass with high signal intensity, suggesting fat component in the lesion. There is also low signal intensity areas suggesting hematopoietic tissue or hemorrhage.

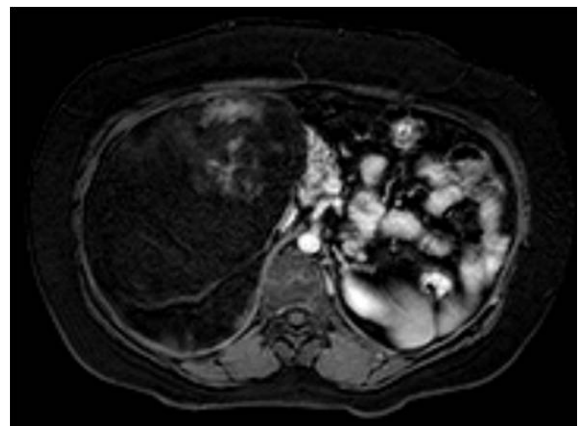


Figure 1d). In axial fat-saturated gadolinium-enhanced T1-weighted gradient-echo abdominal MR image; show low signal intensity (reflecting the presence of fat) and show areas of contrast enhanced areas reflecting hematopoietic tissue or hemorrhage.

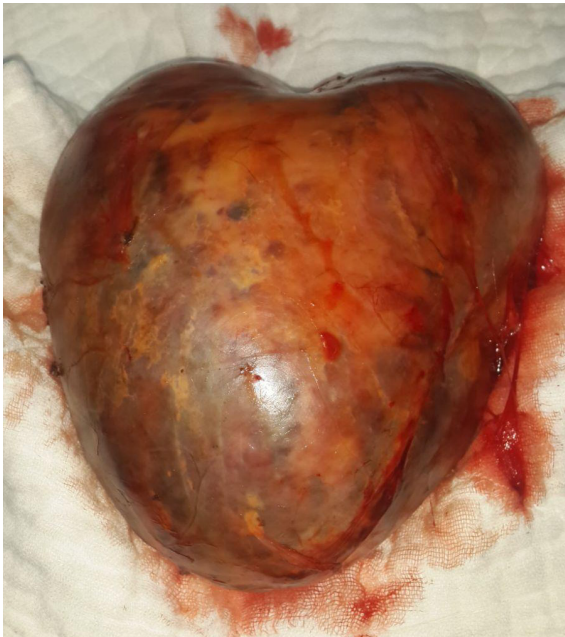

Figure 2. Resected material of adrenal mass was encapsulated, big, smooth-surfaced mass.

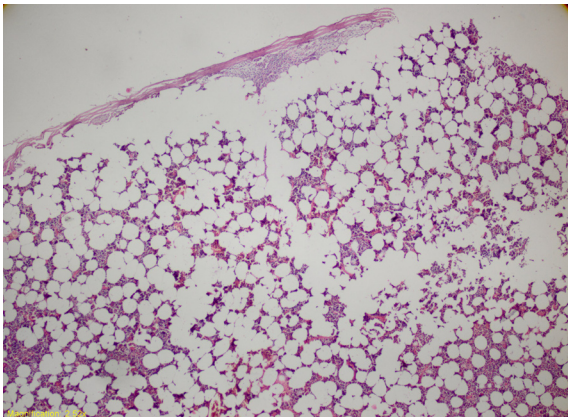


Figure 3a). See the presence of intact adrenal tissue detected as a peripheral thin rim (H&E x40).

(reflecting the presence of fat) and show of contrast enhanced areas reflecting hematopoietic tissue or hemorrhage were seen (1c,d). Hormonal examination of the mass disclosed normal serum cortisol, renin, aldosterone levels, and 24-hour urine vanillylmandelic acid and metanephrine values were within normal limits. It was decided that the mass should be excised.

Macroscopically, resected material of adrenal mass was encapsulated, and smooth-surfaced weighing 2033 gr with dimensions of 22x19x11 cm (Figure 2). On its outer surface yellowish-orange coloured areas just like thin rims which were probably representing adrenal gland were observed. The cut surface of the

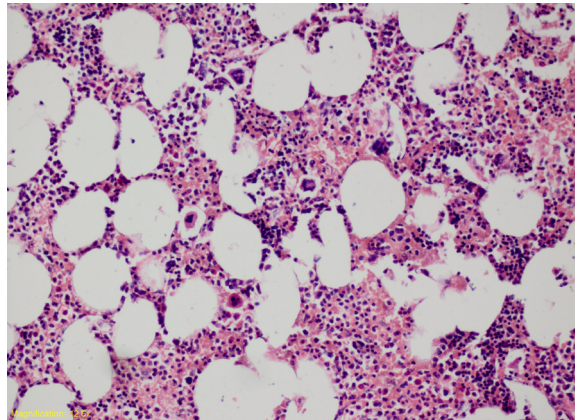


Figure 3b). The lesion consists of myeloid, erythroid, and megakaryocytic cellular components in the adipose tissue with varying proportions (H&E x200).

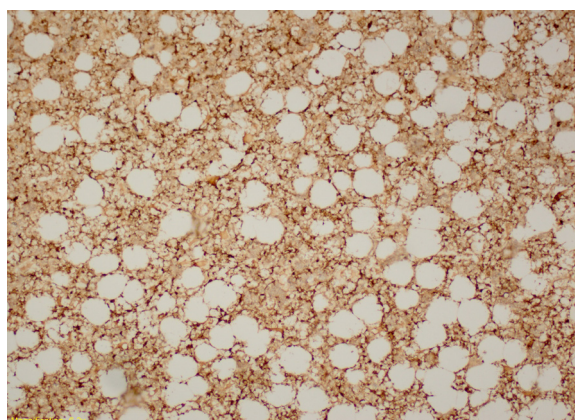
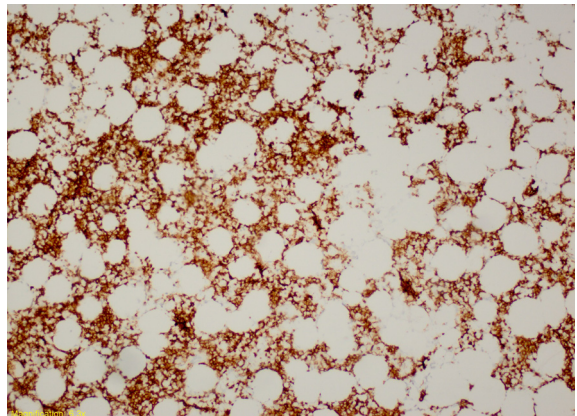


Figure 3c and d). Glycophorin and MPO immunostaining (x 100).

material demonstrated a heterogenous appearance with patchy areas resembling yellowish adipose tissue, and also bleeding regions. On its external surface the largest area consistent with adrenal tissue measured nearly 4 cm in diameter. Multiple number of specimens were obtained for histopathological evaluation. Microscopic examination of tissue samples obtained from areas consistent with adrenal

gland confirmed the presence of intact adrenal tissue detected as a peripheral thin rim (Figure 3a). In most of the areas the lesion consisted of myeloid, erythroid, and megakaryocytic cellular components in the adipose tissue with varying proportions (Figure 3b,c,d). With this appearance it resembled normal bone marrow morphology.

With available findings the diagnosis of "Adrenal Myelolipoma" was made.

## DISCUSSION

Adrenal myelolipomas are very rarely seen. In general population its incidence ranges between 0.08, and 4 percent. In postmortem autopsy series higher incidence rates have been reported<sup>(1)</sup>. Generally its incidence rates are similar in both genders, and it is usually seen during 5.- 7. decades of life. Frequently they are unilateral, and smaller than 4 cm, and tend to develop in the adrenal gland (right/left ratio: 3/2). However bilateral and giant adrenal myelolipomas have been also reported in the literature<sup>(2,3)</sup>. As far as we knew, the largest adrenal myelolipoma cited in the literature was 40 cm in diameter<sup>(4)</sup>. Our case was also a very large adrenal myeloma with its largest diameter of 22 cm.

Since adrenal myelolipomas are small, and non-functional, they are generally detected incidentally. Very large ones may induce various symptoms due to their compression on surrounding tissue. Rarely retroperitoneal bleeding due to spontaneous rupture has been reported. More frequently symptoms as abdominal pain localized on the upper quadrant and low back pain are seen. Our case also demonstrated similar symptoms. US imaging obtained during pregnancy could not reveal any mass lesion in the renal loge which could be attributed to her asymptomatic gestation period or inability to directly evaluate renal loge because of the mass did not reach remarkably detectable size. In both of these conditions very probably the volume of the mass increased progressively to immense dimensions during pregnancy.

The association between adrenal myelolipoma and diseases of the adrenal gland as Cushing disease, Conn syndrome, and congenital adrenal hyperplasia or hematologic diseases as sickle cell anemia, and thalassemia has been also indicated in the lit-

erature 5-6. In our patient none of these concomitant diseases were present. The etiology of this lesion has not been determined precisely, and multiple number of etiopathogenetic factors have been described. Necrosis, infection, inflammation, trauma, and stress have been thought to be effective factors in the etiopathogenesis of the disease. However among the most described theories, hematopoietic stem cell embolization to the adrenal gland is acknowledged.

## CONCLUSION

According to literature findings, our case was the first case who presented with abdominal pain during postpartum period. These pains she experienced during early postpartum period were considered as nonspecific abdominal pains by her attending physician. We think that this progressively increasing mass during nearly 10 months might be related to pregnancy. Can it be a case of stem cell embolization, in other words can hematopoietic stem cells of the fetus transported to the mother via embolization? But, there is no clear and proven information in this regard yet.

**Conflict of Interest:** There is no conflict of interest.

**Funding:** There is no financial support.

**Informed Consent:** Informed consent was obtained from each patient.

## REFERENCES

1. Kale G, Pelley EM, Davis DB. Giant myelolipomas and inadvertent bilateral adrenalectomy in classic congenital adrenal hyperplasia. *Endocrinol Diabetes Metab Case Rep.* 2015;2015:150079. <https://doi.org/10.1530/EDM-15-0079>
2. Al-Bahri S, Tariq A, Lowentritt B, Nasrallah DV. Giant bilateral adrenal myelolipoma with congenital adrenal hyperplasia. *Case Rep Surg.* 2014;2014:728198. <https://doi.org/10.1155/2014/728198>
3. Zattoni D, Balzarotti R, Rosso R The management of bilateral myelolipoma: Case report and review of the literature. *Int J Surg Case Rep.* 2015;12:31-6. <https://doi.org/10.1016/j.ijscr.2015.04.021>
4. Lamont JP, Lieberman ZH, Stephens JS. Giant adrenal myelolipoma. *Am Surg.* 2002 Apr;68(4):392-4.
5. Kumar S, Jayant K, Prasad S, Agrawal S, Parma KM, Roat R, Kumar K. Rare adrenal gland emergencies: a case series of giant myelolipoma presenting with massive hemorrhage and abscess. *Nephrourol Mon* 2015 Jan 19;7(1):e22671. <https://doi.org/10.5812/numonthly.22671>
6. Zorgdrager M, Pol R, van Hemel B, van Ginkel R. Giant adrenal myelolipoma: when trauma and oncology collide. *BMJ Case Rep* 2014 May 28;2014. pii: bcr2014204023. <https://doi.org/10.1136/bcr-2014-204023>