

# **A Child with Maxillofacial Injury by Three Pronged Spear Gun**

## **Üç Mızraklı Zıpkına Bağlı Maksillofasiyal Yaralanması Olan Bir Çocuk**

**Aykut Çağlar<sup>1</sup>, Anıl Er<sup>1</sup>, Cenk Demirdöver<sup>2</sup>, Murat Duman<sup>1</sup>**

<sup>1</sup>Dokuz Eylül Üniversitesi Tıp Fakültesi Çocuk Acil Servisi, İzmir, Türkiye

<sup>2</sup>Dokuz Eylül Üniversitesi Tıp Fakültesi Plastik Cerrahi Servisi, İzmir, Türkiye

### **ÖZET**

Bu raporda, nadir görülen, mortalite ve morbidite ile sonuçlanabilecek zıpkına bağlı maksillofasiyal bir yaralanma olgusu sunulmaktadır. Bu tip hastalarda nasıl müdahale edilmesi gerektiğini bilmek büyük önem taşımaktadır. Olgu, yüzünden zıpkın ile vurulma nedeni ile çocuk acil servisine başvurdu. İlk bakıda bilinci açık, oryantasyonu tam, solunum ve dolaşım bulguları stabildi. Üç mızraklı zıpkın, yüzün sol malar bölgesine saplanmıştı. Zıpkını hastanın yüzünden çıkarmak için gerekli müdahale yapılmadan önce beyin tomografisi ile değerlendirildi ve herhangi bir nörovasküler penetrasyon olmadığı belirendi. Operasyon sırasında hastanın entübasyonu sağlayabilmek için öncelikle zıpkının bağlantı noktası hidrolik kesici ile kesildi ve zıpkının alt parçası acil serviste kontrollü bir şekilde çıkarıldı. Kalan parçalar genel anestezi altında ameliyathane şartlarında çıkarıldı. Hasta 3 gün sonra herhangi bir sekel kalmadan taburcu edildi. Zıpkın oldukça tehlikeli ve çocuklarda tarafından kolayca ulaşılabilen bir ekipmandır. Bu tür vakaların yönetimi farklı zıpkın türlerine göre değişiklik göstermektedir. Bu vaka, acil serviste zıpkına bağlı bir yaralanmaya nasıl müdahale edilmesi gerektiğini ortaya koymaktadır. CAYD 2015;2(1):45-48.

**Anahtar Kelimeler:** Zıpkın, maksillofasiyal, çocuk, travma, acil

### **SUMMARY**

This report illustrates a rare maxillofacial injury by spear gun that can cause mortality and morbidity. It's important to know how to intervene such a patient. He was conscious and oriented when he administered to the emergency department (ED), his respiration and circulation was stable. Three pronged spear was stuck into left malar region. Computed tomography was performed before manipulation of spear gun and no neurovascular penetration was determined. The external part of the spear gun was cut out by a hydraulic cutter to facilitate patient's intubation. The lower fragment of the harpoon was removed in ED. The rest of the spear was removed in operation room under general anesthesia. The patient healed with no deficit and discharged three days after operation. Spear guns are very dangerous equipment that children can easily access. Management of cases can be different according to the different kind of spear guns. This case demonstrates management to the spear gun injuries in ED. CAYD 2015;2(1):45-48.

**Keywords:** Spear gun, maxillofacial, children, trauma, emergency

**Kayıt Tarihi:** 30.09.2014

**Kabul Tarihi:** 07.11.2014

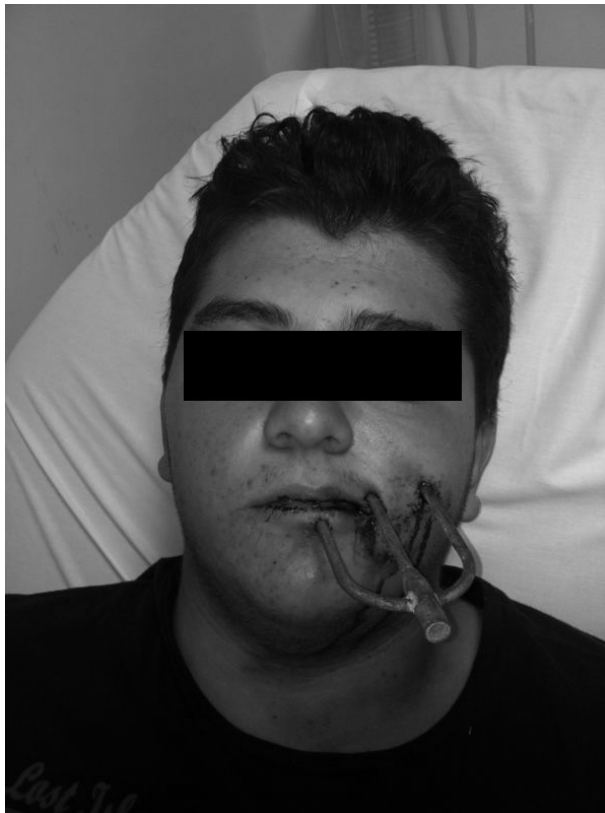**İletişim:** Murat DUMAN, Dokuz Eylül Üniversitesi Tıp Fakültesi Çocuk Acil Servisi, İzmir, Türkiye

## INTRODUCTION

Spear gun is a weapon for underwater fishing. The damage caused by spear gun can be severe and can cause mortality and morbidity (1, 2). In the literature, there are various type of injuries related with spear gun such as maxillofacial, thoracoabdominal, craniofacial and cervical injury (1, 3-5). In these cases, the spear guns range number of prongs, or barb types. The injury of maxillofacial region by spear gun is a very rare condition (1). Hydraulic cutter may be required for removing a spear gun in such cases (3). Therefore, it's important to know mechanism of injury and how to intervene to the patient who is injured by spear gun. We present here a challenging maxillofacial injury case that required hydraulic cutter. We aim to define proper approach and the tips of initial management by reporting a child who was injured with a three pronged spear gun.

## CASE

A-fifteen-years old boy admitted to the pediatric emergency department (ED) because he was accidentally shot in the face with a three pronged spear gun from a distance of approximately one meter

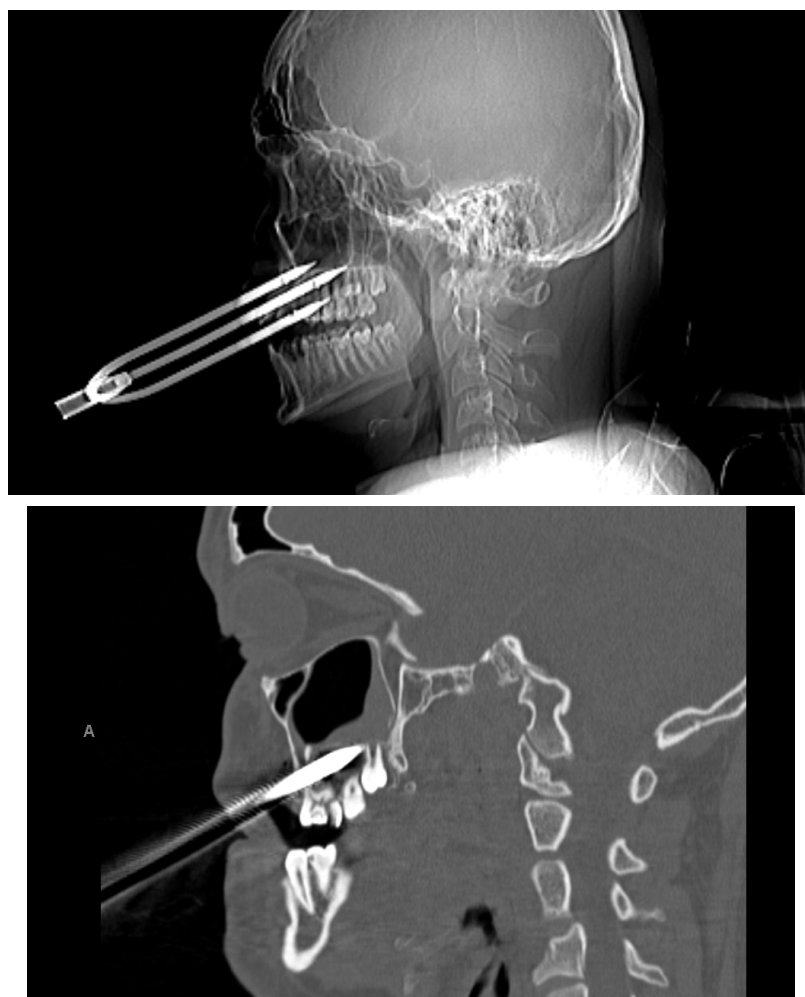


**Figure 1.** Anterior aspects of the patient in ED.

while he and his friend play with it at home. On general assessment, he was conscious and his Glasgow Coma Score was 15; breathing comfortably and the circulation was stable. On physical examination, it was noted that three pronged spear was stuck into left malar region. The entrance sites of prongs were lower lip, upper lip and inferior point of zygomatic arch, respectively (Figure 1). The lower and middle fragments of spear gun had entered into the oral cavity via both lower and upper lips and limited the evaluation of oral cavity. Despite this, the patient's airway was open and was breathing comfortably. His respiratory rate was 18/min, and auscultation of lungs were normal. Oxygen saturation (SpO<sub>2</sub>) was 98% in room air. His heart rate was 95 beats/min, and his blood pressure was 105/55 mmHg. Extra-ocular movements and visual acuity were not affected. The rest of physical examination findings were normal. He was in pain and non-steroidal anti-inflammatory drug was given for analgesia. Unenhanced cranial computed tomography was performed before manipulation of spear gun. Computed tomography revealed three fragments of the harpoon that penetrated to the left maxillofacial region (Figure 2). The inferior and middle fragments caused only soft tissue laceration but the upper fragment of harpoon was penetrated to left maxillary sinus. Neurological and vascular structures were intact. Ampicillin sulbactam at a dosage of 200 mg/kg/day and tetanus toxoid immunization were administered prophylactically in the ED. Dexamethasone at a dosage of 8 mg/day was administered to control post-operative morbidities and to provide comfort for the patient. Brand name and the technical features of harpoon and its arrow were learned and researched before the operation to prevent secondary injuries while removing.

The fragments of the spear gun were planned to remove in the operation room (OR) under general anesthesia conditions but the outer part of the spear gun was preventing proper elective intubation process.

So the external part of the spear gun was cut out by a hydraulic cutter to facilitate patient's intubation. The patient was oriented and sedation wasn't needed. The lower fragment of the harpoon, blocking mandibular movement, was removed gently in ED (Figure 3), and the patient was transferred to the OR for removing the other two fragments. The patient was intubated in the OR, under general anesthesia. The fragments were removed properly and maxillary sinus was fixed. The patient was extubated after the operation. The patient healed with no deficit and discharged three days after the operation.



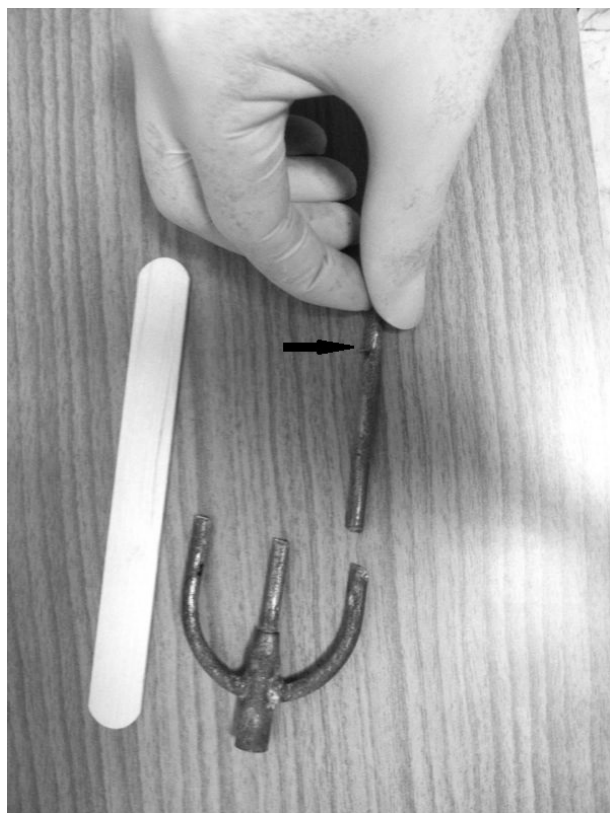**Figure 2.** A and B, Computed tomography and radiograph showing metal object in maxillary sinus.

## DISCUSSION

Spear gun is a weapon for underwater fishing. In literature, the terms such as spear gun, harpoon, fishing gun are used (1, 6, 7). There are two most common types of spear guns: rubber powered and air powered (pneumatic). Our case was shot by rubber powered spear gun. Rubber powered spear gun consist of three main parts: a spear, rubber bands for loading and trigger (1). Stretching of rubber band and attaching to notches in spear gun may be difficult for children. Since children don't have enough strength to pull and fix those rubber bands, the risk of slipping off their hands and injuring the one across is higher. Therefore, children must be avoided from equipment like these. In our country, an authorization to have spear gun is mandatory, but children can get spear guns at home authorized for their parents easier than firearms. Although they are both authorized, firearms are kept away from children more cautiously. The parents may neglect precautions to avoid an injury of spear guns like this. Common point of all

children injuries in literature is that there is no parental supervision (1, 4, 8, 9). Our case was shot at the house while playing with his friend and there was no parental supervision. Most injuries by spear gun occur accidentally but a few cases of suicide were published earlier (2). Although the injuries that caused by spear gun have high risk of mortality and morbidity, fortunately our patient had no severe deficit compared to some cases published before (2, 10, 11). Maxillofacial injuries that caused by spear gun are very rare conditions. In literature, a few case reports were published in recent years (1, 6, 8). Probably, the reason of having no severe deficit in these cases was absorption of the power of trauma by maxillary sinus. Also our case healed with no deficit probably because of the absorption of maxillary sinus and the first molar teeth.

Our case had some difficulties unlike other cases in literature. The spear gun needed to be removed in OR, under general anesthesia but elective intubation was not possible due to inability to open oral cavity. In some cases, cutting the outer part of object



**Figure 3.** Photograph of the spear gun shaft and its barb (arrow) after removal from the patient.

that penetrates to maxillofacial region can be necessary as in ours (8, 10). This process has some risks for the patients. The vibrations of the cutter machine can increase parenchymal damage, so choosing the right cutter machine is important. Also imaging techniques should be performed to reveal extent of the penetration before the cutting process. We used a hydraulic cutter in our case because it causes less vibration.

The structure of harpoon was another consideration in our case. Generally, the arrow of spear guns has a barb to prevent the runaway of the catch. The barb can be mobile or immobile type (1). To be aware of this is important to decrease the complications in surgery (10). So we obtained information about the shape of spear gun arrow before the manipulation. The barb type in our case was immobile (Figure 3).

In post-operative period, primary goals are controlling post-operative morbidities and to provide comfort of the patient. Type of antibiotics and timing is controversial but most surgeons adopt the antibiotic therapy should be initiated pre-operative

period and continued for five days (8, 12). Also dexamethasone is the preferred corticosteroid due to long acting effect (12). We used Ampicillin sulbactam and dexamethasone in our case.

In conclusion, this case is about an injury that could be with high mortality and morbidity but the lucky one. We intend to increase the knowledge of all practitioners who work in ED about this kind of injuries by reporting this case.

## REFERENCES

1. Alper M, Totan S, Cankayali R, et al. Maxillofacial spear gun accident: report of two cases. *Journal of oral and maxillofacial surgery: official journal of the American Association of Oral and Maxillofacial Surgeons*. 1997;55(1):94-7.
2. Bonsignore A, Bernucci LV, Canepa M, et al. Suicide due to four speargun shots: a case report. *The American journal of forensic medicine and pathology*. 2013;34(3):201-4.
3. Wen YS, Huang MS, Shih HC, et al. Unusual thoracoabdominal injury by fishing harpoon. *The Journal of trauma*. 2001;51(2):405-7.
4. Mouzopoulos G, Tzurbakis M. Unusual cervical spine injury by fishing harpoon. *European journal of emergency medicine: official journal of the European Society for Emergency Medicine*. 2009;16(4):209-11.
5. Janeke JB. An unusual craniofacial injury. A case report. *South African medical journal = Suid-Afrikaanse tydskrif vir geneeskunde*. 1984;66(5):190.
6. Burnham R, Bhandari R, Holmes S. Diver's harpoon gun: facial injury caused by an unusual weapon. *The British journal of oral & maxillofacial surgery*. 2010;48(6):482-3.
7. Delikoukos S, Mantzos F. Thyroid storm induced by trauma due to spear-fishing gun trident impaction in the neck. *BMJ case reports*. 2009;2009.
8. Ribeiro AL, de Vasconcellos HG, Pinheiro Jde J. Unusual fishing harpoon injury of the maxillofacial region in a child. *Oral Maxillofac Surg*. 2009;13(4):243-6.
9. Lopez F, Martinez-Lage JF, Herrera A, et al. Penetrating craniocerebral injury from an underwater fishing harpoon. *Child's nervous system: ChNS: official journal of the International Society for Pediatric Neurosurgery*. 2000;16(2):117-9.
10. Abarca-Olivas J, Concepcion-Aramendia LA, Bano-Ruiz E, et al. Perforating brain injury from a speargun. A case report. *Neurocirugia (Asturias, Spain)*. 2011;22(3):271-5.
11. Ban LH, Leone M, Visintini P, et al. Craniocerebral penetrating injury caused by a spear gun through the mouth: case report. *Journal of neurosurgery*. 2008;108(5):1021-3.
12. Sortino F, Cicciu M. Strategies used to inhibit postoperative swelling following removal of impacted lower third molar. *Dental research journal*. 2011;8(4):162-71.