



# The Clinical and Radiological Outcomes of Surgical Decompression in Older Patients with Lumbar Spinal Stenosis

## Lomber Dar Kanallı Yaşlı Hastalarda Cerrahi Dekompresyonun Klinik ve Radyolojik Sonuçları

Şevki Gök,<sup>1</sup> Merih İş,<sup>2</sup> Alp Karaaslan,<sup>1</sup> Recep Başaran,<sup>1</sup> Neşe Keser,<sup>2</sup> Mehmet Zafer Berkman<sup>3</sup>

<sup>1</sup>Department of Neurosurgery, University of Health Sciences Sancaktepe Training and Research Hospital, İstanbul, Türkiye

<sup>2</sup>Department of Neurosurgery, University of Health Sciences Fatih Sultan Mehmet Training and Research Hospital, İstanbul, Türkiye

<sup>3</sup>Department of Neurosurgery, İstanbul Acibadem University, Faculty of Medicine, İstanbul, Türkiye

**Cite this article as:** Gök Ş, İş M, Karaaslan A, Başaran R, Keser N, Berkman MZ. The Clinical and Radiological Outcomes of Surgical Decompression in Older Patients with Lumbar Spinal Stenosis. Bosphorus Med J 2022;9(4):216–221.

**Received:** 17.12.2021

**Revision:** 10.03.2022

**Accepted:** 13.04.2022

### Correspondence:

Dr. Şevki Gök. Sağlık Bilimleri Üniversitesi Sancaktepe Şehit Prof. Dr. İlhan Varank Eğitim ve Araştırma Hastanesi Beyin ve Sinir Cerrahisi Kliniği, İstanbul, Türkiye

**Phone:**

+90 533 654 29 23

**e-mail:**

drsevkigk@hotmail.com

OPEN ACCESS



This work is licensed under a Creative Commons Attribution-NonCommercial 4.0 International License.

### ABSTRACT

**Objectives:** Lumbar spinal stenosis (LSS) is “a clinical syndrome of the buttock or lower extremity pain, which may occur with or without back pain, associated with diminished space available for the neural and vascular elements in the lumbar spine.” This study aims to analyze the clinical and radiological outcomes of lumbar decompression in patients with degenerative LSS.

**Methods:** The patients with degenerative LSS in the Department of Neurosurgery of Haydarpaşa Numune Training and Research Hospital were included retrospectively. The radiological evaluations were measured with the extreme PACS system (2010) by magnetic resonance imaging. The clinical outcomes were evaluated with visual analog score (VAS) and Japanese orthopedic association (JOA) scores. Odom’s criteria were used for outcomes.

**Results:** Thirty-five patients over 65 years old with degenerative LSS were underwent posterior decompression surgery. Of the participants, 40% (n=14) were male and 60% (n=21) were female. The mean age is 63.34±8.08. The area measurements, modified area measurements, AP diameter measurements of the right and left lateral recess, right and left lateral transverse AP diameter measurements, and AP diameter measurements of the right and left neural foramen were improved after surgery. VAS and JOA scores were good after surgery. Fourteen patients had an excellent result, 12 patients had a good result, and nine patients had a fair result according to Odom’s criteria.

**Conclusion:** Improvements in the VAS and JOA scores are prominent after surgery. Foraminotomy and expansion of the lateral recess during surgery increased the quality of life and improved post-operative radiologic parameters in over 65 years of age with degenerative LSS.

**Keywords:** Clinics; degenerative lumbar spinal stenosis; outcome; radiology; surgery.

### ÖZET

**Amaç:** Lomber spinal stenoz (LSS), bel ağrısı veya bel ağrısı olmadan ortaya çıkabilen, bel omurgasındaki nöral ve vasküler elemanlar için mevcut alanın azalmasıyla ilişkili klinik bir kalça veya alt ekstremitte ağrısı sendromudur. Bu çalışmanın amacı, dejeneratif LSS hastalarında lomber dekompresyonun klinik ve radyolojik sonuçlarını analiz etmektir.

**Yöntem:** Haydarpaşa Numune Eğitim ve Araştırma Hastanesi Nöroşirürji Kliniğinde dejeneratif LSS’li hastalar geriye dönük olarak incelendi. Radyolojik değerlendirmeler manyetik rezonans görüntülemeyle Extreme PACS sistemi (2010) ile ölçüldü. Klinik sonuçlar VAS ve JOA skorları ile değerlendirildi. Sonuçlar için Odom kriterleri kullanıldı.

**Bulgular:** Altmış beş yaş üstü dejeneratif LSS’li 35 hastaya posterior dekompresyon ameliyatı uygulandı. Katılımcıların %40’ı (n=14) erkek, %60’ı (n=21) kadındı. Ortalama yaş 63,34±8,08 yıldı. Alan ölçümleri, modifiye edilmiş alan

ölçümleri, sağ ve sol lateral girintinin AP çap ölçümleri, sağ ve sol lateral transvers AP çap ölçümleri, sağ ve sol nöral foramen AP çap ölçümleri ameliyat sonrasında belirgin artma gösterdi. VAS ve JOA skorlarının ameliyattan sonra azaldığı tespit edildi. Odom kriterlerine göre; 14 hastadan mükemmel, 12 hastadan iyi, 9 hastadan orta sonuç alındı.

**Sonuç:** Cerrahi sonrası VAS ve JOA skorlarındaki iyileşme yönünde azalmalar belirgindir. Cerrahi sırasında foraminotomi ve lateral girintinin genişlemesi, 65 yaşın üzerindeki dejeneratif LSS hastalarının yaşam kalitesini artırmış ve postoperatif radyolojik belirteçleri iyileştirmiştir.

**Anahtar sözcükler:** Dejeneratif lomber dar kanal; ameliyat; sonuç; radyoloji; klinik.

Lumbar spinal stenosis (LSS) is “a clinical syndrome of the buttock or lower extremity pain, which may occur with or without back pain, associated with diminished space available for the neural and vascular elements in the lumbar spine.”<sup>[1]</sup> Anatomically, LSS refers to a narrowing of the central spinal canal, lateral recesses, or intervertebral foramen, causing compression of associated neurovascular structures. Degenerative lumbar stenosis results from changes in the spine that occur with aging, including facet joint hypertrophy, loss of intervertebral disk height, disk bulging, osteophyte formation, and hypertrophy of the ligamentum flavum.<sup>[2,3]</sup> The mean anterior-posterior diameter of the lumbar spinal canal was 22–25 mm. The normal height of the lateral recess is 4–5 mm. The lateral recess height <3 mm is suggestive, and <2 mm is a diagnostic sign of stenosis.<sup>[4]</sup> LSS affects more than 200 000 people in the United States, resulting in substantial pain and disability, and it is the most common reason for spinal surgery in patients over 65 years.<sup>[5]</sup> Most cases of LSS occur as acquired degenerative stenosis, resulting from the aging of the spine or following surgery or infection.<sup>[6,7]</sup> Regardless of the etiology, this condition can cause chronic pain and disability, dramatically reducing the quality of life, mobility, and function.<sup>[6]</sup> The L4–L5 vertebral level is frequently affected in degenerative LSS. Lateral recess and neural foraminal stenosis are most commonly seen at the L4–L5 vertebral level.<sup>[8–10]</sup> Surgical treatment is indicated when LSS causes severe leg pain and constant or progressive neurologic signs, such as numbness and weakness.<sup>[11,12]</sup> Several weeks or months of nonsurgical treatments are typically tried before considering surgery.<sup>[5,13]</sup>

This study aims to analyze the clinical and radiological outcomes of lumbar decompression in patients with degenerative LSS.

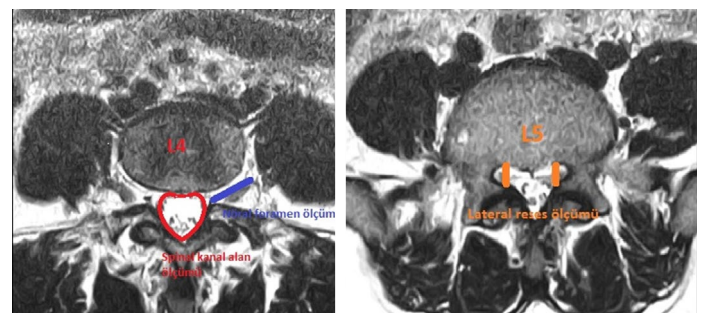
## Methods

Thirty-five patients over 65 years old with degenerative LSS who was hospitalized and underwent surgery in the

Department of Neurosurgery of Haydarpaşa Numune Training and Research Hospital were included in the study. Surgical treatment was applied on LSS caused severe leg pain and progressive neurologic signs. They were evaluated retrospectively based on the file information and the pre- and post-operative MRI images recorded in the extreme PACS system. The neural canal volume, the modified neural canal volume, and the volumes and AP-transverse diameters of the lateral recess and the neural foramen were measured in mm<sup>2</sup> and cm using the extreme PACS system (2010) by MRI in the pre-operative and post-operative periods (Fig. 1). The visual analog score (VAS) and Japanese orthopedic association (JOA) scores (Table 1) of the patients were noted preoperatively and postoperatively. Odom’s criteria (Table 2) were noted in 6 monthly follow-ups of the patients.

## Statistical Analysis

The Number Cruncher Statistical System 2007 and Power Analysis and Sample Size 2008 Statistical Software (Utah, USA) Program was used for statistical analysis. Besides descriptive statistics (Mean, standard deviation, median, frequency, rate, minimum, and maximum), quantitative data were used in the evaluation of study findings. The Kruskal–Wallis test was used to compare three or more groups hav-



**Figure 1.** Measurement of the neural canal volume, the modified neural canal volume, and the volumes and AP-transverse diameters of the lateral recess and the neural foramen at L5 in T2-weighted images of lumbar spine MRI.

Table 1. Japanese orthopedic association score, JOA Score

Score	Description
Lower extremity motor dysfunction	
0	Unable to walk
1	Able to walk on flat floor w/a walking aid (cane or crutch)
2	Able to walk up and/or down stairs w/hand rail
3	Mild lack of stability but walks w/smooth reciprocation unaided/
4	No dysfunction
Lower extremity sensory deficit	
0	Severe sensory loss or pain
1	Mild sensory loss
2	No sensory loss
Sensory deficit in trunk	
0	Severe sensory loss or pain
1	Mild sensory loss
2	No sensory loss
Sphincter dysfunction	
0	Inability to micturate voluntarily
1	Marked difficulty w/micturition
2	Mild-to-moderate difficulty w/micturition
3	Normal micturition

Table 2. Odom's criteria

Outcome	Description
Excellent	All pre-operative symptoms relieved; abnormal findings improved
Good	Minimal persistence of pre-operative symptoms; abnormal findings unchanged or improved
Fair	Definite relief of some pre-operative symptoms; other symptoms unchanged or slightly improved
Poor	Symptoms and signs unchanged or exacerbated

ing no normal distribution. The Mann–Whitney U-test was used to identify the group that caused the difference. The Paired Samples t-test was used in the pre-and post-operative evaluations of normally distributed parameters. The Wilcoxon signed-rank test was used in the pre-and post-operative evaluations of non-normally distributed parameters. The Spearman Correlation Coefficient was used to evaluate the relationships between the parameters. Statistical significance was analyzed at p (0.01) and p (0.05) levels.

## Results

Thirty-five patients over 65 years old with degenerative LSS were hospitalized and underwent posterior decompres-

sion surgery. Twenty-five patients underwent bilateral decompression and foraminotomy with open surgery. On the other hand, ten patients underwent spinal stabilization with a posterior screw rod system. Of the participants, 40% (n=14) were male and 60% (n=21) were female. The mean age is 63.34±8.08. The area measurements, modified area measurements, AP diameter measurements of the right and left lateral recess, right and left lateral transverse AP diameter measurements, and AP diameter measurements of the right and left neural foramen are shown in (Table 3). VAS and JOA scores are shown in (Table 4). When the patients were evaluated according to Odom's criteria in a 6-month follow-up of the patients, 14 patients had an excellent result, 12 patients had a good result, and nine patients had a fair result.

**Table 3.** Measurement and comparison of the neural canal volume, the modified neural canal volume, and the volumes and AP-transverse diameters of the lateral recess and the neural foramen between preoperatively and postoperatively of lumbar spine MRI

	Mean±SD
<b>Area measurement</b>	
Preop	61.21±35.36
Post-operative	91.21±46.23
p-value	0.006
<b>Modified area measurement</b>	
Preop	60.72±44.75
Post-operative	91.36±48.72
p-value	0.003
<b>Right lateral recess AP diameter</b>	
Preop	1.79±1.87
Post-operative	3.15±1.25
p-value	0.007
<b>Right lateral recess transverse diameter</b>	
Preop	2.43±1.93
Post-operative	3.55±1.20
p-value	0.013
<b>Left lateral recess AP diameter</b>	
Preop	0.95±1.85
Post-operative	3.08±1.22
p-value	0.012
<b>Left lateral recess transverse diameter</b>	
Preop	1.92±2.27
Post-operative	3.47±1.36
p-value	0.021
<b>Right Neural foramen AP diameter</b>	
Preop	3.24±2.17
Post-operative	4.22±1.70
p-value	0.012
<b>Right Neural foramen transverse diameter</b>	
Preop	12.24±2.84
Post-operative	12.24±2.84
p-value	1
<b>Left Neural foramen AP diameter</b>	
Preop	3.08±1.92
Post-operative	3.97±1.44
p-value	0.012
<b>Left Neural foramen Atransverse diameter</b>	
Preop	11.75±2.45
Post-operative	11.74±2.44
p-value	0.317

Wilcoxon Signed-Ranks Test \*p&lt;0.05 \*\*p&lt;0.01.

**Table 4.** Measurement and comparison of VAS and JOA between preoperatively and postoperatively

	Mean±SD
<b>Waist VAS</b>	
Preop	7.74±2.28
Post-operative	0.51±0.51
p-value	0.001**
<b>Leg VAS</b>	
Preop	8.84±0.97
Post-operative	0.22±0.43
p-value	0.001**
<b>JOA score</b>	
Preop	7.18±2.07
Post-operative	13.82±1.05
p-value	0.001**

Wilcoxon Signed-Ranks Test, \*p&lt;0.05 \*\*p&lt;0.01, VAS: visual analog scale, JOA: Japanese orthopedic association.

## Discussion

Degenerative LSS is a disease that impairs quality of life with a complaint of neurogenic claudication in advanced age and is usually accompanied by low back pain and/or leg pain. Complaints are caused by narrowing of the spinal canal and the neural foramen due to facet hypertrophy, ligament hypertrophy, and disk protrusion.<sup>[2]</sup> It occurs mostly in the sixth or seventh decade of life. It is more common in women than in men.<sup>[5,14]</sup> In 2007, Qgikubo et al.<sup>[15]</sup> showed that the severity of pain and the shortening of walking distance was correlated with the cross-sectional area of the spinal canal. In a study by Hamanishi et al.,<sup>[16]</sup> they reported the cross-sectional area of the spinal canal below 100 mm<sup>2</sup> at L2-3, L3-4, and L4-5 resulted in claudication. Jönsson et al.<sup>[17]</sup> revealed that there was a relationship between spinal canal width on pre-operative MRI and reduced walking capacity. It was found that the transverse measurements of the right neural foramen in the pre-operative and post-operative periods were significantly lower in the patients with walking distance <100 meters compared to the patients with a walking distance between 100 and 500 meters.<sup>[17]</sup> Jenson et al.<sup>[18]</sup> reported that the measurement of the transverse diameter of the spinal canal is more reliable for central canal stenosis. Beers et al.<sup>[19]</sup> indicated that the neural foraminal diameter is only a quantitative measurement for neural foraminal stenosis and that the neural foraminal diameter of 2–3 mm can be considered as stenosis.<sup>[10]</sup> In our study, we did not find any relationship between spinal canal width (AP and/

or transverse diameter) and walking distance. We think that walking distance alone is not related to spinal canal diameter and that the neural foraminal diameter is also associated with the formation of claudication.

The pre-operative VAS scores were correlated with the spinal canal area regardless of whether the severity of symptoms was associated with narrowing of the spinal canal area or not.<sup>[20]</sup> In 2007, Qgikubo et al.<sup>[15]</sup> showed that there was a correlation between decreased spinal canal area and high pre-operative VAS scores. The pre-operative VAS and ODI scores were correlated with the spinal canal area regardless of whether the severity of symptoms was associated with narrowing of the spinal canal area or not. In a study of Yamakazi et al.<sup>[21]</sup> involving 48 patients, they found that the mean (SD) pre-operative JOA score was 7.3 (1.8), the mean (SD) post-operative JOA score was 11.9 (SD 1.8), the mean (SD) JOA score at the first follow-up examination was 12.1 (2.1), and the mean (SD) JOA score at the final follow-up examination was 12.4 (SD 2.1). They also indicated that this score increased significantly in the post-operative period compared to the pre-operative period.<sup>[21]</sup>

In our study, we observed that the increase in the neural foraminal diameter on pre-operative MRI improved clinical outcomes and affected positively the VAS and JOA scores (which are indicative of the quality of life of patients). We measured the spinal canal area, the modified spinal canal area, and the diameters of the lateral recess and the neural foramen in the patients. A negative relationship was found between the post-operative waist VAS scores of the patients and the area measurements on MRI and the AP diameter measurements of the left neural foramen. A negative relationship was found between the post-operative leg VAS scores of the patients and the AP diameter measurements of the right lateral recess. This showed that the pain scores alone were not associated with the measurement of the spinal canal area. This suggests that the measurement of spinal canal area, as well as the neural foraminal measurements, should be performed in the pre-operative and post-operative evaluations of patients and that the increases in the AP and transverse diameters of the neural foramen in the post-operative period affect significantly pain scores and quality of life of patients. It is thought in these patients that the decrease in the waist and leg VAS scores and the increase in the JOA score in the post-operative period according to the pre-operative period cannot be explained by only the increase in the spinal canal area. The increase in the diameters of the neural foramen

and the lateral recess in the post-operative period according to the pre-operative period has also an effect. When evaluated together with clinical findings of the patients, the decrease in the waist and leg VAS scores and the increase in the JOA score in the post-operative period according to the pre-operative period achieved success together with clinical outcomes of surgical intervention for lateral recess and foraminal stenosis. The pre-operative VAS and JOA scores were correlated with spinal canal area, lateral recess diameter, and neural foramen diameter regardless of whether the severity of symptoms was associated with narrowing of the spinal canal area or not.

## Conclusion

Pre-and post-operative area measurements alone are not responsible for clinical improvement in older patients. Improvements in the VAS and JOA scores are prominent after surgery. Foraminotomy and expansion of the lateral recess during surgery increased the quality of life and improved post-operative outcomes in over 65 years of age with degenerative LSS.

## Disclosures

**Peer-review:** Externally peer-reviewed.

**Conflict of Interest:** None declared.

**Authorship Contributions:** Concept – M.İ.; Design – N.K., M.Z.B.; Supervision– R.B.; Materials – Ş.G., A.K.; Data collection &/or processing – Ş.G.; Analysis and/or interpretation – Ş.K., R.B. Literature search – Ş.K, N.K.; Writing –Ş.K., A.K.; Critical review – R.B., M.Z.B.

## References

1. Watters WC 3rd, Baisden J, Gilbert TJ, Kreiner S, Resnick DK, Bono CM, et al. Degenerative lumbar spinal stenosis: An evidence-based clinical guideline for the diagnosis and treatment of degenerative lumbar spinal stenosis. *Spine J* 2008;8:305–10.
2. Atlas SJ, Delitto A. Spinal stenosis: Surgical versus nonsurgical treatment. *Clin Orthop Relat Res* 2006;443:198–207.
3. Schroeder GD, Kurd MF, Vaccaro AR. Lumbar spinal stenosis: How is it classified? *J Am Acad Orthop Surg* 2016;24:843–52.
4. Zileli M, Özer F. Omurilik ve omurga cerrahisi. İzmir: Meta Basım Matbaacılık Hizmetleri; 2002. p.739–46.
5. Lurie J, Tomkins-Lane C. Management of lumbar spinal stenosis. *Bmj* 2016;352:h6234.
6. Chad DA. Lumbar spinal stenosis. *Neurol Clin* 2007;25:407–18.
7. Lai MKL, Cheung PWH, Cheung JPY. A systematic review of developmental lumbar spinal stenosis. *Eur Spine J* 2020;29:2173–87.
8. Ciric I, Mikhael MA, Tarkington JA, Vick NA. The lateral recess syndrome. A variant of spinal stenosis. *J Neurosurg* 1980;53:433–43.

9. Lee JY, Whang PG, Lee JY, Phillips FM, Patel AA. Lumbar spinal stenosis. *Instr Course Lect* 2013;62:383–96.
10. Orita S, Inage K, Eguchi Y, Kubota G, Aoki Y, Nakamura J, et al. Lumbar foraminal stenosis, the hidden stenosis including at L5/S1. *Eur J Orthop Surg Traumatol* 2016;26:685–93.
11. Liang H, Lu S, Jiang D, Fei Q. Clinical outcomes of lumbar spinal surgery in patients 80 years or older with lumbar stenosis or spondylolisthesis: A systematic review and meta-analysis. *Eur Spine J* 2020;29:2129–42.
12. Shen J, Wang Q, Wang Y, Min N, Wang L, Wang F, et al. Comparison between fusion and non-fusion surgery for lumbar spinal stenosis: A meta-analysis. *Adv Ther* 2021;38:1404–14.
13. Zaina F, Tomkins-Lane C, Carragee E, Negrini S. Surgical versus non-surgical treatment for lumbar spinal stenosis. *Cochrane Database Syst Rev* 2016;2016:CD010264.
14. Deyo RA, Gray DT, Kreuter W, Mirza S, Martin BI. United States trends in lumbar fusion surgery for degenerative conditions. *Spine (Phila Pa 1976)* 2005;30:1441–7.
15. Ogikubo O, Forsberg L, Hansson T. The relationship between the cross-sectional area of the cauda equina and the preoperative symptoms in central lumbar spinal stenosis. *Spine (Phila Pa 1976)* 2007;32:1423–9.
16. Hamanishi C, Matukura N, Fujita M, Tomihara M, Tanaka S. Cross-sectional area of the stenotic lumbar dural tube measured from the transverse views of magnetic resonance imaging. *J Spinal Disord* 1994;7:388–93.
17. Jönsson B, Annertz M, Sjöberg C, Strömqvist B. A prospective and consecutive study of surgically treated lumbar spinal stenosis. Part I: Clinical features related to radiographic findings. *Spine (Phila Pa 1976)* 1997;22:2932–7.
18. Jensen MC, Brant-Zawadzki MN, Obuchowski N, Modic MT, Malkasian D, Ross JS. Magnetic resonance imaging of the lumbar spine in people without back pain. *N Engl J Med* 1994;331:69–73.
19. Beers GJ, Carter AP, Leiter BE, Tilak SP, Shah RR. Interobserver discrepancies in distance measurements from lumbar spine CT scans. *AJR Am J Roentgenol* 1985;144:395–8.
20. Eun SS, Lee HY, Lee SH, Kim KH, Liu WC. MRI versus CT for the diagnosis of lumbar spinal stenosis. *J Neuroradiol* 2012;39:104–9.
21. Yamazaki K, Yoshida S, Ito T, Toba T, Kato S, Shimamura T. Postoperative outcome of lumbar spinal canal stenosis after fenestration: correlation with changes in intradural and extradural tube on magnetic resonance imaging. *J Orthop Surg (Hong Kong)* 2002;10:136–43.