



An Alternative Algorithm for Müller Muscle Conjunctival Resection Surgery for Blepharoptosis Management

Gamze Ozturk Karabulut, Korhan Fazil, Orcun Sonmez, Zehra Karaagac Gunaydin, Kubra Serefoglu Cabuk, Isil Pasaoglu, Muhittin Taskapili

Department of Oculoplastic Surgery, University of Health Sciences, Istanbul Beyoglu Eye Training and Research Hospital, Istanbul, Turkey

Abstract

Objectives: To evaluate the surgical outcomes of Müller Muscle conjunctival resection surgery performed with an alternative formula.

Methods: A total of 58 eyes of 58 patients with mild ptosis (≤ 2 mm) and levator function ≥ 8 mm who responded to 2.5% phenylephrine were enrolled in this study. Müller muscle conjunctival resection was performed between March 2016-March 2018, and the charts were reviewed retrospectively. Margin-reflex distance I was measured before and after five minutes following the instillation of phenylephrine. The amount of excision was 9 mm when the desired elevation was achieved. If the phenylephrine testing resulted in under-correction, 10 mm was resected, and in overcorrection, 8 mm resection was performed. Margin reflex distance and Schirmer test measurements were performed preoperatively and on the first, third and sixth months postoperatively.

Results: The mean increase in margin-reflex distance I was statistically significant at the first, third and sixth months postoperatively when compared to preoperative values ($p < 0.05$, Wilcoxon signed ranks test). Postoperative symmetry was achieved in 54 patients (93.1%) after six months. Compared to the preoperative values, changes in Schirmer-I test results were not statistically significant at each visit after the procedure ($p > 0.05$, Wilcoxon signed ranks test). None of the patients had keratopathy, eyelid contour abnormality, or symblepharon.

Conclusion: Müller muscle conjunctival resection is an alternative procedure to external approach in patients with mild ptosis and good levator function. The algorithm used in this study resulted in a high success rate with high predictability.

Keywords: Blepharoptosis repair, internal ptosis repair; Müller Muscle, Müller Muscle conjunctival resection, phenylephrine testing.

Introduction

Müller Muscle (MM) is a sympathetically innervated upper eyelid elevator, which has been shown to contract in response to topical adrenergic, phenylephrine. MM originates from levator palpebrae superioris (LPS), 15 mm. above the superior border of the tarsus, and it is adherent to the conjunctiva. Levator muscle and MM are loosely attached to each other along their course. Although major elevator of


the upper eyelid is the levator muscle, MM maintains the tone of the upper eyelid and upon stimulation elevates the eyelid 2-3 mm (1). It has been postulated that levator aponeurosis terminates 2-3 mm. above the superior end of the tarsus and supports the anterior lamella, thus skin and orbicularis. Because MM is the major puller of the tarsus, Muller muscle-conjunctival resection (MMCR) results in a favorable correction in ptotic patients with good levator function (> 10 mm) (1).

Address for correspondence: Gamze Ozturk Karabulut, MD. Beyoglu Goz Egitim ve Arastirma Hastanesi, Saglik Bilimleri Universitesi, Okuloplastik Cerrahi Klinigi, Istanbul, Turkey
Phone: +90 532 606 13 03 **E-mail:** gokarabulut@gmail.com

Submitted Date: October 03, 2019 **Accepted Date:** December 02, 2019 **Available Online Date:** December 23, 2019

©Copyright 2019 by Beyoglu Eye Training and Research Hospital - Available online at www.beyoglu-eye.com

OPEN ACCESS This work is licensed under a Creative Commons Attribution-NonCommercial 4.0 International License.



The Fasanella-Servat procedure was first described in 1961 as levator and tarsal resection through the posterior approach, actually, the technique was an MM resection with tarsus (2). Putterman and Urist modified this technique by resection of MM with conjunctiva without resection of tarsus for mild ptosis with good levator function that responds to phenylephrine (3).

In this study, we evaluated the surgical outcomes of MMCR surgery performed with an alternative formula and predictability of this formula in patients with mild ptosis and good levator function that responded to phenylephrine. We also evaluated preoperative and postoperative Schirmer test results and tear break-up time to clarify whether this surgery resulted in a dry eye.

Methods

A total of 58 eyes of 58 patients with mild ptosis, who responded to 2.5% phenylephrine after five minutes following the installation of the ptotic eye, were enrolled in this study. Mild ptosis was described as ≤ 2 mm ptosis and levator function ≥ 8 mm. The patients were recruited from Ophthalmic Plastic and Reconstructive Surgery Department of our hospital, between March 2016-March 2018 and the charts were reviewed retrospectively. Informed consent was obtained from all patients in accordance with the Helsinki Declaration and this study was approved by the local ethics committee. Patients with prior history of ocular, orbital, eyelid or eyebrow surgery, trauma, the conjunctival and ocular surface problems, such as ocular cicatricial pemphigoid or Steven Johnson Syndrome, and any systemic disease that could affect the eyelid position, such as thyroid eye disease, were

excluded from this study.

Light reflex on the mid pupil to upper eyelid margin distance at twelve o'clock position measured with millimeter ruler, margin reflex distance (MRDI) was the reference for the measurement of the upper eyelid position (4). During the preoperative evaluation of patients, MRDI was measured before and after five minutes following instillation of one drop of 2.5% phenylephrine in the upper conjunctival fornix. Elevation of the upper eyelid was accepted as a positive response and degree of elevation determined the amount of MMCR. The amount of excision was 9 mm when the desired elevation was achieved, which was described as symmetry with the contralateral eyelid without ptosis. If the phenylephrine testing resulted in 1 mm under-correction, 10 mm was resected and when the testing resulted in overcorrection, 8 mm resection was performed.

Surgical Technique

The upper eyelid was everted on Desmarres retractor and half of the preoperatively planned resection length was marked from the superior border of the tarsus to the upper fornix on the conjunctival surface at three places aligned with the pupil and the margin of the medial and lateral limbus (Fig. 1 a, b). 2% lidocaine with 1:100,000 epinephrine was injected immediately under conjunctiva superior to the tarsal border of the upper eyelid and 0.5 ml of this solution was injected transcutaneously at the planned area of entrance and exit of sutures. 4/0 silk sutures were passed from the markings on the conjunctival surface and with the aid of these sutures, gentle upward traction was applied on conjunctiva to grasp and separate conjunctiva and MM from LPS (Fig. 1 c). Following entrapment of the conjunctiva and MM with

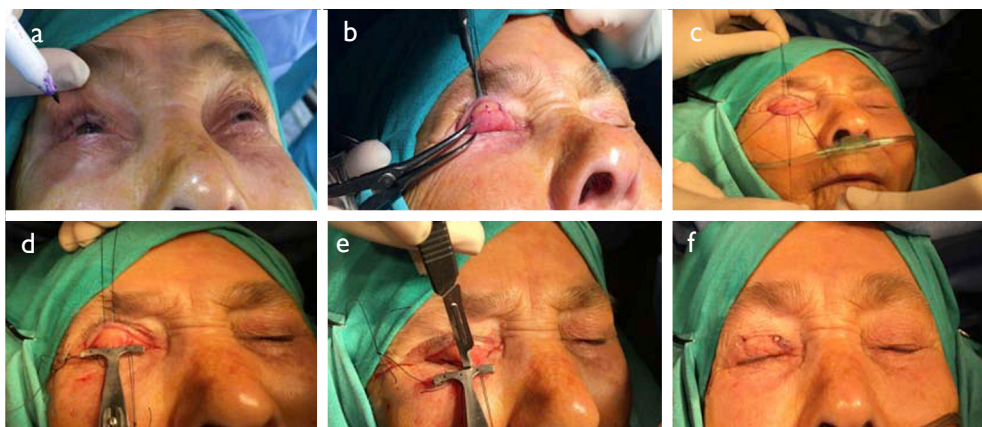


Figure 1. The steps of Müller muscle conjunctiva resection surgery. Marking from the superior border of the tarsus to the upper fornix at three places aligned with the pupil and the margin of the medial and lateral limbus (a, b). 4/0 silk sutures passed from the markings on the conjunctival surface and gentle upward traction on the conjunctiva (c). Entrapment of the conjunctiva and MM with Putterman clamp and saturation through the entire thickness of the eyelid over the tarsus medially and then passed in a running horizontal mattress laterally (d). Excision of entrapped tissue (e). The eyelid was inverted and bolsters of the suture are seen (f).

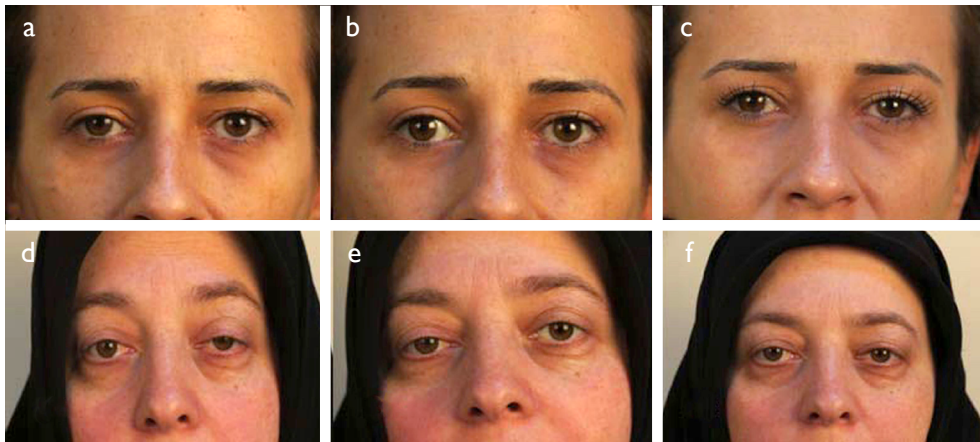

Figure 2. Thirty-eight-year old female with ptosis on the right eye (**a**), and 43-year-old female female with ptosis on the left eye (**d**) before phenylephrine test; photographs of the patients after phenylephrine test (**b, e**) and postoperative sixth month after Müller muscle conjunctiva resection (**c, f**).

Putterman clamp, 6/0 polypropylene suture was passed from the skin through the entire thickness of the eyelid over the tarsus medially and then passed in a running horizontal mattress pattern to the lateral end 1 mm under the clamp (Fig. 1 d). The suture was passed through the entire thickness of the temporal eyelid. After insertion of a bolster, the suture was passed back through the skin adjacent to the temporal exit and run in a reverse horizontal mattress pattern, passed through the full thickness of eyelid near the first entrance and tied over a bolster. A no:15 Bard-Parker blade angled with the sharp surface directing to the clamp was used to excise entrapped tissue (Fig. 1 e). The eyelid was inverted, and the eye was closed with antibiotics for one day (Fig. 1 f). Antibiotic ointment was prescribed three times daily for ten days, and the suture was removed on the tenth day of the surgery.

The MRDI measurements were performed on the first, third and sixth months. The photographs of the patients taken under the same conditions at each visit were analyzed retrospectively. Postoperative success was defined as MRDI of each eyelid within 0.5 mm.

Baseline tear production was measured using the Schirmer-I test (Tear-Flo, Odyssey Medical, Memphis, TN, USA) and tear break-up time was evaluated before the surgery and on the first, third, and sixth months follow-up visits after surgery.

Statistical Analysis

All statistical analyses were performed using SPSS for Windows version 22.0 (SPSS Inc., Chicago, IL, USA). Descriptive statistics included mean values \pm SD for normally distributed variables. Distributions of the variables were measured by the Kolmogorov–Smirnov test. For quantitative analysis, Wilcoxon signed ranks test was used. A p-value of less than 0.05 was considered statistically significant.

Results

This study included 58 eyes of 58 participants (31 female, 53.4%; 27 male, 46.6%) with mild ptosis. The mean \pm SD age of patients was 35.06 \pm 15.13 years (range 10-67 years). Forty-four patients (75.9%) had aponeurotic ptosis, 10 patients (17.2%) had congenital ptosis, and four patients (6.9%) had Horner Syndrome. The mean preoperative levator function was 14.26 \pm 2.76 mm. The average postoperative follow-up was 20.03 \pm 11.03 months. The mean conjunctiva excised in this study was 9.46 \pm 0.89 mm (median 9 mm) (Table 1). The mean increases in MRDI were statistically significant at the first, third and sixth months postoperatively when compared to preoperative values (p=0.000, at all visits, Wilcoxon signed ranks test) (Table 2). Although there was not a statistically significant increase in MRDI between first and third months (p=0.087, Wilcoxon signed ranks test), change in MRDI between first and sixth months and also third and sixth months were significant (p=0.005 and p=0.047, respectively, Wilcoxon signed ranks test). Postoperative symmetry, where MRDI within the 0.5 mm of the fellow eye, was achieved in 54 patients (93.1%) after six months (Fig. 2). No over-correction was seen after surgery at the last follow-up. Of the remaining four patients with under-correction although there was an increase of 1 mm in postoperative MRDI compared with preoperative value, postoperative symmetry was

Table 1. The amount of conjunctiva excised and the number of the patients

Amount of tissue excised (mm)	Number of patients (%)
8	6 (10.3)
9	29 (50)
10	23 (39.7)

Table 2. Comparison of margin reflex distance and Schirmer test results before and after Müller Muscle-Conjunctival Resection surgery

	Mean±SD	p*	p**
MRD I			
Preop	1.64±0.87		
Postop first month	3.02±0.96	0.000^w	
Postop third month	3.18±0.83	0.000^w	0.087 ^w
Postop sixth month	3.30±0.71	0.000^w	0.047^w
Schirmer test			
Preop	11.00±0.26		
Postop first month	11.20±0.16	0.159 ^w	
Postop third month	9.80±0.27	0.105 ^w	0.153 ^w
Postop sixth month	10.70±0.41	0.098 ^w	0.102 ^w

^wWilcoxon signed ranks test; *Comparison with the preoperative values; ** Comparison with the previous visit.

not achieved. These four patients had aponeurotic ptosis, and successful results were obtained with anterior approach levator advancement surgery on the ptotic eye in three of them, and one patient rejected second surgery.

Before MMCR surgery Schirmer-I test result was 11 ± 0.26 mm. After surgery, test results were 11.2 ± 0.16 mm, 9.8 ± 0.27 mm, and 10.7 ± 0.41 mm on the first, third, and sixth months follow-up visits, respectively (Table 2). Compared to the preoperative values, change in Schirmer-I test results were not statistically significant at each visit after the procedure ($p=0.159$, $p=0.105$ and $p=0.098$, respectively, Wilcoxon signed ranks test). There was no difference in tear break-up time scores preoperatively and at all visits postoperatively ($p=0.82$, $p=0.96$, $p=0.78$, respectively, Wilcoxon signed ranks test). None of the patients had keratopathy or ulceration and required additional treatment for dry eye symptoms. Apposition defect of the eyelid margin, contour abnormality and symblepharon were not seen in any of the patients.

Discussion

Müller muscle-conjunctival resection is a less invasive procedure without damage to the orbital septum and fat pads, especially in patients with deep superior sulcus and orbital fat atrophy. This posterior approach provides less tissue dissection, absence of cutaneous scar and shorter operation time, however, needs proper preoperative planning. Diverse published data demonstrated that MMCR procedure could be applied for congenital and acquired ptosis, ptosis associated with Horner Syndrome, ptosis in patients with anophthalmic socket, complex ocular surface disease (corneal disease and corneal surgery) and with glaucoma filtering blebs (5–9).

During the preoperative evaluation of patients, MRDI

should be measured before and after five minutes following instillation of 2.5% or 10% phenylephrine drop, which is a direct-acting adrenergic agent with alpha-1 adrenergic agonistic and weak alpha-2 agonistic effect. However, it has been suggested that alpha-2 receptors predominate in MM. Thus, the phenylephrine test is not a sensitive indicator of MM function (10). It was also shown that MMCR was successful in patients who had negative phenylephrine testing (11). Yazıcı and Beden suggested the usage of 0.5% apraclonidine, which is a peripherally acting alpha-2 agonist agent without any effects on systemic hypertension and pulse rate (12). This drug was found to be as effective as 2.5% phenylephrine, and when 2.5% phenylephrine was ineffective, 0.5% apraclonidine was also ineffective in elevating the eyelid. We used a 2.5% phenylephrine drop in this study and observed that this concentration was effective in evaluating the response of the eyelid.

Since the first description of this technique, several algorithms have been reported in the literature. Putterman and Urist suggested that 8 mm resection was sufficient in most cases (3). However, they recommended 9 mm resection if the phenylephrine test demonstrates an eyelid response slightly lower than level desired and 7 mm resection if the level is slightly higher than the level desired. According to Dresner's algorithm, 4 mm of resection for 1 mm of ptosis, 6 mm of resection for 1.5 mm of ptosis, 10 mm of resection for 2 mm of ptosis, and 11 or 12 mm of resection for 3 mm of ptosis was recommended (13). Symmetrical eyelid position was obtained in 68% of cases. Weinstein and Buerger suggested beginning 8 mm resection for 2 mm ptosis and addition or subtraction 1 mm resection for the final eyelid position by 0.25 mm and reported a 95% success rate with this algorithm (14). Perry et al. (15) concluded that resec-

tion of 9 mm of MM and conjunctiva resulted in roughly the same elevation that was obtained by phenylephrine testing, and for the under-correction, they added 1 mm tarsal resection (up to 2.5 mm of tarsus to prevent tarsal instability) for 1 mm ptosis. If the phenylephrine test resulted in over-correction, Dresner's formula was used and 87% of the patients achieved eyelid symmetry in their study. Yazıcı et al. performed MMCR with resection between 5-11 mm. on 24 patients and reported that 8 mm resection was done in 13 patients that resulted in a 92% success rate (16). Rootman et al. compared the efficacy of standard 7 mm resection length with a variable 4:1 ratio resection length and reported that similar surgical results were detected with no significant difference in MRDI change, final MRDI, change in eyebrow height and final eyebrow height (17). We used a formula similar to the study of Perry et al. (15) for correction of ptosis in this study where 9 mm was the baseline resection amount and 1 mm was added or abstracted according to the MRDI after phenylephrine testing and achieved 93.1% success rate. However, tarsal resection was not considered in this study due to concerns of damaging the tarsal structure and dry eye secondary to removing a portion of meibomian glands and Wolfring Glands. Unlike the previous studies, the formula used in this study was not dependent on the ptosis amount. The amount was calculated according to the similarity between the two upper eyelids after phenylephrine installation.

The mechanism of the action behind this surgery is controversial. Buckman et al. (18) reported that 88% of their specimens revealed absent to minimal smooth muscle. However, they obtained equally successful results when compared to patients with moderate or large muscle resection. They postulated that vertical posterior lamellar shortening, secondary contractile cicatrization of the wound, or advancement of the Müller muscle-levator aponeurosis complex on the tarsus might be the mechanisms. Marcet et al. (19) performed MMCR on one upper eyelid of eight fresh frozen cadavers and used contralateral, unoperated upper eyelid for anatomic comparison. After exenteration of both of the orbits, excised posterior conjunctival tissue and orbits were histologically examined. Their study demonstrated that this procedure advanced the LPS by shortening the posterior lamella. The anterior lamella, including the levator aponeurosis, was plicated as a result of the resection of the posterior lamellar tissues and they concluded that the mechanism of action of MMCR might be due to the advancement of the levator aponeurosis. Baldwin et al. postulated that by resection of MM; the advancement of LPS muscle itself, results in the transmission of contraction force of the levator muscle directly to the tarsal plate instead of through aponeurosis and enhancement of stretch reflex of MM transmitted to LPS results in an increase in the muscle tone in that muscle

(11). In this study, MMCR resulted in an insufficient elevation in four patients with aponeurotic ptosis. These unsuccessful results might be due to the weakened aponeurosis in these four patients that could not transmit the contraction force of LPS to the tarsus, as postulated in the previous studies.

Several modifications of MMCR surgery were reported in the literature. Guyuron and Davies modified the technique as suturing the conjunctiva with a 6/0 running horizontal mattress suture, bringing out the suture ends and tying over the skin (20). In this study, the same procedure was performed using 6/0 polypropylene suture, as described above. Baldwin et al. (11) and Lake et al. (21) performed open sky MMCR in both phenylephrine test positive and negative patients, which is another modification of this technique by direct visualization of MM with intraoperative adjustment of eyelid height. Foster et al. (22) and Kavanagh et al. (23) used fibrin sealant instead of suturing the conjunctival wound with similar effectiveness without any additional risks and with higher patient satisfaction.

Several advantages and disadvantages have been reported with this technique when compared with external levator advancement. Ben Simon et al. (24) compared these two procedures and reported the reoperation rate of the MMCR for residual ptosis was less than the external approach (<3% vs 17%, respectively). Overcorrection and eyelid retraction were more relevant in the MMCR group in their study. Cosmetic outcome evaluating eyelid crease, contour and symmetry was superior in the MMCR group, but there was a selection bias in which patients who underwent external levator advancement had more severe ptosis in their study. Saonanon and Sithanon performed the first randomized controlled trial that compared external levator advancement and MMCR (25). They concluded that although these two surgeries were both effective for the correction of mild to moderate ptosis, MMCR resulted in better cosmetic outcomes, lower reoperation rates with less eyelid asymmetry. However, conjunctival excision in MMCR surgery may result in fornix insufficiency, especially in patients with anophthalmic sockets, ocular cicatricial pemphigoid and Steven Johnson Syndrome (26). Also, in glaucoma patients having filtering trabeculectomy blebs and filtering implants, suture used in MMCR may erode the surface of blebs or implants and may cause blebitis and endophthalmitis (26).

Accessory lacrimal glands Wolfring and Krause provide the basal secretion of the aqueous layer in the tear film. Glands of Krause are located in the upper conjunctival fornix and glands of Wolfring are located at the superior border of the tarsus. Whether the excision of conjunctival tissue, including these structures during the MMCR procedure, might result in tear film instability was a major concern and investigated in many studies (27, 28). These studies demonstrated

that MMCR does not have an effect on tear production. Marcet et al. (19) demonstrated the preservation of superior conjunctival fornix and the glands of Krause in exenterated orbits. Glands of Wolfring were intact at the superior tarsal border in the operated eyes, also. We did not observe any decrease in tear production confirmed by the Schirmer test, and none of the patients complained of dry eye.

Several complications, including keratopathy and ulceration, eyelid contour asymmetry, hematoma formation, suture granuloma and symblepharon formation, can be seen with this procedure (29). Yazıcı et al. (16) reported punctate epithelial keratopathy in two patients, superficial keratitis in one patient and granuloma in the medial tarsal conjunctiva in one patient, all resolved with topical therapy. Eyelash ptosis was seen in two patients in their study, where partial improvement was achieved in one patient with eversion sutures. Bilateral superior epithelial defects were seen in one patient of Perry et al., (15) which resolved in several weeks. However, we did not observe any of these complications in patients included in this study.

In conclusion, MMCR is an alternative procedure in patients with mild ptosis and good levator function. This procedure is less invasive with low complication and re-operation rate. The algorithm used in this study resulted in a high success rate with high predictability.

Disclosures

Ethics Committee Approval: The Ethics Committee of Taksim Training and Research Hospital provided the ethics committee approval for this study (16.01.2019-117).

Peer-review: Externally peer-reviewed.

Conflict of Interest: None declared.

Authorship Contributions: Involved in design and conduct of the study (GOK, KF, ZKG, MT); preparation and review of the study (GOK, OS, KSC); data collection (OS, IP, KSC); and statistical analysis (GOK).

References

- Bang YH, Park SH, Kim JH, Cho JH, Lee CJ, Roh TS. The role of the Muller's muscle reconsidered. *Plast Reconstr Surg* 1998;101:1200-4. [CrossRef]
- Fasanella RM, Servat J. Levator resection for minimal ptosis: another simplified operation. *Arch Ophthalmol* 1961;65:493-6.
- Putterman AM, Urist MJ. Putterman AM, Urist MJ. Mullers muscle-conjunctival resection: a method for treatment of blepharoptosis. *Arch Ophthalmol* 1975;93:619-23. [CrossRef]
- Putterman AM. Margin Reflex Distance (MRD) 1, 2, and 3. *Ophthalmic Plast Reconstr Surg*. 2012;28:308-11. [CrossRef]
- Mazow ML, Shulkin ZA. Mueller's Muscle-conjunctival resection in the treatment of congenital ptosis. *Ophthalmic Plast Reconstr Surg* 2011;27:311-2. [CrossRef]
- Glatt HJ, Putterman AM, Fett DR. Muller's muscle-conjunctival resection procedure in the treatment of ptosis in Horner's syndrome. *Ophthalmic Surg*. 1990;21:93-6.
- Karesh JW, Putterman AM, Fett DR. Conjunctiva-Müller's muscle excision to correct anophthalmic ptosis. *Ophthalmology* 1986;93:1068-71. [CrossRef]
- Michels KS, Vagefi MR, Steele E, Zwick OM, Torres JJ, Seiff SR, et al. Müller Muscle-conjunctiva resection to correct ptosis in high-risk patients. *Ophthalmic Plast Reconstr Surg* 2007;23:363-6. [CrossRef]
- Georgescu D, Cole E, Epstein G, Fountain T, Migliori M, Nguyen Q, et al. Müller Muscle-conjunctiva resection for blepharoptosis in patients with glaucoma filtering blebs. *Ophthalmic Plast Reconstr Surg* 2007;23:285-7. [CrossRef]
- Esmaeli-Gutstein B, Hewlett BR, Pashby RC, Oestreicher J, Harvey JT. Distribution of adrenergic receptors subtypes in the retractor muscles of the upper eyelid. *Ophthalmic Plast Reconstr Surg* 1999;15:92-9. [CrossRef]
- Baldwin HC, Bhagey J, Khooshabeh R. Open sky Müller muscle conjunctival resection in phenylephrine test-negative blepharoptosis patients. *Ophthalmic Plast Reconstr Surg* 2005;21:276-80.
- Yazici B, Beden U. Use of 0.5% Apraclonidine solution in evaluation of blepharoptosis. *Ophthalmic Plast Reconstr Surg* 2008;24:299-301. [CrossRef]
- Dresner SC. Further modifications of Müller's muscle conjunctival resection procedure for blepharoptosis. *Ophthalmic Plast Reconstr Surg* 1991;7:114-22. [CrossRef]
- Weinstein GS, Buerger GF Jr. The modification of Müller's muscle conjunctival resection operation for blepharoptosis. *Am J Ophthalmol* 1982;93:647-51. [CrossRef]
- Perry JD, Kadakia A, Foster JA. A new algorithm for ptosis repair using conjunctival Müllerectomy with or without tarsectomy. *Ophthalmic Plast Reconstr Surg* 2002;18:426-9. [CrossRef]
- Yazici B, Salkaya M, Dogru M. Müller's Muscle-Conjunctival Resection in upper eyelid ptosis. *Turk J Ophthalmol* 2002;32:564-69.
- Rootman DB, Sinha KR, Goldberg RA. Change in eyelid position following Muller's Muscle conjunctival resection with a standard versus variable resection length. *Ophthalmic Plast Reconstr Surg* 2018;34:355-60. [CrossRef]
- Buckman G, Jakobiec FA, Hyde K, Lisman RD, Hornblase A, Harrison W. Success of Fasanella-Servat operation independent of Müller's smooth muscle excision. *Ophthalmology* 1989;96:413-8. [CrossRef]
- Marcet MM, Setabutr P, Lemke BN, Collins ME, Fleming JC, Wesley RE, et al. Surgical microanatomy of the müller muscle-conjunctival resection ptosis procedure. *Ophthalmic Plast Reconstr Surg* 2010;26:360-4. [CrossRef]
- Guyuron B, Davies B. Experience with the modified Putterman procedure. *Plast Reconstr Surg* 1988;82:775-80. [CrossRef]
- Lake S, Mohammad-Ali FH, Khooshabeh R. Open sky Müller's muscle-conjunctiva resection for ptosis surgery. *Eye (Lond)*

- 2003;17:1008–12. [\[CrossRef\]](#)
22. Foster JA, Holck DE, Perry JD, Wulc AE, Burns JA, Cahill KV, et al. Fibrin sealant for Müller muscle-conjunctiva resection ptosis repair. *Ophthalmic Plast Reconstr Surg* 2006;22:184–7. [\[CrossRef\]](#)
23. Kavanagh MC, Ohr MP, Czyz CN, Cahill KV, Perry JD, Holck DE, et al. Comparison of fibrin sealant versus suture for wound closure in Müller Muscle-conjunctiva resection ptosis repair. *Ophthalmic Plast Reconstr Surg* 2009;25:99–102. [\[CrossRef\]](#)
24. Ben Simon GJ, Lee S, Schwarcz RM, McCann JD, Goldberg RA. External levator advancement vs Müller’s muscle-conjunctival resection for correction of upper eyelid involutional ptosis. *Am J Ophthalmol* 2005;140:426–32. [\[CrossRef\]](#)
25. Saonanon P, Sithanon S. External levator advancement versus Müller Muscle-conjunctival resection for aponeurotic blepharoptosis: a randomized clinical trial. *Plast Reconstr Surg* 2018;141:213e–219e. [\[CrossRef\]](#)
26. Yip CC, Foo FY. The Role of Muller’s Muscle-Conjunctiva Resection (MCR) in the Treatment of Ptosis. *Ann Acad Med Singapore* 2007;36(Suppl):22–6.
27. Dailey RA, Saulny SM, Sullivan SA. Müller muscle-conjunctival resection: effect on tear production. *Ophthalmic Plast Reconstr Surg* 2002;18:421–5. [\[CrossRef\]](#)
28. Uğurbaş SH, Alpay A, Bahadır B, Uğurbaş SC. Tear function and ocular surface after muller muscle-conjunctival resection. *Indian J Ophthalmol* 2014;62:654–5. [\[CrossRef\]](#)
29. Cohen AJ, Bernstein JA. Müller Muscle-Conjunctival Resection for Blepharoptosis Repair. *Techniques in Ophthalmology* 2007;5:121–4. [\[CrossRef\]](#)