



Chickenpox Associated Retinitis and Occlusive Vasculitis in a Vaccinated Child: A Case Report and Literature Review

Gokcen Ozcan,¹ Emine Temel,¹ Nilufer Yalcindag,¹ Erdal Ince,² Pinar Bingol Kiziltunc,¹ Elif Ince,³ Huban Atilla¹

¹Department of Ophthalmology, Ankara University, Ankara, Turkey

²Department of Pediatric Infectious Disease, Ankara University, Ankara, Turkey

³Department of Pediatric Hematology, Ankara University, Ankara, Turkey

Abstract

Either retinitis and occlusive vasculitis are rare but vision threatening ocular complications of chickenpox in children. In this case report a 13-year-old girl who developed chickenpox 2 days before complaining with visual loss in her right eye is presented. She was vaccinated one dose of varicella zoster virus (VZV) vaccine when she was 12 months old. Best corrected visual acuity was counting fingers at 1.5 m in right eye. A subtle anterior segment inflammation and mild vitritis were observed. Fundoscopic examination of right eye showed ischemia in paracentral macula and white foci of retinitis along the superotemporal branch of retinal vessels. She was hospitalized and intravenous acyclovir treatment at 3×10 mg/kg daily dose was started. Serum IgM and IgG for VZV were positive. Aqueous humor PCR test was also reported positive for VZV DNA. Oral methylprednisolone was added at a dose of 64 mg/day at the 3rd day acyclovir treatment. Macular edema developed at 4th week of treatment and bevacizumab was administered intravitreally. After 3 injections retinal edema subsided completely. At 6-month follow-up retinal ischemia in superotemporal periphery was observed and photocoagulation was added to treatment.

Keywords: Chickenpox, macular edema, occlusive vasculitis, paracentral acute middle maculopathy, retinitis, single dose vaccine

Introduction

Varicella Zoster virus (VZV) infection can cause two distinct clinical entities: The primary infection (chickenpox) and reactivation (zoster). Chickenpox is a self-limited disease of childhood and early adulthood; however, it rarely causes ocular involvement. A variety of ocular complications related to chickenpox in immunocompetent individuals have been reported so far, such as, 3rd and 6th cranial nerve palsies, internal ophthalmoplegia, external ophthalmoplegia with orbital myositis, conjunctivitis, episcleritis, scleritis, keratitis,

acute anterior uveitis, panuveitis, optic neuritis, periopic neuritis, neuroretinitis, necrotizing herpetic retinopathy with or without retinal vasculitis or isolated retinal vasculitis (1-10). As immune system involves in pathogenesis of complications, it takes times for ocular symptoms to occur after disease onset. Twenty-two cases of chickenpox related retinitis have been reported in literature and ocular symptoms occurred at least 1 week after vesicular skin rash in all of them, except one case, in which ocular symptoms occurred in prodromal phase of chickenpox and preceded vesicles (11) (Table 1). This is the first case of chickenpox related

How to cite this article: Ozcan G, Temel E, Yalcindag N, Ince E, Bingol Kiziltunc P, Ince E, et al. Chickenpox Associated Retinitis and Occlusive Vasculitis in a Vaccinated Child: A Case Report and Literature Review. *Beyoglu Eye J* 2022; 7(2): 143-149.

Address for correspondence: Gokcen Ozcan, MD. Goz Hastaliklari Anabilim Dalı, Ankara Universitesi, Ankara, Turkey
Phone: +90 555 720 40 68 **E-mail:** drgokcencondu@gmail.com

Submitted Date: September 14, 2021 **Accepted Date:** March 22, 2022 **Available Online Date:** May 27, 2022

©Copyright 2022 by Beyoglu Eye Training and Research Hospital - Available online at www.beyoglu-eye.com

OPEN ACCESS This work is licensed under a Creative Commons Attribution-NonCommercial-ShareAlike 4.0 International License.



Table 1. Reported Cases with Chickenpox Retinitis

Case No.	Authors/Year	Age/Gender	Side	Onset	Anterior Segment	Posterior Segment	Clinical Scene
1	Capone and Meredith ^[11] 1992	2y/M	OS	2 days before vesicles	Unremarkable	Papillitis, phlebitis, Retinitis at posterior pole, perivascular sheathing	Chickenpox retinitis, phlebitis
2	Copenhaver and Gainesville ^[23] 1966	3.5 y/M	OU	3 weeks after vesicles	Unremarkable	Papillitis, retinitis at fovea	Chickenpox retinitis
3	Lee and Charles ^[23] 2000	4 y/M	OS	6 weeks after vesicles	Panuveitis	250° giant retinal tear, peripheral retinal necrosis, total retinal detachment	Chickenpox ARN
4	Yu et al. ^[8] 2018	4 y/F	OS	4 weeks after vesicles	2+ aqueous cell, moderate vitritis	Papillitis, temporal peripheral necrotising retinitis and retinal vasculitis	Chickenpox ARN
5	Culbertson et al. ^[24] 1991	6 y/M	OU	2 weeks after vesicles	Granulomatous KP, moderate vitritis	360° multiple peripheral retinitis	Chickenpox ARN
6	Aslan et al. ^[25] 2007	17 y/M	OD	2 weeks after vesicles	No aqueous cell, 2+ cells in vitreous	Chorioretinitis at posterior pole	Chickenpox chorioretinitis
7	Matsuo et al. ^[26] 1990	20 y/F	OU	3 weeks after vesicles	2+ aqueous cells, KP, 2+ vitreous cells	Necrotic retina limited to periphery	Chickenpox ARN
8	Kitamei et al. ^[6] 2012	21 y/M	OD	2 weeks after vesicles	3+ aqueous cells, mutton-fat KP, and Koeppe's nodules, vitreous haze	Sheathing of retinal veins, and yellow-cotton wool spots in peripheral retina	Chickenpox ARN
9	Smith and Chee ^[27] 2000	21 y/M	OD	2 weeks after vesicles	Aqueous cells, dense vitritis	Necrotizing retinitis in periphery	Chickenpox ARN
10	Smith and Chee ^[27] 2000	23 y/F	OS	1 weeks after vesicles	Anterior chamber inflammation, vitritis	Peripheral retinitis, U-shaped tear, total retinal detachment	Chickenpox ARN
11	Matsuo et al. ^[26] 1990	26 y/F	OU	4 weeks after vesicles	3+ aqueous cells, KP, 2+ vitreous cells	Retinal exudates in the periphery	Chickenpox ARN
12	Kelly and Rosenthal ^[7] 1990	27 y/F	OD	2 weeks after vesicles	1+ aqueous cells, 2+ vitreous cells	Chorioretinitis 360° of the periphery, Perivasculitis	Chickenpox ARN
13	Culbertson et al. ^[24] 1991	28 y/F	OD	5 days after vesicles	Granulomatous KP, vitritis	Peripheral retinitis, vascular sheathing	Chickenpox ARN
14	Matsuo et al. ^[26] 1990	29 y/F	OD	20 days after vesicles	3+ aqueous cells, KP, 1+ vitreous cells	Retinal exudates in the peripheral fundus	Chickenpox ARN

Table 1. CONT.

Case No.	Authors/Year	Age/Gender	Side	Onset	Anterior Segment	Posterior Segment	Clinical Scene
15	Smith and Chee ^[27] 2000	29 y/F	OS	2 weeks after vesicles	Moderate uveitis, moderate vitritis	A tiny focus of retinitis at periphery, mild retinal arteritis	Chickenpox ARN
16	Culbertson et al. ^[24] 1991	32 y/M	OD	16 days after vesicles	Moderate uveitis, moderate vitritis	Necrotizing retinitis	Chickenpox ARN
17	Tajunisah and Reddy ^[28] 2001	32 y/F	OD	1 weeks after vesicles	3+ aqueous cells, KP, vitritis	Peripheral retinitis	Chickenpox ARN
18	Bolivar et al. ^[29] 2007	34 y/M	OS	3 weeks after vesicles	4+ aqueous cells, KP, 1+ vitreous cells	Peripheral source of necrotizing retinitis, retinal vasculitis	Chickenpox ARN
19	Culbertson et al. ^[24] 1991	35 y/M	OS	4 weeks after vesicles	aqueous cells, KP, vitritis	Peripheral necrotizing retinitis	Chickenpox ARN
20	Gargouri et al. ^[2] 2016	35 y/M	OD	3 weeks after vesicles	Few aqueous cells, KP, 3+ vitreous cells	Retinal infiltration affecting the far periphery	Chickenpox ARN
21	Ehongo-Bidime et al. ^[30] 1995	43 y/M	OD	12 days after vesicles	-	Retinal necrosis in temporal periphery	Chickenpox ARN
22	Barondes et al. ^[31] 1992	Adult/M	-	2 weeks after vesicles	-	Retinal detachment	Chickenpox ARN

ARN: Acute retinal necrosis.

retinitis and occlusive vasculitis in an immunocompetent girl vaccinated for VZV and the second case which ocular symptoms were seen in very early period of chickenpox in the literature.

Case Report

This study was performed with informed consent and followed the guidelines of the Ethics Committee of the Ankara University Faculty of Medicine. A 13-year-old girl was admitted to ophthalmology department of Ankara University School of Medicine with a 3-day history of visual loss in her right eye. Review of her recent medical history revealed that she was diagnosed with chickenpox by virtue of vesicular skin rash started 5 days ago, and her 4-year-old sister also had chickenpox 2 weeks ago. Best corrected visual acuities were counting fingers at 1.5 m in her right eye and 20/20 in the left eye with myopic correction. Intraocular pressure was within normal limits. Anterior segment's microscopic examination revealed subtle anterior chamber inflammation and mild vitritis. Funduscopic examination of right eye disclosed white patchy areas of retinitis and intraretinal hemorrhages along the superotemporal branch of retinal vessels and yellow colored paracentral macular ischemia (Fig. 1a). FFA showed delayed filling of superotemporal retinal vein, staining of venous wall, ischemia along the side of vein without leakage (Fig. 1b, c). Optical coherence tomography showed the features of paracentral acute middle maculopathy; band-like hyper-reflective plaque at the level of the inner nuclear layer extending from the outer plexiform layer to the inner plexiform layer at paracentral location (Fig. 1d). The left eye was normal. Based on her recent chickenpox infection and clinical characteristics such as occlusive vasculitis and white patchy foci of retinal involvement, chickenpox retinitis was suspected, and for confirmation anterior chamber paracentesis was performed for aqueous PCR analysis. After immediate hospitalization, intravenous acyclovir treatment at 3 × 10 mg/kg daily dose was started. Aqueous humor VZV DNA and serum IgM and IgG for VZV were reported positive. When we question the vaccination history, we found out that when she was 12 months old, she was vaccinated only one dose for VZV vaccine according to national vaccine schema. Her immunoglobulin subgroup analysis was normal and CD4 lymphocyte count was within normal limits. Oral methylprednisolone was added at a dose of 64 mg/day at 3rd day of hospitalization. After 5 days of treatment, white foci of retinitis began to resolve. We discontinued systemic steroid as the inflammation subsided rapidly. She was treated with 14 days of intravenous acyclovir and discharged with oral valacyclovir 3 × 1000 mg/day.

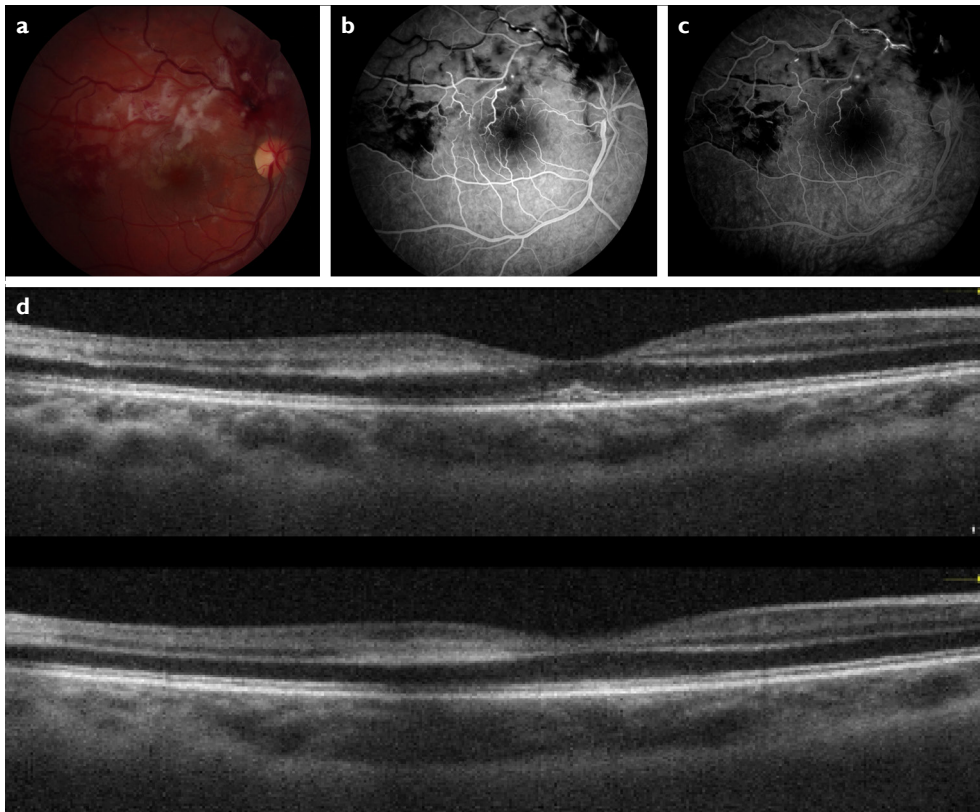


Figure 1. (a) Fundus photography of right eye discloses white patchy foci of retinitis and intraretinal hemorrhages along the superotemporal branch of retinal vessels and yellow paracentral ischemia in macula due to occlusive vasculitis. (b) Early phase of fluorescein angiography reveals delayed filling of superotemporal branch of retinal vein and hypofluorescent areas corresponding to intraretinal hemorrhages. (c) Late phase of the fluorescein angiography shows staining of superotemporal branch of retinal vein without remarkable leakage. (d) Optical coherence tomography shows paracentral irregular hyper-reflective band extending from the outer plexiform layer to the inner plexiform layer.

In the control visit at 4th week of treatment, best corrected visual acuity was 20/50, retinitis resolved but macular edema had developed (Fig. 2a, b). Intravitreal 0.1 ml/2.5 mg bevacizumab treatment with prior anterior chamber paracentesis to prevent intraocular pressure spikes was administered for

3 times in every month. Antiviral therapy was discontinued at the 8 weeks of disease onset after confirmation of PCR negativity of aqueous humor from paracentesis material for VZV DNA. After 3 injections edema subsided completely. At 6 month following-up retinal ischemia in superotemporal

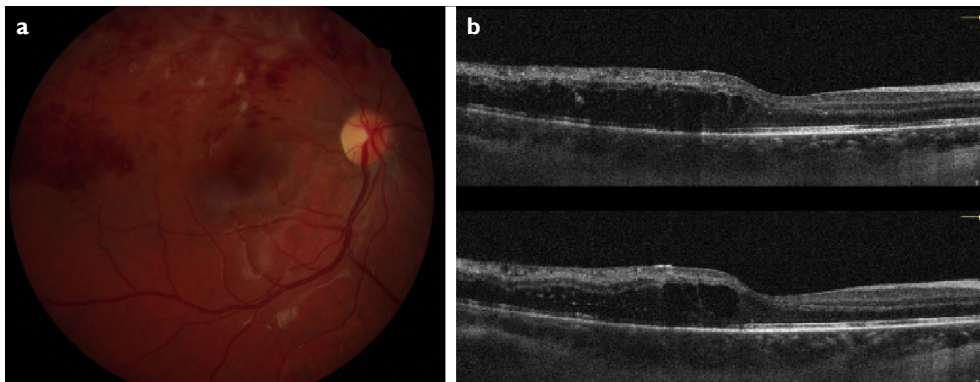


Figure 2. (a) In the control visit at 4th week of treatment, fundus photograph shows that white foci of retinitis had almost disappeared and temporal to macula white centered retinal hemorrhages resembling Roth spots persist. (b) Optical coherence tomography reveals edema in temporal macula.

periphery was observed and photocoagulation of ischemic areas was applied. At the 1st year of the treatment her visual acuity was 20/80 and there was no edema and neovascularization (Fig. 3a, b).

Discussion

VZV is an enveloped DNA virus, and it belongs to herpes virus family like, herpes simplex virus, cytomegalovirus, and Epstein-Barr viruses. Herpes viruses may all cause viral retinitis in healthy or immunocompetent patients. Acute retinal necrosis (ARN) and progressive outer retinal necrosis (PORN) represent a spectrum of rapidly progressing necrotizing herpetic retinopathies, caused by reactivation of latent viral infection. The clinical picture resulting from herpetic infection depends on the host's immune status. ARN generally involves immunocompetent patients, starts peripherally, and spreads centripetally (12). The clinical diagnosis of ARN is based on the diagnostic criteria established by the American Uveitis Society, which consists of: (1) one or more discrete foci of peripheral retinal necrosis, (2) occlusive retinal vasculitis with arteriolar involvement, (3) prominent inflammation

in the anterior and posterior chambers, (4) circumferential disease spread, and (5) rapid progression of disease in the absence of treatment (13). ARN almost always occurs with reactivation of a herpetic latent virus, nonetheless, primary herpes infections may cause a clinical picture resembling ARN. PORN is multifocal outer retinitis with early involvement of posterior pole and seen in immunocompromised patients. Varicella zoster induced PORN has also been reported in immunocompetent patients with idiopathic CD4 lymphocytopenia (14).

Only 1.8% of cases of chickenpox occur after the second decade of life and produce more severe systemic illness than in children (15). It is not surely understood why adults get serious complications whereas children has relatively mild disease. In adults the immune system is stronger and more mature than in children. Hypothetically, it is possible, that existence of the aggressively strong and potent cell mediated immune response to VZV in adults may be harmful for the host, leading to excessive damage of infected cells which consequently lead to more severe disease and higher percentage of complications. The strongest cell-mediated immune responses to VZV appear to be in early adulthood (16).

When we searched the literature 22 cases of viral retinitis related with chickenpox infection were reported up to now (Table 1). When we reviewed these cases, 6 of them were younger than 18 years of age (27.2%). Among the patients younger than 18 years of age, 3 of them (50%) had retinitis with peripheral retinal involvement and severe clinical presentation with iridocyclitis and 2 of these cases also had necrosis as seen in ARN. Remaining 3 cases (50%) had similarities with our case such as, posterior pole involvement, subtle iridocyclitis and mild retinitis without necrosis. However, 16 patients older than 18 years of age had clinical picture resembles ARN without exception (100%). Although chickenpox is rare in adults, considering all these reported cases, chickenpox retinitis is more common in adults than children. Furthermore, we may hypothesize that chickenpox retinitis in adults unexceptionally resembles ARN; nevertheless, in children clinical course can be milder. Considering age difference of immune reaction, mild retinitis in our case and in other three mild cases reported in children could be related with immature cell mediated immunity however severe reaction to chickenpox and ARN like course is inevitable in adults.

Up to 16% of all patients with ARN experience symptoms of abnormal cellular immunity (12). Immunogenetic predisposition may also be responsible for abnormal immune response as well as impaired immunity or increased susceptibility to infection and different clinical course of ocular involvement in same age group.

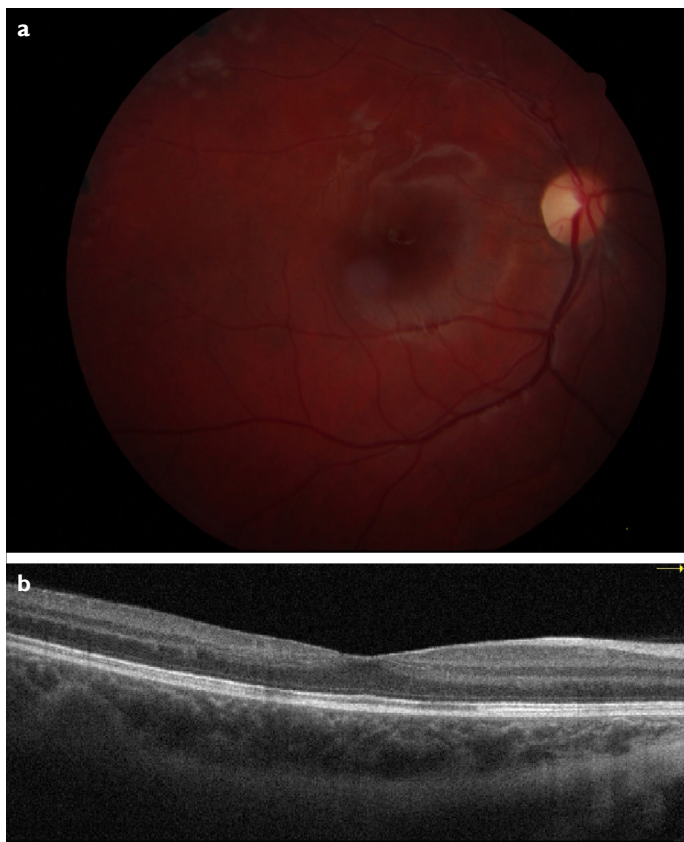


Figure 3. (a) The left fundus photograph 14 months after presentation reveals the disc and retinal vasculature has returned to normal. There is superotemporal atrophic retinal scarring due to photocoagulation. (b) Optical coherence tomography discloses a slight temporal macular atrophy mainly in inner retinal layers.

Cell-mediated immunity, mainly the CD4 lymphocytes responses, are essential for recovery from primary or re-activation infection with VZV (17). The initial encounter of a naive immune-competent lymphocyte with an antigen induces a primary immune response; a later contact of the host with the same antigen will induce a more rapid and severe secondary immune response. Immunological response to chickenpox and zoster is different, advocating retinal involvements may show different clinical features. Chickenpox induces milder anti-varicella immune response which may contribute to rapid improvement of ocular inflammation with good visual prognosis and less anterior chamber inflammation in comparison to varicella zoster. Retinal involvement in chickenpox is less fulminant and less necrotic in nature than varicella zoster which may result in less retinal tear and retinal detachment.

Vasculitis in the form of phlebitis or arteriolitis, as another complication of chickenpox, may coexist with or without VZV retinitis. In eight of 22 reported chickenpox retinitis (36.3%), retinal vasculitis was coexisting with retinitis, as in our case. The exact mechanism of pathogenesis of venous thrombosis following VZV is not known as for arteriopathy, but the postulated theories are vasculitis, direct endothelial damage, or acquired protein S deficiency secondary to molecular mimicry (18). In our case, retinitis resolved successfully with anti-viral treatment in <4 weeks but macular edema due to occlusive vasculitis became the major problem to cope.

Varicella vaccine has been marketed since 2002, in Turkey. In 1st years of marketing a single dose vaccine after 12 months of age was recommended by pediatricians, as a result one dose of vaccine was given to our patient in 2004. One dose of vaccine showed good short-term efficacy in clinical trials, and in the first observational studies (19). However, recent studies on the causes, effects, and consequences of breakthrough varicella after one-dose vaccination show that varicella vaccine should be given in two doses at least 4–6 weeks apart to achieve effective, long-lasting protection against chickenpox (20).

Due to its low bioavailability oral administration of acyclovir is not adequate for initial treatment, the standard of treatment should be intravenous administration. The half-life of acyclovir in circulation is around 3 h, so it is necessary to administer three times daily. The dosage of 3×10 mg/kg is a common regimen for the initial treatment. Although there have been no controlled studies till now, oral treatment is recommended up to 3–4 months following initial intravenous treatment for ARN (21). Our case did not have ARN, only had a mild retinitis which resolved 4 weeks after the start of antiviral treatment. In addition, aqueous humor PCR was negative for VZV DNA at week 8 of treatment.

Therefore, we discontinued antiviral treatment at 8 weeks.

Clinicians should be aware of chickenpox as a cause of occlusive retinal vasculitis and retinitis even in vaccinated children. Without treatment, the prognosis is poor, with progressive retinitis and ischemia, complex retinal detachment; the outcome for these patients following vitrectomy remains poor (23). This case demonstrates that with early diagnosis and treatment, a good visual outcome can be achieved.

Conclusion

Clinicians should be aware of chickenpox as a cause of occlusive retinal vasculitis and retinitis even in vaccinated children. Without treatment, the prognosis is poor, with progressive retinitis and ischaemia, complex retinal detachment; the outcome for these patients following vitrectomy remains poor. 23 This case demonstrates that with early diagnosis and treatment, a good visual outcome can be achieved.

Disclosures

Informed consent: Written informed consent was obtained from the patient for the publication of the case report and the accompanying images.

Peer-review: Externally peer-reviewed.

Conflict of Interest: None declared.

Authorship Contributions: Concept – G.O.; Design – G.O.; Supervision – G.O., N.Y., H.A., E.I., E.T.; Materials – G.O., E.T.; Data collection and/or processing – G.O., E.T.; Analysis and/or interpretation – A.G.O., E.T.; Literature search – G.O., E.T.; Writing – G.O., E.T., P.B.K., N.Y.; Critical review – G.O., H.A., E.I., E.T.

References

1. Kim JH, Lee SJ, Kim M. External ophthalmoplegia with orbital myositis in an adult patient after chickenpox infection. *BMJ Case Rep.* 2014;2014:bcr201320241. [CrossRef]
2. Gargouri S, Khohtali S, Zina S, Khairallah M, Zone-Abid I, Kaibi I, et al. Ocular involvement associated with varicella in adults. *J Ophthalmic Inflamm Infect* 2016;6:1–5. [CrossRef]
3. Azevedo AR, Simões R, Silva F, Pina S, Santos C, Pêgo P, et al. Optic neuritis in an adult patient with chickenpox. *Case Rep Ophthalmol Med* 2012;2012:1–4. [CrossRef]
4. Ryu J, Park KA, Oh SY, Kim SJ, Cho K, Min JH, et al. Periopic neuritis related with varicella-zoster virus infection preceding sixth cranial nerve palsy and progressive outer retinal necrosis in an immunocompetent patient. *J Neurol Sci* 2017;373:155–6.
5. Biswas J, Nagpal A, Chopra S, Karna S. Resolution of chickenpox neuroretinitis with oral acyclovir: A case report. *Ocul Immunol Inflamm* 2003;11:315–8. [CrossRef]
6. Kitamei H, Namba K, Kitaichi N, Wakayama A, Ohno S, Ishida S. Chickenpox chorioretinitis with retinal exudates and periphlebitis. *Case Rep Ophthalmol* 2012;3:180–4. [CrossRef]
7. Kelly SP, Rosenthal AR. Chickenpox chorioretinitis. *Br J Oph-*

- thalmol 1990;74:698–9. [\[CrossRef\]](#)
8. Yu J, Ashworth J, Hughes S, Jones N. Varicella-zoster virus necrotising retinitis, retinal vasculitis and panuveitis following uncomplicated chickenpox in an immunocompetent child. *BMJ Case Rep* 2018;2018:bcr2017223823. [\[CrossRef\]](#)
 9. Poonyathalang A, Sukavatcharin S, Sujirakul T. Ischemic retinal vasculitis in an 18-year-old man with chickenpox infection. *Clin Ophthalmol* 2014;8:441–3. [\[CrossRef\]](#)
 10. Donbaloğlu M, Bozkurt B, Kerimoğlu H, Öztürk BT. Suçiçeği geçiren bir çocukta granümatöz ön üveit, internal oftalmopleji ve retinal vaskülit/Granulomatous anterior uveitis, internal ophthalmoplegia, and retinal vasculitis during chickenpox disease in a child. *Turk J Ophthalmol* 2013;43:358–61. [\[CrossRef\]](#)
 11. Capone AJ, Meredith TA. Central visual loss caused by chickenpox retinitis in a 2-year-old child. *Am J Ophthalmol* 1992;113:592–3. [\[CrossRef\]](#)
 12. Guex-crosier Y, Rochat C, Herbort CP, Guex-crosier Y, Rochat C. Necrotizing herpetic retinopathies a spectrum of herpes virus-induced diseases determined by the immune state of the host. *Ocul Immunol Inflamm* 1997;5:259–65. [\[CrossRef\]](#)
 13. Duker J, Blumenkranz M. Diagnosis and management of the acute retinal necrosis (ARN) syndrome. *Surv Ophthalmol* 1991;35:327–43. [\[CrossRef\]](#)
 14. Gupta M, Jardeleza MS, Kim I, Durand ML, Kim L, Lobo AM. Varicella zoster virus necrotizing retinitis in two patients with idiopathic CD4 lymphocytopenia. *Ocul Immunol Inflamm* 2016;24:544–8. [\[CrossRef\]](#)
 15. Centres for Disease Control. Chickenpox in the United States, 1972–77. *J Infect Dis* 1979;140:257–60. [\[CrossRef\]](#)
 16. Elnour AA. Evaluation the aggressive reaction of varicella in young adult immune system compared to children immune response. *MOJ Proteomics Bioinforma.* 2018;7:1–2. [\[CrossRef\]](#)
 17. Zerboni L, Sommer M, Ware CF, Arvin AM. Varicella-zoster virus infection of a human CD4-positive T-cell line. *Virology* 2000;285:278–85. [\[CrossRef\]](#)
 18. Sardana V, Mittal LC, Meena SR, Sharma D, Khandelwal G. Acute venous sinus thrombosis after chickenpox infection. *J Assoc Physicians India* 2014;62:741–3.
 19. Vázquez M, LaRussa P, Gershon A, Steinberg S, Freudigman K, Shapiro E. The effectiveness of the varicella vaccine in clinical practice. *N Engl J Med* 2001;344:955–60. [\[CrossRef\]](#)
 20. Wutzler P, Knuf M, Liese J. Varicella: Efficacy of two-dose vaccination in childhood. *Dtsch Arztebl Int* 2008;105:567–72. [\[CrossRef\]](#)
 21. Nussenblatt RB, Whitcup SM. Uveitis: Fundamentals and Clinical Practice. 3rd ed. Philadelphia, PA: Mosby, Inc.; 2004.
 22. Copenhaver RM, Gainesville F. Chickenpox with retinopathy. *Arch Ophthalmol* 1966;75:199–200. [\[CrossRef\]](#)
 23. Lee WH, Charles SJ. Acute retinal necrosis following chickenpox in a healthy 4 year old patient. *Br J Ophthalmol* 2000;84:667–72. [\[CrossRef\]](#)
 24. Culbertson WW, Brod RD, Flynn HW, Taylor BC, Brod BA, Lightman DA, et al. Chickenpox-associated acute retinal necrosis syndrome. *Ophthalmology* 1991;98:1641–6. [\[CrossRef\]](#)
 25. Aslan O, Soykan E, Ozkan SS. Varicella chorioretinitis. *Acta Ophthalmol Scand* 2007;85:907–8. [\[CrossRef\]](#)
 26. Matsuo T, Koyama M, Matsuo N. Acute retinal necrosis as a novel complication of chickenpox in adults. *Br J Ophthalmol* 1990;74:443–4. [\[CrossRef\]](#)
 27. Smith JR, Chee SP. Complicating. *Chickenpox* 2000;41:602–3.
 28. Tajunisah I, Reddy SC. Acute retinal necrosis complicating chicken pox in a healthy adult. *Ann Ophthalmol* 2007;39:57–62.
 29. Bolivar G, Gorrondo MB, Paz J, Pajera J. Acute retinal necrosis syndrome following chickenpox/Síndrome de necrosis retiniana aguda tras. *Arch Soc Esp Oftalmol* 2007;82:579–81. [\[CrossRef\]](#)
 30. Ehongo-Bidime A, Pereleux A, Zanen A. Necrose retinienne aigue postvaricelleuse. *Bull Soc Beige Ophtalmol* 1995;255:61–8.
 31. Barondes MJ, Tellez F, Siegel A. Acute retinal necrosis after chickenpox in a healthy adult. *Ann Ophthalmol* 1992;24:335–6.