



Acute Myopic Shift and Internal Limiting Membrane Folds Linked to Topiramate Use: A Case Report

 Levent Dogan

Department of Ophthalmology, Tatvan State Hospital, Bitlis, Turkey

Abstract

We present a case report of a 26-year-old female patient with acute visual impairment, who had been treated with 50 mg/day topiramate for 5 days for migraine prophylaxis. Ocular examination showed bilateral anterior chamber narrowing and macular striae. She had no previous ocular pathology, but her cycloplegic refraction showed a myopic shift of about 6 D. Topiramate was stopped and the patient's unaided visual level and macular stria returned to normal with topical steroid and cyclopentolate treatment. Recognition of this side effect and discontinuation of the causative drug may prevent angle closure and related vision loss.

Keywords: Visual impairment, myopic shift, macular striae, topiramate

Introduction

Topiramate is a sulfa-derivative monosaccharide that was first approved by the Food and Drug Administration for the treatment of epilepsy. Later it was used for migraine prophylaxis (1). The other rare indications of topiramate are bipolar diseases, neuropathic pain, and idiopathic intracranial hypertension, as well as obesity as it can cause weight loss (2).

Some of the ocular side effects of topiramate are acute myopia, angle-closure glaucoma, and retinal folds (3). In our case report, we aimed to present a case of acute visual impairment with bilateral macular striae due to topiramate.

Case Report

A 26-year-old female patient was admitted to the emergency department due to acute visual impairment. She had a history of uncomplicated ischemic cerebrovascular stroke during her pregnancy period. There was no finding other than decreased vision in the neurological examination of the patient. Brain diffusion MRI was normal. In the ophthalmological examination, the Snellen unaided visual acuity was 2/60 in both eyes. Prior to this emergency department admission, she had no medical history related to vision. Her clinical history was unremarkable except for the cerebrovascular event she had during her pregnancy 6 years ago, and she had a known migraine disease. Oral

How to cite this article: Dogan L. Acute Myopic Shift and Internal Limiting Membrane Folds Linked to Topiramate Use: A Case Report. *Beyoglu Eye J* 2022; 7(1): 71-75.

Address for correspondence: Levent Dogan, MD. Goz Hastaliklari Anabilim Dali, Tatvan Devlet Hastanesi, Bitlis, Turkey

Phone: +90 538 685 22 32 **E-mail:** drleventdogan@gmail.com

Submitted Date: July 17, 2021 **Accepted Date:** December 28, 2021 **Available Online Date:** February 18, 2022

©Copyright 2022 by Beyoglu Eye Training and Research Hospital - Available online at www.beyoglueye.com

OPEN ACCESS This work is licensed under a Creative Commons Attribution-NonCommercial-ShareAlike 4.0 International License.



topiramate treatment had been started for migraine prophylaxis 5 days before the onset of visual impairment. She was taking a dose of 50 mg of topiramate per day. At admission, the intraocular pressure was 17 mmHg in the right eye and 19 mmHg in the left eye. In the anterior segment examination, the anterior chamber was clear and shallow (grade 2, Schaffer grading system, closure possible). The iris-lens diaphragm was bowed anteriorly. There was no corneal edema and reactive afferent pupillary defect.

The refractometry showed myopization of -6.50 D in the right eye and -6.00 D in the left eye. Her best corrected visual acuity was noted as 20/25 (Snellen) OU af-

ter refraction to -6.00 D sphere. We noticed prominent retinal folds limited to macula with symmetrically normal disk in the fundus examination (Fig. 1a, b). We have seen macular folds more clearly at red-free fundus photos (Fig. 2a, b). Correspondingly, spectral domain optical coherence tomography (SD-OCT) demonstrated the macular striae (Fig. 3a, b). Considering bilateral myopization, narrow anterior chamber, and macular striae developed after topiramate treatment, we associated the acute visual impairment to topiramate use. Topiramate was stopped and both eyes were treated with topical prednisolone acetate five times per day and cyclopentolate three times per day. The patient

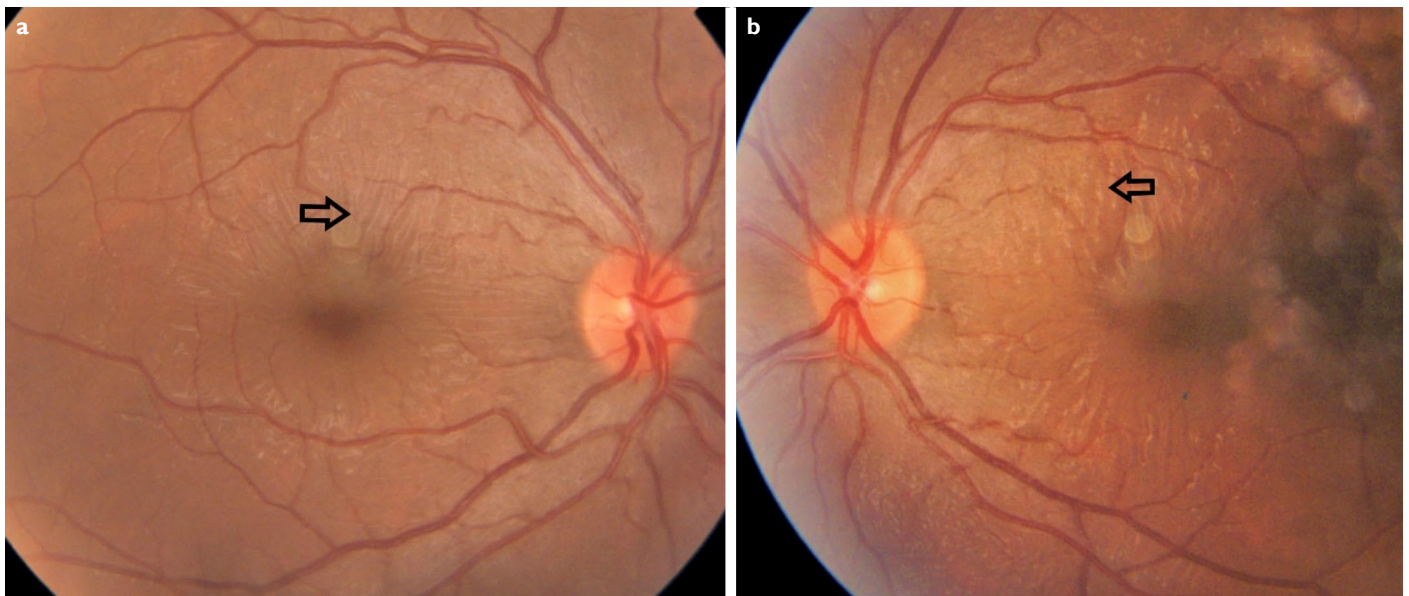


Figure 1. Color fundus photos of right (a) and left (b) eye with macular striae

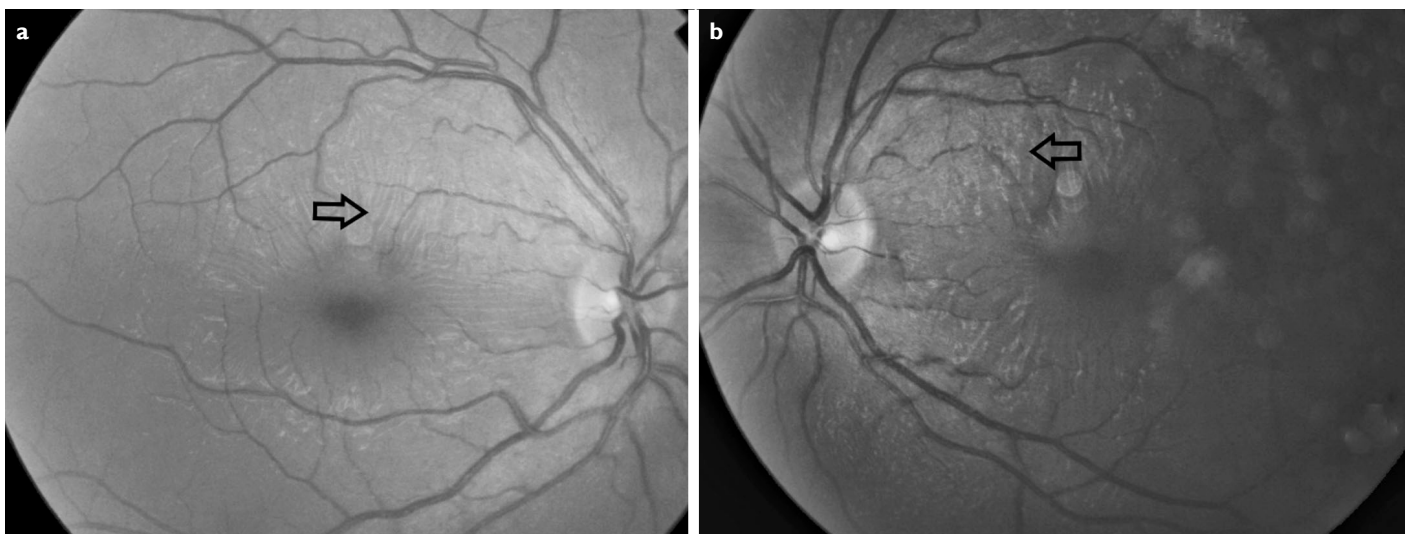

Figure 2. Red free fundus photos of right (a) and left (b) eye with macular striae.

was examined after 5 days, her acute myopia resolved, and the anterior chamber deepened. Cyclopentolate was stopped at the end of the 7th day. The macular folds and myopization were completely resolved and these findings

supported with SD-OCT (Figs. 4a, b and 5a, b) after one month. The topical steroid treatment was tapered off and stopped at the end of 1 month. The patient provided informed written consent for the publication of the case.

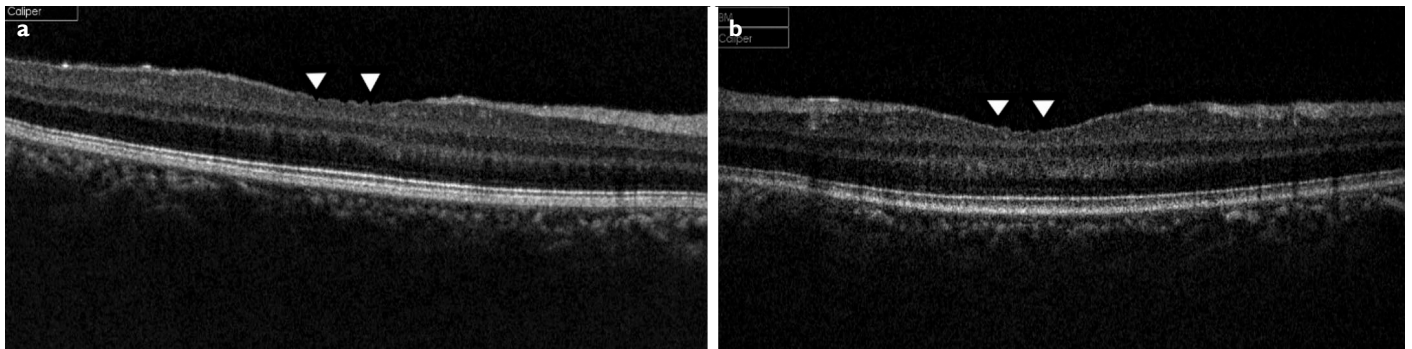


Figure 3. Spectral domain optical coherence tomography (SD-OCT) images of right (a) and left (b) eye with changes of internal limiting membrane.

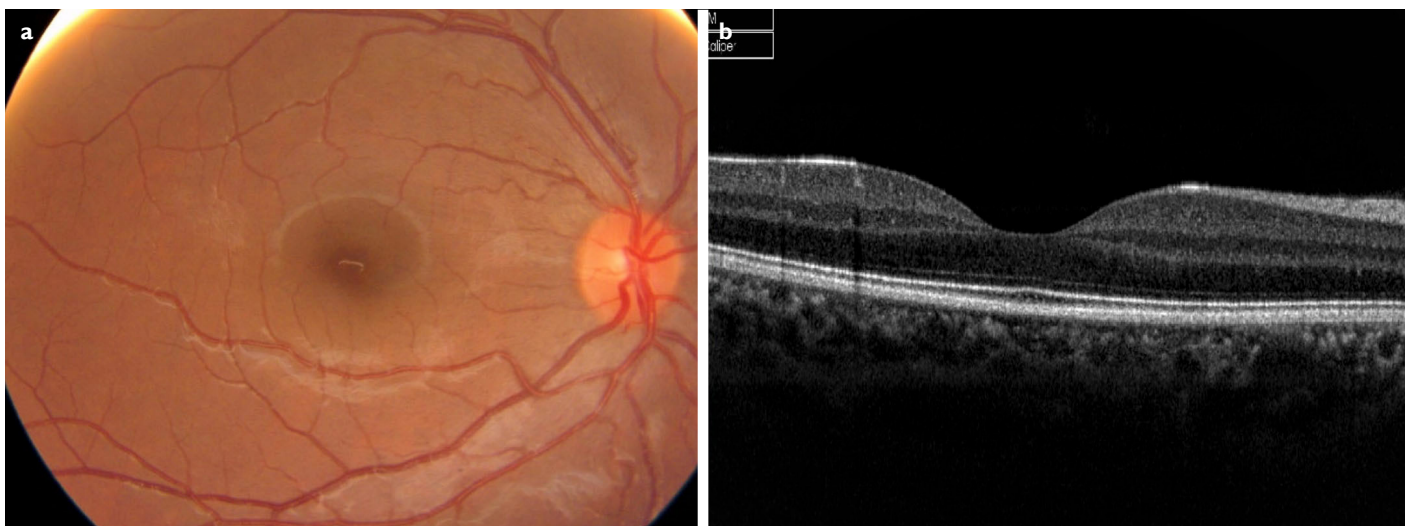


Figure 4. Color fundus photo (a) and SD-OCT image of the right eye (b) after 1 month.

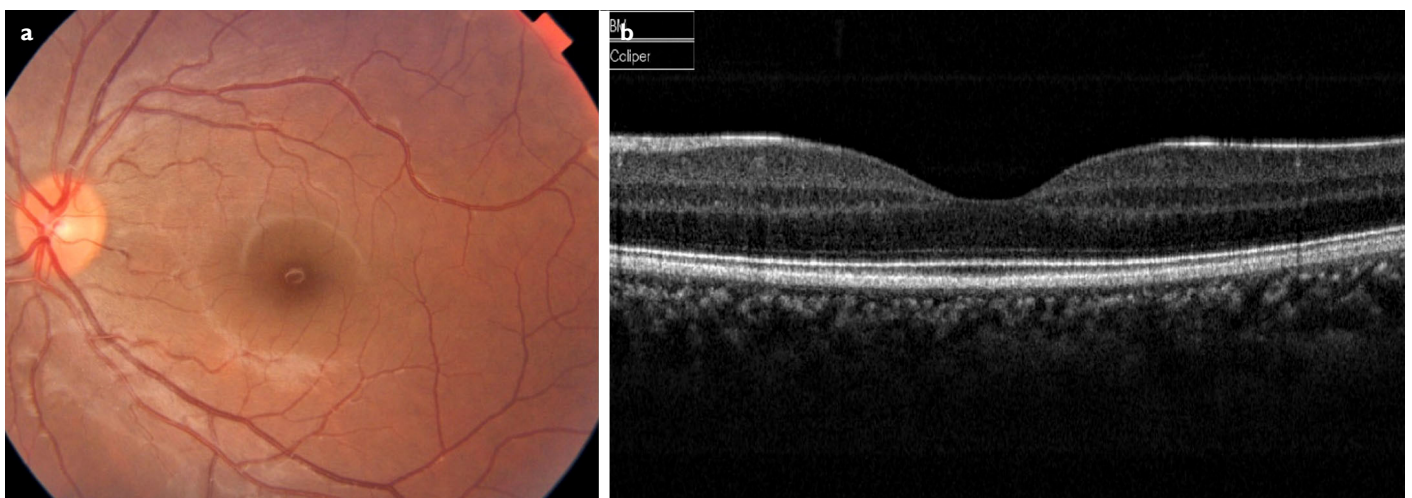


Figure 5. Color fundus photo (a) and SD-OCT image of the left eye (b) after 1 month.

Discussion

Schear et al. have presented a case of acute myopization associated with topiramate therapy for the first time in the literature (4). Then, several cases about acute angle closure and myopization linked to topiramate treatment have been presented (5,6). Except topiramate, other drugs, such as acetazolamide, chlorothiazide, ethoxzolamide, and indapamide, induce myopia (7). The accused mechanism in the cases associated with topiramate therapy is different from pupillary block angle closure. The accused mechanism in the shallowing of the anterior chamber and acute angle closure was associated with effusion and then forward rotation of the ciliary process. As a result of the forward shift of the iris-lens diaphragm, acute myopia occurs (8). The most common ocular adverse effect of topiramate is acute angle closure glaucoma (AACG) (53–74.8% of the cases), and the second most common adverse effect is the myopic shift. AACG is commonly seen in 7–12 days after the topiramate therapy and myopization took about 8.59 days to the occurrence (9). In our case, the patient had been taking the topiramate for 5 days, and she had a narrow anterior chamber but there was no angle closure. Her intraocular pressure was 17 and 19 mmHg in right and left eyes, respectively. In addition, about 89% of reported adverse events have occurred in female patients (9).

Macular stria is another adverse effect associated with topiramate use and has a different presentation in reported cases. Natesh et al. (10) presented a case with subtle internal limiting membrane (ILM) folds. Gualtieri et al. (11) showed full-thickness retinal and choroidal folds. The retinal striae may be caused by mild vitreoretinal traction with the forward shift of iris-lens diaphragm, especially ILM folds, and inner retinal changes may be due to vitreoretinal traction (12). Moreover, posterior choroidal effusion causes the choroidal and outer retinal changes in the advanced cases (12). In our case, retinal changes were limited with subtle ILM folds, which were resolved at 1 month following cessation of topiramate. In these cases, and our case, retinal toxicity was temporary, but Beyenburg et al. reported persistent retina pigment epithelial abnormalities and visual impairment 6 months after cessation of the drug (13).

The first step in the management of topiramate-related side effects is the discontinuation of the drug, and the discontinuation of topiramate should be coordinated with the neurologist. Aqueous suppressants can be used to reduce increased intraocular pressure, but acetazolamide and miotics should be avoided. Further displacement of the ciliary body may be triggered by topical pilocarpine; therefore, the instillation of pilocarpine is contraindicated. Laser iridotomy

and peripheral iridectomy are not necessary because there is no real pupillary block component (14). Cycloplegic drugs can be used to reduce the circumferential muscle tension in the ciliary body. Topical steroids are used to decrease the ciliary effusion by increasing the stabilization of cell membranes (14).

In cases of acute myopic shift or angle closure glaucoma without pupillary block, ophthalmologists must keep in mind that topiramate may be used, especially by patients with no previous eye problem. Topiramate has a wide range of indications; therefore, ophthalmologists and neurologists need to be aware of potential ocular side effects. Finally, visual impairment and macular striae associated with topiramate use usually resolve completely after conservative treatment without any permanent visual impairment.

Disclosures

Informed consent: Written informed consent was obtained from the patient for the publication of the case report and the accompanying images.

Peer-review: Externally peer-reviewed.

Conflict of Interest: None declared.

References

1. Ramadan NM, Buchanan TM. New and future migraine therapy. *Pharmacol Ther* 2006;112:199–212. [CrossRef]
2. Fariba K, Saadabadi A. Topiramate. [Updated 2020 Dec 5]. In: StatPearls [Internet]. Treasure Island (FL): StatPearls Publishing; 2021 Jan-. Available at: <https://www.ncbi.nlm.nih.gov/books/NBK554530/>. Accessed Jan 17, 2022.
3. Banta JT, Hoffman K, Budenz DL, Ceballos E, Greenfield DS. Presumed topiramate-induced bilateral acute angle-closure glaucoma. *Am J Ophthalmol* 2001;132:112–4. [CrossRef]
4. Schear NJ, Rowan AJ, Wiener JA, Haug SJ, Mindel JS. Drug-induced myopia: a transient side effect of topiramate. *Epilepsia* 1990;31:643.
5. Koçer AM, Bahar TS, Elgin KU. Topiramata bağlı miyopik kayma ve akut bilateral açığı kapanması glokomu. *Glokom Katarakt* 2019;14:47–50.
6. Orum O, Tarakcioglu H, Yigit U. Topiramate-induced myopic shift and bilateral secondary angle-closure glaucoma. *TJO* 2012;42:154–6.
7. Kalina PH, Kalina AG. Bilateral transient myopia induced by oral acetazolamide in the early postoperative period after phacoemulsification. *JCRS* 2020;8:1–3.
8. Craig JE, Ong TJ, Louis DL, Wells JM. Mechanism of topiramate-induced acute-onset myopia and angle closure glaucoma. *Am J Ophthalmol* 2004;137:193–5. [CrossRef]
9. Abtahi MA, Abtahi SH, Fazel F, Roomizadeh P, Etemadifar M,

- Jenab K, et al. Topiramate and the vision: a systematic review. *Clin Ophthalmol* 2012;6:117–31. [\[CrossRef\]](#)
10. Natesh S, Rajashekhara SK, Rao AS, Shetty B. Topiramate-induced angle closure with acute myopia, macular striae. *Oman J Ophthalmol* 2010;3:26–8. [\[CrossRef\]](#)
11. Gualtieri W, Janula J. Topiramate maculopathy. *Int Ophthalmol* 2013;33:103–6. [\[CrossRef\]](#)
12. Sears N, Modi YS, Engel R, Singh RP. Topiramate-induced myopic shift with associated retinal striae. *Can J Ophthalmol* 2015;50:e46–50. [\[CrossRef\]](#)
13. Beyenburg S, Weyland C, Reuber M. Presumed topiramate-induced maculopathy. *Epilepsy Behav* 2009;14:556–9. [\[CrossRef\]](#)
14. Guier CP. Elevated intraocular pressure and myopic shift linked to topiramate use. *Optom Vis Sci* 2007;84:1070–3. [\[CrossRef\]](#)