



Treatment of Intravitreal Ranibizumab Resistant Radiation Retinopathy with Intravitreal Dexamethasone Implant: A Case Report

Mehmet Cem Sabaner, Mustafa Dogan

Department of Ophthalmology, Faculty of Medicine, Afyonkarahisar Health Sciences University, Afyonkarahisar, Türkiye

Abstract

A 43-year-old female patient presented with complaints of decreased vision in both eyes. Her medical history revealed the diagnosis of metastatic breast cancer. She was treated with chemotherapy, and whole-brain, manubrium sterni, and right chest wall radiation therapy. Best-corrected visual acuity (BCVA) was 20/200 and 20/160 in the right and left eye, respectively. Optical coherence tomography (OCT) confirmed the presence of cystoid macular edema (CME). OCT angiography confirmed the presence of microaneurysms, ischemia, and capillary drop-out on the macula. Fundus fluorescein angiography revealed multiple microaneurysms with surrounding ischemia and leakage. Based on these findings and medical history, a diagnosis of radiation maculopathy was considered. The patient was administered intravitreal four doses of ranibizumab injections. Laser photocoagulation was performed on the ischemic areas of the retina in both eyes. Despite the follow-up and treatment, the presence of residual CME and BCVA 20/200 in both eyes was determined; it was decided to change the treatment regimen to an intravitreal dexamethasone implant. One month after injection, BCVA was 20/80 in both eyes, and normal foveal contour and no edema as confirmed on OCT. The DEX implant showed a promising result and should be kept in mind in the treatment of radiation retinopathy.

Keywords: Cystoid macular edema, dexamethasone, ischemia, radiation retinopathy, ranibizumab

Introduction

Radiation retinopathy is a vision-threatening complication that can occur with the effect of irradiation applied to the globe and orbit, as well as the head and neck (1,2). The total dosage and daily fraction size, the applied area, and the type of irradiation affect the incidence and severity of radiation retinopathy (3,4). It occurs due to progressive occlusive microangiopathy of retinal capillaries due to endothelial

cell damage (1-4). Different treatment modalities have been tried so far including laser photocoagulation, intravitreal triamcinolone, and intravitreal anti-vascular endothelial growth factor agents with variable results (2,5-9).

In this report, we describe the case of a female patient who developed radiation retinopathy with ranibizumab-resistant macular edema, as a result of irradiation for brain metastatic breast cancer, and was treated with intravitreal dexamethasone (DEX) implant.

How to cite this article: Sabaner MC, Dogan M. Treatment of Intravitreal Ranibizumab Resistant Radiation Retinopathy with Intravitreal Dexamethasone Implant: A Case Report. *Beyoglu Eye J* 2022; 7(4): 324-328.

Address for correspondence: Mehmet Cem Sabaner, MD. Department of Ophthalmology, Faculty of Medicine, Afyonkarahisar Health Sciences University, Afyonkarahisar, Türkiye
Phone: +90 536 261 62 83 **E-mail:** drmcemsabaner@yahoo.com

Submitted Date: April 09, 2022 **Revised Date:** June 12, 2022 **Accepted Date:** June 23, 2022 **Available Online Date:** November 15, 2022

Beyoglu Eye Training and Research Hospital - Available online at www.beyoglueye.com

OPEN ACCESS This is an open access article under the CC BY-NC license (<http://creativecommons.org/licenses/by-nc/4.0/>).



Case Report

A 43-year-old female patient presented with complaints of decreased vision in both eyes. Her medical history revealed the diagnosis of metastatic breast cancer in the same year. At the time of diagnosis, she had metastasis to the brain and manubrium sterni. She was treated with chemotherapy and whole-brain, manubrium sterni, and right chest wall radiation therapy ($300 \times 10:3000$ cGy) in the medical and radiation oncology departments of our clinic. She had no other systemic disease. On presentation, best-corrected visual acuity (BCVA) was 20/200 and 20/160 in the right eye and left eye, respectively. Fundus examination revealed cystoid macular edema (CME). Optical coherence tomography (OCT) confirmed the presence of CME. Furthermore, OCT revealed serous macular detachment (SMD) in the right eye. Optical coherence tomography angiography (OCTA) confirmed the presence of microaneurysms, ischemia, and capillary drop-out on the macula (Fig. 1). Fundus fluorescein angiography (FFA) revealed multiple microaneu-

rysms with surrounding ischemia and leakages corresponding to microaneurysms (Fig. 2). The maculopathy that concerning the radiotherapy and the radiation dose delivered, confirmed the diagnosis of radiation maculopathy. The patient was administered intravitreal four doses of ranibizumab (Lucentis, Novartis, Basel Switzerland) injections to each eye with monthly follow-up in 6 months. Laser photocoagulation was performed on the ischemic areas of the retina in both eyes. Despite the follow-up and treatment, BCVA was 20/200 in both eyes. The OCT revealed SMD and persistent CME in both eyes. Following the decision to change the treatment option, intravitreal DEX (Ozurdex, Allergan, Irvine, California, USA), a sustained-release intravitreal implant of 0.7 mg DEX, was administered. One month after injection, BCVA was 20/80 in both eyes and OCT showed normal foveal contour and no macular edema (Fig. 3). No side effects or complications including increased intraocular pressure were observed. No recurrence was observed 3 months after the DEX implant. However, follow-up of the patient continues in the ophthalmology department within

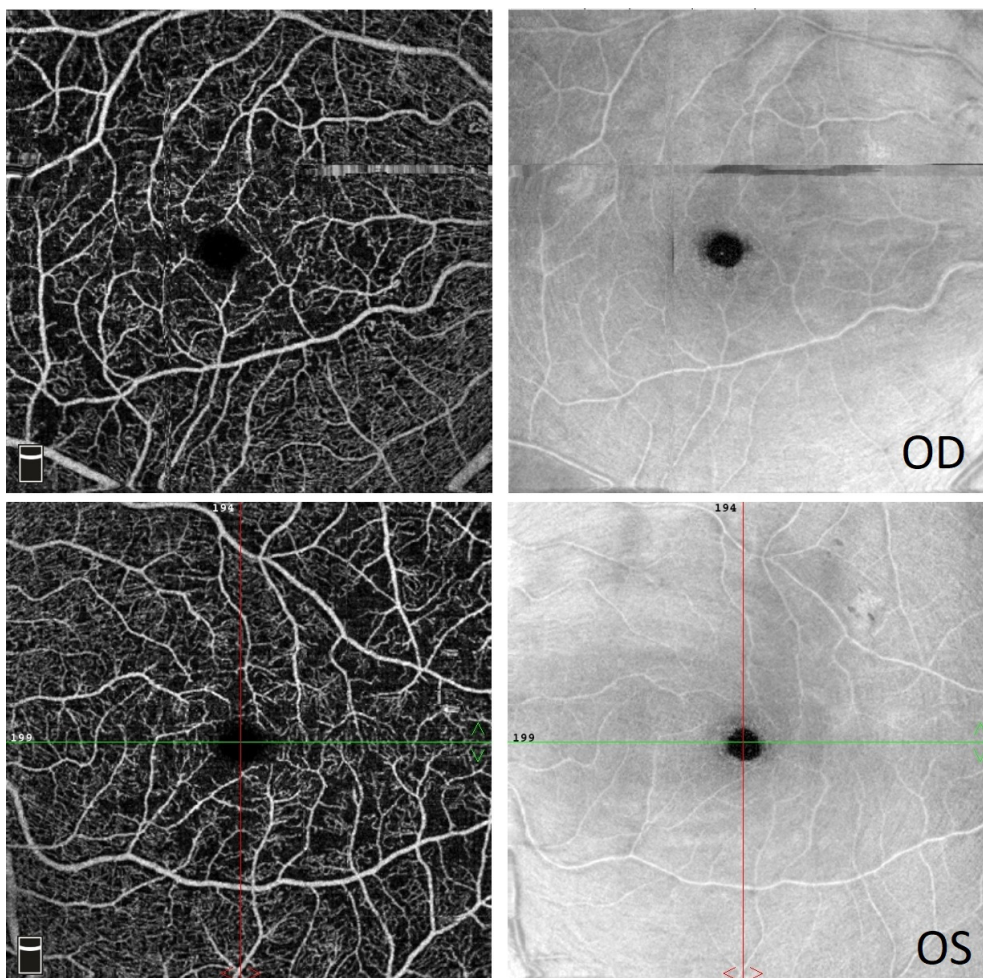


Figure 1. Optical coherence tomography angiography scan revealed the presence of microaneurysms, ischemia, and capillary drop-out in both macula.

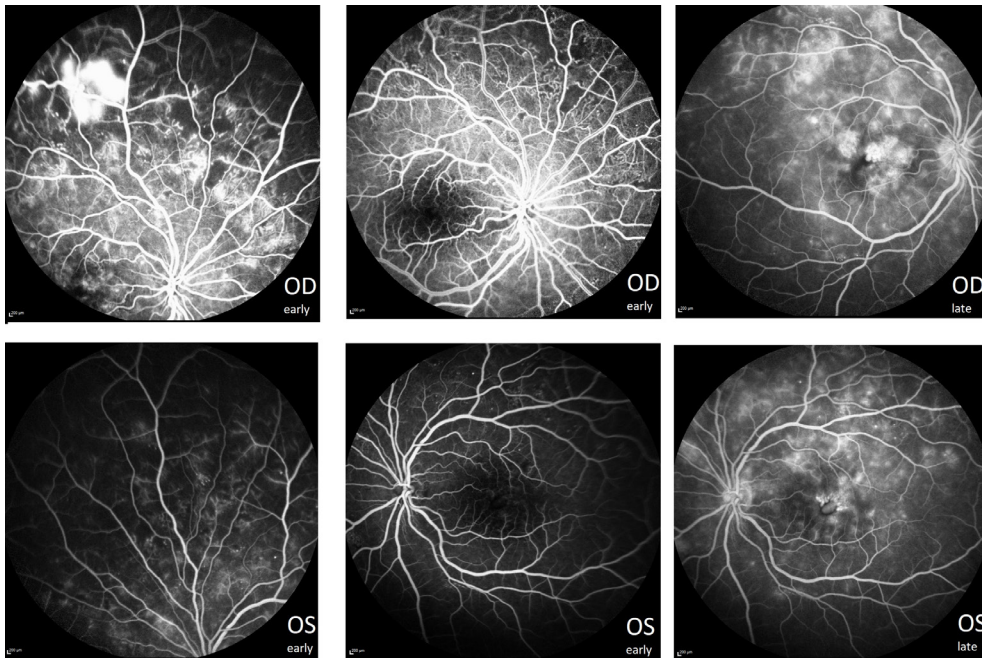


Figure 2. Fundus fluorescein angiography showed multiple microaneurysms with surrounding ischemia in the early stage and leakages in the late stage in both eyes.

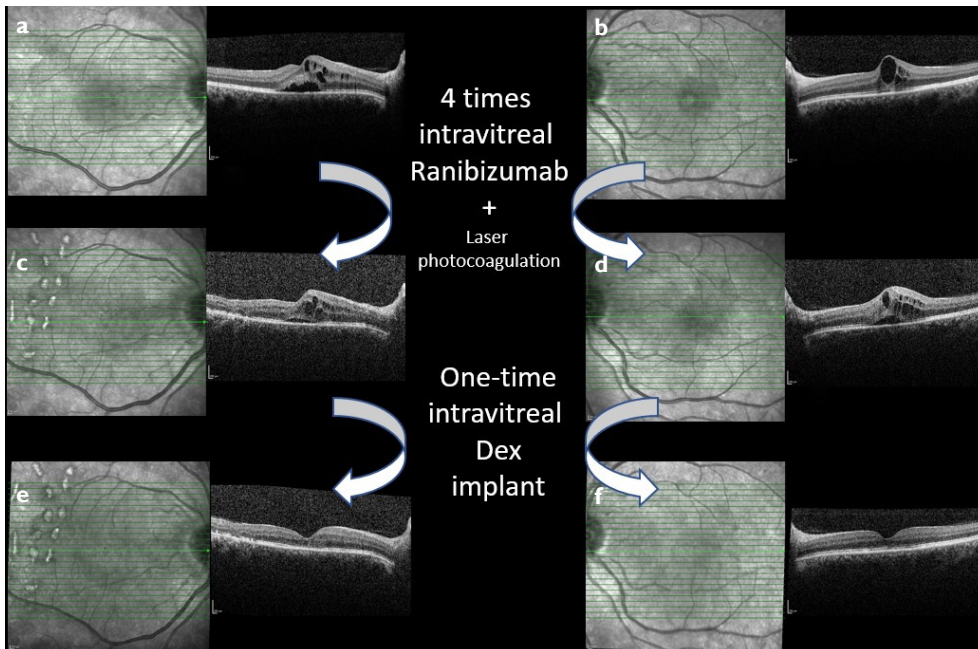


Figure 3. Optical coherence tomography images of a patient with radiation retinopathy and related macular edema. (a, b) Note that before injection of intravitreal ranibizumab, presence of cystoid macular edema (CME) in both eyes and serous macular detachment (SMD) in the right eye. Central macular thickness (CMT) was 392 μm (including 205 μm subretinal fluid) in right and 501 μm in the left eye. (c, d) After four times injections of ranibizumab, persistent CME and presence of bilateral SMD were present. CMT was 355 μm (including 109 μm subretinal fluid) in right and 522 μm (including 188 μm subretinal fluid) in the left eye. (e, f) After implantation of intravitreal dexamethasone implant, the disappearance of CME and normalization of foveal contour in both eyes. CMT was 183 μm in right and 197 μm in the left eye.

the pro re nata (PRN) strategy, and intravitreal anti-VEGF or DEX administration was planned in case of recurrence. Written informed consent was obtained for all injections. Furthermore, signed informed consent was obtained from the patient for the publication and any accompanying images. This case report is following the ethical principles outlined in the Declaration of Helsinki.

Discussion

Radiation maculopathy can occur after plaque radiotherapy and external beam radiotherapy for diseases such as primary choroidal melanoma, neck and head cancers, metastases, leukemia, and non-neoplastic Graves' disease (4-9). Although various precautions are taken for patients during and after radiotherapy, unfortunately, radiation maculopathy can still be encountered today. Our patient had received external beam radiotherapy due to the diagnosis of brain and sternum metastasis of the primary breast cancer.

Retinopathy ordinarily occurs 6 months to 3 years after irradiation sessions (1,5,9). Furthermore, when it occurs, unluckily, it is irreversible. This delayed effect is explained by abnormal aberrant mitotic processes and the chronic endothelial toxic effects of radiation. In this patient, blurred vision complaints, and macular edema confirmed with OCT were detected approximately 9 months after irradiation.

The threshold for radiation retinopathy is 45–50 Gy with daily fractions of 1.8–2 Gy. Using larger beam, doses and rates increase radiation complications (2,5). Radiation retinopathy develops in more than 50% of patients who receive an average of 65 Gy to a healthy retina (5). In this case, retinopathy developed despite irradiation of 30 Gy in total. For this reason, it will be appropriate to perform an eye examination of patients who are irradiated even at this dose.

Demonstration of capillary non-perfusion in FFA is important in the diagnosis of radiation retinopathy (1,2). Furthermore, vascular occlusive changes, venous beading, microaneurysm, intraretinal microangiopathy, vascular dilatation, neovascularization, and retinal hemorrhage can be detected, and macular leakage can be observed in the presence of macular edema (5-9). In this case, leakage was detected due to macular edema, and severe vascular occlusion findings were observed by OCTA and FFA.

Macular laser, anti-VEGF agents, triamcinolone acetonide, and the DEX implant are used in the treatment of macular edema, which is suggested to be due to ischemic damage (2,5-9). However, the DEX implant is not an approved treatment for radiation retinopathy and is used off-label. Although the response to anti-VEGF therapy is reported to be good, persistent or resistant macular edema may also be seen (7-9). In addition, control of macular edema and retinal structure with OCT is recommended after 3 to 5 intravitreal

anti-VEGF loading doses in diabetic macular edema (10,11). Although three loading doses are generally valid in Türkiye, there may be differences between the opinion of physicians and clinics. Since radiation retinopathy is an occlusive event similar to diabetic retinopathy, similar initial treatment may be rational. For these reasons, the treatment was planned four loading injections of intravitreal anti-VEGF for this radiation maculopathy and related macular edema case. After loading doses, the visual acuity of the patient decreased on the left (20/160 to 20/200), remained the same in the right eye (both 20/200); also, macular edema increased in the left eye (CMT: 501 to 522 μm), and although subretinal fluid decreased (205 to 109 μm) in the right, macular cystoid edema persisted, and the sensorineural retinal thickness increased (187 to 246 μm). Therefore, due to all these, this situation is considered an insufficient response/resistance to ranibizumab. A previous case report showed the fine result of the DEX implant for bevacizumab-resistant macular edema (8). In this case report, a ranibizumab-resistant macular edema case successfully showed functional and anatomical recovery with DEX. However, the DEX implant is generally not recommended as the first treatment option due to ischemic and occlusive events. Apart from these, follow-up of the patient is important because radiation retinopathy is an entity where recurrence can occur (9,12). For this reason, follow-up of this patient continues within the PRN regimen.

Conclusion

The intravitreal DEX implant showed a promising result and should be kept in mind in the treatment of radiation retinopathy and related macular edema. It may represent an alternative selection in those with suboptimal response, resistance, or contraindication to intravitreal anti-VEGF therapy. Furthermore, we recommend that patients irradiated to the head and neck region undergo a dose-independent routine eye examination.

Declaration

This case report was presented in “The 4th Beyoglu Goz Gunleri” Symposium in 2020, Istanbul, Türkiye (Poster No: 2020/2). Signed informed consent was obtained from the patient.

Disclosures

Informed consent: Written informed consent was obtained from the patient for the publication of the case report and the accompanying images.

Peer-review: Externally peer-reviewed.

Conflict of Interest: None declared.

Authorship Contributions: Concept: M.C.S., M.D.; Design: M.C.S., M.D.; Supervision: M.D.; Data collection and/or processing: M.C.S.; Analysis and/or interpretation: M.C.S., M.D.; Literature search: M.C.S., M.D.; Writing: M.C.S., M.D.; Critical reviews: M.C.S., M.D.

References

1. Gupta A, Dhawahir-Scala F, Smith A, Young L, Charles S. Radiation retinopathy: Case report and review. *BMC Ophthalmol* 2007;7:6. [\[CrossRef\]](#)
2. Grange JD. Radiation-induced retinopathy. *J Fr Ophtalmol* 2001;24:993–1003.
3. Naseripour M, Falavarjani KG, Mirshahi R, Sedaghat A. Optical coherence tomography angiography (OCTA) applications in ocular oncology. *Eye (Lond)* 2020;34:1535–45. [\[CrossRef\]](#)
4. Özcan G, Gündüz AK, Mirzayev İ, Oysul K, Uysal H. Early results of stereotactic radiosurgery in Uveal melanoma and risk factors for radiation retinopathy. *Turk J Ophthalmol* 2020;50:156–62.
5. Reichstein D. Current treatments and preventive strategies for radiation retinopathy. *Curr Opin Ophthalmol* 2015;26:157–66.
6. Seibel I, Vollhardt D, Riechardt AI, Rehak M, Schmied S, Schiller P, et al. Influence of Ranibizumab versus laser photocoagulation on radiation retinopathy (RadiRet)- a prospective randomized controlled trial. *Graefes Arch Clin Exp Ophthalmol* 2020;258:869–78. [\[CrossRef\]](#)
7. Horowitz SA, Damasceno NP, Damasceno EF. Treatment of radiation retinopathy with intravitreal injection of ranibizumab (Lucentis®). *Int Med Case Rep J* 2020;13:27–32. [\[CrossRef\]](#)
8. Tarmann L, Langmann G, Mayer C, Weger M, Haas A, Wackernagel W. Ozurdex(®) reduces the retinal thickness in radiation maculopathy refractory to bevacizumab. *Acta Ophthalmol* 2014;92:e694–6. [\[CrossRef\]](#)
9. Fallico M, Chronopoulos A, Schutz JS, Reibaldi M. Treatment of radiation maculopathy and radiation-induced macular edema: A systematic review. *Surv Ophthalmol* 2021;66:441–60. [\[CrossRef\]](#)
10. Sugimoto M, Tsukitome H, Okamoto F, Oshika T, Ueda T, Niki M, et al. Clinical preferences and trends of anti-vascular endothelial growth factor treatments for diabetic macular edema in Japan. *J Diabetes Investig* 2019;10:475–83. [\[CrossRef\]](#)
11. Huang WH, Lai CC, Chuang LH, Huang JC, Wu CH, Lin YT, et al. Foveal microvascular integrity association with anti-VEGF treatment response for diabetic macular edema. *Invest Ophthalmol Vis Sci* 2021;62:41. [\[CrossRef\]](#)
12. Finger PT, Chin KJ, Semenova EA. Intravitreal anti-VEGF therapy for macular radiation retinopathy: A 10-year study. *Eur J Ophthalmol* 2016;26:60–6. [\[CrossRef\]](#)