



Choroidal and Macular Thickness in Eyes with Amblyopia

Rengin Aslihan Kurt.¹ Sezin Akca Bayar.² Zeynep Eylul Ercan.²

Eylem Yaman Pinarci.¹ Mustafa Agah Tekindal.³ Sibel Oto²

¹Department of Ophthalmology, Baskent University Istanbul Health Application Research Center, Istanbul, Turkey

²Department of Ophthalmology, Baskent University Faculty of Medicine, Ankara, Turkey

³Department of Biostatistics, Baskent University Faculty of Medicine, Ankara, Turkey

Abstract

Objectives: This study was performed to assess and analyze the retinal and choroidal thickness in amblyopic eyes using spectral-domain optical coherence tomography and enhanced depth imaging optical coherence tomography.

Methods: A total of 67 children with amblyopia and 31 age- and gender-matched healthy non-amblyopic control subjects were enrolled in the study. The 67 amblyopic children were divided into 3 groups: hypermetropic amblyopia (Group 1), microesotropia (Group 2), and myopic anisometropia (Group 3). All of the participants underwent a detailed ophthalmologic examination and orthoptic assessment. The subfoveal choroidal thickness was measured at 500-, 750-, 1000-, and 1500-micron intervals nasally and temporally. Central macular thickness was also measured in the subfoveal, parafoveal inferior, parafoveal superior, parafoveal nasal, and parafoveal temporal superior, inferior, nasal, and temporal quadrants. All of the parameters of the amblyopic eyes, fellow eyes, and control eyes were compared.

Results: In all, 34 female and 33 male patients were studied. The mean age was 8.6 ± 2.8 years (range: 5–12 years). Comparison of the choroidal thickness and macular thickness measurements between the amblyopic and non-amblyopic eye of the same patient within each group revealed no statistically significant differences. Comparison of the findings in the amblyopic eyes of Group 1 and Group 3 with the control group revealed that the choroidal thickness measurements were smaller in the amblyopic eyes in all quadrants, however, only the nasal quadrant measurements demonstrated a statistical significance. The subfoveal macular thickness value was also smaller in both groups when compared with the control eyes.

Conclusion: Our results indicated that amblyopia, whether anisometropic or microtropic, did not seem to significantly affect choroidal thickness.

Keywords: Amblyopia, choroidal thickness, enhanced depth imaging optical coherence tomography

Introduction

The most common cause of unilateral vision impairment in children and young adults is amblyopia, with a prevalence of 0.72–3.29% (1). Amblyopia may be secondary to strabismus,

aniso-metropia or deprivation (2). It is very well known that amblyopia is related to the changes in visual cortex however changes in retina and choroid had been investigated by many different authors and varying results had been achieved (3).

How to cite this article: Kurt RA, Akca Bayar S, Ercan ZE, Yaman Pinarci E, Tekindal MA, Oto S. Choroidal and Macular Thickness in Eyes with Amblyopia. *Beyoglu Eye J* 2021; 6(4): 320-327.

Address for correspondence: Rengin Aslihan Kurt, MD, Baskent Universitesi Istanbul Saglik Uygulama Arastirma Merkezi, Goz Hastaliklari Bolumu, Istanbul Turkey

Phone: +90 532 394 10 46 **E-mail:** renginakurt@yahoo.com

Submitted Date: August 02, 2021 **Accepted Date:** October 11, 2021 **Available Online Date:** December 17, 2021

©Copyright 2021 by Beyoglu Eye Training and Research Hospital - Available online at www.beyoglu-eye.com

OPEN ACCESS This work is licensed under a Creative Commons Attribution-NonCommercial-ShareAlike 4.0 International License.



In the past decade, choroidal imaging has emerged with the advent of advanced imaging technologies, especially with the use of enhanced depth imaging optical coherence tomography (EDI-OCT) (4). EDI-OCT has enabled in vivo cross-sectional choroidal imaging and accurate quantitative analysis of choroidal thickness. Besides retina and choroid morphology in healthy children, the effect of amblyopia on retinal and choroidal morphology has been an area of interest (5-7).

Methods

Patients aged between 5 and 12 years, who were amblyopic due to anisometropia or microtropia were included in the study group. The control group consisted of age and gender matched healthy non-amblyopes. This study was approved by Başkent University Institutional Review Board and Ethics Committee (KA13/58). The research adhered to the tenets of the Declaration of Helsinki, and a detailed written informed consent was obtained before each individual's participation in the study.

The participants underwent full ophthalmologic and orthoptic examination. Sixty-seven patients with amblyopia were analysed in three different subgroups. Group 1 (n=33, 49.2%) included hypermetropic amblyopic children. Group 2 (n=23, 34.3%) included children with microesotropia and Group 3 (n=11, 16.4%) included myopic anisometropic children. Group 4 (n=31) consisted of the control group which had uncorrected visual acuity of 0.1 LogMAR (logarithm of minimum angle) in each eye and normal ocular findings. Anisometropia was defined as 1.5 D and more difference between amblyopic and non-amblyopic eyes and microtropia was accepted as 8 PD and less squint. Patients with more than 10 PD manifest eso/exotropia or higher refractive error than 5 D were excluded.

All OCT scans were performed at the same time of the day, in the morning, to avoid diurnal fluctuations. Choroidal thickness measurements were performed by the same experienced technician using a high speed and high-resolution Fourier domain-OCT device ($\lambda=840$ nm, 26,000 A-scans/s, and 5 μm axial resolution). Optovue RTVue software version 3.5 (Optovue Inc., Fremont, CA). The scan pattern was the retina cross line, consisting of 2 orthogonally oriented 6-mm lines which contains 1024 A-scans. By automatically inverting the image, the chorioretinal interface became adjacent to the zero delay. The retina crossline scan has 32 frames averaged, 16/direction, without tracking (8).

Choroidal thickness was measured perpendicularly from the outer edge of the retinal pigment epithelium to the choroid-sclera boundary at the fovea and at 5 more points which are located at respectively, 500 μm nasal to the fovea, 1000 μm nasal to the fovea, 500 μm temporal to the fovea, 1000 μm temporal to the fovea and 1500 μm temporal to the fovea

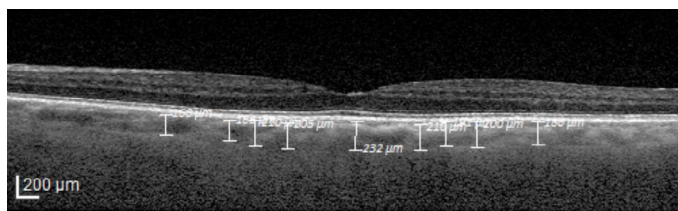


Figure 1. Choroidal thickness measurement in enhanced depth imaging optical coherence tomography.

(Fig. 1). Choroidal thickness measurements were made by two masked physicians (SAB and EE). The average of the two measurements was taken; the differences between readings of the masked physicians were found to be within 10% of the mean.

Statistical Analysis

The results of tests were expressed as the number of observations (n), mean \pm standard deviation, median and min-max values. The results of the homogeneity (Levene's Test) and normality tests (Shapiro Wilk) were used to decide which statistical methods to apply in the comparison of the study groups. Normally distributed and with homogeneous variances groups were compared two groups by Student's t-test. Paired t-test and compared three or more groups by Analysis of Variance. According to those tests results parametric test assumptions were not available for some variables, so the comparisons of two independent groups were performed by Mann-Whitney U test, comparisons of two dependent groups by Wilcoxon test and three independent groups were performed by Kruskal Wallis test. Multiple comparison tests, the adjusted Bonferroni test was used. All statistical analyses were performed with the Statistical Package for the Social Sciences (SPSS) software (SPSS Ver. 17.0; SPSS Inc., Chicago IL, USA). $P < 0.05$ was considered statistically significant.

Results

Of 67 patients 34 were female and 33 were male. The mean age was 8.6 ± 2.8 (5-12) years. The mean best corrected visual acuity of amblyopic eyes was 0.23 ± 0.09 (0.04-0.4) LogMAR in Group 1, 0.18 ± 0.33 (0.09-1.3) LogMAR in Group 2, and 0.21 ± 0.12 (0.1-0.8) LogMAR in Group 3. The mean best corrected visual acuity of non-amblyopic eyes was 0.02 ± 0.04 (0-0.15) LogMAR, 0.02 ± 0.06 (-0.07-0.09) LogMAR and 0.02 ± 0.05 (0-0.09) LogMAR respectively. Spheric equivalent difference in between eyes was 1.75 ± 1.81 (0.75-5.0) in Group 1, 0.99 ± 0.87 (0-3.25) in Group 2 and 1.62 ± 0.87 (1.50-3.62) in Group 3. Spheric equivalent difference in diopters was 1.75 ± 1.81 (0.75-5.0) in Group 1, 0.99 ± 0.87 (0-3.25) in Group 2 and 1.62 ± 0.87 (1.50-3.62) in Group 3 and $0.13 \pm (0-0.75)$ in Group 4. Anisometropia in diopters was 2.1 ± 0.76 (1.50-4.50) in Group 1, 1.3 ± 0.56 (0.50-3.25)

Table 1. Demographic features of the study groups

Groups	Hypermetropic Anisometropia Group 1	Micro-esotropica Group 2	Myopic Anisometropia Group 3	Control Group 4
BCVA (Log-MAR) of the amblyopic eye	0.23±0.09 (0.04–0.4)	0.18±0.33 (0.09–1.3)	0.21±0.12 (0.1–0.8)	0.0
BCVA (Log-MAR) of the non-amblyopic eye	0.02±0.04 (0–0.15)	0.02±0.06 (-0.07–0.09)	0.02±0.05 (0–0.09)	0.0
Difference of SE values	1.75±1.81 (0.75–5.0)	0.99±0.87 (0–3.25)	1.62±0.87 (1.50–3.62)	0.13± (0–0.75)
Anisometropia (in Diopters)	2.1±0.76 (1.50–4.50)	1.3±0.56 (0.50–3.25)	1.62±0.87 (1.50–3.62)	0.23± (0–0.75)
Interocular line difference	3.8± (2–8)	2.5± (2–6)	2.4± (2–5)	0

All values were shown as mean±standard deviation (range). BCVA: Best corrected visual acuity; SE: Spherical equivalent.

in Group 2. 1.62±0.87 (1.50–3.62) in Group 3 and 0.23±(0–0.75) in Group 4 (Table 1).

Choroidal thickness and macular thickness measurements were compared within each group between the amblyopic and non-amblyopic eye of the same patient. There were no statistically significant difference in any of the groups (Tables 2–4).

Choroidal thickness measurements of the amblyopic eyes in each group was compared to the control group separately. In group 1 and group 3 choroidal thickness measurements were thinner than the control group in all quadrants how-

ever only nasal quadrant measurements revealed statistical significance ($p=0.045$ for Group 1 and $p=0.043$ in Group 3). Choroidal thickness measurements of Group 2 did not show any statistical significant difference when compared to the control group (Table 5).

Macular thickness measurements of the amblyopic eyes were compared to the control group. Macular subfoveal thickness was statistically significantly thinner in group 1, 2 and 3 in comparison to the control group ($p=0.00$). Inferior quadrant central foveal thickness was found to be thinner in group 3 when compared to the control group ($p=0.041$) (Table 6).

Table 2. Comparison of choroidal and macular thickness between amblyopic and non-amblyopic eyes in Group 1

CT	Foveal	Nasal 500µ	Nasal 750µ	Nasal 1000µ	Nasal 1500µ	Temporal 500µ	Temporal 750µ	Temporal 1000µ	Temporal 1500µ
GROUP-I Amblyopic	336.33	320.15	311.78	310.78	299.81	326.75	331.81	330.57	327.30
GROUP-I Non-amblyopic	350.75	331.03	325.75	321.03	305.69	331.72	336.30	334.96	334.12
p-value	0.376	0.492	0.364	0.506	0.690	0.787	0.774	0.785	0.654
MT	Foveal	Parafoveal superior	Parafoveal inferior	Parafoveal nasal	Parafoveal temporal	Superior	Inferior	Nasal	Temporal
GROUP-I Amblyopic	252.46	314.37	319.00	320.50	306.59	289.93	281.96	304.28	272.21
GROUP-I Non-amblyopic	251.21	312.87	313.62	317.84	304.50	286.46	276.12	298.53	266.50
p-value	0.713	0.584	0.068	0.104	0.068	0.383	0.155	0.153	0.234

Choroidal and macular thickness measurements did not show any statistically significant difference in between amblyopic and non-amblyopic eyes in hypermetropic anisometropic group ($p>0.05$ for all). CT: Choroidal thickness; MT: Macular thickness.

Table 3. Comparison of choroidal and macular thickness between amblyopic and non-amblyopic eyes in Group 2

CT	Foveal	Nasal 500µ	Nasal 750µ	Nasal 1000µ	Nasal 1500µ	Temporal 500µ	Temporal 750µ	Temporal 1000µ	Temporal 1500µ
GROUP-2 Amblyopic	380.00	352.13	353.21	348.91	342.04	364.34	358.95	357.56	353.08
GROUP-2 Non-amblyopic	367.78	351.47	348.13	345.47	331.00	343.30	350.56	351.13	349.69
p-value	0.364	0.962	0.740	0.816	0.455	0.189	0.603	0.764	0.886

MT	Foveal	Parafoveal superior	Parafoveal inferior	Parafoveal nasal	Parafoveal temporal	Superior	Inferior	Nasal	Temporal
GROUP-2 Amblyopic	249.00	316.13	311.66	317.45	303.68	284.59	273.45	286.54	269.09
GROUP-2 Non-amblyopic	241.04	311.86	310.43	314.82	303.17	285.21	274.04	297.00	269.56
p-value	0.266	0.299	0.722	0.451	0.751	0.977	0.988	0.480	0.872

Choroidal and macular thickness measurements did not show any statistically significant difference in between amblyopic and non-amblyopic eyes in microesotropic group (p>0.05. for all). CT: Choroidal thickness; MT: Macular thickness.

Table 4. Comparison of choroidal and macular thickness between amblyopic and non-amblyopic eyes in Group 3

CT	Foveal	Nasal 500µ	Nasal 750µ	Nasal 1000µ	Nasal 1500µ	Temporal 500µ	Temporal 750µ	Temporal 1000µ	Temporal 1500µ
GROUP-3 Amblyopic	336.64	327.36	315.82	309.64	293.09	332.27	329.09	320.55	320.00
GROUP-3 Non-amblyopic	333.91	325.91	314.45	303.18	291.45	323.36	322.55	326.00	309.09
p-value	0.917	0.948	0.934	0.737	0.93	0.675	0.78	0.767	0.517

MT	Foveal	Parafoveal superior	Parafoveal inferior	Parafoveal nasal	Parafoveal temporal	Superior	Inferior	Nasal	Temporal
GROUP-3 Amblyopic	247.90	316.90	315.10	319.00	305.00	276.10	264.20	301.00	257.90
GROUP-3 Non-amblyopic	243.90	320.20	310.50	316.60	290.60	279.90	266.30	296.90	262.40
p-value	0.276	0.613	0.22	0.347	0.204	0.229	0.376	0.23	0.507

Choroidal and macular thickness measurements did not show any statistically significant difference in between amblyopic and non-amblyopic eyes in myopic anisometropic group (p>0.05. for all). CT: Choroidal thickness; MT: Macular thickness.

Discussion

In this study our aim is to compare the choroidal and macular thickness measurements in am-blyopic eyes with the fellow eye and the healthy control group. Many different studies by dif-ferent authors have been published on this topic until today and as a result there are controver-sies in the litera-

ture regarding the choroidal thickness and macular thickness changes in ambly-opic eyes.

Very first studies that analysed macular thickness in amblyopia are from early 2000 s and many different results have been achieved (9). In a meta-analyses including 28 studies with 408 pa-tients. many controversial results have been found however the authors concluded that amblyopia is

Table 5. Comparison of choroidal thickness in amblyopic eyes

CT	Foveal	Nasal 500µ	Nasal 750µ	Nasal 1000µ	Nasal 1500µ	Temporal 500µ	Temporal 750µ	Temporal 1000µ	Temporal 1500µ
GROUP-1									
Amblyopic	336.33	320.15	311.78	310.78	299.81*	326.75	331.81	330.57	327.30
GROUP-2									
Amblyopic	380.00	352.13	353.21	348.91	342.04	364.34	358.95	357.56	353.08
GROUP-3									
Amblyopic	336.64	327.36	315.82	309.64	293.09*	332.27	329.09	320.55	320.00
CONTROL	377.45	348.54	339.75	335.74	324.88	350.22	355.48	351.69	347.33
p-value	>0.05	>0.05	>0.05	>0.05	*0.045. 0.043	>0.05	>0.05	>0.05	>0.05

*CC measurements in the amblyopic eye in hyperopic and myopic anisometropia were thinner in all quadrants than the control group, but only nasal 1500 µ was found to be statistically thinner than the control group (p=0.045, p=0.043); microtropic group measurements were not different with the control group (p>0.05) CT: Choroidal thickness.

Table 6. Comparison of macular thickness in amblyopic eyes

MT	Foveal	Parafoveal superior	Parafoveal inferior	Parafoveal nasal	Parafoveal temporal	Superior	Inferior	Nasal	Temporal
GROUP-1									
Amblyopic	252.46*	314.37	319.00	320.50	306.59	289.93	281.96	304.28	272.21
GROUP-2									
Amblyopic	249.00*	316.13	311.66	317.45	303.68	284.59	273.45	286.54	269.09
GROUP-3									
Amblyopic	247.90*	316.90	315.10	319.00	305.00	276.10	264.20**	301.00	257.90
CONTROL	308.08	314.48	315.54	318.20	307.67	284.24	274.35	298.54	267.79
p-value	*0.00	>0.05	>0.05	>0.05	>0.05	>0.05	**0.041	>0.05	>0.05

*Macular subfoveal thickness was found to be thinner in amblyopic eyes in all three groups than in the control group (p=0.00). **Lower quadrant central foveal thickness was found to be thinner in amblyopic eyes in myopic anisometropia (p=0.041). MT: Macular thickness..

associated with foveal and macular thickness increase (10). Similar to the results of Li's meta-analyses from 2015, more recent studies of Rajawi et al. (11), Kasem et al. (12), Kuhl-Hattenbach et al. (13) revealed increased central macular thickness in amblyopic eyes. Taskiran Comez et al. (14) and three more studies did not show any statistically significant difference in amblyopic and fellow eyes (15-17). In our study, no statistically significant difference in macular thickness was found between the amblyopic and fellow eyes which is compatible with the recent studies. We found that macular subfoveal thickness was statistically significantly thinner in all groups when compared to the control group. This finding was thought to be due to the morphological effect of amblyopia.

Xu et al. (18) found that there were no differences in the thickness of the foveal and the retinal nerve fiber layers be-

tween eyes with esotropic amblyopic and the normal fellow eyes. Pang et al. (19) analyzed 31 children with unilateral high myopia. Their results revealed that amblyopic children with unilateral high myopia have a thicker fovea and thinner inner and outer macula in the amblyopic eye. However, these findings were thought to be due to the morphological effect of amblyopia.

It is well known that choroid has a role in emmetropization however imaging of the choroid and accurate measurements could only be possible within the last decade with the progress in posterior segment imaging. Since resolution of the spectral domain OCT below the level of retinal pigment epithelium is very low, EDI-OCT offers the required technology for choroidal imaging.

Vincent et al. (20) analysed the eyes of 22 non-amblyopic myopic anisometropes and found that subfoveal choroid was

thinner in the amblyopic eyes and this finding was correlated with the axial length. Araki et al. (21) examined 31 patients with hyperopic anisometropic amblyopia. 15 patients with strabismic amblyopia without anisometropia and 24 age-matched controls. Their results showed that the anisometropic amblyopia group had thicker choroids than that of fellow eyes and control group. It is hypothesised that the difference in choroidal thickness in myopic amblyopes and hyperopic amblyopes may be due to the axial length alterations. Despite these controversial results a meta-analysis of 11 clinical trials with 449 patients showed that the choroid was found to be thicker in the amblyopic eyes than that in the fellow and control eyes (22). Similarly in a recent study of Zha et al. (23) with 31 children, choroid was found significantly thicker in subfoveal area. 1 mm nasal and 1 mm superior to the fovea in amblyopic eyes than control eyes. In the study of Hansen et al. including 20 children with amblyopia, subfoveal choroidal thicknesses was found to be higher in amblyopic eyes when compared to fellow eyes and healthy controls (15). In a study of Niyaz et al. (24), 90 patients with different categories of amblyopia such as anisometropic, strabismic and mixed were analysed and increased choroidal thickness was found in anisometropic group compared to fellow and control eyes.

Karaca et al. (25) showed that macular choroidal thickness was thicker than healthy controls both in amblyopic and non-amblyopic eyes. They hypothesized that this finding can indicate bilateral emmetropization delay implying that amblyopia influences both eyes' visual feedback. Since the subfoveal choroidal thickness was found to be higher in amblyopic eyes and fellow eyes in a study of Xu et al. (26), their results suggested thicker choroid might be used as a diagnostic parameter for amblyopia.

However in our study there was no statistically significant difference in choroidal thickness measurements between the amblyopic and non-amblyopic eyes. In our study choroidal thickness measurements of the amblyopic eyes in each group was compared to the healthy control group separately as well. In hyperopic anisometropic group and myopic anisometropic group choroidal thickness measurements were thinner than the control group in all quadrants however only nasal quadrant measurements revealed statistical significance.

Nishi et al. (27) analysed the choroidal structure in amblyopic children by using binarization of optical coherence tomography images. The total choroidal area and luminal/stromal ratio in the amblyopic eyes was significantly larger than that of the fellow eyes. They speculated that the lumen/stroma ratio increase may be due to the immature development of these eyes. Similarly Baek et al. (28) analysed choroidal vascularity in eyes of 32 hyperopic amblyopic

children and 38 healthy controls. They observed a positive correlation between choroidal thickness and choroidal vascularity in healthy eyes. However in amblyopic eyes a negative correlation was observed which was thought to show decreased blood supply of the choroid and outer retina in amblyopic eyes. While several factors may affect subfoveal choroidal thickness, choroidal vascularity index (CVI) remained unaltered, implying that CVI is a more reliable indicator of choroidal disorders (29).

In our study comparison of choroidal thickness in the amblyopic and non-amblyopic fellow eyes did not show any statistical significance. This finding suggested that amblyopic eyes have a metabolic activity which is as high as the fellow eye of the same patient. Mohan et al. (30) studied retinal vascular oxygen saturation in amblyopic eyes and compared them to unaffected fellow eyes and healthy control group. Controversial to our results, they found that amblyopic eyes showed higher mean oxygen saturations than the fellow eyes which was thought to be neuronal activity alterations. While interpreting the results of all these various studies, it is important to remember that subfoveal choroidal thickness is influenced by different factors like age, ethnicity, intraocular pressure and axial length (31).

Choroidal thickness may change with treatment and it had been shown by many different authors. Hashimoto et al. (32) showed that both choroidal blood flow increased and choroidal thickness decreased in the amblyopic eyes with treatment in two anisohypermetropic amblyopic cases. In a series of Nishi et al. (33) with 24 anisohypermetropic amblyopic children showed optical correction resulted in choroidal thinning in the amblyopic eyes and fellow eyes. Araki et al. (34) investigated the effect of amblyopia treatment on macular choroidal thickness in 13 patients. Controversial to Nishi and Hashimoto, their results revealed that despite the increase in visual acuity, treatment did not cause any decrease in the choroidal thickening.

In conclusion although our study has a limitation of relatively small sample size, we believe that our results have scientific value. Prospective studies with larger patient numbers can enlighten the choroidal and macular structural changes in amblyopia.

Disclosures

Ethics Committee Approval: This study was approved by Başkent University Institutional Review Board and Ethics Committee (KA13/58).

Peer-review: Externally peer-reviewed.

Conflict of Interest: None declared.

Authorship Contributions: Involved in design and conduct of the study (SAB, SO); preparation and review of the study (RAK, SAB); data collection (ZEE, EYP); and statistical analysis (MAT).

References

1. Fu Z, Hong H, Su Z, Lou B, Pan CW, Liu H. Global prevalence of amblyopia and disease burden projections through 2040: a systematic review and meta-analysis. *Br J Ophthalmol* 2020;104:1164–70. [\[CrossRef\]](#)
2. Vagge A, Nelson LB. Amblyopia update: new treatments. *Curr Opin Ophthalmol* 2016;27:380–6. [\[CrossRef\]](#)
3. Birch EE. Amblyopia and binocular vision. *Prog Retin Eye Res* 2013;33:67–84. [\[CrossRef\]](#)
4. Spaide R, Koizumi H, Pozzoni M. Enhanced depth imaging spectral-domain optical coherence tomography. *Am J Ophthalmol* 2008;146:496–500. [\[CrossRef\]](#)
5. Park KA, Oh SY. Choroidal thickness in healthy children. *Retina* 2013;33:1971–6. [\[CrossRef\]](#)
6. Nishida Y, Fujiwara T, Imamura Y, Lima LH, Kurosaka D, Spaide RF. Choroidal thickness and visual acuity in highly myopic eyes. *Retina* 2012;32:1229–36.
7. Read SA, Collins MJ, Vincent SJ, Alonso-Caneiro D. Choroidal thickness in childhood. *Invest Ophthalmol Vis Sci* 2013;54:3586–93. [\[CrossRef\]](#)
8. Branchini L, Regatieri CV, Flores-Moreno I, Baumann B, Fujimoto JG, Duker JS. Reproducibility of choroidal thickness measurements across three spectral domain optical coherence tomography systems. *Ophthalmology* 2012;119:119–23.
9. Yen MY, Cheng CY, Wang AG. Retinal nerve fiber layer thickness in unilateral amblyopia. *Invest Ophthalmol Vis Sci* 2004;45:2224–30. [\[CrossRef\]](#)
10. Li J, Ji P, Yu M. Meta-analysis of retinal changes in unilateral amblyopia using optical coherence tomography. *Eur J Ophthalmol* 2015;25:400–9. [\[CrossRef\]](#)
11. Rajavi Z, Sabbaghi H, Behradfar N, Yaseri M, Aghazadeh Amiri M, Faghihi M. Macular thickness in moderate to severe amblyopia. *Korean J Ophthalmol* 2018;32:312–8. [\[CrossRef\]](#)
12. Kasem MA, Badawi AE. Changes in macular parameters in different types of amblyopia: optical coherence tomography study. *Clin Ophthalmol* 2017;11:1407–16.
13. Kuhli-Hattenbach C, Koss MJ, Kohnen T, Fronius M. A morphological study of amblyopic eyes in children failing to achieve normal visual acuity after electronically monitored long-term occlusion treatment. *Graefes Arch Clin Exp Ophthalmol* 2015;53:2021–8.
14. Taskiran Comez A, Sanal Ulu E, Ekim Y. Retina and optic disc characteristics in amblyopic and non-amblyopic eyes of patients with myopic or hyperopic anisometropia. *Turk J Ophthalmol* 2017;47:28–33. [\[CrossRef\]](#)
15. Hansen MH, Munch IC, Li XQ, Skovgaard AM, Olsen EM, Larsen M, et al. Visual acuity and amblyopia prevalence in 11- to 12-year-old Danish children from the Copenhagen Child Cohort 2000. *Acta Ophthalmol* 2019;97:29–35. [\[CrossRef\]](#)
16. Kusbeci T, Karti O, Karahan E, Oguztoreli M. The evaluation of anatomic and functional changes in unilateral moderate amblyopic eyes using optical coherence tomography and pupil cycle time. *Curr Eye Res* 2017;42:1725–32.
17. Altintas O, Gumustas S, Cinik R, Anik Y, Ozkan B, Karabas L. Correlation of the measurements of optical coherence tomography and diffuse tensor imaging of optic pathways in amblyopia. *Int Ophthalmol* 2017;37:85–93. [\[CrossRef\]](#)
18. Xu J, Lu F, Liu W, Zhang F, Chen W, Chen J. Retinal nerve fiber layer thickness and macular thickness in patients with esotropic amblyopia. *Clin Exp Optom* 2013;96:267–71.
19. Pang Y, Goodfellow GW, Allison C, Block S, Frantz KA. A prospective study of macular thickness in amblyopic children with unilateral high myopia. *Invest Ophthalmol Vis Sci* 2011;52:2444–9. [\[CrossRef\]](#)
20. Vincent SJ, Collins MJ, Read SA, Carney LG. Retinal and choroidal thickness in myopic anisometropia. *Invest Ophthalmol Vis Sci* 2013;54:2445–56. [\[CrossRef\]](#)
21. Araki S, Miki A, Goto K, Yamashita T, Takizawa G, Haruishi K, et al. Macular retinal and choroidal thickness in unilateral amblyopia using swept-source optical coherence tomography. *BMC Ophthalmol* 2017;17:167.
22. Liu Y, Dong Y, Zhao K. A Meta-Analysis of Choroidal Thickness Changes in Unilateral Amblyopia. *J Ophthalmol* 2017;2017:2915261.
23. Zha Y, Zhuang J, Feng W, Zheng H, Cai J. Evaluation of choroidal thickness in amblyopia using optical coherence tomography. *Eur J Ophthalmol* 2020;30:629–34. [\[CrossRef\]](#)
24. Niyaz L, Yucel OE, Ariturk N, Terzi O. Choroidal thickness in strabismus and amblyopia cases. *Strabismus* 2017;25:56–9.
25. Karaca EE, Çubuk MÖ, Akçam HT, Uzun F, Yüksel E. Choroidal Thickness in Turkish Children with Anisometric Amblyopia. *Semin Ophthalmol* 2017;32:291–6. [\[CrossRef\]](#)
26. Xu J, Zheng J, Yu S, Sun Z, Zheng W, Qu P, et al. Macular choroidal thickness in unilateral amblyopic children. *Invest Ophthalmol Vis Sci* 2014;55:7361–8. [\[CrossRef\]](#)
27. Nishi T, Ueda T, Mizusawa Y, Shinomiya K, Semba K, Mitamura Y, et al. Choroidal structure in children with anisohypermetropic amblyopia determined by binarization of optical coherence tomographic images. *PLoS One* 2016;11:e0164672.
28. Baek J, Lee A, Chu M, Kang NY. Analysis of choroidal vascularity in children with unilateral hyperopic amblyopia. *Sci Rep* 2019;9:12143. [\[CrossRef\]](#)
29. Agrawal R, Gupta P, Tan KA, Cheung CM, Wong TY, Cheng CY. Choroidal vascularity index as a measure of vascular status of the choroid: Measurements in healthy eyes from a population-based study. *Sci Rep* 2016;6:21090.
30. Mohan A, Kemmanu V, Baliga S, Patil M, Madhavrao B, Webers CAB, et al. Retinal oximetry in normal and amblyopic children: a pilot study. *Acta Ophthalmol* 2019;97:684–7. [\[CrossRef\]](#)
31. Prousalis E, Dastiridou A, Ziakas N, Androudi S, Mataftsi A. Choroidal thickness and ocular growth in childhood. *Surv Oph-*

- thalmol 2021;66:261–75.
32. Hashimoto R. Kawamura J. Hirota A. Oyamada M. Sakai A. Maeno T. Changes in cho-roidal blood flow and choroidal thick-ness after treatment in two cases of pediatric anisohy-permetropic amblyopia. *Am J Ophthalmol Case Rep* 2017;8:39–43.
33. Nishi T. Ueda T. Mizusawa Y. Semba K. Shinomiya K. Mitamura Y. et al. Effect of optical correction on subfoveal choroidal thickness in children with anisohypermetropic amblyopia. *PLoS One* 2017;12:e0189735. [[CrossRef](#)]
34. Araki S. Miki A. Goto K. Yamashita T. Takizawa G. Haruishi K. et al. Effect of amblyopia treatment on choroidal thick-ness in hypermetropic anisometropic amblyopia using swept-source optical coherence tomography. *BMC Ophthalmol* 2018;18:227.