



Long-term Results of Ranibizumab, Dexamethasone Implant, and Triamcinolone in Macular Edema due to Branch Retinal Vein Occlusion

Nevin Hande Dikel,¹ Erhan Yumusak,² Nesrin Buyuktortop Gokcinar³

¹Department of Ophthalmology, Karaman State Hospital, Karaman, Turkey

²Department of Ophthalmology, University of Health Sciences, Gulhane Faculty of Medicine, Ankara, Turkey

³Department of Ophthalmology, Kirikkale University Faculty of Medicine, Kirikkale, Turkey

Abstract

Objectives: The present study aims to compare the long-term efficacy and safety results of intravitreal ranibizumab (RAN), dexamethasone intravitreal implant (DEX) and intravitreal triamcinolone acetonide (IVTA) injections in macular edema due to branch retinal vein occlusion (BRVO).

Methods: In this retrospective study, one eye each of 43 patients who were treated with intravitreal injections for macular edema secondary to BRVO was recruited into one of the study groups: RAN group (n=17), DEX group (n=16) and IVTA group (n=10). All patients were followed-up for 12 months. Best-corrected visual acuity (BCVA), central macular thickness (CMT), subfoveal choroidal thickness (SFCT) and intraocular pressure (IOP) at month 1, 3, 6, and 12 were compared with baseline.

Results: The BCVA increased significantly in the RAN and DEX groups at all visits (all $p < 0.05$). BCVA increase in the IVTA group was significant only at month 1 and 6. CMT decreased significantly in all groups at the end of one year of follow-up ($p = 0.007$; $p = 0.001$; $p = 0.044$, respectively). SFCT significantly decreased in all groups at month 1 (all $p < 0.05$). IOP significantly increased in none, 18.8%, 30% of the patients in the RAN, DEX and IVTA groups, respectively. Cataract surgery was performed in none of the patients, 6.3%, and 30% of the patients in the RAN, DEX, and IVTA groups, respectively.

Conclusion: BCVA increase was more prominent in both of the RAN and DEX groups than in the IVTA group. DEX may decrease the injection burden; however, ranibizumab may be a safer choice.

Keywords: Branch retinal vein occlusion, dexamethasone intravitreal implant, macular edema, ranibizumab, triamcinolone acetonide.

Introduction

Retinal vein occlusion (RVO) is the second most common cause of vision loss from retinal vascular disease, following diabetic retinopathy (1). Branch retinal vein occlusion (BRVO) is often due to a compression of the adjacent vein by atherosclerotic retinal arteries at the site of arteriovenous crossing, leading to turbulent flow and venous stasis.

Thrombosis of a retinal vein causes an increase in retinal capillary pressure, resulting in increased capillary permeability and leakage of fluid and blood into the retina. Accompanying retinal ischemia may worsen this process by the production of vascular endothelial growth factor (VEGF), which then increases retinal capillary permeability and leakage into the extracellular space resulting in macular edema (ME) (2). ME is the most common cause of visual loss in RVO, followed by

Address for correspondence: Nesrin Buyuktortop Gokcinar, MD. Kirikkale Universitesi Tıp Fakultesi,
Goz Hastaliklari Anabilim Dalı, Kirikkale, Turkey

Phone: +90 533 230 74 12 **E-mail:** tortopn@kku.edu.tr

Submitted Date: July 03, 2019 **Accepted Date:** November 26, 2019 **Available Online Date:** December 27, 2019

©Copyright 2019 by Beyoglu Eye Training and Research Hospital - Available online at www.beyoglueye.com

OPEN ACCESS This work is licensed under a Creative Commons Attribution-NonCommercial 4.0 International License.



macular ischemia, neovascularization, neovascular glaucoma, vitreous hemorrhage, and retinal detachment (2). The main goal of treatment for ME is to reduce the photoreceptor damage by decreasing the duration of edema. Currently, laser photocoagulation, intravitreal corticosteroids, and anti-VEGF agents are being used for the treatment of ME in RVO. Macular grid photocoagulation may be considered in patients with BRVO who are adverse to intravitreal therapy. However, visual acuity (VA) results in lag behind the results for anti-VEGF therapies (3).

One of the first therapeutic agents used for the treatment of ME is intravitreal triamcinolone acetonide (IVTA). In the SCORE study, the efficacy and safety of different doses IVTA were compared with standard care, including grid photocoagulation. Successful anatomic and functional results were obtained with IVTA. However, adverse effects, such as cataract and glaucoma, are major limitations (4).

GENEVA studies evaluated the safety and efficacy of an intravitreal implant of dexamethasone (DEX) (Ozurdex®; Allergan plc, Dublin, Ireland) in patients with ME secondary to RVO. The outcomes of DEX were better than in controls. Based on these studies, Ozurdex received United States Food and Drug Administration (FDA) and European Union (EU) approval for 0.7-mg implants for the treatment of adult patients with ME following either BRVO or CRVO (5, 6).

Nowadays, anti-VEGF injections are mostly preferred as the first-line therapy for ME in BRVO (2). The BRAVO and CRUISE studies demonstrated that ranibizumab (RAN) (Lucentis®; Novartis, Pharma AG, Switzerland) was associated with a significantly greater mean reduction in central macular thickness (CMT), and improvement in vision (7-9). RAN received FDA approval upon these studies.

There are studies about the efficacy and safety of the available therapeutic agents. However, current evidence on drug comparisons is limited. To our knowledge, there is no study comparing the long term results of RAN, DEX, and IVTA for the treatment of ME in BRVO. Short-term safety and efficacy comparisons were previously reported by our group (10). In this study, we present the long-term results of the above-mentioned three agents for the treatment of macular edema due to RVO in terms of efficacy and safety in real-life practice.

Methods

This was a comparative, retrospective study. The protocol followed the tenets of the Declaration of Helsinki and informed consent was obtained from all patients. Ethics approval was obtained from Kırıkkale University Clinical Research Ethics Committee (#09/12-04.04.2017). The charts of patients with macular edema secondary to RVO who received an intravitreal injection of 0.5 mg/0.05 ml RAN, 0.7 mg DEX, or

4 mg IVTA between January 2014 and January 2017 were reviewed. The exclusion criteria included glaucoma, ocular hypertension, epiretinal membrane, vitreomacular traction, central macular thickness <250 μ m, history of macular laser photocoagulation, an ischemic area of >10-disc diameters, and previous intravitreal injection or recent ocular surgery (within six months). There were no strict criteria for a loading dose. Criteria for repeated injection were the progression of CMT \geq 300 μ m or persistent or increased intraretinal or subretinal fluid on OCT with a decrease in VA by five letters. The best-corrected visual acuity (BCVA), intraocular pressure (IOP), CMT and subfoveal choroidal thickness (SFCT) was recorded at each visit during follow-up. Fundus fluorescein angiography (Canon CF-I Digital Mydriatic Retinal Camera; Canon Inc., Tokyo, Japan) and spectral-domain optical coherence tomography (OCT) (Nidek RS-3000 OCT Advance; Nidek Co. Ltd., Gamagori, Japan) examinations were performed in all patients. Informed consent was obtained from all patients before the injections. All intravitreal injections were performed in an operating room under sterile conditions. Treated eyes were divided into three groups according to the treatment agent as the intravitreal RAN group, the DEX implant group, and the IVTA group.

The main outcomes measured were changes in BCVA, IOP, CMT, SFCT, and ocular adverse effects. Data related to baseline and post-injection visits at month 1, 3, 6, and 12 were compared.

Statistical Analysis

The research data were evaluated using the Statistical Package for the Social Sciences (SPSS) for Windows 22.0 (IBM SPSS, Armonk, NY: IBM Inc.). Chi-square test was used to evaluate categorical variables. The conformity of the variables to normal distribution was examined using histograms, probability plots, and the Shapiro-Wilk test. The Kruskal-Wallis test was used for statistical analysis between three independent groups, and the Wilcoxon signed-rank test was used for statistical analysis between two dependent groups. When a significant difference was found between the three independent groups, the Mann-Whitney U test and posthoc Bonferroni correction was used to find the source of the difference. A p-value of <0.05 was accepted as statistically significant.

Results

In total, 43 eyes of 43 subjects were included in the analysis. All patients were followed up for 12 months. Demographic findings and the mean number of injections for each group are given in Table 1. Of the 43 eyes, 17 (39.5%) received RAN, 16 (37.2%) received DEX, and the remaining 10 (23.3%) received IVTA injections. The mean age of the patients and sex distribution between the groups were similar.

Table 1. The baseline patient characteristics, number of the injections and ocular adverse effects in the study groups

	Total (n=43)	RAN (n=17)	DEX (n=16)	IVTA (n=10)	p
Age (years)					
Mean±SD (min-max)	63.42±12.90 (23-83)	67.65±10.00 (43-83)	57.25±17.06 (23-82)	66.10±2.13 (63-70)	0.082**
Sex, n (%)					
Female	28 (65.1)	11 (64.7)	11 (68.8)	6 (60.0)	0.901*
Male	15 (34.9)	6 (35.3)	5 (31.3)	4 (40.0)	
Systemic disease, n (%)	28 (65.1)	11 (64.7)	11 (68.8)	6 (60.0)	0.901*
DM	4 (9.3)	1 (5.9)	3 (18.8)	0	0.228*
HT	13 (30.2)	5 (29.4)	5 (31.3)	3 (30.0)	0.993*
DM+HT	11 (25.6)	5 (29.4)	3 (18.8)	3 (30.0)	0.731*
Laser, n (%)	13 (30.2)	3 (17.6)	6 (37.5)	4 (40.0)	0.345*
Number of injections, mean±SD (min-max)	2.30±0.86 (1-4)	2.35±1.00 (1-4)	1.88±0.62 ^z (1-3)	2.90±0.57 ^z (2-4)	0.008**
n (%) of patients receiving					
1 injection	8 (18.6)	4 (23.5)	4 (25)	0	
2 injections	17 (39.5)	5 (29.4)	10 (62.5)	2 (20)	
3 injections	15 (34.8)	6 (35.2)	2 (12.5)	7 (70)	
4 injections	2 (4.6)	1 (5.8)	0	1 (10)	
5 injections	1 (2.3)	1 (5.8)	0	0	
Lens status, n (%)					
Phakic with clear lens	11 (25.5)	5 (29.4)	6 (37.5)	0	
Phakic with lens opacity	20 (46.5)	8 (47.1)	6 (37.5)	6 (60)	
Pseudophakic	12 (28)	4 (23.5)	4 (25)	4 (40)	

SD: Standard deviation; n: Number; %: Percentage of the column; IVTA: Intravitreal Triamcinolone acetonide; RAN: Ranibizumab; DEX: Dexamethasone intravitreal implant; *chi-square test; **Kruskal-Wallis test; ^z: In post-hoc pairwise comparisons there was a significant difference between the DEX and IVTA groups (p<0.017). Bold letters indicate p<0.05.

The mean number of injections was significantly higher in the IVTA group than in the DEX group (2.9 vs. 1.8). Although the mean number of injections was higher in the RAN group than in the DEX group (2.3 vs. 1.8), this difference was not significant. During the one-year follow-up period, scatter laser photocoagulation was performed for ischemic areas in 17.6%, 37.5%, and 40% of the patients in the RAN, DEX, and IVTA groups, respectively (p=0.345).

Best-corrected Visual Acuity

The changes in BCVA values during follow-up are given in Figure 1 and Table 2. The baseline BCVA values were similar between the groups (p=0.996). There was a statistically significant increase in BCVA from baseline at all visits in both the RAN and DEX groups (all p<0.05). The BCVA increase from baseline in the IVTA group was significant at month 1 and 6 (p=0.049; p=0.03, respectively), but not at month 3 and 12 (p=0.602; p=0.261, respectively).

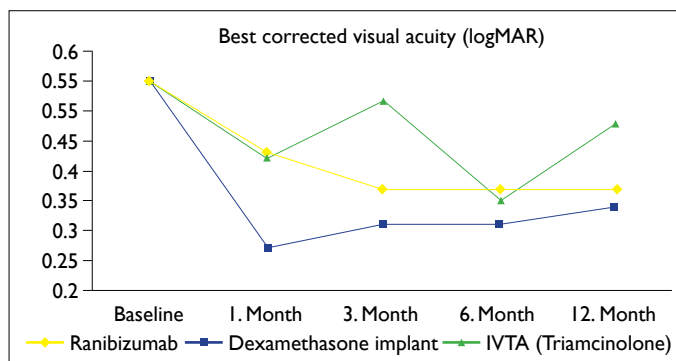


Figure 1. The best-corrected visual acuity during follow-up in the study groups.

Central Macular Thickness

The changes in CMT values during follow-up are given in Figure 2 and Table 2. There was a statistically significant decrease in the mean CMT from baseline at all visits after the

Table 2. The BCVA, IOP, CMT, and SFCT values at the baseline, month 1, month 3, month 6 and month 12

	n	Baseline mean±SD	Month 1 mean±SD	p*	Month 3 mean±SD	p*	Month 6 mean±SD	p*	Month 12 mean±SD	p*
BCVA										
RAN	17	0.55±0.60	0.43±0.48	0.038	0.37±0.56	0.007	0.37±0.53	0.018	0.37±0.52	0.026
DEX	16	0.55±0.67	0.27±0.52	0.001	0.31±0.50	0.004	0.31±0.48	0.020	0.34±0.49	0.046
IVTA	10	0.55±0.63	0.42±0.67	0.049	0.52±0.88	0.602	0.35±0.53	0.030	0.48±0.56	0.261
IOP										
RAN	17	14.77±3.56	14.06±2.84	0.344	14.29±2.26	0.482	15.12±2.57	0.723	15.24±2.02	0.565
DEX	16	15.56±3.69	17.13±3.86	0.038	18.19±5.47	0.032	17.44±4.18	0.031	16.06±2.96	0.531
IVTA	10	17.20±2.04	21.30±9.27	0.031	19.50±4.88	0.042	17.00±3.46	0.752	14.10±3.64	0.011
CMT										
RAN	17	385.3±123.3	292.1±107.7	0.025	268.4±73.5	0.001	346.4±142.7	0.185	296.2±96.2	0.007
DEX	16	495.6±100.4	292.2±54.9	<0.001	371.8±141.0	0.008	364.9±134.5	0.008	344.7±89.4	0.001
IVTA	10	515.5±133.2	400.6±119.5	0.007	367.5±105.3	0.022	379.5±71.9	0.047	393.2±95.9	0.044
SFCT										
RAN	17	224.9±67.6	184.3±43.9	0.020	195.2±38.8	0.084	207.0±36.0	0.485	205.3±33.5	0.315
DEX	16	197.2±28.6	171.6±38.4	0.046	204.4±41.6	0.756	191.8±36.0	0.352	196.6±38.4	0.170
IVTA	10	234.3±15.1	210.5±34.6	0.049	234.2±23.2	0.893	224.4±34.3	0.213	222.6±34.6	0.102

BCVA: Best-corrected visual acuity in logMAR values; IOP: Intraocular pressure; CMT: Central macular thickness; SFCT: Subfoveal choroidal thickness; n: number of patients; SD: Standard deviation; IVTA: Intravitreal triamcinolone acetonide; RAN: Ranibizumab; DEX: Dexamethasone intravitreal implant; *p-values come from the Wilcoxon signed-rank test when compared with the baseline. Bold letters indicate p<0.05.

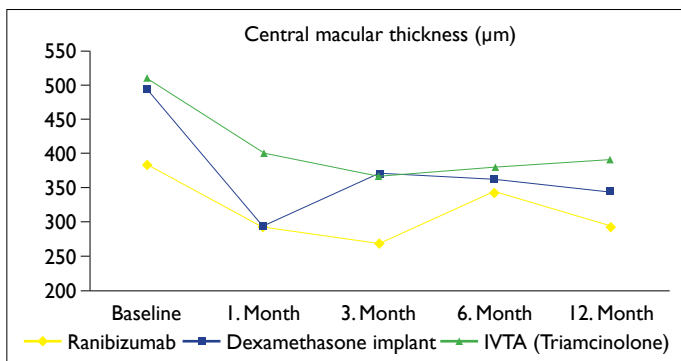


Figure 2. The central macular thickness during follow-up in the study groups.

injection in both the IVTA and DEX groups (all p<0.05). In the RAN group, there was a significant decrease in the mean CMT from baseline at all visits, except month 6 (p=0.185).

Subfoveal Choroidal Thickness

The changes in SFCT values during follow-up are given in Figure 3 and Table 2. There was a statistically significant decrease in SFCT from baseline at month 1 in all study groups (all p<0.05). However, there was no significant difference between baseline SFCT and SFCT at month 3, 6, and 12, in any groups (all p>0.05).

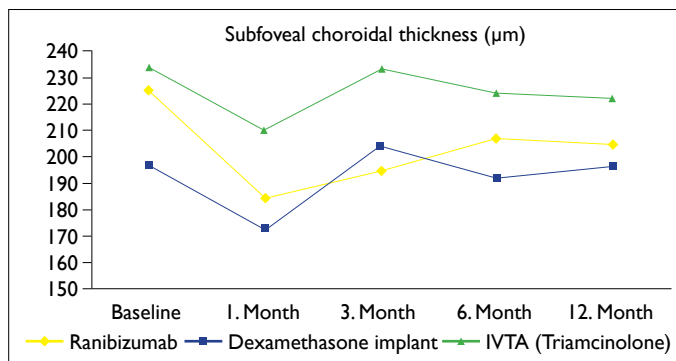


Figure 3. The subfoveal choroidal thickness during follow-up in the study groups.

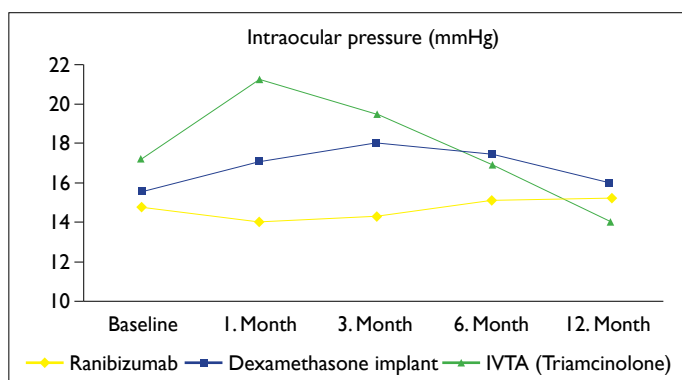
Safety Outcomes

The changes in IOP values among the groups during follow-up are given in Figure 4. There was no statistically significant difference between baseline and follow-up IOP values in the RAN group. In the DEX group, a statistically significant increase was found from baseline at month 1, 3, and 6 after the injection (all p<0.05). Topical antiglaucomatous treatment was started in three patients in the DEX group; therefore, IOP values at month 12 were similar to baseline (p=0.531). Patients in the IVTA group had significantly higher IOP values at month 1 and month 3 compared with baseline (p=0.031);

Table 3. The ocular adverse effects in the study groups during follow-up

Ocular adverse effects, n (%)	Total (n=43)	RAN (n=17)	DEX (n=16)	IVTA (n=10)	p
IOP rise	6 (14.0)	0	3 (18.8)	3 (30.0)	0.074*
Cataract surgery	4 (9.3)	0	1 (6.3)	3 (30.0)	0.030*

n: Number; %: Percentage of the column; IVTA: Intravitreal Triamcinolone acetonide; RAN: Ranibizumab; DEX: Dexamethasone intravitreal implant; *chi-square test. Bold letters indicate $p < 0.05$.

**Figure 4.** The intraocular pressure during follow-up in the study groups.

$p=0.042$, respectively), whereas the IOP values at month 12 were significantly lower compared with pre-injection values, probably due to the initiation of antiglaucomatous drops in three patients ($p=0.011$) (Table 2). No patients in the RAN group had a significant IOP rise. However, 18.8% of the patients in the DEX group and 30% of the patients in the IVTA group required antiglaucomatous medication. Fortunately, in all cases, the IOP rise could be controlled with a single drop.

The baseline lens status in the groups is given in Table 1. There were no patients with clear lenses at baseline in the IVTA group; the patients either had a cataract or were pseudophakic. Cataract surgery was performed in none, 6.3%, and 30% of the patients in the RAN, DEX, and IVTA groups, respectively (Table 3). In phakic patients cataract, progression rates were none, 8.3% and 50% in the RAN, DEX, and IVTA groups, respectively. The percentage of patients who underwent cataract surgery was significantly higher in the IVTA group than in the other groups ($p=0.03$). However, all phakic patients in the IVTA group had already a baseline lens opacity. None of the patients with a clear lens received triamcinolone injections in our study. Additionally, none of the patients had serious complications related to injections.

Discussion

In our study, we evaluated the long-term results of IVTA, DEX, and RAN injections for the treatment of ME due to RVO. BCVA increased significantly in the RAN and DEX groups at all visits. However, the BCVA increase in the IVTA

group was significant at the first and sixth months only. CMT decreased significantly in all groups at the end of the one-year follow-up period.

Intravitreal corticosteroids have been shown to be effective for the treatment of ME secondary to RVO. In the SCORE study, 411 patients with ME due to BRVO were recruited into one of the following study groups: standard care, 1-mg IVTA, or 4-mg IVTA. VA gain and decreased CMT was more prominent at month 4 in the 4-mg IVTA group compared with the 1-mg IVTA and standard care groups. However, at the end of the 12 months, VA results were similar among the groups (4). In another study, including 76 patients with BRVO, CMT significantly decreased at month 1 following IVTA injections, but the CMT decrease and visual gain were not significantly different from the natural course group, between month 6 and month 12 (11). Consistent with the literature, BCVA significantly increased at month 1 after the IVTA injection in our study. There was no significant difference in BCVA at the 3rd and 12th months of follow-up. Interestingly, we found a significant increase in BCVA at month 6, probably due to repeated injections. CMT significantly decreased at all visits compared with baseline. This may be related to repeated injections or a relatively higher baseline mean CMT in the IVTA group. Although the CMT significantly decreased at each visit, a proportional BCVA increase could not be achieved at all visits in our study, probably due to macular ischemia.

In the GENEVA studies, 0.7 mg DEX, 0.35 mg DEX, and sham groups were compared concerning efficacy and safety in ME due to RVO (5, 6). After a single administration, both DEX groups provided significantly quicker visual gain compared with sham. Improvement in mean BCVA was greater in both DEX implant groups compared with sham at all follow-up visits (5). Likewise, in our study, a significant increase in BCVA and a significant decrease in CMT were achieved with DEX implants at all visits when compared with baseline. In a study by Bezatis et al., (12) favorable results were obtained using DEX in BRVO; however, early reinjection required in 40.7% of the patients after approximately 18 weeks. Simsek et al. reported that BCVA increased and CMT decreased significantly after the first injection of DEX in eyes with ME due

to RVO during four months of follow-up. However, there was a recurrence in 65% of the patients with BRVO, and in 70% of the patients with CRVO. After the second injection of the DEX implant, a significant improvement was achieved in BCVA and CMT (13). Kaldırım et al. indicated that DEX injections should be repeated after three or four months (14). In that study, a single dose of DEX was better than anti-VEGF agents concerning VA and CMT for the first three months, whereas it remained behind RAN and aflibercept at the end of a 6-month follow-up period. A significant improvement in BCVA and CMT was achieved at the end of 12 months of follow-up in our study because 75% of the patients in the DEX group received two or more injections.

In the BRAVO study, the efficacy and safety results of monthly injections of 0.3 mg RAN, 0.5 mg RAN, and sham groups were compared for the treatment of RVO-induced ME. At the end of six months, the average change in BCVA from baseline, and a decrease in the mean CMT were significantly more in both RAN groups (7). In the 12-month outcomes of the BRAVO study, the improvements achieved in the first 6 months could be maintained during 6-11 months with low rates of ocular and nonocular safety events (8). In the HORIZON trial, which was an extension of the BRAVO and CRUISE trials, patients were seen at least every three months and given RAN injections when required. Reduced frequency of injections in the second year resulted in a worsening of vision in patients with CRVO. Fortunately, the visual gain in patients with BRVO remained relatively stable after one year of the follow-up (15). It was suggested that individualized follow-up and more frequent injections were required, especially in patients with CRVO. However, it was reported that in real-world clinical practice, injection numbers could not reach the ideal levels in controlled trials (16). Likewise, in our study, the mean number of RAN injections was lower than in prospective, controlled studies (7, 17), probably due to poor patient compliance, cost, and the PRN application of the injections. However, our results of fewer RAN injections are comparable with the literature. In our study, compared with baseline, the visual improvement in the RAN group was significant at all visits during the one-year follow-up. CMT also significantly decreased from baseline at month 1, 3, and 12. The decrease in the mean CMT could not be maintained at month 6, probably due to a lower frequency of injections. In another real-world retrospective study by Ozkaya et al., favorable functional and anatomic outcomes were obtained with ranibizumab, although the number of injections was lower than the multicenter controlled studies (18).

In the COMO study, the mean change from baseline in BCVA at month 12 was significantly higher in the RAN group than in the DEX group (17). The superiority of RAN in that study might be related to the higher frequency of injections

in the RAN group: the mean number of injections was 2.5 vs. 8 in the DEX and RAN groups, respectively. Compared with real-world practice, the frequency of RAN retreatment was reported to be high in that study (17). In our study, the mean number of injections was 1.88 vs. 2.35 in the DEX and the RAN groups, respectively.

The mean SFCT was reported to be significantly increased in eyes with BRVO compared with the fellow eye, and healthy eyes without BRVO (19, 20). The mean SFCT decreased significantly after injections of IVTA, RAN, and DEX (19, 21). In accordance with the literature, the mean SFCT in our study was significantly decreased one month after the injection in all treatment groups. Interestingly, SFCT increased in later visits. This may be a sign of the chronicity of the disease. However, further studies are required to explain the etiopathogenesis.

Cataract progression rates after IVTA are high in the literature. Lens opacity onset or progression rate was 35% in the SCORE study using 4-mg IVTA (4). The cataract surgery rate in the phakic patients of the IVTA group was even higher in our study (50%) because all phakic patients in our IVTA group had existing lens opacity at baseline. None of the patients with a clear lens received triamcinolone injections in our study. IVTA might accelerate cataract progression. According to the GENEVA report, about the 12-month results of DEX implants in RVO, cataracts progressed in 29.8% of eyes that were retreated with DEX, whereas the rate was 5.7% in eyes that received a single implant (6). In a head-to-head comparison study of DEX vs. RAN, cataract surgery rates were 3.1% vs. 0% (17). Our cataract surgery rates were the same in the RAN group and close to that study in the DEX group. According to the literature, it should be kept in mind that cataract surgery rates may increase up to 70.5% with higher numbers of DEX injections and longer follow-up periods (22).

In our study, IOP increased significantly in 30% of the patients in the IVTA group and in 18.3% in the DEX group. There was no significant increase in IOP in the RAN group. The increase in IOP could be controlled with topical anti-glaucomatous agents in all patients. Therefore, there was no statistically significant difference between IOP values at baseline and at month 12 in any of the groups. Although the mean number of IVTA injections was slightly higher in our study than the 4-mg IVTA group of the SCORE study (2.9 vs. 2.1), the percentage of patients with an IOP increase after IVTA was lower (30% vs. 41%) (6). This difference may be related to the smaller sample size of the IVTA group in our study. The percentage of patients with an IOP rise after DEX in our study was lower than in the COMO and GENEVA studies (18.8% vs. 38.6% and 35.8%, respectively), but it was consistent with the study of Simsek et al. (18.8% vs. 17.5%)

(6, 13, 17). As reported previously, a higher number of repeated DEX injections may increase the risk of ocular hypertension to 54.5% (21).

The limitations of our study are its retrospective nature and the small sample size in the groups. The number of injections was fewer than the injections in multicenter randomized controlled studies. However, it has the advantage of being a real-world comparison of the efficacy and safety of three agents. We believe that further prospective studies using new therapeutics may contribute to our decision-making in the treatment of ME secondary to BRVO.

Conclusion

In real-world clinical practice, visual and anatomic outcomes of DEX and RAN treatment were similar. DEX may decrease the injection burden; however, ranibizumab may be a safer choice. The treatment of ME in BRVO should be patient-specific, with consideration to patient characteristics and possible adverse effects.

Acknowledgement

This study was presented in the 19th EVRS meeting in Lisbon at 29.06.2019.

Disclosures

Ethics Committee Approval: The Ethics Committee of Kırıkkale University Clinical Research provided the ethics committee approval for this study (04.04.2017-09/12).

Peer-review: Externally peer-reviewed.

Conflict of Interest: None declared.

Authorship Contributions: Involved in design and conduct of the study (NHD, EY, NBG); preparation and review of the study (NHD, EY, NBG); data collection (NHD, EY); and statistical analysis (NHD, EY).

References

- Cugati S, Wang JJ, Rochtchina E, Mitchell P. Ten-year incidence of retinal vein occlusion in an older population: the Blue Mountains Eye Study. *Arch Ophthalmol* 2006;124:726–32. [CrossRef]
- Sivaprasad S, Amoaku WM, Hykin P; RVO Guideline Group. The Royal College of Ophthalmologists Guidelines on retinal vein occlusions: executive summary. *Eye (Lond)* 2015;29:1633–8.
- Ehlers JP, Kim SJ, Yeh S, Thorne JE, Mruthyunjaya P, Schoenberger SD, et al. Therapies for Macular Edema Associated with Branch Retinal Vein Occlusion: A Report by the American Academy of Ophthalmology. *Ophthalmology* 2017;124:1412–23. [CrossRef]
- Scott IU, Ip MS, VanVeldhuisen PC, Oden NL, Blodi BA, Fisher M, et al; SCORE Study Research Group. A randomized trial comparing the efficacy and safety of intravitreal triamcinolone with standard care to treat vision loss associated with macular edema secondary to branch retinal vein occlusion: the Standard Care vs Corticosteroid for Retinal Vein Occlusion (SCORE) study report 6. *Arch Ophthalmol* 2009;127:1115–28. [CrossRef]
- Haller JA, Bandello F, Belfort R Jr, Blumenkranz MS, Gillies M, Heier J, et al; OZURDEX GENEVA Study Group. Randomized, sham-controlled trial of dexamethasone intravitreal implant in patients with macular edema due to retinal vein occlusion. *Ophthalmology* 2010;117:1134–46.e3. [CrossRef]
- Haller JA, Bandello F, Belfort R Jr, Blumenkranz MS, Gillies M, Heier J, et al; OZURDEX GENEVA Study Group. Dexamethasone intravitreal implant in patients with macular edema related to branch or central retinal vein occlusion: twelve-month study results. *Ophthalmology* 2011;118:2453–60. [CrossRef]
- Campochiaro PA, Heier JS, Feiner L, Gray S, Saroj N, Rundle AC, et al; BRAVO Investigators. Ranibizumab for macular edema following branch retinal vein occlusion: six-month primary end point results of a phase III study. *Ophthalmology* 2010;117:1102–12.e1. [CrossRef]
- Brown DM, Campochiaro PA, Bhisitkul RB, Ho AC, Gray S, Saroj N, et al. Sustained benefits from ranibizumab for macular edema following branch retinal vein occlusion: 12-month outcomes of a phase III study. *Ophthalmology* 2011;118:1594–602.
- Brown DM, Campochiaro PA, Singh RP, Li Z, Gray S, Saroj N, et al. Ranibizumab for macular edema following central retinal vein occlusion: six-month primary end point results of a phase III study. *Ophthalmology* 2010;117:1124–33.e1. [CrossRef]
- Yumusak E, Buyuktortop N, Ornek K. Early results of dexamethasone implant, ranibizumab and triamcinolone in macular edema due to branch retinal vein occlusion. *Eur J Ophthalmol* 2016;26:54–9. [CrossRef]
- Kwon SI, Kim YW, Bang YW, Lee JY, Park IW. Comparison of natural course, intravitreal triamcinolone and intravitreal bevacizumab for treatment of macular edema secondary to branch retinal vein occlusion. *J Ocul Pharmacol Ther* 2013;29:5–9.
- Bezatis A, Spital G, Höhn F, Maier M, Clemens CR, Wachtlin J, et al. Functional and anatomical results after a single intravitreal Ozurdex injection in retinal vein occlusion: a 6-month follow-up-the SOLO study. *Acta Ophthalmol* 2013;91:e340–7. [CrossRef]
- Simsek M, Citirik M, Ozates S, Ozkoyuncu D. The efficacy of intravitreal dexamethasone implant as the first-line treatment for retinal vein occlusion-related macular edema in a real-life scenario. *Indian J Ophthalmol* 2018;66:831–6. [CrossRef]
- Kaldırım HE, Yazgan S. A comparison of three different intravitreal treatment modalities of macular edema due to branch retinal vein occlusion. *Int Ophthalmol* 2018;38:1549–58. [CrossRef]
- Heier JS, Campochiaro PA, Yau L, Li Z, Saroj N, Rubio RG, et al. Ranibizumab for macular edema due to retinal vein occlusions: long-term follow-up in the HORIZON trial. *Ophthalmology* 2012;119:802–9. [CrossRef]
- Kiss S, Liu Y, Brown J, Holekamp NM, Almony A, Campbell J, et al. Clinical utilization of anti-vascular endothelial growth-factor agents and patient monitoring in retinal vein occlusion and diabetic macular edema. *Clin Ophthalmol* 2014;8:1611–21. [CrossRef]

17. Bandello F, Augustin A, Tufail A, Leaback R. A 12-month, multi-center, paralel group comparison of dexamethasone intravitreal implant versus ranibizumab in branch retinal vein occlusion. *Eur J Ophthalmol* 2018;28:697–705. [\[CrossRef\]](#)
18. Ozkaya A, Alkin Z, Yesilkaya C, Erdogan G, Perente I, Taskapili M. Ranibizumab in Macular Edema Secondary to Retinal Vein Occlusion in a Real Life Practice: A Retrospective Case Series. *Beyoglu Eye J* 2016;1:5–9.
19. Coban-Karatas M, Altan-Yaycioglu R, Ulas B, Sizmaz S, Canan H, Sariturk C. Choroidal thickness measurements with optical coherence tomography in branch retinal vein occlusion. *Int J Ophthalmol* 2016;9:725–9.
20. Arifoglu HB, Duru N, Altunel O, Baskan B, Alabay B, Atas M. Short-term effects of intravitreal dexamethasone implant (OZURDEX®) on choroidal thickness in patients with naive branch retinal vein occlusion. *Arq Bras Oftalmol* 2016;79:243–6.
21. Yumusak E, Ornek K, Dikel NH. Comparison of choroidal thickness changes following intravitreal dexamethasone, ranibizumab and triamcinolone in eyes with retinal vein occlusion. *Eur J Ophthalmol* 2016;26:627–32. [\[CrossRef\]](#)
22. Blanc J, Deschasse C, Kodjikian L, Dot C, Bron AM, Creuzot-Garcher C. Safety and long-term efficacy of repeated dexamethasone intravitreal implants for the treatment of cystoid macular edema secondary to retinal vein occlusion with or without a switch to anti-VEGF agents: a 3-year experience. *Graefes Arch Clin Exp Ophthalmol* 2018;256:1441–8. [\[CrossRef\]](#)