



# Anterior Segment Optic Coherence Tomography Changes Before and After Phacoemulsification in Primary Open-Angle Glaucoma

Sibel Zirtiloglu, Ozen Ayranci Osmanbasoglu, Tulay Alpar Akcetin, Yeliz Acar, Mustafa Suat Alikma, Erkan Unsal, Kadir Eltutar

Department of Ophthalmology, Istanbul Training and Research Hospital, Istanbul, Turkey

## Abstract

**Objectives:** The goal of this study was to compare measurements of values such as the anterior chamber angle (ACA), thickness of the iris, thickness of the cornea, and the angle-opening distance (AOD) of eyes with primary open-angle glaucoma before and after undergoing phacoemulsification with intraocular lens implantation using anterior segment optical coherence tomography (AS-OCT).

**Methods:** The data of 49 eyes of 39 glaucoma patients who presented at the Cataract and Refractive Surgery Unit of the Ophthalmology Clinic of , University of Health Sciences, Istanbul Training and Research Hospital between December 2014 and May 2016 were included in the study. All of the patients were examined with AS-OCT. All of the preoperative and postoperative data were evaluated statistically using a paired t-test and the Wilcoxon test. A statistical significance level of alpha was accepted as  $p < 0.05$ .

**Results:** The AS-OCT measurements of 39 patients (22 women and 17 men) with primary open-angle glaucoma were included in the study. The median age of the total population was  $67 \pm 8$  years. No statistically significant difference was found between preoperative and postoperative measurements of the corneal thickness ( $p = 0.480$ ). However, there was a statistically significant difference between measurements of the ACA, AOD ( $500 \mu\text{m}$  and  $750 \mu\text{m}$ ), thickness of the iris curvature, anterior chamber depth, and trabecular-iris space area before and after the operation ( $p < 0.001$ ). Intraocular pressure (IOP) levels decreased significantly in the first and third months after surgery ( $p = 0.019$ ;  $p = 0.003$ , respectively).

**Conclusion:** This study with AS-OCT imaging has confirmed after phacoemulsification and intraocular lens implantation in patients with glaucoma, the angle of the anterior chamber grows wider. As a result, IOP decreases and becomes easier to control.

**Keywords:** Anterior chamber optical coherence tomography, anterior opening distance, cataract, phacoemulsification, primary open-angle glaucoma.

## Introduction

Glaucoma is a progressive optic neuropathy characterized by various changes in the optic nerve head and retinal nerve fiber layer that may or may not include a visual field defect (1, 2).

Primary open-angle glaucoma (POAG) is one of the most common causes of glaucoma and accounts for about three-quarters (74%) of all glaucoma cases (3). Although clinical investigations have confirmed the importance of intraocular pressure (IOP) in the development and progression of open-angle glaucoma, ocular and systemic factors (age, demographic factors, genetic and vascular causes, etc.) are also factors in

the development and progression of glaucoma (4, 5).

In general, glaucoma and cataract formations are diseases that occur in similar age groups, and they may occur in combination. It has been established that drugs such as pilocarpine, used in glaucoma treatment, can accelerate the formation of a cataract. In addition, with age, lens volume increases, leading to narrowing of the anterior camera and iridocorneal angle, and consequently increasing resistance in the aqueous outflow, which induces IOP elevation (6).

Examination of angle elements with gonioscopy lenses is accepted as the gold standard. However, it is a subjective technique and influenced by the experience of the examiner

**Address for correspondence:** Sibel Zirtiloglu, MD. Istanbul Egitim ve Arastirma Hastanesi, Oftalmoloji Anabilim Dalı, Istanbul, Turkey  
**Phone:** +90 505 665 99 65 **E-mail:** sibel1077@hotmail.com

**Submitted Date:** January 24, 2019 **Accepted Date:** May 12, 2019 **Available Online Date:** August 09, 2019

©Copyright 2019 by Beyoglu Eye Training and Research Hospital - Available online at [www.beyoglu-eye.com](http://www.beyoglu-eye.com)

OPEN ACCESS This work is licensed under a Creative Commons Attribution-NonCommercial 4.0 International License.



(7). There are many studies in the literature that demonstrate the effect of phacoemulsification on narrow-angle glaucoma (8, 9). The aim of this study was to evaluate these changes in open-angle glaucoma using anterior segment optical coherence tomography (AS-OCT). After phacoemulsification, the degree of the iridocorneal angle increases. This research was designed to examine the correlation between iris thickness (IT) and angle-opening distance (AOD) at both 500 $\mu$ m and 750 $\mu$ m (AOD500 and AOD750). AS-OCT is a non-invasive and non-contact technique (optical biopsy) that allows for cross-sectional imaging of the AS at a resolution of 6 $\mu$ m to 25 $\mu$ m with real-time, 2-dimensional imaging. Three-dimensional images are available in the latest models. AS-OCT does not require local anesthesia as a non-contact method (10). The main disadvantage is that the wavelength is absorbed by the pigments of the iris, which does not allow for a view behind the iris. Therefore it may not be possible to see some reasons for secondary angle closure, such as plateau iris, ciliary body tumors, lens subluxation, or ciliary effusion. The great advantage of AS-OCT is that it is both quick and simple to perform (11).

## Methods

A total of 49 eyes of 39 patients who underwent phacoemulsification with intraocular lens (IOL) implantation due to age-related cataract formation in the glaucoma department of a single institution between December 2014 and May 2016 were studied retrospectively. The study was performed in accordance with the Declaration of Helsinki. Informed consent was obtained from all of the patients. Approval was granted by the ethical committee of Istanbul Bakirkoy Dr. Sadi Konuk Training and Research Hospital on 27/07/2016 (no: 2016-238). After the approval of local Ethics Committee, The study data were then collected from the hospital archive. The inclusion and exclusion criteria are presented in Table I.

Each patient underwent a typical annual ophthalmic examination before treatment. Biomicroscopic examination and IOP measurements with a Goldmann applanation tonometer were performed preoperatively and postoperatively at the first and third month. Antiglaucoma medications were evaluated 1 month after the surgery. The iridocorneal angle was assessed with a 3-mirror lens. Cases classified as Grade 4 glaucoma according to the Shaffer system were included in the study. Patients with onset and moderate-level disease were evaluated in the glaucoma department according to the RNFL and visual field findings. Funduscopy examination was performed using a 90D biomicroscopy lens after application of 1% cyclopentolate (Sikloplejin; Abdi Ibrahim Ilac Sanayi ve Tic A.S., Istanbul, Turkey) and 1% tropicamide (Tropamid Forte; Bilim Ilac Sanayi ve Tic A.S., Istanbul, Turkey) eye drops.

Following the required surgical site cleaning, the standard

**Table I.** Criteria for inclusion and exclusion

### Criteria for inclusion

- Glaucoma history
- Cataract accompanied by glaucoma.
- Phacoemulsification surgery without complications.
- At least 6 months of follow-up in the glaucoma department.
- Use at least one glaucoma medication
- Intraocular pressure control with drugs and no need for glaucoma surgery
- No neurological or psychiatric illness that would make compliance difficult.
- No additional ocular disease (senile macular degeneration, uveitis, ocular disease, trauma, retinal detachment, etc.).
- No additional systemic disease that will cause ocular complications (diabetes mellitus, hypertension etc.).

### Criteria for exclusion

- Mature cataracts.
- Patients with alpha 1 blocker due to hypertension or benign prostatic hyperplasia.
- Cataract diagnosis due to trauma, uveitis or secondary causes.
- Follow-up due to narrow-angle or secondary angle glaucoma.
- Newly diagnosed (less than 6 months) glaucoma patients.
- Attempts to change the anterior segment structure, such as trabeculectomy or iridotomy.
- Patients with eye disease other than cataracts and glaucoma
- Conditions such as a macular disease that will cause a non-glaucoma visual field defect in the fundus
- Patients with advanced level glaucoma (based on visual field and RNFL findings).

phacoemulsification technique was performed by a single surgeon in all cases. A corneal incision was made with a 2.8-mm blade. Typical phacoemulsification techniques were applied according to the type of nucleus. A foldable IOL was implanted into the capsule through the main incision using viscoelastic material. The clear cornea cataract incision was inflated with balanced salt solution and the operation was completed with an intracameral injection of cefuroxime antibiotic prophylaxis.

Central corneal thickness (CCT), anterior chamber angle (ACA), IT, AOD at both 500 $\mu$ m and 750 $\mu$ m (AOD500 and AOD750), maximum iris bow height (MIBH), and anterior chamber depth at 2000 $\mu$ m (ACD) were measured using the AS-OCT scans and evaluated to determine whether any significant changes had occurred. The AOD500 is defined as the length of a line beginning at a point on the cornea-trabecular meshwork (500 $\mu$ m anterior to the scleral spur) and perpendicular to the iris surface. The IT at 500 $\mu$ m (IT500) records the IT measured at the iris surface 500 $\mu$ m from the scleral spur. The MIBH is the perpendicular distance measured from the posterior iris pigment epithelial surface at its

apex (i.e., the point where iris bowing was greatest) to the line joining the iris pigment epithelium at the pupil edge to its insertion at the ciliary body. The trabecular iris space area (TISA500) is bounded by the corneal endothelium, trabecular meshwork, and anterior iris surface to a distance 500µm from the scleral spur.

The patients were evaluated preoperatively and again at 1 and 3 months postoperatively. The study included analysis of patient age, sex, preoperative findings, IOP change, postoperative visual acuity, and perioperative and postoperative complications. AS imaging was performed in a darkened room (curtains and doors closed, only OCT scan beams) with a Topcon 3D OCT-2000FA Plus (Topcon Corp., Tokyo, Japan) AS-OCT device after biomicroscopic AS examination. The temporal cross-section of the cornea was focused on the right eye at 9 o'clock and the left eye at 3 o'clock. All measurements were recorded at least twice at different times by the same individual. CCT, ACD, ACA, AOD500, and AOD250 were measured using the scales provided with the device software (Fig. 1).

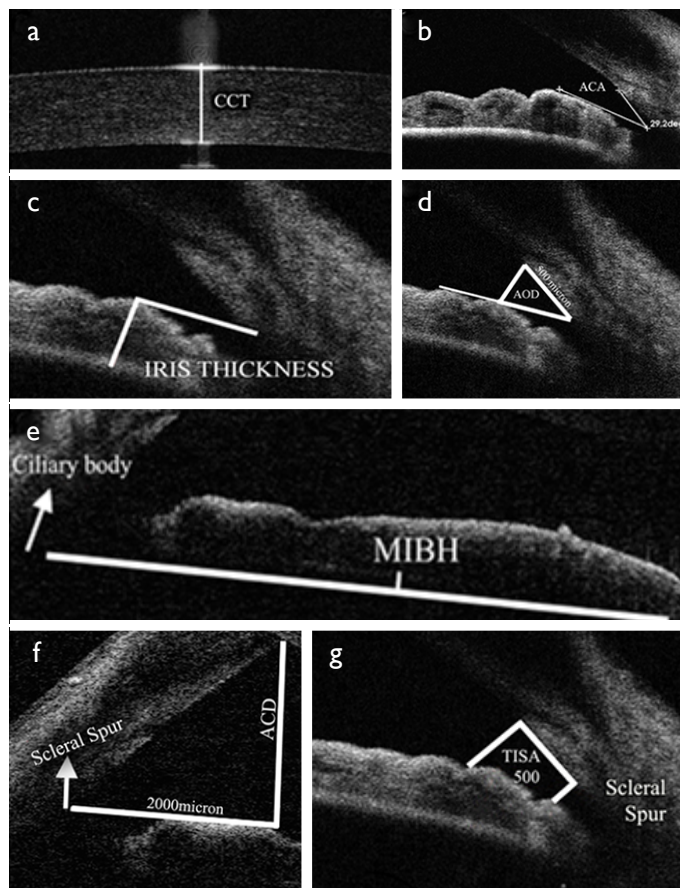
SPSS for Windows, Version 15.0 (SPSS Inc., Chicago, IL, USA) was used for the statistical calculations. Descriptive statistics were reported as mean and SD. A paired t-test was used to assess 2 dependent groups if the data were normally distributed, and the Wilcoxon test was applied when the distribution was not normal. Statistical significance was accepted at  $p < 0.05$ .

**Results**

The mean age of the patients was  $67 \pm 8$  years. The mean values of the other parameters and data are shown in Tables 2 and 3. No significant difference was observed between the preoperative and postoperative first- and third-month CCT values ( $p=0.490$ ;  $p=0.480$ , respectively).

The ACA, IT, AOD500, AOD750, ACD, TISA500 values were statistically significantly greater after the surgery. Post-

operative MIBH values were significantly smaller when compared with the measurements recorded before the surgery (Table 2). IOP measurements were also significantly reduced at postoperative month 1 and 3 (Tables 3 and 4).



**Figure 1.** Images of optical coherence tomography measurements. (a) CCT: Central corneal thickness; (b) ACA: Anterior chamber angle; (c) Iris thickness; (d) AOD: Anterior opening distance; (e) MIBH: Maximum iris bow height; (f) ACD: Anterior chamber depth; (g) TISA: Trabecular iris space area. All of these images were digitally processed with Microsoft Paint (Microsoft Corp., Redmond, WA, USA).

**Table 2.** Mean values for preoperative and postoperative measurements

	Preoperative	Postoperative 1 <sup>st</sup> month	p	Postoperative 3 <sup>rd</sup> month	p
CCT (µm)	540.9±49.3	539±37.8	0.490	538.3±34.4	0.480
ACA (degrees)	35.3±9.8	42.3±9.2	<0.001	46.1±11.5	<0.001
IT (µm)	336.9±68.7	361.4±67.8	0.030	362.3±67.7	0.037
AOD 500 (µm)	362.6±120.1	451.5±110.2	<0.001	452.3±106.6	0.005
AOD 750 (µm)	499.6±142.0	618.7± 132.2	0.002	628.4±124.6	<0.001
MIBH (µm)	121.0±109.0	65.0±90.3	<0.001	55.0±91.3	<0.001
ACD (µm)	1696.9±275.4	2129.8± 275.2	0.010	2231.9±281.1	<0.001
TISA 500 (µm <sup>2</sup> )	252181.8±106815.2	341115.0±102255.6	<0.001	351125.0±122255.6	<0.002

ACA: Anterior chamber angle; ACD: Anterior chamber depth; CCT: Central corneal thickness; IT: Iris thickness; MIBH: Maximum iris bow height; TISA: Trabecular iris space area.

**Table 3.** Mean values for preoperative and postoperative IOP measurements

	Preoperative	Postoperative 1 <sup>st</sup> month	Postoperative 3 <sup>rd</sup> month
Mean IOP±SD (mmHg)	17.9±3.0	14.6±3.0	15.6±2.8

IOP: Intraocular pressure.

**Table 4.** P value of preoperative and postoperative IOP measurement comparisons

	Preoperative vs. 1 <sup>st</sup> month	Preoperative vs. 3 <sup>rd</sup> month	Postoperative 1 <sup>st</sup> vs. 3 <sup>rd</sup> month
p	0.019	0.003	0.002

IOP: intraocular pressure.

## Discussion

Cataract surgery is the most common surgical procedure in the world. The development of a cataract or glaucoma is associated with advanced age and may occur simultaneously. Cataract surgery provides generally positive results for glaucoma patients. Elimination of cataract-associated media opacification facilitates monitoring of the progression of optical neuropathy (e.g., changes in cup/disc ratio, optical nerve head analysis) and the patient's visual field (12). It has been established that changes in the AS morphology occur after phacoemulsification and IOL implantation (13). The objective of our study was to demonstrate these morphology changes in patients with open-angle glaucoma using AS-OCT.

The crystalline lens is larger than an IOL in anterior-posterior thickness and volume. After cataract surgery, the iris-lens diaphragm moves backward and increases the anterior chamber volume and expands the iridocorneal angle (8). Cataract surgery relieves the load on the anterior chamber with the removal of the swollen lens. Combined phacoemulsification and IOL with trabeculectomy or single surgery may be considered, depending on the degree of the cataract and the severity of the glaucoma in eyes with the simultaneous presence of both.

Phacoemulsification should not be planned to provide IOP control, but it is notable that the IOP may remain the same or may fall within a year (14, 15). The ACD is an important parameter that should be determined before cataract surgery and IOL placement. In order to determine the correct lens position, as well as the IOL power obtained using keratometry and axial length values, the ACD must be measured accurately preoperatively. The ACD is particularly important in the diagnosis and treatment of glaucoma patients (16). Yagci et al. (17) found that there was an increase in the ACD as well as the ACA in their study results, which revealed an inverse correlation with preoperative values. The

IT500 measured from the scleral spur represents the anterior-posterior IT nearer the angle vs the pupil. Lin et al. (18) reported that the IT may be more relevant as an indicator of angle status and risk for a narrow angle and that it was predictive of IOP decrease (18). They also stated that crowding of the angle can be associated with the IOP outcome after phacoemulsification. However, Unsal et al. (19) found no significant difference in IT before and after phacoemulsification. In our study, there was a significant increase in IT compared with the preoperative results. We attributed this to the decrease in crowding in the anterior segment. A number of studies have been conducted in our country that have evaluated anterior chamber parameters (20, 21)

Our research revealed no statistically significant difference between the first and third months, although the IOP values in the third month were slightly higher than those of the first month. At the first postoperative visit, antiglaucoma treatment was reevaluated and some patients discontinued the use of medications. In the healthy population, CCT has a diurnal variation with a wide standard deviation. It is independent of age and ocular biometric values. Anterior chamber dynamics during surgery may lead to a greater postoperative CCT due to tissue damage and endothelial cell damage (22, 23). Different techniques, such as optical slit scanning pachymetry, partial coherence interferometry, OCT, confocal biomicroscopy, specular microscope, and the Pentacam Scheimpflug-imaging system (OCULUS Optikgeräte GmbH, Wetzlar, Germany) are used to record measurements, as well as the gold standard of ultrasonic pachymetry (24, 25). CCT does not change with age or sex (26). The most important factor affecting CCT in cataract surgery is the duration of phacoemulsification. In this study, there was no significant difference between the preoperative and postoperative CCT values. Nigra cataracts were excluded, all of the operations were performed by the same surgeon, and the duration of the phacoemulsification was similar. The main reason for vari-

ability in the measurement analysis is the choice of the image frame to be measured and differences in the location of the scleral spur. Room lighting, fixation, and accommodative effort are factors that affect the AS anatomy and are therefore factors that must remain constant, especially when quantitative measures are taken. AS-OCT has been shown to have good repeatability and reproducibility in other studies (27). Since scleral angular aperture measurements are made on the iris plane, irregularities, such as anterior synechiae, can alter the iris contour and affect the results. Ishikawa et al. (28) first identified the angle recess area, a triangle defined by the iris surface (apex), the internal corneal wall (sides), and the scleral angle opening distance (floor). This angle of view can be difficult to observe, however, and Radhakrishnan et al. (29) defined the trabeculo-iris space area, which does not need to be very well displayed.

This study has some limitations. First, the duration of this study was only 3 months; glaucoma patients are known to require longer follow-up. Second, this study included a relatively small number of participants. Third, we did not evaluate the diurnal variation of IOP.

## Conclusion

AS imaging methods give us valuable information about glaucoma pathogenesis. Phacoemulsification affects the AS parameters in primary open-angle glaucoma. AS-OCT can be used more often in primary open-angle glaucoma.

## Disclosures

**Ethics Committee Approval:** Approval was granted by the ethical committee of Istanbul Bakirkoy Dr. Sadi Konuk Training and Research Hospital on 27/07/2016 (no: 2016-238).

**Peer-review:** Externally peer-reviewed.

**Conflict of Interest:** None declared.

**Authorship Contributions:** Involved in design and conduct of the study (T.A.A., S.Z.); preparation and review of the study (S.Z., O.A.O., K.E.); data collection (M.S.A., Y.A.); and statistical analysis (Z.A.).

## References

- Begum VU, Addepalli UK, Senthil S, Garudadri CS, Rao HL. Optic nerve head parameters of high-definition optical coherence tomography and Heidelberg retina tomogram in perimetric and preperimetric glaucoma. *Indian J Ophthalmol* 2016;64:277–84.
- Chong RS, Martin KR. Glial cell interactions and glaucoma. *Curr Opin Ophthalmol* 2015;26:73–7. [CrossRef]
- Kapetanakis VV, Chan MP, Foster PJ, Cook DG, Owen CG, Rudnicka AR. Global variations and time trends in the prevalence of primary open angle glaucoma (POAG): a systematic review and meta-analysis. *Br J Ophthalmol* 2016;100:86–93.
- Actis AG, Versino E, Brogliatti B, Rolle T. Risk Factors for Primary Open Angle Glaucoma (POAG) Progression: A Study Ruled in Torino. *Open Ophthalmol J* 2016;10:129–39. [CrossRef]
- He J, Zou H, Lee RK, Tong X, Tang W, Zhang Y, et al. Prevalence and risk factors of primary open-angle glaucoma in a city of Eastern China: a population-based study in Pudong New District, Shanghai. *BMC Ophthalmol* 2015;15:134. [CrossRef]
- Takata T, Nakamura-Hirota T, Inoue R, Morishima K, Sato N, Sugiyama M, et al. Asp 58 modulates lens  $\alpha$ A-crystallin oligomer formation and chaperone function. *FEBS J* 2018;285:2263–77.
- Li M, Chen Y, Chen X, Zhu W, Chen X, Wang X, et al. Differences between fellow eyes of acute and chronic primary angle closure (glaucoma): An ultrasound biomicroscopy quantitative study. *PLoS One* 2018;13:e0193006. [CrossRef]
- Man X, Chan NC, Baig N, Kwong YY, Leung DY, Li FC, et al. Anatomical effects of clear lens extraction by phacoemulsification versus trabeculectomy on anterior chamber drainage angle in primary angle-closure glaucoma (PACG) patients. *Graefes Arch Clin Exp Ophthalmol* 2015;253:773–8. [CrossRef]
- Römken HCS, Beckers HJM, Schouten JSAG, Nuijts RMMA, Berendschot TTJM, Breusegem CM, et al. Early Phacoemulsification After Acute Angle Closure in Patients With Coexisting Cataract. *J Glaucoma* 2018;27:711–6. [CrossRef]
- Maslin JS, Barkana Y, Dorairaj SK. Anterior segment imaging in glaucoma: An updated review. *Indian J Ophthalmol* 2015;63:630–40. [CrossRef]
- Krema H, Santiago RA, Gonzalez JE, Pavlin CJ. Spectral-domain optical coherence tomography versus ultrasound biomicroscopy for imaging of nonpigmented iris tumors. *Am J Ophthalmol* 2013;156:806–12. [CrossRef]
- Huang G, Gonzalez E, Peng PH, Lee R, Leeungurasatien T, He M, et al. Anterior chamber depth, iridocorneal angle width, and intraocular pressure changes after phacoemulsification: narrow vs open iridocorneal angles. *Arch Ophthalmol* 2011;129:1283–90. [CrossRef]
- Kim M, Park KH, Kim TW, Kim DM. Anterior chamber configuration changes after cataract surgery in eyes with glaucoma. *Korean J Ophthalmol* 2012;26:97–103. [CrossRef]
- Iancu R, Corbu C. Intraocular pressure after phacoemulsification in patients with uncontrolled primary open angle glaucoma. *J Med Life* 2014;7:11–6.
- Chen PP, Lin SC, Junk AK, Radhakrishnan S, Singh K, Chen TC. The Effect of Phacoemulsification on Intraocular Pressure in Glaucoma Patients: A Report by the American Academy of Ophthalmology. *Ophthalmology* 2015;122:1294–307. [CrossRef]
- Perez CI, Chansangpetch S, Feinstein M, Mora M, Nguyen A, Badr M, et al. Novel Gonioscopy Score and Predictive Factors for Intraocular Pressure Lowering After Phacoemulsification. *J Glaucoma* 2018;27:622–6. [CrossRef]
- Yağcı R, Güler E, Uzun F, Güragaç BF, Acer S, Hepşen İF. Assessment of anterior chamber parameters after cataract surgery by Galilei dual Scheimpflug analyzer. *Eye Contact Lens* 2015;41:40–3. [CrossRef]

18. Lin SC, Masis M, Porco TC, Pasquale LR. Predictors of Intraocular Pressure After Phacoemulsification in Primary Open-Angle Glaucoma Eyes with Wide Versus Narrower Angles (An American Ophthalmological Society Thesis). *Trans Am Ophthalmol Soc* 2017;115:T6.
19. Ünsal E, Eltutar K, Muftuoglu İK. Morphologic changes in the anterior segment using ultrasound biomicroscopy after cataract surgery and intraocular lens implantation. *Eur J Ophthalmol* 2017;27:31–8. [\[CrossRef\]](#)
20. Kandarakis A, Soumplis V, Karampelas M, Koutroumanos I, Panos C, Kandarakis S, et al. Response of corneal hysteresis and central corneal thickness following clear corneal cataract surgery. *Acta Ophthalmol* 2012;90:526–9. [\[CrossRef\]](#)
21. Kucumen RB, Yenerel NM, Gorgun E, Kulacoglu DN, Dinç UA, Alimgil ML. Investigation of the Anterior Chamber Depth and Angle Changes by the Anterior Segment Optical Coherence Tomography After Cataract Surgery. *Journal of Glaucoma-Cataract* 2008;3.
22. Ismi T, Yilmaz A. Effects of cataract surgery on intraocular pressure in patients with and without glaucoma. *Turk J Ophthalmol*. 2013;43:167–72. [\[CrossRef\]](#)
23. Shazly TA, Latina MA, Dagianis JJ, Chitturi S. Effect of central corneal thickness on the long-term outcome of selective laser trabeculoplasty as primary treatment for ocular hypertension and primary open-angle glaucoma. *Cornea* 2012;31:883–6.
24. Kránitz K, Kovács I, Miháltz K, Sándor GL, Juhász É, Gyenes A, et al. Changes of corneal topography indices after CXL in progressive keratoconus assessed by Scheimpflug camera. *J Refract Surg* 2014;30:374–8. [\[CrossRef\]](#)
25. Gokcinar NB, Yumusak E, Ornek N, Yorubulut S, Onaran Z. Agreement and repeatability of central corneal thickness measurements by four different optical devices and an ultrasound pachymeter. *Int Ophthalmol* 2018 Jul 9 [Epub ahead of print], doi: 10.1007/s10792-018-0983-2. [\[CrossRef\]](#)
26. Keel S, Malesic L, Chan SP. Diurnal variation in central corneal thickness and intraocular pressure in eyes with pseudoexfoliation syndrome without glaucoma. *Indian J Ophthalmol* 2014;62:1072–6. [\[CrossRef\]](#)
27. Lee W, Bae HW, Kim CY, Seong GJ. The change of anterior segment parameters after cataract surgery in normal-tension glaucoma. *Int J Ophthalmol* 2017;10:1239–45.
28. Sheppard LB. Intrasccleral Drainage Channels of the Normal Rabbit Eye. *Trans Am Ophthalmol Soc* 1959;57:99–108.
29. Radhakrishnan S, Goldsmith J, Huang D, Westphal V, Dueker DK, Rollins AM, et al. Comparison of optical coherence tomography and ultrasound biomicroscopy for detection of narrow anterior chamber angles. *Arch Ophthalmol* 2005;123:1053–9.