



A Rare Cause of Preseptal Cellulitis: Cutaneous Leishmaniasis

Hazal Bircan, Nilay Yuksel

Department of Ophthalmology, Ankara City Hospital, Ankara, Türkiye

Abstract

Cutaneous leishmaniasis (CL) is a protozoal disease that occurs in many parts of the world, usually caused by *Leishmania major* and *Leishmania tropica* and transmitted by sandfly bites. Eyelid involvement is rarely seen as the movement of the eyelids prevents the fly vector from biting the skin in this area. We report a case of cutaneous leishmaniasis with eyelid involvement causing preseptal cellulitis in a 71-year-old male patient.

Keywords: Eyelid, leishmaniasis, preseptal cellulitis

Introduction

Leishmaniasis is a disease caused by protozoan parasites of the genus *Leishmania* and transmitted by the bite of infected female phlebotomine sandflies (1-3). The disease can be seen in three forms: Cutaneous, mucocutaneous, and visceral leishmaniasis (3).

Cutaneous leishmaniasis (CL) is the most common form with 1.5 million new cases per year (1). It is caused by *Leishmania major* and *Leishmania tropica* and is an important public health problem in many regions of the world (1). Cutaneous leishmaniasis is endemic in certain regions of Afghanistan, Algeria, Iran, Iraq, Saudi Arabia, Syria, Türkiye, Brazil, and Peru (3). The clinical picture is characterized by the development of single or multiple localized lesions that begin as nodules on the exposed areas of the skin bitten by sandflies typically ulcerate and usually heal spontaneously within 3–6 months (4). Although the face is the region where the infection is the most common, the eyelids are a rare

region due to the movement of the lids and eyelashes (2,4). Therefore, eyelid involvement accounts for 2.5% of cutaneous leishmaniasis cases (2,3).

Herein, we report the clinical features, diagnosis, and treatment of CL on the eyelid in a patient who presented with preseptal cellulitis.

Case Report

A 71-year-old-man living in the countryside presented to several clinics with the complaint of swelling and redness on the right forehead 5 months ago and received various topical antibiotic treatments. However, lesions did not respond to treatments and spread to the periorbital region, and he was referred to our clinic with a preliminary diagnosis of preseptal cellulitis. On inspection, there were edema and hyperemia on both eyelids on the right side, predominantly on the upper eyelid, and crusted lesions that were mainly located on the lateral aspect of the right eyebrow

How to cite this article: Bircan H, Yuksel N. A Rare Cause of Preseptal Cellulitis: Cutaneous Leishmaniasis. *Beyoglu Eye J* 2022; 7(4): 320-323.

Address for correspondence: Hazal Bircan, MD. Department of Ophthalmology, Ankara City Hospital, Ankara, Türkiye

Phone: +90 506 785 33 64 **E-mail:** hazalbircan44@gmail.com

Submitted Date: May 04, 2022 **Revised Date:** August 01, 2022 **Accepted Date:** August 18, 2022 **Available Online Date:** November 15, 2022

Beyoglu Eye Training and Research Hospital - Available online at www.beyoglueye.com

OPEN ACCESS This is an open access article under the CC BY-NC license (<http://creativecommons.org/licenses/by-nc/4.0/>).



and spread to the forehead (Fig. 1). There was no heat or tenderness on the eyelids. Bilateral visual acuity was 20/20. The anterior segment and fundus examinations were normal. Eye movements were normal bilaterally. Medical history revealed no trauma, chronic systemic disease, or known immunodeficiency disorder. Orbital computed tomography was reported to be consistent with preseptal cellulitis. The patient was consulted by the dermatology department to rule out herpetic infection and impetigo. Intravenous ampicillin-sulbactam 4 × 2 g was started after consultation with the infectious diseases department. On the 5th day of the treatment, there was no response to the treatment. Thus, the infectious diseases and dermatology departments were consulted again. Infectious diseases started intravenous (iv) amphotericin-B 3 mg/kg for possible fungal infection and it was decided to continue with intravenous (iv) piperacillin-tazobactam 3 × 0.5 g. There was no additional recommendation from the dermatology department. No regression was observed in clinical findings on the 12th day of treatment. Therefore, it was decided to perform a biopsy of the skin lesions.

Histopathological evaluation of the biopsy was reported as cutaneous leishmaniasis. The patient was consulted by the dermatology department again and it was decided to perform an intralesional glucantime injection. Glucantime injection was administered as an intralesional injection once a week for 5 weeks (1 cycle). At the end of this period, regression of the lesions was observed and the treatment was con-

tinued for one more cycle. After the second cycle, significant improvement was detected in the lesions (Fig. 2). Following 4 years of treatment, there was no sign of infection and the lesions healed without any scarring (Fig. 3).

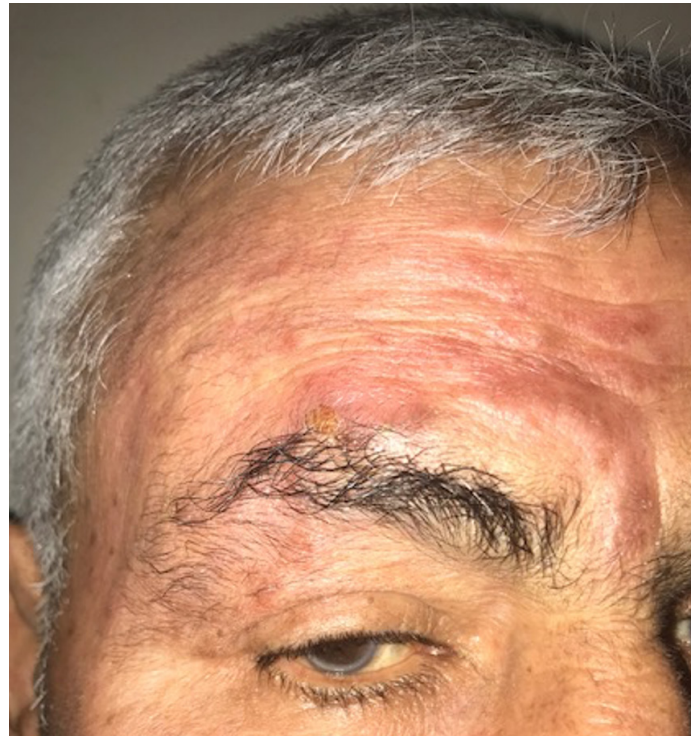

Figure 2. After the 2nd cycle of the treatment.

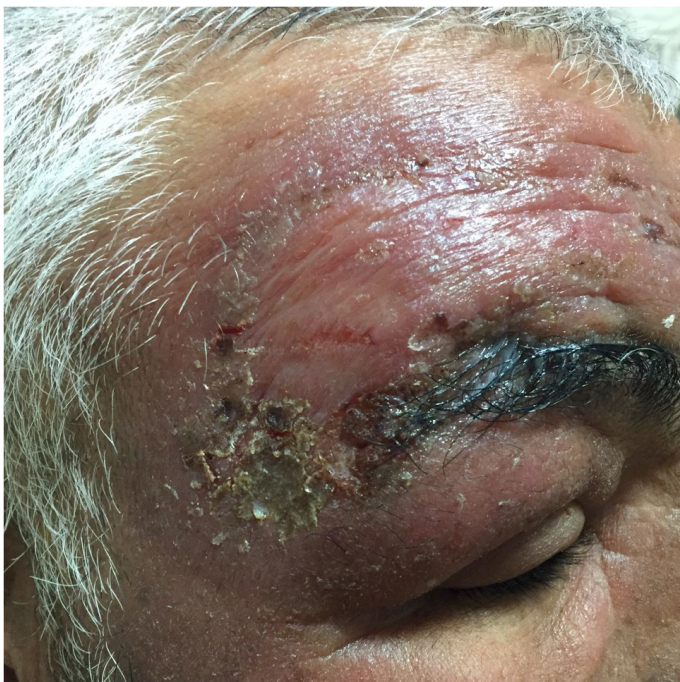

Figure 1. Eyelid edema and crusted lesions mainly located on the lateral aspect of the right eyebrow.

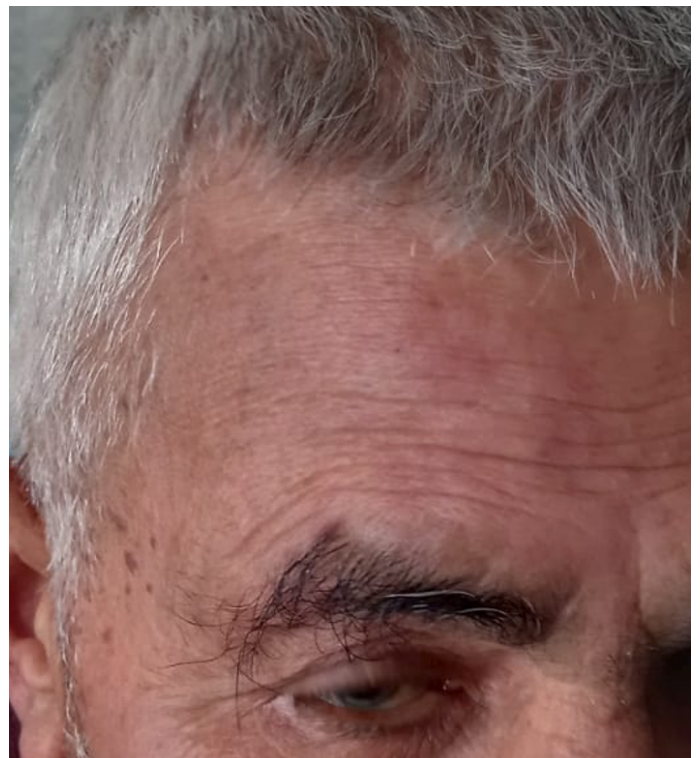


Figure 3. After 4 years of the treatment.

Discussion

Leishmaniasis is endemic in nearly 98 countries where more than 350 million people are at risk (1).

The clinical manifestations of CL are seen in a wide spectrum depending on the *Leishmania* strains and the immune status of the host. The typical clinical presentation is characterized by a painless ulcer with raised edges covered with a crust adhered to a necrotic base in the affected area after an incubation period of 1–12 weeks following an infected sandfly bite (3). Fever or pain is not a feature of an ulcer (5,6).

The face is a common site of involvement in CL, but eyelid involvement is rare and accounts for only 2–5% of cases of facial CL (2,3). Durdu et al. evaluated 2622 lesions of 2066 patients with CL in a prospective study conducted between 1998 and 2004 and it was found that 66 (2.5%) of the lesions were located in the periocular area in 59 (2.9%) of the patients (5). In a study conducted in the Southeastern Anatolia Region of Türkiye, where CL is endemic, 1703 CL lesions were found in 987 patients, and 33 (1.93%) of these lesions were observed in the eyelids and periorbital region (7). The authors stated that the frequent movements of the eyelids and eyelashes prevent insects from biting the skin in that area. However, CL lesions on the eyelids may cause local spread due to their fragility (8).

Diagnosis of ocular leishmaniasis may be challenging because it can mimic other conditions such as preseptal/orbital cellulitis and eyelid tumors (such as basal cell carcinoma, squamous cell carcinoma, and keratoacanthoma) (2,3,7-9). On the eyelids, CL is most commonly seen in the lateral canthal region and can be seen in different clinical presentations as chalazion-like lesions, ulcerated nodules, erythematous plaques, or eczema-like, chronic granulomatous blepharitis-like lesions (3,7,8). Another case with eyelid CL and preseptal cellulitis was reported; however, there was only one immobile mass near the medial canthus (9). In our case, the lesions were eczema-like and more extensive.

The most commonly used method for diagnosis in CL is the microscopic examination of tissue smears (obtained as tissue biopsy, needle aspirates, or section-skin smears) stained with Giemsa or Hematoxylin and Eosin dye, where the amastigotes (*Leishman-Donovan* bodies) in macrophages are seen (3). In the literature, cases of CL involving the eyelid in pediatric and adult patients have been reported (1-4,6,8-11). In some of these cases, a diagnosis of CL was obtained as a result of biopsies taken from lesions that did not respond to systemic or topical antibiotic treatments. In our case, the diagnosis of CL was not considered in the first place and diagnosis was made by biopsy since it did not respond to systemic antibiotics and antifungal treatment.

Treatment options include local and topical treatments

(cryotherapy, intralesional injection of pentavalent antimony derivatives, local heat therapy, and various topical paromomycin preparations), and oral or parenteral systemic treatments. Local and topical treatments are the first choice for uncomplicated cutaneous lesions. Systemic treatment is recommended when lesions are multiple, or located in cosmetically and functionally important areas such as the nose, ear, eyelids, fingers and toes or associated with lymphangitis. Furthermore, immunosuppressive patients and persistent lesions after local treatments require systemic therapy. Pentavalent antimonials, including sodium stibogluconate and meglumine antimonate, are the most commonly used systemic agents and the efficacy is generally good (3).

Long-term complications of CL lesions on the eyelids may be ectropion, entropion, ptosis, lagophthalmos, and stenosis in the nasolacrimal duct, secondary infections that cause destruction of the underlying soft and bone tissue by leaving scar tissue, interstitial keratitis, conjunctivitis, episcleritis, scleromalacia, and even blindness with local spread (2,3).

In our case, satisfactory results were obtained after 2 cycles of intralesional glucantime treatment and no recurrence and scar tissue were observed during 4 years of follow-up.

Conclusion

Although CL is a self-limiting disease, untreated lesions can cause permanent ocular complications. In the differential diagnosis of atypical chronic erythematous plaques or ulcerated lesions of the eyelids in areas where the disease is endemic or in a patient from an endemic region, consideration of CL by ophthalmologists may help in early diagnosis and treatment. Due to the potential risks of ocular involvement and complications, early diagnosis and treatment of CL cases on the eyelid are very important.

Disclosures

Informed consent: Written informed consent was obtained from the patient for the publication of the case report and the accompanying images.

Peer-review: Externally peer-reviewed.

Conflict of Interest: None declared.

Authorship Contributions: Concept – N.Y., H.B.; Design – N.Y., H.B.; Supervision – N.Y., H.B.; Resource – N.Y., H.B.; Materials – H.B.; Data collection and/or processing – H.B.; Analysis and/or interpretation – H.B.; Literature search – H.B.; Writing – N.Y., H.B.; Critical review – N.Y., H.B.

References

1. Doroodgar M, Doroodgar MO, Doroodgar A. Eyelid cutaneous leishmaniasis: A case report. *Iran J Public Health* 2017;46:261–4. [CrossRef]
2. Jafari AK, Akhyani M, Valikhani M, Ghodsi ZS, Barikbin B, Toosi S. Bilateral cutaneous leishmaniasis of upper eyelids: A case re-

- port. *Dermatol Online J* 2006;12:20. [\[CrossRef\]](#)
3. Duman R, Duman N, Yavaş GF, Doğan M, Duman R. Lesson of the month 2: Chronic erythematous painless plaque on the eyelid co-presenting with multiple ulcerated nodules on the extremities. *Clin Med (Lond)* 2015;15:304–6. [\[CrossRef\]](#)
 4. Mencía-Gutiérrez E, Gutiérrez-Díaz E, Rodríguez-Peralto JL, Monsalve-Córdova J. Old World eyelid cutaneous leishmaniasis: A case report. *Case Rep Dermatol Online J* 2005;11:29.
 5. Durdu M, Gökçe S, Bagirova M, Yalaz M, Allahverdiyev MA, Uzun S. Periocular involvement in cutaneous leishmaniasis. *J Eur Acad Dermatol Venereol* 2007;21:214–8. [\[CrossRef\]](#)
 6. Ayatollahi J, Ayatollahi A, Shahcheraghi SH. Cutaneous leishmaniasis of the eyelid: A case report. *Case Rep Infect Dis* 2013;2013:214297. [\[CrossRef\]](#)
 7. Satici A, Gurler B, Aslan G, Ozturk I. Ocular involvement in cutaneous leishmaniasis four cases with blepharoconjunctivitis. *Eur J Epidemiol* 2004;19:263–6. [\[CrossRef\]](#)
 8. Sadeghian G, Nilfroushzadeh MA, Moradi SH, Hanjani SH. Ocular leishmaniasis: A case report. *Dermatol Online J* 2005;11:19.
 9. Turkoglu EB, Basol I, Ayaz Y, Dogan ME, Apaydin KC, Unal B. A rare etiology of preseptal cellulitis: Leishmaniasis. *J Fr Ophtalmol* 2020;43:e247–9. [\[CrossRef\]](#)
 10. Oliveira-Neto MP, Martins VJ, Mattos MS, Pirmez C, Brahin LR, Benchimol E. South American cutaneous Leishmaniasis of the eyelids: Report of five cases in Rio de Janeiro State, Brazil. *Ophthalmology* 2000;107:169–72. [\[CrossRef\]](#)
 11. Veraldi S, Bottini S, Currò N, Gianotti R. Leishmaniasis of the eyelid mimicking an infundibular cyst and review of the literature on ocular leishmaniasis. *Int J Infect Dis* 2010;14:e230–2.