



# Comparison of Long-Term Visual and Refractive Results of Transepithelial and Mechanical Photorefractive Keratectomy

Basak Saracoglu Yilmaz,<sup>1</sup> Alper Agca,<sup>2</sup> Muhittin Taskapili<sup>3</sup>

<sup>1</sup>Department of Ophthalmology, University of Health Sciences Gaziosmanpasa Training and Research Hospital, Istanbul, Turkey

<sup>2</sup>Department of Ophthalmology, Dunya Goz Hospital, Istanbul, Turkey

<sup>3</sup>Department of Ophthalmology, University of Health Sciences Beyoglu Eye Training and Research Hospital, Istanbul, Turkey

## Abstract

**Objectives:** The aim of the study was to present and compare 2 years results of mechanical photorefractive keratectomy (M-PRK) and transepithelial photorefractive keratectomy (T-PRK) for myopia.

**Methods:** One hundred and nine eyes of 55 patients were included in this retrospective study. The mean age of the patients was 26.9±5.2 years. Forty-four eyes (40.4%) had M-PRK and 65 eyes (59.6%) had T-PRK. Follow-up time was 2 years. Refractive errors (RE), uncorrected visual acuity (UCVA), and high-order corneal aberrations were compared.

**Results:** The mean RE was -2.33±0.88 D and the mean UCVA was 0.24±0.17 logMAR at baseline for M-PRK patients. At month 24, those measurements were changed to -0.27±0.32 D and 0.99±0.04 logMAR. The mean RE was 2.19±0.73 D and the mean UCVA was 0.23 ± 0.15 logMAR at baseline for T-PRK patients. At month 24, those measurements were changed to -0.14±0.32 D and 0.99±0.01 logMAR. The mean REs significantly decreased and the mean UCVA significantly increased after both type of surgeries (all p<0.001). In M-PRK group, 4 mm zone total corneal aberration and 6 mm total-coma-spherical corneal aberrations were statistically significantly increased in post-operative term. In T-PRK group, only 6 mm total-spherical corneal aberrations were statistically significantly increased in post-operative term. There was no serious complication during surgeries or follow-up time.

**Conclusion:** M-PRK and T-PRK were a safe and effective in the treatment of myopia in 2 years term. Some high-order aberrations may be increase after those treatments.

**Keywords:** High-order corneal aberrations, myopia, photorefractive keratectomy, transepithelial photorefractive keratectomy

## Introduction

Photorefractive keratectomy (PRK) has been commonly been used as an effective and safe refractive surgery technique for many years (1). After the introduction of the laser in situ keratomileusis (LASIK), the use of PRK has been reduced (2). Because LASIK offers more comfortable post-operative term with less pain, less inflammation, and faster visual re-

covery (3). However, PRK is still a good treatment option for patients with thin corneas, basal membrane alterations (4). PRK is also a useful to correct of residual refractive errors (REs) after LASIK (5).

PRK surgery starts with a removing the corneal epithelium (6). Then, stromal laser ablation is performed (6). There are several different methods for epithelial debridement such as mechanical, alcohol debridement, rotating brush, and using

**How to cite this article:** Saracoglu Yilmaz B, Agca A, Taskapili M. Comparison of Long-Term Visual and Refractive Results of Transepithelial and Mechanical Photorefractive Keratectomy. *Beyoglu Eye J* 2022; 7(2): 121-125.

**Address for correspondence:** Basak Saracoglu Yilmaz, MD. Saglik Bilimleri Universitesi Gaziosmanpasa Egitim ve Arastirma Hastanesi, Istanbul, Turkey

**Phone:** +90 531 472 65 74 **E-mail:** saracoglubasak@gmail.com

**Submitted Date:** February 21, 2022 **Accepted Date:** April 24, 2022 **Available Online Date:** May 27, 2022

©Copyright 2022 by Beyoglu Eye Training and Research Hospital - Available online at [www.beyoglu-eye.com](http://www.beyoglu-eye.com)

OPEN ACCESS This work is licensed under a Creative Commons Attribution-NonCommercial-ShareAlike 4.0 International License.



excimer laser (6,7). In transepithelial PRK (T-PRK), excimer laser is used for epithelial removal while in mechanical PRK (M-PRK), blunt spatula is used for the same purpose (8,9).

An increasing high-order aberration (HOA) after excimer laser surgeries is still a problem.[10] HOAs can negatively affect post-operative visual quality with causing a photopic phenomenon such as glare, halos, and/or starbursts (10). Furthermore, PRK has a disadvantage of an early post-operative pain (9,10). A single-step T-PRK has a potential for shortening the operative time and reducing early post-operative pain. Furthermore, the epithelial removal method that least affects HOAs is still a matter of debate.

In this study, we aim to evaluate and compare the long-term (2 years) results of T-PRK and M-PRK.

## Methods

One hundred and nine eyes of 55 consecutive patients who underwent PRK laser surgery in between 2014 and 2017 included in this retrospective study. At baseline, the participants underwent ophthalmologic examinations including; refraction, visual acuity, slit-lamp biomicroscopy, dilated funduscopy, and corneal topography. Inclusion criteria were; having undergone PRK surgery in our hospital for RE (in spherical equivalent)  $-5.00$  D or less and being 18 years old or older. Exclusion criteria were; having any ocular disease or systemic disease, follow-up time  $<24$  months, and having any previous eye surgery. Patients were followed up at month 1, month 3, month 6, month 12, and month 24. Written informed consent was obtained from all patients. The study was approved by the Local Ethics Committee and was performed according to the tenets of the Declaration of Helsinki.

## Surgery

Schwind Amaris 750s device was used in all surgeries. In M-PRK, periorbital skin was cleaned with 10% povidone-iodine. A minute after waiting, sterile drape is applied and attached to the blepharostat. Central 9 mm corneal scraped with a knife. Afterward, it was cleaned with a blunt spatula from the center to the periphery with mechanical corneal debridement. In the final, excimer laser ablation was performed with the standard algorithm of the device. In T-PRK, periorbital skin was cleaned with 10% povidone-iodine. A minute after waiting, sterile drape was applied and attached to the blepharostat. Corneal epithelial removal was performed using the ORK-CAM software of the device with an excimer laser in a 7–9 mm zone. Afterward, corneal ablation was performed with excimer laser.

In both methods, at least 6.5 mm ablation zone was used. After ablation was completed, 0.02% mitomycin-C was placed on the stromal bed for 30 s. Then, mitomycin-C is removed from the medium using 40 mL of balanced salt solution. Finally, a soft bandage contact lens was used until epithelialization was achieved. Antibiotic drops were used

and blepharostat was removed.

Patients were examined daily until epithelialization was achieved. 0.5% moxifloxacin was used (Vigamox, Alcon Co., Inc., Canada) drops 5 times a day. Artificial tear drops were applied 5 times a day. After making sure that the epithelialization was completed, the therapeutic contact lens was removed. After the contact lens removal, 1% preservative-free dexamethasone (Dexasine SEÓ, Alcon Pharma, Freiburg, Germany) drops were added to the treatment. It was started to be used 4 times a day in the 1st week. Then, the drug dose was reduced by one drop per day each week. At the end of 1 month, other medications were completely discontinued, except for artificial tears.

## Data Analysis

All relevant data in the study were presented with mean, standard deviation, and maximum-minimum values. The Kolmogorov–Smirnov test was applied to assess the normal distribution of data. The appropriate test (paired samples t-test, independent-samples t-test, and one-way ANOVA) was used in the analysis. The Statistical Package for the Social Sciences version 22, Chicago, IL, USA, was used for data analysis in which values of  $p < 0.05$  were considered to be statistically significant.

## Results

The mean age was  $26.9 \pm 5.3$  years (range: 19–38). Twenty-five patients (45%) were male and 30 patients (55%) were female. Fifty-four (49.5%) right eyes and 55 (50.5%) left eyes were included in the study. M-PRK was applied to 44 eyes (40.4%) and T-PRK was applied to 65 eyes (59.6%) (Table 1).

The mean RE and visual acuity results of the patients in the pre-operative period and at the post-operative month 24 are given in Table 2. Accordingly, in the final control, a sta-

**Table 1.** Clinical characteristics of the participants

	M-PRK	T-PRK
Refractive error (s.e., D)	$-2.33 \pm 0.88$ (-4.75/-0.50)	$-2.19 \pm 0.73$ (-4.5/-0.75)
UCVA (Snellen, decimal)	$0.24 \pm 0.17$ (0.05/-0.7)	$0.23 \pm 0.15$ (0.05/0.6)
BCVA (Snellen, decimal)	$0.97 \pm 0.07$ (0.7/1.0)	$0.97 \pm 0.07$ (0.7/1.0)
Mean K value	$43.68 \pm 1.71$ (40.66/47.36)	$43.78 \pm 1.44$ (40.86/46.62)

All data are presented as the mean  $\pm$  SD. UCVA: Uncorrected visual acuity; BCVA: Best-corrected visual acuity; s.e.: Spherical equivalent; D: Diopter; M-PRK: Mechanical photorefractive keratectomy; T-PRK: Transepithelial photorefractive keratectomy.

**Table 2.** Comparison of the mean values in groups (pre-operative vs. month 24)

	M-PRK			T-PRK		
	Pre-operative	Post-operative	P	Pre-operative	Post-operative	P
RE (s.e., D)						
Mean	2.33	-0.27	<0.001*	-2.19	-0.14	<0.001*
SD	0.88	0.32		0.73	0.32	
Min.	-4.75	-1.50		-4.50	-1.00	
Max.	-0.50	0.00		-0.75	0.50	
UCVA (Snellen, decimal)						
Mean	0.24	0.99	<0.001*	0.23	0.99	<0.001*
SD	0.17	0.04		0.15	0.01	
Min.	0.05	0.80		0.05	0.90	
Max.	0.70	1.00		0.60	1.00	

UCVA: Uncorrected visual acuity; RE: Refractive error; s.e.: Spherical equivalent; D:diopeter; M-PRK: Mechanical photorefractive keratectomy; T-PRK: Transepithelial photorefractive keratectomy. \*Paired samples t-test.

tistically significant decrease was found in RE compared to the pre-operative period (Table 2). A statistically significant increase was found in UCVA compared to the pre-operative period (Table 2).

The mean RE of patients measured at baseline and at follow-up surgery is given in Figure 1. The mean REs of the patients decreased after surgery at month 1 and this normalization continued throughout the follow-up period (Fig. 1).

In M-PRK group, the mean RE was between  $\pm 0.25$  D in 63.64% of eyes,  $\pm 0.50$  D in 93.18%, and  $\pm 1$  D in 95.45% of eyes at the last visit. In T-PRK group, the mean RE was between  $\pm 0.25$  D in 73.85% of eyes,  $\pm 0.50$  D in 89.23%, and  $\pm 1$  D in 98.46% of eyes at the last visit. The mean UCVA was significantly increased at month 1 after both type of surger-

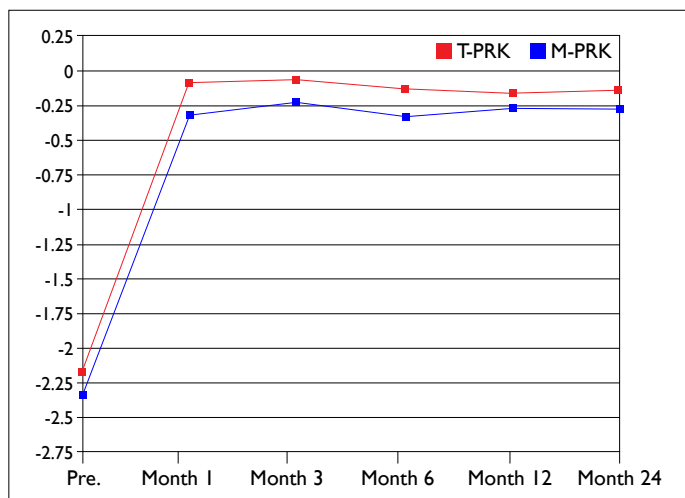
ies and this effect seen in both methods until the last control examination (Fig. 2).

There were some significant changes detected in HOAs in the post-operative period. These changes are given in Table 3.

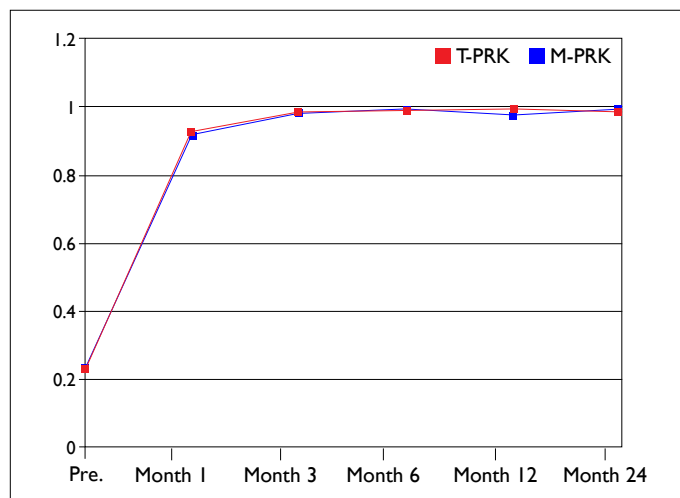
No serious side effects were observed in any of the patients participating in the study. Late-onset corneal haze which was responding to medical treatment was detected in 3 eyes (6.8%) who underwent M-PRK.

### Discussion

There are some publications in the literature reporting the results of the PRK method in the treatment of myopia (11-15) Alio et al. reported the results of PRK in 33 eyes with



**Figure 1.** The mean refractive errors of the participants at the baseline and follow-up.



**Figure 2.** The mean UCVA of the participants at the baseline and follow-up.

**Table 3.** The mean HOAs at baseline and follow-up. (pre-operative vs. month 24)

	M-PRK			T-PRK		
	Pre-operative	Post-operative	P	Pre-operative	Post-operative	P
Total	0.14±0.04	0.17±0.08	0.021	0.14±0.05	0.15±0.05	0.093
4 mm	(0.07–0.23)	(0.08–0.61)		(0.06–0.41)	(0.04–0.31)	
Coma	0.08±0.04	0.09±0.05	0.108	0.07±0.04	0.07±0.04	0.711
4 mm	(0.02–0.18)	(0.01–0.21)		(0.01–0.17)	(0.01–0.22)	
Trefoil	0.07±0.03	0.07±0.05	0.648	0.06±0.05	0.07±0.04	0.164
4 mm	(0.01–0.16)	(0.01–0.21)		(0.01–0.35)	(0.01–0.18)	
Spherical	0.05±0.02	0.06±0.02	0.229	0.05±0.02	0.05±0.03	0.966
4 mm	(0.02–0.10)	(0.01–0.12)		(0.01–0.10)	(0.00–0.13)	
Total	0.45±0.12	0.57±0.16	<0.01	0.42±0.12	0.48±0.14	<0.01
6 mm	(0.24–0.80)	(0.34–1.00)		(0.24–0.78)	(0.24–0.99)	
Coma	0.29±0.12	0.35±0.18	0.029	0.27±0.12	0.25±0.15	0.313
6 mm	(0.07–0.55)	(0.03–0.72)		(0.05–0.58)	(0.00–0.87)	
Trefoil	0.18±0.10	0.18±0.11	0.815	0.15±0.09	0.17±0.10	0.178
6 mm	(0.03–0.50)	(0.01–0.53)		(0.03–0.61)	(0.01–0.46)	
Spherical	0.23±0.08	0.33±0.12	<0.01	0.23±0.06	0.27±0.12	0.003
6 mm	(0.06–0.50)	(0.06–0.61)		(0.13–0.38)	(0.04–0.57)	

All data are presented as the mean and min.–max. M-PRK: Mechanical photorefractive keratectomy; T-PRK: Transepithelial photorefractive keratectomy.

REs up to  $-10.00$  D myopia (11). At the end of the 15 years, 54% of the eyes had a RE of  $\pm 1.00$  D spherical equivalent and 84% had a  $\pm 2.00$  D spherical equivalent remained between the equivalent values. [11] Guerin et al. presented PRK results of 39 eye which has myopia up to  $-7.00$  D. In post-operative term, 79% of the eyes had RE  $\pm 1.00$  D spherical equivalent and 95% of it  $\pm 2.00$  D spherical equivalent (12). Moon reported 4-year results PRK in patients with moderate and low myopia (13). They reported that the mean RE was  $-0.29 \pm 0.51$  D, and the mean UCVA was reported to be 1.0 in 89% of eyes (13). Hashemi et al. reported the results of PRK in 5 years. The mean RE was  $-3.40 \pm 1.73$  D at baseline and it changed to  $-0.08 \pm 0.40$  D postoperatively (14). The mean UCVA was changed from  $0.02 \pm 0.07$  logMAR to  $0.00 \pm 0.04$  logMAR (14). Epstein et al. reported PRK results of 495 eyes with RE between  $-1.25$  and  $-7.50$  D. They reported that 91% of eyes have UCVA of 0.5 and above, 81% of them remained at 0.7 and above (15). Post-operative RE was in  $\pm 1.00$  D in 87% eyes and  $\pm 0.50$  D in 71% eyes (15). In our study, we have found similar good results. In our study, the refractive and visual results are in line with the literature publications presented. In M-PRK group, the mean RE was  $-2.33 \pm 0.88$  D in pre-operative and decreased to  $-0.27 \pm 0.32$  D at last post-operative visit. Similarly, in T-PRK group, the mean RE was  $-2.19 \pm 0.73$  D in pre-operative and decreased

to  $-0.14 \pm 0.32$  D at last post-operative visit. Both methods were found to be successful at the end of the 2-year follow-up period, similar to the literature. The mean UCVA changed to  $0.99 \pm 0.04$  from  $0.24 \pm 0.17$  at baseline in M-PRK group, and it changed to  $0.99 \pm 0.01$  from  $0.23 \pm 0.15$  at baseline in T-PRK group.

Naderi et al. study compared the results of M-PRK and T-PRK and reported that T-PRK had is a superior method (16). In their study, they worked on 340 eyes of 170 patients. In T-PRK group 6 months after surgery, the mean spherical RE was  $-0.09 \pm 0.2$  D and the mean cylindrical RE was  $-0.09 \pm 0.2$  D. In the M-PRK group, the same values were found as  $-0.05 \pm 0.01$  D and  $-0.01 \pm 0.08$  D. They reported that the mean RE values seen in the T-PRK group were found to be statistically significantly lower both spherically and astigmatismatically (16). Oppositely, in our study, we found that two PRK methods were equally successful in terms of RE remaining.

Lee et al. evaluated the change in HOAs after T-PRK in their study (17). They reported that the mean spherical HOA was pre-operative  $0.29 \pm 0.08$  and post-operative, it increased to  $0.51 \pm 0.20$ . The coma HOA reported  $0.28 \pm 0.14$  pre-operative and changed to  $0.27 \pm 0.14$  after surgery (17). Similarly, in our study, there were changes in HOAs after both type of PRK operations. In M-PRK group, there was an increase in total HOAs at 4 mm zone and there was an in-

crease in total, coma, and spherical HOAs at 6 mm zone after surgery. In T-PRK group, there was no significant increase in HOAs at 4 mm zone but there was an increase in total and spherical HOAs in 6 mm zone after surgery. Accordingly, it may be thought that the T-PRK method is slightly more advantageous than the M-PRK method in terms of HOAs.

The main study limitations were the limited sample size and retrospective design of the study. However, this study presented the comparative results of two PRK surgery types which are still commonly used recently. In addition, study compares the HOAs results between two groups.

## Conclusion

This study showed that both M-PRK and T-PRK methods were safe and effective treatments option for patients with moderate myopia. T-PRK method may be superior to M-PRK in terms of HOAs. Further comparative studies, with higher case numbers and longer follow-up times, are needed to confirm this.

## Disclosures

**Ethics Committee Approval:** The study was approved by the Local Ethics Committee and was performed according to the tenets of the Declaration of Helsinki.

**Peer-review:** Externally peer-reviewed.

**Conflict of Interest:** None declared.

**Authorship Contributions:** Concept – B.S.Y.; Design – B.S.Y.; Supervision – M.T., A.A.; Materials – B.S.Y., A.A.; Data collection and/or processing – B.S.Y.; Analysis and/or interpretation – B.S.Y.; Literature search – B.S.Y.; Writing – B.S.Y.; Critical review – A.A., M.T.

## References

1. Ang EK, Couper T, Dirani M, Vajpayee RB, Baird PN. Outcomes of laser refractive surgery for myopia. *J Cataract Refract Surg* 2009;35:921–33. [\[CrossRef\]](#)
2. Tomás-Juan J, Murueta-Goyena Larrañaga A, Hanneken L. Corneal regeneration after photorefractive keratectomy: A review. *J Optom* 2015;8:149–69. [\[CrossRef\]](#)
3. Ambrósio R Jr., Wilson S. LASIK vs LASEK vs PRK: Advantages and indications. *Semin Ophthalmol* 2003;18:2–10. [\[CrossRef\]](#)
4. Gamaly TO, El Danasoury A, El Maghraby A. A prospective, randomized, contralateral eye comparison of epithelial laser in situ keratomileusis and photorefractive keratectomy in eyes prone to haze. *J Refract Surg*. 2007;23 Suppl 9:S1015–20. [\[CrossRef\]](#)
5. Srinivasan S, Drake A, Herzig S. Photorefractive keratectomy with 0.02% mitomycin C for treatment of residual refractive errors after LASIK. *J Refract Surg* 2008;24:S64–7. [\[CrossRef\]](#)
6. Zarei-Ghanavati S, Shandiz JH, Abrishami M, Karimpour M. Comparison of mechanical debridement and trans-epithelial myopic photorefractive keratectomy: A contralateral eye study. *J Curr Ophthalmol* 2019;31:135–41. [\[CrossRef\]](#)
7. Özüken K, İlhan Ç. Comparison of higher-order aberrations after single-step transepithelial and conventional alcohol-assisted photorefractive keratectomy. *Turk J Ophthalmol* 2020;50:127–32. [\[CrossRef\]](#)
8. Yildirim Y, Olcucu O, Alagoz N, Agca A, Karakucuk Y, Demirok A. Comparison of visual and refractive results after transepithelial and mechanical photorefractive keratectomy in myopia. *Int Ophthalmol* 2018;38:627–33. [\[CrossRef\]](#)
9. Shapira Y, Mimouni M, Levartovsky S, Varssano D, Sela T, Munzer G, et al. Comparison of three epithelial removal techniques in PRK: mechanical, alcohol-assisted, and transepithelial laser. *J Refract Surg* 2015;31:760–6. [\[CrossRef\]](#)
10. Jun I, Kang DS, Arba-Mosquera S, Choi JY, Lee HK, Kim EK, Seo KY, et al. Comparison between Wavefront-optimized and corneal Wavefront-guided Transepithelial photorefractive keratectomy in moderate to high astigmatism. *BMC Ophthalmol*;18:154. [\[CrossRef\]](#)
11. Alio JL, Soria FA, Abbouda A, Garcila PP. Fifteen years follow-up of photorefractive keratectomy up to 10 D of myopia: Outcomes and analysis of the refractive regression. *Br J Ophthalmol* 2015;100:626–32. [\[CrossRef\]](#)
12. Guerin MB, Darcy F, O'Connor J, O'Keeffe M. Excimer laser photorefractive keratectomy for low to moderate myopia using a 5.0 mm treatment zone and no transitional zone: 16-year follow-up. *J Cataract Refract Surg* 2012;38:1246–50. [\[CrossRef\]](#)
13. Moon CH. Four-year visual outcomes after photorefractive keratectomy in pilots with low-moderate myopia. *Br J Ophthalmol* 2015;100:253–7. [\[CrossRef\]](#)
14. Hashemi M, Amiri MA, Tabatabaee M, Ayatollahi A. The results of photorefractive keratectomy with Mitomycin-C in myopia correction after Five Years. *Pak J Med Sci* 2016;32:225–8. [\[CrossRef\]](#)
15. Epstein D, Fagerholm P, Hamberg-Nyström H, Tengroth B. Twenty-four-month follow-up of excimer laser photorefractive keratectomy for myopia. Refractive and visual acuity results. *Ophthalmology* 1994;101:1558–63. [\[CrossRef\]](#)
16. Naderi M, Jadidi K, Mosavi SA, Daneshi SA. Transepithelial photorefractive keratectomy for low to moderate myopia in comparison with conventional photorefractive keratectomy. *J Ophthalmic Vis Res* 2016;11:358–62. [\[CrossRef\]](#)
17. Lee H, Kang DS, Reinstein DZ, Arba-Mosquera S, Kim EK, Seo KY, et al. Comparing corneal higher-order aberrations in corneal wavefront-guided transepithelial photorefractive keratectomy versus small-incision lenticule extraction. *J Cataract Refract Surg* 2018;44:725–33. [\[CrossRef\]](#)