



Hazardous Effects of Electrocautery on Penile Arteries: An Experimental Study

Elektrokoterin Penil Arterler Üzerindeki Zararlı Etkisi: Deneysel Çalışma

© Binali Fırıncı¹, © Remzi Arslan², © Özgür Çağlar³, © Ali Ahiskaloğlu⁴, © Mehmet Dumlu Aydın⁵

¹Atatürk University Faculty of Medicine, Department of Pediatric Surgery, Erzurum, Turkey

²Atatürk University Faculty of Medicine, Department of Pathology, Erzurum, Turkey

³Ankara Etlük City Hospital, Clinic of Pediatric Surgery, Ankara, Turkey

⁴Atatürk University Faculty of Medicine, Department of Anesthesiology and Reanimation, Erzurum, Turkey

⁵Atatürk University Faculty of Medicine, Department of Neurosurgery, Erzurum, Turkey

ABSTRACT

Objective: Urethral arteries may be affected during electrocauterization. The present study aims to investigate whether urethral artery spasm induced by electrocauterization during penile surgery causes pudendal nerve injury.

Method: Eighteen male New Zealand rabbits were allocated into control (G-I, n=5), penile surgery without electrocauterization (SHAM group, G-II, n=6) and monopolar cauterization under general anesthesia (study group, G-III, n=9) groups. The animals were followed up for three weeks and then sacrificed. Vasospasm index values (VSI: wall ring surface value/lumen surface value) of urethral arteries and degenerated neuron densities (DNDs) of pudendal nerve dorsal root ganglia at sacral-3 level (S3) were examined using stereological methods. Results were compared using the one-way ANOVA test.

Results: Neuronal angulation, cytoplasmic condensation, nuclear shrinkage, and condensed nuclei were detected in the pudendal nerve ganglia. The mean VSI values of urethral arteries and DNDs of pudendal ganglia (n/mm³) were estimated as 1.012±0.024 vs. 4±1 in G-I; 1.082±0.323 vs. 28±7 in G-II and 2.54±0.0621 vs. 137±14 in G-III, respectively. Statistical significance values (p-values) in terms of VSI, and DND for the differences between G-I and G-II (p<0.01 vs. p<0.005), G-II and G-III (p<0.001 vs. p<0.0001)- and G-I and G-III (p<0.0001 vs. p<0.0001) were as indicated.

Conclusion: Electrocautery during penile surgery should not be used because of retrograde degeneration of the pudendal nerve and ganglia secondary to the injury to urethral taste bud-like structures.

Keywords: Urethral arteries, pudendal ganglia, electrocautery

ÖZ

Amaç: Üretral arterler elektrokoter kullanımından etkilenebilir. Bu çalışma penis cerrahisi sırasında elektrokoter ile pudendal sinir hasarının üretral arter spazmı olup olmadığını araştırmayı amaçlamaktadır.

Yöntem: On sekiz erkek Yeni Zelanda tavşanı incelendi: beşi kontrol (G-I, n=5), beşi elektrokotersiz penil cerrahi (SHAM grubu, G-II, n=6) ve dokuzu genel anestezi altında monopolar koter ile opere edilen grup (çalışma grubu, G-III, n=9). Hayvanlar üç hafta boyunca izlendi ve sonrasında sakrifiye edildi. Üretral arterlerin vazospazm indeks değerleri (VSI: Wall ring yüzey değeri/lümen yüzey değeri) ve sakral-3 seviyesindeki (S3) pudendal sinir dorsal kök ganglionlarının dejenerasyonunu nöron yoğunlukları (DND) stereolojik yöntemlerle incelendi. Sonuçlar one-way ANOVA testi kullanılarak karşılaştırıldı.

Bulgular: Pudendal sinir ganglionlarında nöronal açılanma, sitoplazmik yoğunlaşma, nükleer büzülme ve yoğunlaşmış çekirdekler saptandı. Üretral arterlerin ortalama VSI değerleri ve pudendal ganglionların dejenerasyonunu nöron yoğunlukları (n/mm³) G-I'de 1,012±0,024/4±1; G-II'de 1,082±0,323/28±7 ve 2,54±0,0621/137±14 olarak hesaplandı. G-III. VSI için istatistiksel değerler: (p<0,01)-G-I/G-II; (p<0,001)-G-II/G-III ve (p<0,0001)-G-I/G-III; ve DND için ise (p<0,005)-G-I/G-II; (p<0,005)-G-II/G-III ve (p<0,0001)-G-I/G-III olarak bulundu.

Sonuç: Tat tomurcuğuna benzer yapıların yaralanmasına sekonder pudendal sinir ve ganglionların retrograd dejenerasyonu nedeniyle penis cerrahisi sırasında elektrokoter kullanılmamalıdır.

Anahtar kelimeler: Üretral arterler, pudendal ganglia, elektrokoter

Received: 04.07.2023

Accepted: 21.09.2023

Corresponding Author

Binali Fırıncı,
Atatürk University Faculty of
Medicine, Department of Pediatric
Surgery, Erzurum, Turkey
✉ bfrnc@hotmail.com
ORCID: 0000-0002-0852-2458

Cite as: Fırıncı B, Arslan R, Çağlar Ö,
Ahiskaloğlu A, Aydın MD. Hazardous
Effects of Electrocautery on Penile
Arteries: An Experimental Study.
J Behcet Uz Child Hosp 2023;13(3):192-197



INTRODUCTION

Various somatosensitive, parasympathetic, and sympathetic nerves are responsible for the control of penile tissues. Penile tissue is mainly innervated by parasympathetic nerves that come from the Onuf's nucleus located in the parasympathetic region of the spinal cord, sympathetic nerves arise from the sympathetic region of the spinal cord from L1-L2 and fibers of somatosensitive neurons stem from the dorsal root ganglia (DRG) L6-S1⁽¹⁾. Healthy sexual functioning in human beings requires an intact spinal cord⁽²⁾, sacral parasympathetic and thoracolumbar sympathetic networks together with taste bud-like structures innervated by them⁽³⁾.

Since normal functioning of above-mentioned anatomical structures also requires an intact interaction between pudendal network, Onuf's nucleus⁽⁴⁾ and vascular supply, an electrocautery knife should be used with a lower voltage current or it should not be used unless absolutely necessary⁽⁵⁾. If orgasmic pleasures are regulated by taste bud-like structures in penile tissues and the pudendal nerve network, urethral artery spasm induced penile injuries may also be responsible for sexual dysfunctions and sexual anhedonia. This paper emphasizes the concerns about using electrosurgical devices such as monopolar electrocautery in penile surgeries.

MATERIALS and METHODS

Our study was initiated with the approval of the Atatürk University Animal Experiments Local Ethics Committee (decision no: 177, date: 17.09.2018). We preferred the rabbit model for our experiment. Five of 18 male New Zealand rabbits were allocated into control (G-I,) group. Penile incision was performed without using electrocautery in five rabbits (SHAM group, G-II) while monopolar cautery was used under general anesthesia in eight rabbits (study group, G-III).

The rabbit's penises were sterilized using a povidone-iodine solution. Within the SHAM group, solely an anteroposterior midline incision was performed, and hemostasis was accomplished without the utilization of cautery. A urethral catheter was introduced into the rabbits' urethra. The procedure in the SHAM group was conducted without employing electrocautery, whereas cautery was utilized in the research group. In accordance with the study conducted by some authors, a 15-W energy level was chosen for cautery. This energy level was administered for a duration of 5

seconds on an approximate region of 2 mm on both the ventral and dorsal sides of the apex of the penile shaft⁽⁶⁾. The cauterization was performed following the incision made on the penis. Subsequently, the surgical cut was sealed using uninterrupted stitches made of Vicryl (7/0) threads. Antibiotics and analgesics were administered during the postoperative phase. The animals were housed in cages under typical laboratory room conditions for a duration of three weeks following operation. The animals were sedated by administering a combination of ketamine hydrochloride (25 mg/kg), lidocaine hydrochloride (15 mg/kg), and acepromazine (1 mg/kg) through a subcutaneous injection. The circumcision procedure involved the use of surgical scissors and monopolar cautery (20W/400 kHz/Petas-Petkot 600) after sterilizing the operative area with local antiseptics. Following the administration of general anesthesia, all animals were euthanized. The pudendal nerves were revealed by dissecting between the gluteus maximus and medius muscles.

Subsequently, a laminectomy was performed on the S1-S3 vertebrae to extract the spinal cord at the S2 level and the pudendal ganglia. In addition, the edges of the cut ventral urethra were carefully separated from the surrounding tissue and removed together with its associated nerve and blood vessel structures. Following fixation in a 10% formalin solution for one week, all collected tissues were subsequently embedded in paraffin blocks. The blocks were sliced into slices measuring five micrometers and then treated with hematoxylin and eosin stain. The preparations were observed using a microscope at magnifications of 4x and 40x. The density of neurons in pudendal ganglia and taste bud-like structures was estimated using the stereological method outlined in the work by Caglar et al.⁽⁴⁾, together with the taste bud-like structures estimation method employed in our most recent investigation.

Statistical Analysis

Statistical analysis was performed using one-way ANOVA test in SPSS 20.0 for Windows ($p < 0.005$).

Statistical significance values (p -values) in terms of vasospasm index values (VSI), and DND for the differences between Gi and GII ($p < 0.01$ vs. $p < 0.005$), GII and GIII ($p < 0.001$ vs. $p < 0.0001$)- and GI and GIII ($p < 0.0001$ vs. $p < 0.0001$) were as indicated.

RESULTS

All DNDs of pudendal nerves of S3 were evaluated by stereologic analysis. The control and SHAM groups

shows urethral and penile arteries with normal and nearly normal endothelium and smooth muscle cells (Figure 1 and 2, respectively). Severe vasospasm of urethral arteries, axonal degeneration in the pudendal nerve roots, and neuronal degeneration and apoptosis in the S2 DRG were observed in the electrocautery group (Figure 3-5). Electrocautery might adversely affect urethral and pudendal nerves with resultant damage to centers related to sexual function. Pudendal nerve injury induced by an electrocautery knife may accompany urethral artery spasm following penile surgery (Figure 6). The degree of DND and VSI values were analyzed. Histopathological examinations were performed by a pathologist (R.A.) blinded to the allocated study groups using a light microscope.

Neuronal angulation, cytoplasmic condensation, nuclear shrinkage, and condensed nuclei were detected in the pudendal nerve ganglia. The mean VSI values of urethral arteries and degenerated neuron densities of pudendal ganglia (n/mm^3) were estimated as 1.012 ± 0.024 and 4 ± 1 in GI; 1.082 ± 0.323 and 28 ± 7 in GII and 2.54 ± 0.0621 and 137 ± 14 in GIII, respectively.

DISCUSSION

Pelvic visceral tissues innervated by pelvic plexus which is composed of somatosensitive and autonomic networks. Penile tissues innervated by neural web which contains parasympathetic fibers originated from Onuf's nucleus and sympathetic nerves arising from L1-L2

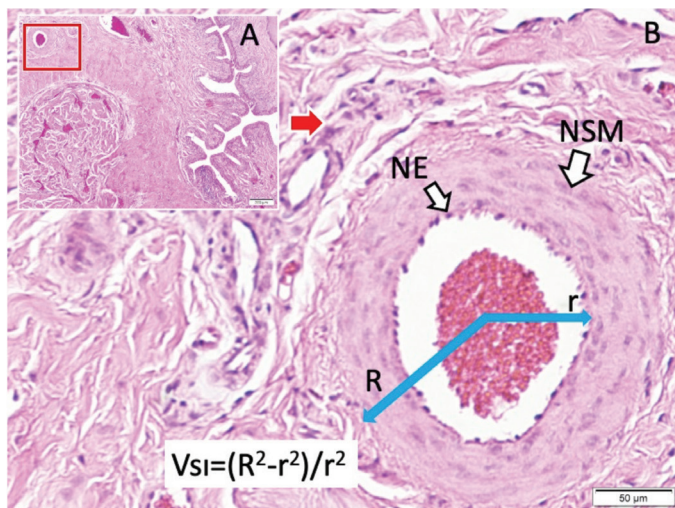


Figure 1. Urethral and penile arteries with normal endothelium (NE) and normal smooth muscle cells (NMC) of an intact rabbit penis seen under low (LM, H&E, x4/A) and higher magnification (LM, H&E, 10/B) and display of VSI estimation formula

levels of the spinal cord and travel with pelvic nerves somatosensitive neurons coming from DRG L6-S1⁽¹⁾.

Intact spinal cord, sacral parasympathetic and thoracolumbar sympathetic networks are required for the maintenance of normal sexual function^(2,3). Sympathetic nerves cause vasospasm and

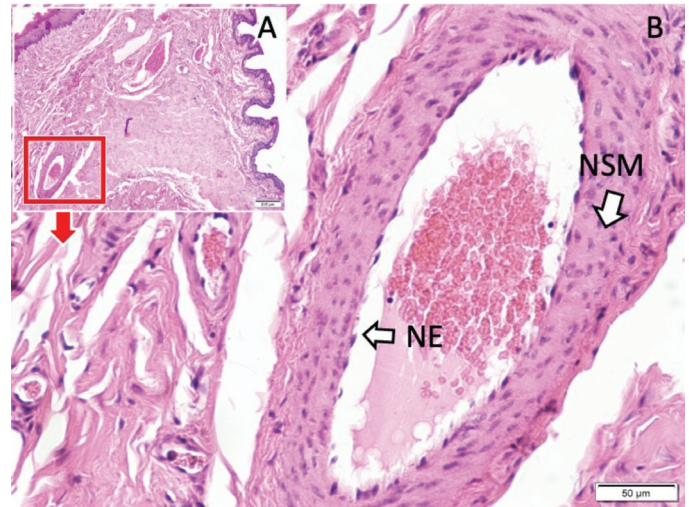


Figure 2. Urethral and penile arteries with nearly normal endothelium (NE) and normal smooth muscle cells (NMC) in a simple circumcision applied rabbit penis seen under low (LM, H&E, x4/A) and higher magnification (LM, H&E, 10/B)

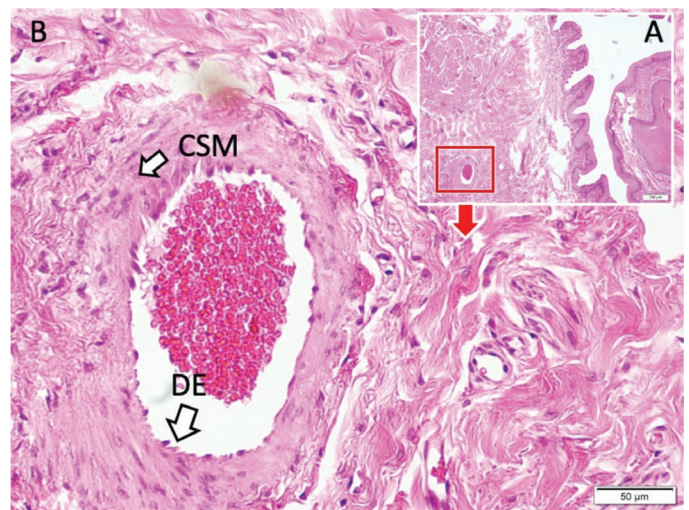


Figure 3. Urethral and penile arteries with minimally degenerated endothelium (DE) and contracted smooth muscle cells (CMC) seen in MEC electrocautery blade applied in rabbit penile tissue (images seen under low (LM, H&E, x4/A) and higher magnification (LM, H&E, 10/B)

parasympathetic nerves dilation of penile arteries⁽¹⁾. We think that electrocautery may be more hazardous for parasympathetic than sympathetic nerves, because parasympathetic fibers are more densely populated in penile tissue⁽¹⁾.

As orgasmic pleasure is modulated by taste bud-like structures and pudendal nerves, the disruption of that network following penile surgery may cause sexual dissatisfaction and also infertility⁽⁴⁾. In the circumcision procedure, a ritual which has been used for centuries, currently applied monopolar electrocautery may damage very delicate penile tissues. Indeed electrocauterization induces development of neural/extraneural injuries with its thermal or electricity effects⁽⁷⁾. These hazardous effects can cause neuroma formation, vascular injury, degeneration of DRG and phimosis⁽⁸⁾.

Neuronal degeneration criteria such as neuronal shrinkage, angulation of cells, cytoplasmic condensation and cytoplasmic halo formation were more prominent in the electrocautery group than in the non-electrocautery group. Therefore, electrocautery used during spine surgery may be injurious to spinal ganglia and should be used with a lower voltage current⁽⁹⁾. The animals that underwent facet denervation exhibited vascular wall injury, endothelial necrosis, muscle lesions, and thrombus development in the spinal radicular arteries. Facet denervation by monopolar electrocautery can

lead to arterial lesions and the formation of blood clots in the radicular arteries. Therefore, it should only be used when absolutely necessary⁽⁵⁾. Electrocautery-related mechanism of electrical injury can cause neuroma⁽⁸⁾ and scar formation⁽¹⁰⁾. Since electrocauterization causes neurodegeneration⁽⁹⁾, endothelial-muscular insults and formation of thrombi in the radicular arteries it should not be used unless absolutely necessary⁽⁵⁾.

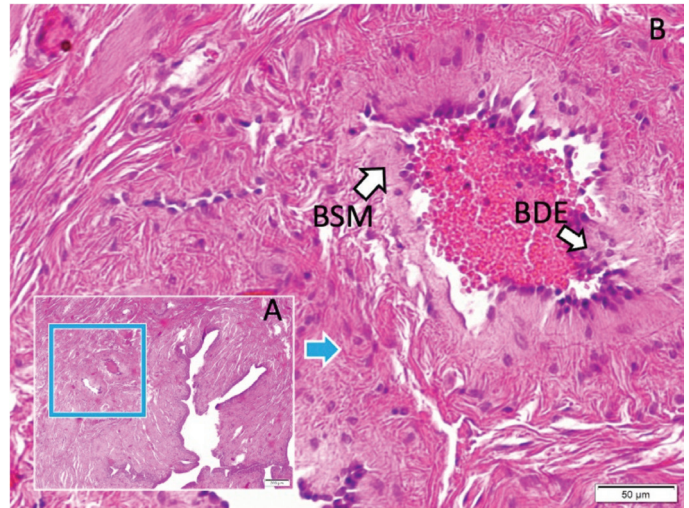


Figure 5. Urethral and penile arteries with moderately boiled/ degenerated endothelium (DE) and boiled/contracted/degenerated smooth muscle cells (BMC) seen in thermocoagulation applied rabbit penile tissue [images seen under low (LM, H&E, x4/A) and higher magnification (LM, H&E, 10/B)]

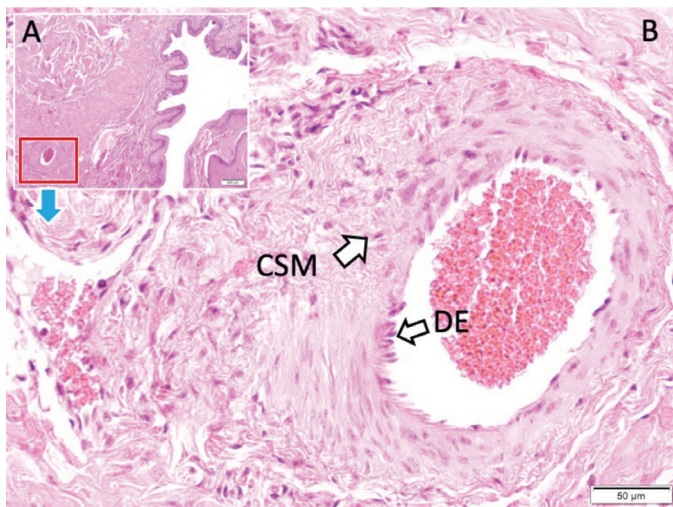


Figure 4. Urethral and penile arteries with severely degenerated/desquamated endothelium (DE) and prominently contracted smooth muscle cells (CMC) seen in MEC electrocautery blade applied rabbit penile tissue [images seen under low (LM, H&E, x4/A) and higher magnification (LM, H&E, 10/B)]

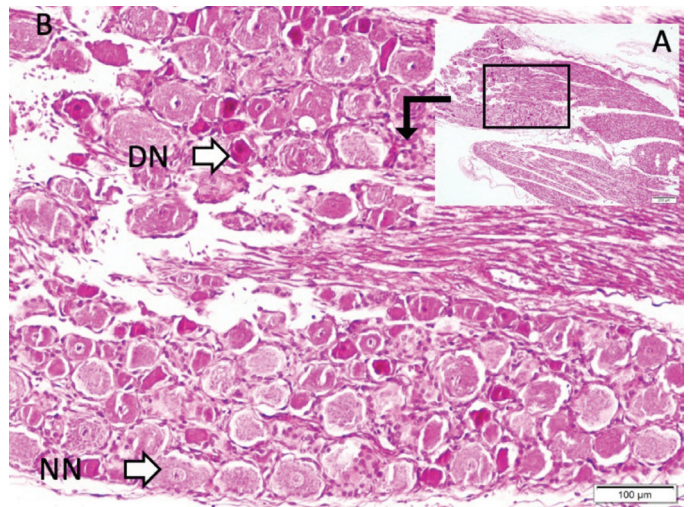


Figure 6. Histopathological view of pudendal dorsal root ganglia (DRG) with normal (NN) and degenerated neurons (DN) seen under lower and higher magnification (LM, H&E, x4/A; x10/B) in an animal study

Since electrocauterization can transmit electric current to neurovascular tissues, target tissue damage occurs because electric energy is converted to thermal energy or heat⁽⁷⁾. The damage that occurs depends on the tissue resistance, sensitivity and type of the tissue, as well as the duration, targeted direction, type, intensity and strength of the electric current⁽⁸⁾.

In the present study; angulation of cells, cytoplasmic condensation, neuronal shrinkage and cytoplasmic halo formation accepted as cellular degeneration criteria were more prominent in the electrocautery group than in the non-electrocautery group. We recommend that electrocautery should be used with lower voltage current⁽⁹⁾. For example, Aydin et al.⁽⁵⁾ have shown that application of high voltage electrocautery causes vascular injury and thrombus formation in the radicular arteries. Our study has also shown that application of electrocautery during penile surgery can be hazardous for penile arteries and pudendal nerve networks which has not been mentioned so far. Surgical circumcision is a common procedure frequently performed, and the related complications that develop can cause irreversible problems. It should be noted that the first of these complications is the damage due to the use of electric current, because electrocauterization and surgical cutting are widely used during circumcision.

This study shows that electrocautery used during surgery of apex of penis leads to degeneration of urethral arteries and pudendal nerve ganglia. Although we did not discuss it in this article, we have determined by the analysis of testicular tissues that this procedure may also have negative effects on spermatogenesis.

Study Limitations

This type of study should be performed in the future again using more advanced techniques, methods, and adequate number of experimental animal subjects. Besides, this study does not represent the human model. If a researcher opts to use small number of experimental animals for the conduction of this type of experiment, misleading conclusions may be drawn.

CONCLUSION

We would like to emphasize that either low-voltage or bipolar cautery should be used or preferably not applied in penile surgery, since the use of electrocautery causes damage to Onuf's nucleus-pudendal nerve-orgasmic sensation-sensing taste bud network and urethral arteries.

It is now certain that the amputation of the naturally occurring preputium causes medical problems. We anticipate that this harmful application will cause significant legal problems in the future.

Acknowledgement

The authors gratefully acknowledge the financial support by Atatürk University BAP Project grant number 2019/7014.

Ethics

Ethics Committee Approval: Our study was initiated with the approval of the Atatürk University Animal Experiments Local Ethics Committee (decision no: 177, date: 17.09.2018).

Informed Consent: Informed consent is not required.

Peer-review: Externally and internally peer reviewed.

Author Contributions

Surgical and Medical Practices: B.F., Concept: M.D.A., Design: Ö.Ç., Data Collection or Processing: A.A., Analysis or Interpretation: R.A., Literature Search: R.A., Writing: B.F.

Conflict of Interest: The authors have no conflict of interest to declare.

Financial Disclosure: This study was supported by Atatürk University BAP Project grant number 2019/7014.

REFERENCES

1. Dail WG, Trujillo D, de la Rosa D, Walton G. Autonomic innervation of reproductive organs: analysis of the neurons whose axons project in the main penile nerve in the pelvic plexus of the rat. *Anat Rec*. 1989;224(1):94-101. doi: 10.1002/ar.1092240112
2. Akca N, Ozdemir B, Kanat A, Batcik OE, Yazar U, Zorba OU. Describing a new syndrome in L5-S1 disc herniation: Sexual and sphincter dysfunction without pain and muscle weakness. *J Craniovertebr Junction Spine*. 2014;5(4):146-50. doi: 10.4103/0974-8237.147076
3. Aydin MD, Aydin N, Dane Ş, Gündoğdu C, Gürsan N, Akçay F, et al. Taste bud-like structures in penile tissues and a predictive neural mechanism of male orgasm: a preliminary hypothesis based on histological evidence. *Neurol Psychiatry Brain Res*. 2014;20(3):55-62. doi: 10.1016/j.npbr.2014.06.003
4. Çağlar O, Aydin MD, Aydin N, Ahiskalioglu A, Kanat A, Aslan R, et al. Important interaction between urethral taste bud-like structures and Onuf's nucleus following spinal subarachnoid hemorrhage: A hypothesis for the mechanism of dysorgasmia. *Rev Int Androl*. 2022;20(1):1-10. doi: 10.1016/j.androl.2020.05.011
5. Aydin MD, Yildirim OS, Gundogdu C, Onder A, Okur A. Thrombogenic effect of facet denervation using in disc surgery on spinal radicular arteries: an experimental study. *Minim Invasive Neurosurg*. 2006;49(6):328-30. doi: 10.1055/s-2006-954825

6. Günal YD, Boybeyi Ö, Atasoy P, Kısa U, Aslan MK, Bakar B, et al. Oxidative and histopathological effects of the application of electro-surgical devices to the penile tissue of rats. *J Pediatr Urol.* 2020;16(1):39. doi: 10.1016/j.jpuro.2019.10.005
7. Hunt JL, Mason AD Jr, Masterson TS, Pruitt BA Jr. The pathophysiology of acute electric injuries. *J Trauma.* 1976;16(5):335-40. doi: 10.1097/00005373-197605000-00001
8. Koshima I, Moriguchi T, Soeda S, Murashita T. High-voltage electrical injury: electron microscopic findings of injured vessel, nerve, and muscle. *Ann Plast Surg.* 1991;26(6):587-91. doi: 10.1097/00000637-199106000-00017
9. Aydın MD, Dane S, Gundogdu C, Gursan N. Neurodegenerative effects of monopolar electrocauterization on spinal ganglia in lumbar disc surgery. *Acta Neurochir (Wien).* 2004;146(10):1125-9. doi: 10.1007/s00701-004-0300-x
10. Çağlar O, Arslan R, Firinci B, Aydın ME, Karadeniz E, Nalci KA, et al. Comparing the effects of current circumcision techniques on dorsal root ganglia: an experimental study. *Ann Pediatr Surg.* 2021;17(1):1-9. doi: 10.1186/s43159-021-00077-9