



# Evaluation of Cases with Pediatric Hydatid Cyst: A 20-years Experience from Turkey

## Pediatric Kist Hidatik Olgularının Değerlendirilmesi: Türkiye'den 20 Yıllık Deneyim

İ Şenay Erdoğan Durmuş<sup>1</sup>, İ Cansu Türker<sup>2</sup>, İ Nuray Kepil<sup>2</sup>, İ Şenol Emre<sup>3</sup>

<sup>1</sup>University of Health Sciences Turkey, Basakşehir Çam and Sakura City Hospital, Department of Pathology, İstanbul, Turkey

<sup>2</sup>İstanbul University-Cerrahpaşa, Cerrahpaşa Faculty of Medicine, Department of Pathology, İstanbul, Turkey

<sup>3</sup>İstanbul University-Cerrahpaşa, Cerrahpaşa Faculty of Medicine, Department of Pediatric Surgery, İstanbul, Turkey

### ABSTRACT

**Objective:** The aim of the study is to evaluate the demographic features, localizations and pathological features of pediatric cases with hydatid cyst (HC).

**Method:** We analyzed retrospectively 79 patients that histopathologically diagnosed as HCs between 2000 and 2020. Data such as patients' characteristics, site of lesions were collected from pathology reports.

**Results:** Patient's mean age was 11.24±4.42 (age range: 2-18 years). Most (51.9%) of the patients (n=41) were female and 48.1% of the patients (n=38) were male. The patients were distributed in the age groups of <6 (n=9) 6-11 (n=29), and >11 (n=29) years, as indicated. There was a male predominance in >11 years group while female predominance was seen in other age groups. HCs were most frequently localized in the liver (54.4%, n=43), and then in the lungs (31.6%, n=25). The other localization sites of HCs were spleen, cerebrum, kidney, orbit, abdomen, bone, and submandibular area. Hepatic HCs were seen mostly in female (25/43; 54.0%), and pulmonary HCs in male (13/25; 52%) patients. Histopathologically all cases shared the same typical microscopic features of HC.

**Conclusion:** The incidence rate of HCs in pediatric age group was increased by age. It is more common in older children (>11 years). Hepatic HCs were more common in female patients. Pulmonary HCs were more frequently seen in male patients. HCs can be seen in atypical localizations in pediatric age which should always be considered in the differential diagnosis of cystic lesions.

**Keywords:** Hydatid cyst, echinococcosis, pediatric age, *Echinococcus granulosus*

### ÖZ

**Amaç:** Pediatrik kist hidatik (KH) olgularının demografik özelliklerini, lokalizasyonlarını ve patolojik özelliklerini değerlendirmek amaçlanmıştır.

**Yöntem:** 2000-2020 yılları arasında histopatolojik olarak KH tanısı alan 79 hasta retrospektif olarak incelendi. Hasta özellikleri, lezyon lokalizasyonları gibi veriler patoloji raporlarından elde edildi.

**Bulgular:** Hastanın ortalama yaşı 11,24±4,42 (yaş aralığı: 2-18 yıl) idi. Hastaların %51,9'u (n=41) kadın ve hastaların %48,1'i (n=38) erkekti. <6 yaş grubunda 9, 6-11 yaş grubunda 29, >11 yaş grubunda 41 hasta vardı. >11 yaş grubunda erkek, diğerlerinde kadın baskınlığı görüldü. En sık yerleşim yeri karaciğer (%54,4, n=43) iken, bunu akciğer (%31,6, n=25) izlemektedir. Diğer bölgeler dalak, beyin, böbrek, orbita, abdomen, kemik, submandibular bölgeydi. Kırk üç karaciğer yerleşimli kistin 25'i (%54,0) kadın hastalarda, akciğer yerleşimli 25 KH'nın 13'ü (%52) erkek hastalarda görüldü. Histopatolojik olarak tüm vakalarda KHlerin tipik mikroskopik özellikleri mevcuttu.

**Sonuç:** Pediatrik yaş grubunda KH insidansı yaşla birlikte artmaktadır. Daha büyük çocuklarda (>11 yaş) daha sık görülür. Karaciğer lokalize kistler kadın cinsiyette, akciğer yerleşimli kistler erkek cinsiyette daha sık görüldü. Pediatrik yaşta atipik lokalizasyonda hidatik kistler görülebilir. Bu her zaman kistik lezyonların ayırıcı tanısında düşünülmelidir.

**Anahtar kelimeler:** Kist hidatik, ekinokokozis, pediatrik yaş, *Echinococcus granulosus*

Received: 19.01.2022

Accepted: 22.07.2022

### Corresponding Author

Şenay Erdoğan Durmuş MD,  
University of Health Sciences Turkey,  
Basakşehir Çam and Sakura City  
Hospital, Department of Pathology,  
İstanbul, Turkey  
✉ senayerdgn@gmail.com  
ORCID: 0000-0003-3388-9312

**Cite as:** Erdoğan Durmuş Ş, Türker C,  
Kepil N, Emre Ş. Evaluation of Cases  
with Pediatric Hydatid Cyst: A 20-years  
experience from Turkey. J Dr Behcet Uz  
Child Hosp. 2022;12(3):211-215

\*The study was presented in the  
9<sup>th</sup> National & 2<sup>nd</sup> International  
Congress of Hydatidology, 15-17  
November 2018, Nicosia, the  
Turkish Republic of Northern  
Cyprus and printed as an abstract in  
the congress book.

## INTRODUCTION

Hydatid cyst (HC) is a zoonosis which causes serious morbidity and mortality in many regions of the world. Its most common pathogen is *Echinococcus granulosus* (EG) that causes cystic hydatid disease followed by *Echinococcus multilocularis* that causes alveolar hydatid disease. The primary hosts for EG tapeworm, are dogs and canines and the intermediate hosts are frequently sheeps. Human infection occurs by oral intake of products contaminated with parasite eggs or contacting with infected dogs <sup>(1,2)</sup>. EG is endemic in the Mediterranean region, some parts of Russia, Central Asia, China, Australia, some parts of America (especially South America) and North and East Africa <sup>(3)</sup>. HC is also a serious public health problem in Turkey and endemic especially in animal husbandry areas. Socioeconomic, educational, environmental and agricultural factors contribute to the transmission of infection especially in pediatric age <sup>(4,5)</sup>.

HC is usually asymptomatic. Symptoms or complications are associated with the location and the size of the cyst. It can affect various organs and the progression of disease is different in children and adults <sup>(1,6)</sup>. The aim of the study is to evaluate the demographic features, localizations and pathological features of pediatric cases diagnosed as HC in an university hospital of Turkey.

## MATERIALS and METHODS

The study was ethically approved by the local Ethics Committee of the University of Health Sciences Turkey, Basakşehir Çam and Sakura City Hospital, (protocol number: 2021.08.173, date: 19.08.2021).

### Case Analysis

We retrospectively analyzed 503 patients including 79 pediatric cases that were histopathologically diagnosed as HC in İstanbul University-Cerrahpaşa, Cerrahpaşa Faculty of Medicine, Department of Pathology between 2000 and 2020. The data including patients' characteristics, site of lesions were collected from pathology reports. Histopathological examinations were done by light microscopic examination of the sections stained with hematoxylin and eosin.

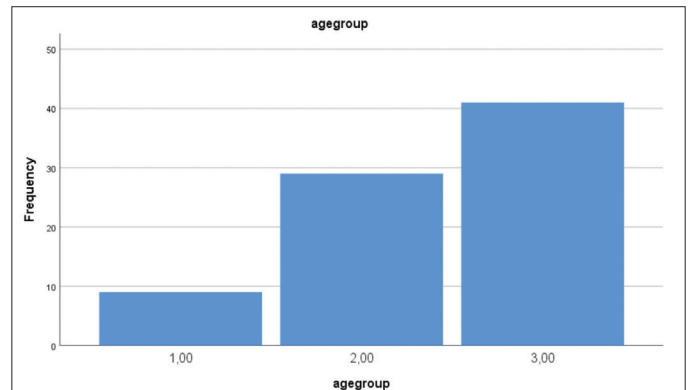
### Statistical Analysis

Data analysis was performed using the SPSS 22.0 program. Descriptive statistics of the results were expressed as mean values, while the nominal variables were shown as the number of cases and percentages. Spearman, Pearson correlation and independent samples

tests were used for comparison and correlations. A  $p=0.05$  was chosen as the level of statistical significance.

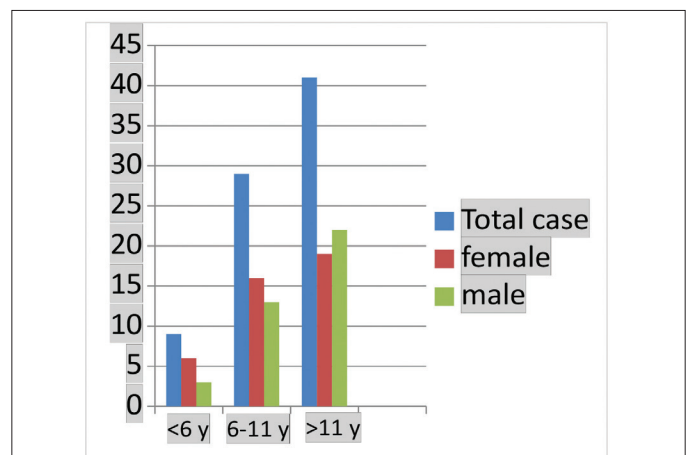
## RESULTS

Patient's mean age was  $11.24 \pm 4.42$  years (age range: 2-18 years). Patient's ages were normally distributed. (Sig:  $>0.05$  in the Kolmogorov-Smirnov test). There was a slight female predominance, with a female to male ratio of 41:38. The patients were distributed in the age groups of  $<6$  ( $n=9$ ) 6-11 ( $n=29$ ), and  $>11$  ( $n=41$ ) years, as indicated. The incidence increased with age (Graphic 1). The gender distribution by age is shown in Graphic 2. There was a female predominance in the age groups of  $<6$  and 6-11 years while male predominance was seen in the age group of  $>11$  years. However there was no significant difference between groups ( $p>0.05$  for each group).



**Graphic 1.** The frequency of hydatid cyst according to age groups

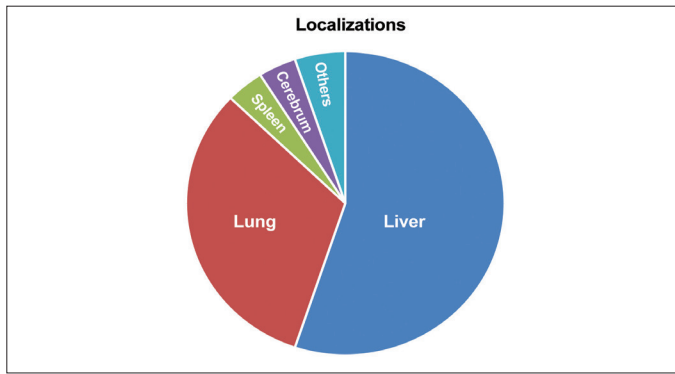
(1:  $<6$  years, 2: 6-11 years, 3:  $>11$  years)



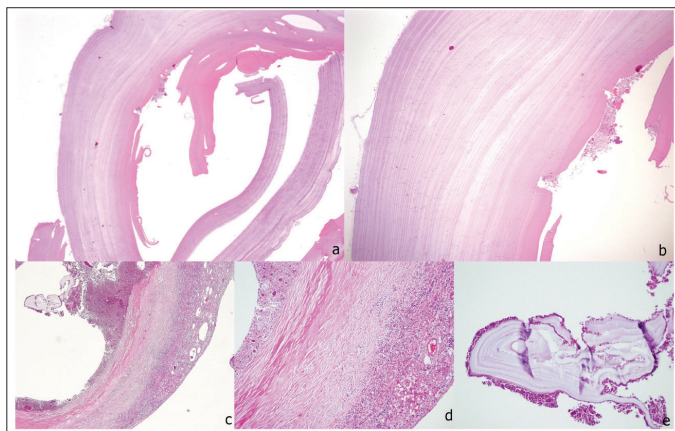
**Graphic 2.** The gender distribution by age

HCs were most frequently localized in the liver (54.4%, n=43), and then in the lungs (31.6%, n=25). The other localization sites were spleen (n=3), cerebrum (n=3), kidney (n=1), orbit (n=1), abdomen (n=1), bone (n=1), and submandibular area (n=1) (Graphic 3). Hepatic HCs were seen mostly in female (25/43; 54.0%), and pulmonary HCs in male (13/25; 52%) patients without any significant difference between genders (p=0.470).

Histopatologically all cases shared the same microscopic features of HCs such as; presence of an avascular, eosinophilic, refractile, chitinous, thin laminated membrane, germinal layer, with or without scolex surrounded by a dense fibrous tissue (Figure 1).



**Graphic 3.** The localization sites of the lesions



**Figure 1.** A- and b- Histologic appearance pulmonary HC. Avascular, eosinophilic, chitinous laminated membrane and a few scolexes. (a- H&Ex100, b- H&Ex200); c, d and e- Histologic appearance of a hepatic HC. The germinal layer with scolexes, laminated membrane, surrounded by dense fibrous tissue and atrophic liver tissue (c- H&Ex40, d- H&Ex100, e- H&Ex200)  
 HC: Hydatid cyst

**DISCUSSION**

Cystic *echinococcus* (CE) is a more common disease in adults but it is known that it is acquired in childhood.

Pediatric cases constitute 10-20% of all cases (7). In our study; 15.7% of total cases with HCs consisted of pediatric cases. In children the most common site for CE is the lung. On the contrary hepatic cysts are mostly seen in adults.

It is suggested that because of relatively higher elasticity of children’s lungs HCs grow faster in the lungs than in the liver in pediatric cases (4,5,7-9). A study from Diyarbakır, indicated that not only in children but also in adult cases cystic pulmonary hydatidosis was found more frequently than other sites (10). But in another study which investigated HC of children; most of cysts were located in the liver (11). In our study the most common site was liver (54.4%), followed by lung (31.6%). Pulmonary HCs are more common in males whereas hepatic cysts are more frequent in females (12). However some other studies showed contrary results (13,14). Similar to literature in our study hepatic HCs were more common in females and pulmonary HCs in males. However there was no significant difference between genders regarding this issue.

HCs can be seen in atypic locations especially in pediatric age. Splenic HC is very rare and generally develops by or intraperitoneal spread from a ruptured liver cyst or systemic dissemination (15). In our study there were 3 splenic HC cases. One of them was primarily localized in spleen however 2 of them occurred after the rupture of a hepatic HC.

Incidence of cerebral CE is 0.8-4%, and 50-75% of them are seen in the pediatric age (15,16). Renal involvement is also very rare (0.4-4%) (15-17). In our study rates of cerebral and renal CE were 3.8% and 1.2%, respectively.

CE also rarely involves bones (0.5-2.4%). It is most commonly seen in spine (35%), pelvis (21%), femur (16%), tibia (10%) and other sites (15-18). In our study one case with sacral bone involvement had a history of operations due to spinal bone HC.

Peritoneal HCs are almost always secondary to hepatic involvement but a few primary peritoneal HC cases have been described (18). In our study in one case HC was localized in abdomen without hepatic involvement.

HCs of the head and neck are also rare. Only a few cases of submandibular HC with submandibular gland involvement have been described (19,20). In our case HC

was located in the submandibular area which expanded to tonsils without a relationship with the salivary gland.

Histopathological examination play a significant role in HC diagnosis. There are three cyst layers consisting of a fibrous outermost pericyst layer, laminated, hyalinized and acellular middle ectocyst layer and the inner endocyst or germinative layer which contains daughter cysts and scolices <sup>(15,18)</sup>.

Differential diagnosis is related to the site of the lesion. Lymphangioma, hemangioma, epidermoid cyst, abscess, hematoma and posttraumatic pseudocyst should be considered in the differential diagnosis of splenic HC. Renal HCs can be misdiagnosed as simple renal cysts, renal abscess, or cystic variants of renal cell carcinoma. A spinal HC can mimic tuberculous spondylitis or chronic osteomyelitis. Benign bone cysts, fibrous dysplasia and also osteosarcoma should be evaluated in the differential diagnosis <sup>(15,18,21)</sup>. HC can be seen in atypical sites especially in pediatric age such as cardiac localizations <sup>(22)</sup>.

Therapeutic management of CE hydatid disease includes medical treatment, surgical treatment and use of minimally invasive methods <sup>(23)</sup>. Our cases consisted of surgically treated patients, and HC was diagnosed histopathologically.

### Study Limitations

The study has also limitations. Although the cases of a reference center with a wide patient profile have been examined, the number of cases is limited. Larger case series from multiple centers may provide more data for childhood HC.

### CONCLUSION

The incidence rate of HC in pediatric age group increases with age. It is more common in older children (>11 years). Hepatic HCs were more common in female patients. Pulmonary HCs were more frequently seen in male patients. HC can be found in all parts of the body and it can be especially seen in atypical localizations in pediatric age. HC should be into account in the differential diagnosis of cystic lesions.

### Acknowledgments

The authors would like to thank Prof. Dr. Nil Çomunoğlu for her contribution to the initial routine review of cases and writing of manuscript. And authors would like to thank to Assoc. Prof. Dr. Şebnem Batur for

her collaboration at the presentation of the study in the 9<sup>th</sup> National & 2<sup>nd</sup> International Congress of Hydatidology, 2018.

### Ethics

**Ethics Committee Approval:** The study was ethically approved by the local Ethics Committee of the University of Health Sciences Turkey, Başakşehir Çam and Sakura City Hospital, (protocol number: 2021.08.173, date: 19.08.2021).

**Informed Consent:** Retrospective study.

**Peer-review:** Externally and internally peer reviewed.

### Author Contributions

Surgical and Medical Practices: Ş.E., Concept: Ş.E.D., N.K., Ş.E., Design: Ş.E.D., N.K., Data Collection and/or Processing: Ş.E.D., C.T., Analysis and/ or Interpretation: Ş.E.D., C.T., N.K., Ş.E., Literature Search: Ş.E.D., C.T., Writing: Ş.E.D.

**Conflict of Interest:** The authors have no conflict of interest to declare.

**Financial Disclosure:** The authors declared that this study has received no financial support.

### REFERENCES

1. Aslanabadi S, Zarrintan S, Abdoli-Oskouei S, Salehpour F, Zarrintan A, Beheshtirouy S, et al. Hydatid cyst in children: A 10-year experience from Iran. *Afr J Paediatr Surg.* 2013;10(2):140-4. doi: 10.4103/0189-6725.115040.
2. Azulay AA, Refaely Y, Ruderman L, Neshet L, Semionov M. A Huge Hydatid Pulmonary Cyst. *Int Med Case Rep J.* 2020;24;13:61-4. doi: 10.2147/IMCRJ.S228657.
3. Grosso G, Gruttadauria S, Biondi A, Marventano S, Mistretta A. Worldwide epidemiology of liver hydatidosis including the Mediterranean area. *World J Gastroenterol.* 2012;18(13):1425-37. doi: 10.3748/wjg.v18.i13.1425.
4. McManus DP, Zhang W, Li J, Bartley PB. Echinococcosis. *Lancet.* 2003;18;362(9392):1295-304. doi: 10.1016/S0140-6736(03)14573-4.
5. Bakal U, Simsek S, Kazez A. Surgical and Molecular Evaluation of Pediatric Hydatid Cyst Cases in Eastern Turkey. *Korean J Parasitol.* 2015;53(6):785-8. doi: 10.3347/kjp.2015.53.6.785.
6. Montazeri V, Sokouti M, Rashidi M. Comparison of pulmonary hydatid disease between children and adults. *Tanaffos.* 2007;6:13-8. Available from: <https://citeseerx.ist.psu.edu/viewdoc/download?doi=10.1.1.1039.6735&rep=rep1&type=pdf>.
7. Berberian G, Rosanova MT, Inda L, Sarkis C, Questa H, Paulin P, et al. Echinococcosis in children: Experience in a tertiary care hospital outside the endemic area. *Arch Argent Pediatr.* 2017;115(3):282-6. doi: 10.5546/aap.2017.eng.282.
8. Mirshemirani A, Razavi S, Sadeghian S. Surgical treatment of pulmonary hydatid cyst in 72 children. *Tanaffos.* 2009;8:56-61. Available from: [http://www.tanaffosjournal.ir/article\\_242239\\_aef00e0c15e09c2923be005d5fc76daf.pdf](http://www.tanaffosjournal.ir/article_242239_aef00e0c15e09c2923be005d5fc76daf.pdf).



9. Vlad DC, Neghina AM, Dumitrascu V, Marincu I, Neghina R, Calma CL. Cystic echinococcosis in children and adults: a seven-year comparative study in western Romania. *Foodborne Pathog Dis.* 2013;10(2):189-95. doi: 10.1089/fpd.2012.1281.
10. Gulsun S, Cakabay B, Nail Kandemir M, Aslan S, Atalay B, Sogutcu N, et al. Retrospective analysis of echinococcosis in an endemic region of Turkey, a review of 193 cases. *Iran J Parasitol* 2010;5(3):20-6. Available from: <https://www.ncbi.nlm.nih.gov/pmc/articles/PMC3279843/pdf/IJP-5-020.pdf>
11. Djuricic SM, Grebeldinger S, Kafka DI, Djan I, Vukadin M, Vasiljevic ZV. Cystic echinococcosis in children - the seventeen-year experience of two large medical centers in Serbia. *Parasitol Int.* 2010;59(2):257-61. doi: 10.1016/j.parint.2010.02.011.
12. Kanat F, Turk E, Aribas OK. Comparison of pulmonary hydatid cysts in children and adults. *ANZ J Surg.* 2004;74(10):885-9. doi: 10.1111/j.1445-1433.2004.03022.x.
13. Mirshemirani A, Khaleghnejad A, Kouranloo J, Sadeghian N, Rouzrokh M, Hasas-Yeganeh S. Liver Hydatid Cyst in Children (A 14-year Review). *Iran J Pediatr.* 2011;21(3):385-9. Available from: <https://www.ncbi.nlm.nih.gov/pmc/articles/PMC3446171/pdf/IJPD-21-385.pdf>.
14. Usluer O, Ceylan KC, Kaya S, Sevinc S, Gursoy S. Surgical management of pulmonary hydatid cysts: is size an important prognostic indicator? *Tex Heart Inst J.* 2010;37(4):429-34. Available from: <https://www.ncbi.nlm.nih.gov/pmc/articles/PMC2929855/>.
15. Keser SH, Selek A, Ece D, Barişik CC, Şensu S, Geçmen GG, et al. Review of Hydatid Cyst with Focus on Cases with Unusual Locations. *Türk Patoloji Derg.* 2017;33(1):30-36. doi: 10.5146/tjpath.2016.01369.
16. Mushtaque M, Mir MF, Malik AA, Arif SH, Khanday SA, Dar RA. Atypical localizations of hydatid disease: experience from a single institute. *Niger J Surg.* 2012;18(1):2-7. doi: 10.4103/1117-6806.95466.
17. Demirci E, Altun E, Çalık M, Durur Subaşı I, Şipal S, Gündoğdu ÖB. Hydatid Cyst Cases with Different Localization: Region of Erzurum. *Türkiye Parazitoloj Derg.* 2015;39(2):103-7. doi: 10.5152/tpd.2015.3590.
18. Polat P, Kantarci M, Alper F, Suma S, Koruyucu MB, Okur A. Hydatid disease from head to toe. *Radiographics.* 2003;23(2):475-94. doi: 10.1148/rg.232025704.
19. Pal PP, Shankar S. Hydatid cyst in submandibular salivary gland. *Indian J Otolaryngol Head Neck Surg.* 2008;60(2):188-90. doi: 10.1007/s12070-008-0040-y.
20. Berkiten G, Topaloglu I. Submandibular hydatid cyst fistulized into the oral cavity. *B-ENT.* 2013;9(3):251-3. Available from: <http://www.b-ent.be/en/submandibular-hydatid-cyst-fistulized-into-the-oral-cavity-16381>.
21. Siwach R, Singh R, Kadian VK, Singh Z, Jain M, Madan H, et al. Extensive hydatidosis of the femur and pelvis with pathological fracture: a case report. *Int J Infect Dis.* 2009;13(6):e480-2. doi: 10.1016/j.ijid.2008.12.017.
22. Cakir IM, Aslan S, Bekci T. Cardiac and hepatic hydatid cyst in a child with chest pain. *Rev Soc Bras Med Trop.* 2021;28;54:e0131 2021. doi: 10.1590/0037-8682-0131-2021.
23. Botezatu C, Mastalier B, Patrascu T. Hepatic hydatid cyst - diagnose and treatment algorithm. *J Med Life.* 2018;11(3):203-9. doi: 10.25122/jml-2018-0045.